This is a digital copy of a book that was preserved for generations on library shelves before it was carefully scanned by Google as part of a project to make the world's books discoverable online.

It has survived long enough for the copyright to expire and the book to enter the public domain. A public domain book is one that was never subject to copyright or whose legal copyright term has expired. Whether a book is in the public domain may vary country to country. Public domain books are our gateways to the past, representing a wealth of history, culture and knowledge that's often difficult to discover.

Marks, notations and other marginalia present in the original volume will appear in this file - a reminder of this book's long journey from the publisher to a library and finally to you.

Usage guidelines

Google is proud to partner with libraries to digitize public domain materials and make them widely accessible. Public domain books belong to the public and we are merely their custodians. Nevertheless, this work is expensive, so in order to keep providing this resource, we have taken steps to prevent abuse by commercial parties, including placing technical restrictions on automated querying.

We also ask that you:

+ *Make non-commercial use of the files* We designed Google Book Search for use by individuals, and we request that you use these files for personal, non-commercial purposes.
+ *Refrain from automated querying* Do not send automated queries of any sort to Google's system: If you are conducting research on machine translation, optical character recognition or other areas where access to a large amount of text is helpful, please contact us. We encourage the use of public domain materials for these purposes and may be able to help.
+ *Maintain attribution* The Google "watermark" you see on each file is essential for informing people about this project and helping them find additional materials through Google Book Search. Please do not remove it.
+ *Keep it legal* Whatever your use, remember that you are responsible for ensuring that what you are doing is legal. Do not assume that just because we believe a book is in the public domain for users in the United States, that the work is also in the public domain for users in other countries. Whether a book is still in copyright varies from country to country, and we can't offer guidance on whether any specific use of any specific book is allowed. Please do not assume that a book's appearance in Google Book Search means it can be used in any manner anywhere in the world. Copyright infringement liability can be quite severe.

About Google Book Search

Google's mission is to organize the world's information and to make it universally accessible and useful. Google Book Search helps readers discover the world's books while helping authors and publishers reach new audiences. You can search through the full text of this book on the web at `http://books.google.com/`

H. M. P.

[illegible] OF THE
[illegible] BOSTON,
[illegible] IN THE
[illegible] LIBRARY

Accessions 4[illegible]8,793

Shelf No. 7781.3
v. 38.
1887.

FOUNDED 1852
ATRIBUS SIT DEUS
NOBIS
BOSTON
CONDITA A.D.
1630.
BOSTON PUBLIC LIBRARY

Received Jan. 26, 1888

THE FRANCIS A. COUNTWAY
LIBRARY OF MEDICINE
BOSTON, MA

SEP 03 2003

TRANSACTIONS

OF THE

PATHOLOGICAL SOCIETY OF LONDON.

VOLUME THE THIRTY-EIGHTH.

*7786.3
v.38
1887

COMPRISING THE REPORT OF THE PROCEEDINGS FOR
THE SESSION 188

THE FRANCIS A. COUNTWAY
LIBRARY OF MEDICINE
BOSTON, MA

SEP 08 2003

LONDON:
SMITH, ELDER & CO., 15, WATERLOO PLACE.
1887.

The present publication, being the Thirty-eighth Volume of Transactions, constitutes the Forty-first published Annual Report of the Pathological Society's Proceedings.

The Council think it right to repeat that the exhibitors are alone responsible for the descriptions given of the Specimens exhibited by them, the only change made in the Reports furnished by the authors being such verbal alterations as were absolutely necessary.

53, Berners Street, Oxford Street;
October, 1887.

BM.
408,793
Jan. 26, 1888

TABLE OF CONTENTS

OF VOLUME XXXVIII.

	PAGE
List of Presidents of the Society	IV
List of Officers and Members for 1887	V—XXXVI
Annual Report of Council for 1886-87	XXXVII
List of Specimens Exhibited during the Session 1886-87	XLI
List of Specimens Reported on by the Committee on Morbid Growths	L
List of Plates	LVII
List of Woodcuts	LIX
Address by the President	1
Diseases, etc., of the Nervous System	9
Diseases, etc., of the Organs of Respiration	83
Diseases, etc., of the Organs of Circulation	96
Diseases, etc., of the Organs of Digestion	127
Diseases, etc., of the Genito-Urinary Organs	164
Diseases, etc., of the Osseous System	250
Diseases, etc., of Organs of Special Sense	321
Morbid Growths and Tumours	323
Diseases, etc., of the Ductless Glands	396
Diseases of the Skin	410
Special Communications	412
Miscellaneous Specimens	439
Diseases, etc., of the Lower Animals	451
Diseases, etc., of Vegetables	460
Index	493

Presidents of the Society.

ELECTED

1846 CHARLES J. B. WILLIAMS, M.D., F.R.S.
1848 CHARLES ASTON KEY.
1850 PETER MERE LATHAM, M.D.
1852 CÆSAR H. HAWKINS, F.R.S.
1853 BENJAMIN GUY BABINGTON, M.D., F.R.S.
1855 JAMES MONCRIEFF ARNOTT, F.R.S.
1857 SIR THOMAS WATSON, BART., M.D., F.R.S.
1859 SIR WILLIAM FERGUSSON, BART., F.R.S.
1861 JAMES COPLAND, M.D., F.R.S.
1863 SIR PRESCOTT G. HEWETT, BART., F.R.S.
1865 THOMAS BEVILL PEACOCK, M.D.
1867 SIR JOHN SIMON, K.C.B., D.C.L., F.R.S.
1869 RICHARD QUAIN, M.D., F.R.S.
1871 JOHN HILTON, F.R.S.
1873 SIR WILLIAM JENNER, BART., M.D., K.C.B., D.C.L., F.R.S.
1875 GEORGE D. POLLOCK.
1877 CHARLES MURCHISON, M.D., LL.D., F.R.S.
1879 JONATHAN HUTCHINSON, F.R.S.
1881 SAMUEL WILKS, M.D., F.R.S.
1883 JOHN WHITAKER HULKE, F.R.S.
1885 JOHN SYER BRISTOWE, M.D., F.R.S.
1887 SIR JAMES PAGET, BART., D.C.L., LL.D., F.R.S.

OFFICERS AND COUNCIL

OF THE

Pathological Society of London,

ELECTED AT

THE GENERAL MEETING, JANUARY 4TH, 1887.

President.

SIR JAMES PAGET, BART., D.C.L., LL.D., F.R.S.

Vice-Presidents.

HENRY CHARLTON BASTIAN, M.D., F.R.S.
JOHN SYER BRISTOWE, M.D., F.R.S.
THOMAS HENRY GREEN, M.D.
RICHARD DOUGLAS POWELL, M.D.
WILLIAM MORRANT BAKER.
SYDNEY JONES.
SIR JOSEPH LISTER, BART., D.C.L., LL.D., F.R.S.
THOMAS PICKERING PICK.

Treasurer.

JOHN WOOD, F.R.S.

Council.

ROBERT E. CARRINGTON, M.D.*
HENRY RADCLIFFE CROCKER, M.D.
DAVID WHITE FINLAY, M.D.
JAMES KINGSTON FOWLER, M.D.
JAMES FREDERIC GOODHART, M.D.
WALTER BAUGH HADDEN, M.D.
A. E. TEMPLE LONGHURST, M.D.
NORMAN MOORE, M.D.
JOSEPH ARDERNE ORMEROD, M.D.
FELIX SEMON, M.D.
ANTHONY A. BOWLBY.
HENRY TRENTHAM BUTLIN.
WILLIAM WATSON CHEYNE.
FREDERIC S. EVE.
CUTHBERT H. GOLDING-BIRD.
JOHN HAMMOND MORGAN.
SAMUEL G. SHATTOCK.
JOHN BLAND SUTTON.
CHARTERS J. SYMONDS.
FREDERICK TREVES.

Honorary Secretaries.

SIDNEY COUPLAND, M.D.
RICKMAN JOHN GODLEE.

Trustees.

RICHARD QUAIN, M.D., F.R.S.
GEORGE D. POLLOCK.
SAMUEL WILKS, M.D., F.R.S.

* Deceased.

*** *Members are requested to indicate to the Secretaries corrections when necessary.*

LIST OF MEMBERS OF THE SOCIETY.

Honorary Members.

BILLROTH, THEODOR, M.D., Professor of Surgery in the University of Vienna.
BRUECKE, ERNST, M.D., Professor of Physiology in the University of Vienna.
CHARCOT, J. M., M.D., Physician to the "Hôpital de la Salpêtrière," and Professor at the Faculty of Medicine of Paris.
DONDERS, FRANZ CORNELIUS, M.D., LL.D., Professor of Physiology and Ophthalmology at the University of Utrecht.
VON HELMHOLTZ, H., M.D., Professor of Physiology in the University of Heidelberg.
LUDWIG, C., M.D., Professor of Physiology in the University of Leipzig.
PASTEUR, PROFESSOR L., Member of the Institute, Paris.
RINDFLEISCH, EDOUARD, M.D., Professor of Pathological Anatomy in the University of Bonn.
THIERSCH, CARL, M.D., Professor of Surgery in the University of Leipzig.
VIRCHOW, RUDOLF, M.D., Professor of Pathological Anatomy in the University of Berlin.

EXPLANATION OF ABBREVIATIONS.

O.M.—Original Member.
Pres.—President.
T.—Treasurer.
V.-P.—Vice-President.
S.—Secretary.
C.—Member of Council.

Those marked thus (†) have paid Composition Fee for Annual Subscription.
Those marked thus (‡) have paid Composition Fee for Transactions.

GENERAL LIST OF MEMBERS.

Elected

1879 ABERCROMBIE, JOHN, M.D., Assistant Physician to Charing Cross Hospital, 23, Upper Wimpole-street, Cavendish-square, W.

1885 ABRAHAM, PHINEAS S., 11, Nottingham-place, W.

1858 ACLAND, Sir HENRY WENTWORTH, K.C.B., M.D., F.R.S., Regius Professor of Medicine, University of Oxford; Broad-street, Oxford.

1883 ACLAND, THEODORE DYKE, M.D., Assistant Physician to St. Thomas's Hospital, and to the Hospital for Consumption, Brompton; 7, Brook-street, Hanover-square, W.

‡1866 ADAMS, ARTHUR BAYLEY.

1869 ADAMS, JAMES EDWARD, Grately, Andover, Hants.

O.M. ADAMS, WILLIAM, Consulting Surgeon to the National Orthopædic Hospital; 5, Henrietta-street, Cavendish-square, W. (C. 1851-4. V.-P. 1867-9.)

1883 ADAMS, WILLIAM COODE, M.B., 1, Elm Avenue, South Hampstead.

1848 AIKIN, CHARLES A., 7, Clifton-place, Sussex-square, Hyde-park, W. (C. 1864-6.)

1872 AIKIN, CHARLES EDMUND, 7, Clifton-place, Sussex-square, Hyde-park, W.

1871 AIR, A. CUMMINGS, 2, Belle Vue, South Norwood, S.E.

1880 AITKEN, Sir WILLIAM, M.D., F.R.S., Professor of Pathology, Army Medical School, Netley, Southampton; Park Villa, Weston-grove-road, Woolston, Southampton.

1869 ALLBUTT, THOMAS CLIFFORD, M.D., F.R.S., Consulting Physician to the Leeds General Infirmary; 35, Park-square, Leeds.

1882 ALLCHIN, WILLIAM HENRY, M.B., Physician to, and Lecturer on Medicine at, the Westminster Hospital; 5, Chandos-street, Cavendish-square, W.

1877 ALTHAUS, JULIUS, M.D., Senior Physician to the Hospital for Epilepsy and Paralysis, Regent's Park; 48, Harley-street, Cavendish-square, W.

1884 ANDERSON, ALEXANDER RICHARD, Resident Surgeon, General Hospital, Nottingham.

1868 ANDERSON, J. FORD, M.D., 1, Buckland-crescent, Belsize-park, N.W.

1880 ANDERSON, JAMES, M.A., M.D., C.M., 84, Wimpole-street, Cavendish-square, W.

1871 ANDERSON, WILLIAM, Assistant Surgeon to, and Lecturer on Anatomy at, St. Thomas's Hospital; 25, Grosvenor-road, Westminster.

1863 ANDREW, JAMES, M.D., Physician to St. Bartholomew's Hospital; 22, Harley-street, W. (C. 1868-70.)

1883 ASHBY, HENRY, M.D., Physician to the Manchester General Hospital for Children, and Lecturer on Diseases of Children at Owens College; 13, St. John-street, Manchester.

Elected

1882 AXE, J. WORTLEY, Professor of Pathological Histology and Morbid Anatomy at the Royal Veterinary College; The Mount, Manor-park-road, Willesden.

1863 BAGSHAWE, FREDERICK, M.A., M.D., 16, Warrior-square, Hastings.

1864 BAKER, WILLIAM MORRANT (V.-P.), Surgeon to St. Bartholomew's Hospital; 26, Wimpole-street, Cavendish-square, W. (C. 1873-6, 1881-3. S. 1878-80. V.-P. 1886-7.)

‡1856 BALDING, DANIEL BARLEY, Royston, Herts.

1880 BALL, BENJAMIN, Professeur à la Faculté de Médecine de Paris, Médecin en Chef de la Clinique des Maladies Mentales; rue du Faubourg St. Honoré, 3, Paris.

1881 BALLANCE, CHARLES A., M.S., Demonstrator of Anatomy, St. Thomas's Hospital; 56, Harley-street, W.

1875 BARKER, ARTHUR E. J., Surgeon and Assistant Teacher of Clinical Surgery, University College Hospital; 87, Harley-street, Cavendish-square, W. (C. 1884-6.)

1885 BARLING, GILBERT, M.B., 85, Edmund-street, Birmingham.

1874 BARLOW, THOMAS, M.D., B.S., Assistant Physician to University College Hospital and Physician to the Children's Hospital, Great Ormond-street; 10, Wimpole-street, Cavendish-square, W. (C. 1879-81.)

1871 BARNES, ROBERT, M.D., 15, Harley-street, Cavendish-square, W. (C. 1883-5.)

1862 BARRATT, JOSEPH GILLMAN, M.D.

1877 BARROW, A. BOYCE, Assistant Surgeon to the Westminster Hospital, and to the West London Hospital; 17, Welbeck-street, Cavendish-square, W.

1881 BARRS, ALFRED GEORGE, M.D., Assistant Physician, General Infirmary, Leeds; 22, Park-place, Leeds.

1879 BARTLETT, HENRY, M.D., Sunnyside, High-road, Balham, S.W.

1853 BARWELL, RICHARD, Surgeon to, and Lecturer on Surgery at, the Charing Cross Hospital; 55, Wimpole-street, Cavendish-square, W. (C. 1862-4.)

1861 BASTIAN, H. CHARLTON, M.A., M.D., F.R.S. (V.-P.), Professor of Clinical Medicine in University College, and Physician to University College Hospital; 20, Queen Anne-street, W. (C. 1869-71. V.-P. 1885-87.)

1877 BATEMAN, ARTHUR W., B.A., Tenterfield, New South Wales.

†1876 BATTESON, JOHN, Medical Officer of the Royal Humane Society; 1, Coborn-place, Bow-road, E.

1882 BATTLE, WILLIAM HENRY, Resident Assistant Surgeon, St. Thomas's Hospital, Albert Embankment, S.E.

1870 BÄUMLER, CHRISTIAN G. H., M.D., Professor of Materia Medica in the University of Erlangen.

1874 BEACH, FLETCHER, M.B., Metropolitan District Asylum, Darenth, near Dartford, Kent.

Elected

1879 BEALE, EDWIN CLIFFORD, M.B., Physician to Great Northern Hospital; 23, Upper Berkeley-street, Portman-square, W.

1852 BEALE, LIONEL S., M.B., F.R.S., Professor of Medicine at King's College, Physician to King's College Hospital; 61, Grosvenor-street, W. (C 1858-9. V.-P. 1874-5.)

1856 BEALEY, ADAM, M.D., M.A., Oak-lea, Harrogate.

†1878 BEANEY, JAMES GEORGE, Senior Surgeon to the Melbourne Hospital, Melbourne, Victoria.

1870 BECK, MARCUS, M.S., Professor of Surgery in University College, London, and Surgeon to University College Hospital; 30, Wimpole-street, Cavendish-square, W. (C. 1875-7.)

1865 BEEBY, WALTER, M.D., Bromley, Kent.

†1880 BEEVOR, CHARLES EDWARD, M.B., 33, Harley-street, Cavendish-square.

1865 BELLAMY, EDWARD, Surgeon to the Charing Cross Hospital; 17, Wimpole street, Cavendish-square, W. (C. 1876-8.)

1883 BENHAM, ROBERT FITZROY, Abercorn House, Baron's-court, S.W.

1847 BENNET, JAMES HENRY, M.D., Mentone, Alpes Maritimes, France.

1886 BENNETT, FREDERICK JOSEPH, 28, George-street, Hanover-square, W.

1877 BENNETT, WILLIAM HENRY, Assistant Surgeon to St. George's Hospital, Surgeon to the Belgrave Hospital for Children; 1, Chesterfield-street, Mayfair, W.

1878 BERNARD, FRANCIS R., M.D., 25, Tentercroft-street, Lincoln.

1882 BERRIDGE, WILLIAM ALFRED, Redhill, Surrey.

1886 BERRY, JAMES, 60, Welbeck-street, Cavendish-square, W.

‡1856 BICKERSTETH, EDWARD R., Surgeon to the Liverpool Royal Infirmary; 2 Rodney-street, Liverpool.

1882 BINDLEY, PHILIP HENRY, M.B.

1878 BINDON, WILLIAM JOHN VEREKER, M.D., 18, St. Ann's-street, Manchester.

1850 BIRKETT, EDMUND LLOYD, M.D., Consulting Physician to the City of London Hospital for Diseases of the Chest; 48, Russell-square, W.C. (C. 1856-7.)

1881 BISS, CECIL YATES, M.D., Assistant Physician to the Middlesex Hospital, Assistant Physician to the Hospital for Consumption, Brompton; 135, Harley-street, Cavendish-square, W.

1865 BISSHOPP, JAMES, Bedford-place, Tunbridge Wells.

1877 BLACK, JAMES, Assistant Surgeon to the North-West London Hospital, Lecturer on Anatomy at Westminster Hospital; 16, Wimpole-street, Cavendish-square, W.

1850 BLAGDEN, ROBERT, Stroud, Gloucestershire.

1863 BLANCHET, JEAN B., M.D., M.S., Montreal, Quebec, Canada.

1876 BLASSON, WILLIAM, Edgeware, Middlesex.

1879 BOILEAU, J. P. H., M.D., Surgeon-Major, Army Medical Department. [India.]

1876 BOND, THOMAS, M.B., Assistant Surgeon and Lecturer on Forensic Medicine to Westminster Hospital; 7, Broad Sanctuary, Westminster, S.W

Elected

1869 BOURNE, WALTER, M.D., Archacho, France.

1861 BOWER, RICHARD NORRIS, Ivel Lodge, Sandy, Bedfordshire.

1881 BOWLBY, ANTHONY A. (C.), Surgical Registrar, St. Bartholomew's Hospital; 75, Warrington-crescent, Maida Vale, W. (C. 1886–7.)

1851 BOWMAN, Sir WILLIAM, Bart., F.R.S., Consulting Surgeon to the Royal Ophthalmic Hospital; 5, Clifford-street, Bond-street, W. (C. 1855-6. V.P. 1882-4.)

1882 BOYD, STANLEY, M.B., Assistant Surgeon to Charing Cross Hospital; 27, Gower-street, W.C.

1883 BRADSHAW, JAMES DIXON, M.B., 30, George-street, Hanover-square, W.

1879 BRAILEY, WM. ARTHUR, M.D., Lecturer on Comparative Anatomy at, and Assistant Ophthalmic Surgeon to, Guy's Hospital; 11, Old Burlington-street, W.

1880 BRAMWELL, BYROM, M.D., 23, Drumsheugh-gardens West, Edinburgh.

1886 BRENCHLEY, ALGERNON DUTTON, M.B., 124, Denmark-hill, S.E.

1877 BRIDGES, ROBERT, M.B., M.A., Manor House, Yattendon, Berks.

‡1867 BRIDGEWATER, THOMAS, M.B. Lond., Harrow-on-the-hill, Middlesex.

1873 BRIGGS, JACOB MYERS, M.D., Coeymans, New York, U.S.

1868 BRIGHT, G. C., M.B., Cannes, France.

1857 BRISCOE, JOHN, 12, Broad-street, Oxford.

1885 BRISCOE, JOHN F., Boreatton-park, Buschurch, Shrewsbury.

†1851 BRISTOWE, JOHN S., M.D., F.R.S. (V.P.), Physician to, and Lecturer on the Theory and Practice of Medicine at, St. Thomas's Hospital; 13, Old Burlington-street, W. (C. 1854-8. S. 1861-4. C. 1865-7. V.-P. 1868-76, 1887. P. 1885-86.)

1860 BROADBENT, WILLIAM HENRY, M.D., Physician to St. Mary's Hospital, and Consulting Physician to the London Fever Hospital; 34, Seymour-street, Portman-square, W. (C. 1871-3. V.P. 1882-4.)

1886 BROCKATT, ANDREW ALEXANDER, St. Thomas's Hospital, S.E.

BROCKMAN, see DRAKE-BROCKMAN.

1852 BRODHURST, BERNARD E., Surgeon to the Royal Orthopædic Hospital; 20, Grosvenor-street, W. (C. 1862-4.)

1884 BRODIE, CHARLES GORDON, Fernhill, Wootton Bridge, Isle of Wight.

1863 BRODIE, GEORGE BERNARD, M.D., Consulting Physician-Accoucheur to Queen Charlotte's Hospital; 3, Chesterfield-street, Mayfair, W.

1865 BROWN, AUGUSTUS, M.D., Glencoe, Hatherley-road, Sidcup, Kent.

1871 BROWN, FREDERICK GORDON, 17, Finsbury-circus, E.C.

1875 BROWNE, GEORGE BUCKSTON, 80, Wimpole-street, Cavendish-square, W.

1866 BROWNE, LENNOX, Surgeon to the Central Throat and Ear Hospital, and to the Royal Society of Musicians; 36, Weymouth-street, Portland-place, W.

1877 BRUCE, J. MITCHELL, M.D., Physician to the Charing Cross Hospital, and Assistant Physician to the Hospital for Consumption, Brompton; 70, Harley-street, Cavendish-square, W.

1855 BRYANT, THOMAS, Surgeon to Guy's Hospital; 65, Grosvenor-street Grosvenor-square, W. (C. 1863-6. V.-P. 1877-79.)

Elected

1854 BUCHANAN, GEORGE, M.D., F.R.S., Medical Officer of the Local Government Board, 24, Nottingham-place, Marylebone-road, W. (C. 1864-6. V.-P. 1880-82.)

1887 BULL, WILLIAM CHARLES, M.B., 35, Clarges-street, Piccadilly.

1878 BURNET, ROBERT WILLIAM, M.D., 6, Upper Wimpole-street, Cavendish-square, W.

1880 BURTON, SAMUEL HERBERT, M.B., Norfolk and Norwich Hospital, Norwich.

1887 BUTLER-SMYTHE, ALBERT CHARLES, Senior Surgeon to the Grosvenor Hospital for Women and Children; 35, Brook-street, Grosvenor-square, W.

1872 BUTLIN, HENRY TRENTHAM (C.), Assistant Surgeon to, and Demonstrator of Practical Surgery and of Disease of the Larynx at, St. Bartholomew's Hospital; 82, Harley-street, Cavendish-square, W. (C. 1876-8, 1887. S. 1884-6.)

1866 BUTT, WILLIAM FREDERICK, 48, Park-street, Park-lane, W.

1883 BUXTON, DUDLEY W., M.D., Administrator and Teacher of the use of Anæsthetics in University College Hospital; Anæsthetist to the Hospital for Women, Soho-square, and to the Dental Hospital; 82, Mortimer-street, Cavendish-square, W.

1856 BUZZARD, THOMAS, M.D., Physician to the National Hospital for the Epileptic and Paralysed; 56, Grosvenor-street, W. (C. 1869-70. V.-P. 1881-3.)

1885 CAHILL, JOHN, 12, Seville-street, Lowndes-square, S.W.

†O.M. CAMPS, WILLIAM, M.D. (C. 1856-9.)

‡1855 CARPENTER, ALFRED, M.D., High-street, Croydon.

1855 CARTER, H. VANDYKE, M.D., Principal of, and Professor of Anatomy and Physiology at, Grant Medical College, Bombay.

1876 CARTER, ROBERT BRUDENELL, Ophthalmic Surgeon to, and Lecturer on Ophthalmic Surgery at, St. George's Hospital; 27, Queen Anne-street, Cavendish-square, W.

1879 CASSIDY, JOSEPH LAMONT, M.D., 44, Harley-street, Cavendish-square, W.

1877 CASSON, JOHN HORNSEY, 47A, Portland-place, W.

†1868 CAVAFY, JOHN, M.D., Physician to St. George's Hospital; 2, Upper Berkeley-street, Portman-square, W. (C. 1881-3.)

1864 CAY, CHARLES VIDLER, Deputy Surgeon-General, Army.

1863 CAYLEY, WILLIAM, M.D., Physician to, and Lecturer on the Principles and Practice of Medicine at, the Middlesex Hospital; 27, Wimpole-street, Cavendish-square, W. (C. 1870-1, 1875-8. S. 1872-4. V.-P. 1884-6.)

1869 CHAFFERS, EDWARD, Keighley, Yorkshire.

1884 CHAFFEY, WAYLAND CHARLES, M.B., Assistant Physician to the Royal Alexandra Hospital for Sick Children, Brighton.

1849 CHALK, WILLIAM OLIVER, 3, Nottingham-terrace, Regent's-park, N.W. (C. 1856-7.)

Elected

1876 CHARLES, T. CRANSTOUN, M.D., M.C., Lecturer on Practical Physiology at St. Thomas's Hospital; Cookstown, Co. Tyrone, Ireland, and 9, Albert Mansions, Victoria-street, Westminster.

1884 CHAVASSE, THOMAS FREDERICK, M.D., C.M., Surgeon to the Birmingham General Hospital; 24, Temple-row, Birmingham.

1879 CHEYNE, WILLIAM WATSON, M.B., C.M. (C.), Assistant Surgeon to King's College Hospital; 59, Welbeck-street, Cavendish-square, W. (C. 1885-7.)

1858 CHILD, GILBERT W.

1873 CHISHOLM, EDWIN, M.D., Abergeldie, Ashfield, near Sydney, New South Wales [care of Messrs. Dawson, 121, Cannon-street, E.C.].

1855 CHOLMELEY, WILLIAM, M.D., Physician to the Great Northern Hospital; 63, Grosvenor-street, W. (C. 1871-3.)

1871 CHRISTIE, THOMAS BEATH, M.D., Superintendent of the Royal India Asylum, Ealing, Middlesex.

1865 CHURCH, WILLIAM SELBY, M.D., Physician to St. Bartholomew's Hospital; 130, Harley-street, Cavendish-square, W. (C. 1871-3.)

†1868 CHURCHILL, FREDERICK, M.B., Surgeon to the Victoria Hospital for Children; 4, Cranley-gardens, Queen's-gate, S.W.

1861 CLAPTON, EDWARD, M.D., 10A, St. Thomas's-street, Southwark, S.E.

1854 CLARK, Sir ANDREW, Bart., M.D., LL.D., F.R.S., Physician to, and Emeritus Professor of Clinical Medicine at, the London Hospital; 16, Cavendish-square, W. (C. 1862-5. V.-P. 1881-3.)

1872 CLARK, ANDREW, Assistant Surgeon to the Middlesex Hospital; 19, Cavendish-place, W.

1886 CLARK, FRANCIS WILLIAM, Croydon Infirmary, Mayday-road, Thornton-heath, Surrey.

1883 CLARKE, ERNEST, M.D., B.S., 21, Lee-terrace, Blackheath, S.E.

1885 CLARKE, JOHN MICHELL, M.B., 2, York Buildings, Clifton, Bristol.

1881 CLARKE, W. BRUCE, M.B., Assistant Surgeon and Demonstrator of Anatomy, St. Bartholomew's Hospital; 46, Harley-street, Cavendish-square, W.

†1875 CLUTTON, HENRY HUGH, M.A., Assistant Surgeon to St. Thomas's Hospital; 2, Portland-place, W. (C. 1884-6.)

‡1865 COATES, CHARLES, M.D., Physician to the Bath General and Royal United Hospitals; 10, Circus, Bath.

1885 COATS, JOSEPH, M.D., 31, Lynedoch-street, Glasgow.

1856 COCKLE, JOHN, M.D., M.A., Physician to the Royal Free Hospital; 8, Suffolk-street, Pall Mall, S.W.

1886 COLLIER, WILLIAM, M.D., 62, High-street, Oxford.

1879 COLLINS, WM. MAUNSELL, M.D., 10, Cadogan-place, S.W.

1878 COLLYNS, R. T. POOLE, Atkinson Morley Hospital, Copse-hill, Wimbledon.

1882 COLQUHOUN, DANIEL, M.D., Dunedin, New Zealand.

Elected

1882 COMPTON, FRANCIS CHARLES, 72, High-street, Poole, Dorset.

1858 COOKE, R. T. E. BARRINGTON, Consulting Surgeon to the Scarborough Dispensary, Consulting Surgeon to the Royal Northern Sea-Bathing Infirmary; 15, St. Nicholas-cliff, Scarborough, Yorkshire.

1871 COOKE, THOMAS, Assistant Surgeon to the Westminster Hospital; 40, Brunswick-square, W.C.

1866 COOMBS, ROWLAND HILL, Mill-street, Bedford.

1879 COOPER, ARTHUR, 20, Old Burlington-street, W.

1853 CORNISH, WILLIAM ROBERT, Surgeon-Major, Madras Army, Sanitary Commissioner for Madras.

1875 CORY, ROBERT, M.D., Assistant Obstetric Physician to St. Thomas's Hospital; 73, Lambeth Palace-road, S.E.

1876 COTTLE, WYNDHAM, M.D., Assistant Surgeon to the Hospital for Diseases of the Skin, Blackfriars; 3, Savile-row, W.

†1861 COUPER, JOHN, Surgeon to the London Hospital, and to the Royal London Ophthalmic Hospital; 80, Grosvenor-street, Grosvenor-square, W. (C. 1870-2.)

1873 COUPLAND, SIDNEY, M.D. (HON. SECRETARY), Physician to, and Lecturer on Practical Medicine at, the Middlesex Hospital; 14, Weymouth-street, Portland-place, W. (C. 1878-81. S. 1886-7.)

1881 CREIGHTON, CHARLES, M.D., 11, New Cavendish-street, W.

1884 CRICHTON, GEORGE, M.B., 3, Cambridge-villas, Twickenham.

1873 CRIPPS, WILLIAM HARRISON, Assistant Surgeon to St. Bartholomew's Hospital; 2, Stratford-place, Oxford-street, W. (C. 1883-5.)

1877 CROCKER, HENRY RADCLIFFE, M.D. (C.), Physician to the Skin Department, University College Hospital; Physician to the East London Hospital for Children; 28, Welbeck-street, Cavendish-square, W. (C. 1887.)

1856 CROFT, JOHN, Surgeon to St. Thomas's Hospital; 48, Brook-street, Grosvenor-square, W. (C. 1870-2. V.-P. 1882–4)

1879 CROOKE, GEORGE FREDERICK, M.D., General Hospital, Birmingham.

1886 CROOKSHANK, EDGAR, M.B., Professor of Bacteriology at King's College, London; 24, Manchester-square, W.

1861 CROSBY, THOMAS BOOR, M.D., 21, Gordon-square, W.C.

1875 CROSS, FRANCIS RICHARDSON, 5, The Mall, Clifton, Bristol.

1885 CULLINGWORTH, CHARLES JAMES, M.D., 260, Oxford-road, Manchester.

1871 CUMBERBATCH, ELKIN, Aural Surgeon at St. Bartholomew's Hospital; 17, Queen Anne-street, W.

1858 CUMBERBATCH, LAURENCE T., M.D., 25, Cadogan-place, Sloane-street, S.W.

1873 CURNOW, JOHN, M.D., Professor of Anatomy at King's College, Physician to King's College Hospital, and Senior Visiting Physician to the Seamen's Hospital; 3, George-street, Hanover-square, W. (C. 1882-4.)

Elected

‡1865 CURRAN, WILLIAM, M.D. [33, Auriol-road, West Kensington, W.], care of Mr. Lewis, Gower-street.

1884 DAKIN, W. RADFORD, M.D., B.S., 57, Welbeck-street, Cavendish-square, W.

1884 DALLAWAY, DENNIS, 75, Park-street, Grosvenor-square, W.

1883 DALTON, NORMAN, M.D., Assistant Physician to King's College Hospital; 18, Clement's-inn, Strand, W.C.

1873 DAVIDSON, ALEXANDER, M.D., Physician to the Liverpool Royal Infirmary, Lecturer on Pathology at the Liverpool Medical School; 2, Gambier-terrace, Liverpool.

1885 DAVIES, ARTHUR, M.B., 23, Finsbury-square, E.C.

1869 DAVIES-COLLEY, J. NEVILLE C., M.B. Surgeon to Guy's Hospital; 36, Harley-street, Cavendish-square, W. (C. 1880-82.)

1883 DAVIS, EDWIN HARRY, West Hartlepool.

‡1859 DAVIS, FRANCIS WILLIAM, R.N., Surgeon to the Naval Medical Establishment, Lisbon. [Agents: Messrs. Hallett and Co., 7, St. Martin's-place, Trafalgar-square, W.C.]

1879 DAVY, HENRY, M.D., Physician to the Devon and Exeter Hospital; 34, Southernhay, Exeter.

1866 DAY, WILLIAM HENRY, M.D., Physician to the Samaritan Free Hospital for Women and Children; 10, Manchester-square, W.

1872 DECASTRO, JAMES C., M.B. [Pau, France.]

1887 DELÉPINE, SHERIDAN, M.B., 6, Chapel-place, Cavendish-square, W.

1880 DENT, CLINTON T., Assistant Surgeon to St. George's Hospital; 61, Brook-street, Grosvenor-square W.

1863 DEVEREUX, DANIEL, Tewkesbury, Gloucestershire.

1856 DICK, H., M.D.

1871 DICKINSON, EDWARD HARRIMAN, M.A., M.D., Physician to the Liverpool Northern Hospital, and Lecturer on Comparative Anatomy at the Liverpool School of Medicine; 162, Bedford-street, Liverpool.

1858 DICKINSON, WILLIAM HOWSHIP, M.D., Physician to the Hospital for Sick Children, Physician and Lecturer on Medicine to St. George's Hospital; Honorary Fellow of Caius College, Cambridge; 9, Chesterfield-street, Mayfair, W. (C. 1866-8. S. 1869-71. V.-P. 1872-4.)

1872 DIVER, EBENEZER, M.D., Kenley, Caterham-valley, Surrey.

1872 DORAN, ALBAN HENRY GRIFFITHS, Surgeon to Out-Patients, Samaritan Hospital; 9, Granville-place, W. (C. 1882-84.)

†1866 DOWN, JOHN LANGDON H., M.D., Physician to, and Lecturer on Clinical Medicine at, the London Hospital; 81, Harley-street, Cavendish-square, W. (C. 1872-4.)

1872 DOWSE, THOMAS STRETCH, M.D., 14, Welbeck-street, Cavendish-square, W.

1877 DRAKE-BROCKMAN, E. F., Madras Medical Service [care of Mr. Lewis, Gower-street, W.C.]

1880 DRESCHFELD, JULIUS, M.D., Physician to the Manchester Infirmary; 325, Oxford-road, Manchester.

Elected

1879 DREWITT, F. G. DAWTREY, M.D., 52, Brook-street, Grosvenor-square, W.

1865 DUCKWORTH, Sir DYCE, M.D., Physician to St. Bartholomew's Hospital; 11, Grafton-street, Bond-street, W. (C. 1877.)

1863 DUDFIELD, THOMAS ORME, M.D., 14, Ashburn-place, South Kensington, S.W.

1847 DUDGEON, ROBERT E., M.D., 53, Montagu-square, W.

1852 DUFF, GEORGE, M.D., High-street, Elgin.

1865 DUFFIN, ALFRED BAYNARD, M.D., Physician to King's College Hospital; 18, Devonshire-street, Portland-place, W. (C. 1872-4.)

1875 DUKA, THEODORE, M.D., Surgeon-Major, H.M.'s Bengal Army.

1868 DUKE, OLIVER THOMAS, M.B., India.

1871 DUKES, CLEMENT, M.D., B.S. Lond., Physician to Rugby School; Sunnyside, Rugby.

1877 DUNBAR, J. J. MACWHIRTER, M.D., Assistant House-Physician to St. George's Hospital; Hedingham House, Clapham-common, S.W.

1877 DUNCAN, ANDREW, M.D., 8, Henrietta-street, Covent-garden, W.C.

1880 DUNCAN, JAS. MATTHEWS, M.D., LL.D., F.R.S., Obstetric Physician to St. Bartholomew's Hospital; 71, Brook-street, Grosvenor-square, W.

1884 DUNN, LOUIS ALBERT, M.B., B.S., Demonstrator of Anatomy, Guy's Hospital; and Assistant Surgeon to the East London Hospital for Children; 15, St. Thomas's-street, S.E.

1861 DUNN, ROBERT WILLIAM, 13, Surrey-street, Strand, W.C.

1858 DURHAM, ARTHUR EDWARD, Surgeon to Guy's Hospital; 82, Brook-street, Grosvenor-square, W. (C. 1869-71. V.P. 1883-5.)

1879 DURHAM, FREDERIC, M.B., 82, Brook-street, Grosvenor-square, W.

†1880 EDMUNDS, WALTER, M.D., 79, Lambeth Palace-road, S.E.

1882 EDWARDES, EDWARD JOSHUA, M.D., 16, Acacia-road, St. John's Wood, N.W.

1882 EDWARDS, F. SWINFORD, Surgeon to the West London Hospital, and to St. Peter's Hospital for Stone; 93, Wimpole-street, Cavendish-square, W.

1883 ELDER, GEORGE, M.D., Surgeon to the Hospital for Women; 17, Regent-street, Nottingham.

1867 ELLIS, JAMES, M.D., California.

1873 ENGELMANN, GEORGE JULIUS, M.D., A.M., 3003, Locust-street, St. Louis, Miss., U.S.

1846 ERICHSEN, JOHN ERIC, LL.D., F.R.S., Surgeon Extraordinary to Her Majesty the Queen, Emeritus Professor of Surgery at University College, and Consulting Surgeon to University College Hospital; 6, Cavendish-place, Cavendish-square, W. (C. 1849-51. V.-P. 1863-4.)

1853 EVANS, CONWAY, M.D., The Garden House, Clement's-inn, W.C. (C. 1867-8.)

1875 EVANS, JULIAN, A.M., M.D., Physician to the Victoria Hospital for Children; 123, Finboro'-road, Redcliffe-square, West Brompton, S.W.

Elected

1879 EVE, FREDERIC S. (C.), Pathological Curator of the Museum, Royal College of Surgeons of England, and Assistant Surgeon to the London Hospital; 15, Finsbury-circus, E.C. (C. 1885-7.)

1876 EWART, JAMES COSSAR, M.B., C.M., School of Medicine, Edinburgh.

1881 EWART, JOSEPH, M.D., late Professor of Medicine at Calcutta Medical College; Montpellier Terrace, Brighton.

1877 EWART, WILLIAM, M.B., Assistant Physician to, and Lecturer on Physiology at, St. George's Hospital; 33, Curzon-street, Mayfair, W.

‡1859 EWENS, JOHN, 14, Whiteladies-road, Clifton, Bristol.

1887 EYLES, CHARLES HENRY, Myrtle-lodge, Windsor-road, New Hampton; and Gold Coast Colony.

1872 FAYRER, Sir JOSEPH, K.C.S.I., M.D. F.R.S. Hon. Physician to the Queen, Surgeon-Major, Bengal Army, Examining Medical Officer to the Secretary of State for India in Council; 53, Wimpole-street, Cavendish-square, W. (C. 1880-2.)

1872 FENN, EDWARD L., M.B., The Old Palace, Richmond, Surrey.

1880 FENWICK, BEDFORD, M.D., Assistant Physician to the City of London Hospital for Diseases of the Chest; 20, Upper Wimpole-street, Cavendish-square, W.

1883 FENWICK, E. HURRY, Assistant Surgeon to the London Hospital, Surgeon and Pathologist to St. Peter's Hospital for Stone; 5, Old Burlington-street, W.

1872 FENWICK, JOHN C. J., M.D., Physician to the Durham County Hospital; 25, North-road, Durham.

1863 FENWICK, SAMUEL, M.D., Physician to the London Hospital; 29, Harley-street, W.

1885 FÉRÉ, CHARLES, M.D., Médecin d'Bicêtre; Boulevard St. Michel, 37, Paris.

1846 FINCHAM, GEORGE T., M.D., Consulting Physician to the Westminster Hospital; 13, Belgrave-road, S.W. (C. 1855.)

1876 FINLAY, DAVID W., M.D. (C.), Physician to the Middlesex Hospital; 9, Lower Berkeley-street, Portman-square, W. (C. 1886-7.)

1870 FISH, JOHN CROCKETT, M.D., 92, Wimpole-street, W.

1859 FISHER, ALEXANDER, M.D., Assistant Surgeon R.N., Her Majesty's Ship "Endymion."

1882 FLEMING, GEORGE, C.B., LL.D., F.R.C.V.S., Principal Veterinary Surgeon to the Army, Cathcart Lodge, Tyrwhitt-road, St. John's, S.E.

1872 FORBES, DANIEL MACKAY, 204, Hoxton-street, N.

‡1866 FOSTER, Sir BALTHAZAR WALTER, M.D., M.P., Physician to the General Hospital, Birmingham; 16, Temple-row, Birmingham.

1872 FOTHERBY, HENRY J., M.D., Physician to the Metropolitan Free Hospital; 3, Finsbury-square, E.C.

Elected

1880 FOWLER, JAMES KINGSTON, M.A., M.D. (C.), Assistant Physician to, and Lecturer on Pathological Anatomy at, the Middlesex Hospital, and Assistant Physician to the Hospital for Consumption, Brompton; 35, Clarges-street, Piccadilly, W. (C. 1887.)

1878 FOX, THOMAS COLCOTT, M.B., B.A., Physician to the Skin Department of the Westminster Hospital, and to the Paddington Green Hospital; 14, Harley-street, Cavendish-square, W.

1858 FRANCIS, CHARLES RICHARD, M.B., Bengal Medical Establishment, Indian Army.

O.M. FRERE, J. C.

1864 FRODSHAM, JOHN MILL, M.D., Streatham, S.W.

1880 GABBETT, HENRY SINGER, M.B., 20, Burlington-place, Eastbourne.

‡1858 GAIRDNER, WILLIAM TENNANT, M.D., LL.D., Professor of Medicine in the University of Glasgow; 225, St. Vincent-street, Glasgow.

1870 GALTON, EDMUND H., Springfield House, Brixton-hill, S.W.

1870 GALTON, JOHN H., M.D., 39, Anerley-road, Upper Norwood, S.E.

1855 GAMGEE, J.

1877 GARLICK, GEORGE, M.D., 45, Woburn-place, Russell-square, W.C.

1846 GARROD, Sir ALFRED BARING, M.D., F.R.S., Consulting Physician to King's College Hospital; 10, Harley-street, Cavendish-square, W. (C. 1851. V.-P. 1863-5.)

1879 GARSTANG, THOMAS WALTER HARROPP, The Heath, Knutsford, Cheshire.

1872 GARTON, WILLIAM, M.D., Hardshaw-street, St. Helen's, Lancashire.

1880 GIBBES, HENEAGE, M.B., Lecturer on Physiology at the Westminster Hospital; Park-cottage, Hampton-Wick.

1853 GIBBON, SEPTIMUS, M.D., 39, Oxford-terrace, Hyde-park, W.

1878 GIBBONS, R. A., M.D., Physician to the Grosvenor Hospital for Women and Children; 29, Cadogan-place, S.W.

1876 GILL, JOHN, M.D., 31, Apsley-road, Clifton, Bristol.

1881 GLYNN, THOMAS ROBINSON, M.D., Physician to the Liverpool Royal Infirmary; 62, Rodney-street, Liverpool.

1873 GODLEE, RICKMAN JOHN, M.B., B.S. (HON. SECRETARY), Assistant Surgeon to University College Hospital; Teacher of Operative Surgery in University College, London; 81, Wimpole-street, Cavendish-square, W. (C. 1877-80. S. 1887.)

1875 GODSON, CLEMENT, M.D., Assistant Physician-Accoucheur to St. Bartholomew's Hospital; Consulting Physician to the City of London Lying-in Hospital; 9, Grosvenor-street, W.

1879 GODWIN, CHARLES HENRY YOUNG, Surgeon Major, Army; Victoria Hospital, Netley.

1878 GOLDING-BIRD, CUTHBERT H., M.B. (C.), Assistant Surgeon to, and Lecturer on Physiology at, Guy's Hospital; 18, St. Thomas's-street, S.E. (C. 1885-7.)

Elected

1871 GOODHART, JAMES FREDERIC, M.D. (C.), Physician to, and Lecturer on Pathology at, Guy's Hospital; Physician to the Evelina Hospital for Sick Children; 25, Weymouth-street, Portland-place, W. (C. 1876-8, 1886-7. S. 1883-5.)

1875 GOULD, ALFRED PEARCE, M.S., Assistant Surgeon to the Middlesex Hospital,; 16, Queen Anne-street, W. (C. 1883-5.)

1870 GOWERS, WILLIAM RICHARD, M.D., F.R.S. (C.), Professor of Clinical Medicine in University College, London, and Physician to University College Hospital; 50, Queen Anne-street, Cavendish-square, W. (C. 1878-9.)

1858 GOWLLAND, PETER Y., Surgeon to St. Mark's Hospital; 34, Finsbury-square, E.C.

1867 GREEN, T. HENRY, M.D. (V.-P.), Physician to Charing Cross Hospital, Assistant Physician to the Hospital for Consumption, Brompton; 74, Wimpole-street, W. (C. 1871-3, 1878-9. S. 1875-6. V.-P. 1886-7.)

1873 GREENFIELD, WILLIAM SMITH, M.D., B.S., Professor of General Pathology in the University of Edinburgh; 7, Heriot-row, Edinburgh. (C. 1877-80.)

‡1855 GREENHILL, WILLIAM ALEXANDER, M.D., 5, The Croft, Hastings.

1863 GREENHOW, EDWARD HEADLAM, M.D., F.R.S., Consulting Physician to the Middlesex Hospital; Castle Lodge, Reigate. (C. 1867-9. V.-P. 1877-8.)

1886 GREVES, EDWIN HYLA, M.D., Rodney House, Suffolk-road, Bournemouth.

1885 GRIFFITH, WALTER SPENCER ANDERSON, M.B., Physician to the Samaritan Free Hospital for Women and Children; 114, Harley-street, Cavendish-square, W.

1887 GRIFFITHS, JOSEPH, M.B., Cambridge.

1876 GRIFFITHS, THOMAS D., M.D., Hearne Lodge, Swansea.

1882 GROSS, CHARLES, M.B., St. Saviour's Infirmary; Walworth, S.E.

1861 GUENEAU DE MUSSY, HENRI, M.D., 15, Rue du Cirque, Paris.

1863 GULL, SIR WILLIAM WITHEY, Bart., M.D., D.C.L., F.R.S., Physician in Ordinary to H.M. the Queen; Consulting Physician to Guy's Hospital; 74, Brook-street, Grosvenor-square, W.

1881 GULLIVER, GEORGE, M.B., Assistant Physician to, and Lecturer on Comparative Anatomy at, St. Thomas's Hospital; 16, Welbeck-street Cavendish-square, W.

1880 GUNN, R. MARCUS, M.B., C.M., 54, Queen Anne-street, Cavendish-square, W.

1876 GWYTHER, JAMES, M.B., St. Mary Church, Torquay.

1887 HABERSHON, SAMUEL HERBERT, M.D., 2, Upper Wimpole-street, Cavendish-square, W.

1849-59 HABERSHON, SAMUEL OSBORNE, M.D., 70, Brook-street, Grosvenor-square, W. (Re-elected 1874.) (C. 1855-6.)

1851 HACON, E. DENNIS, 269, Mare-street, Hackney, N.E. (C. 1872.)

1879 HADDEN, WALTER BAUGH, M.D. (C.), Assistant Physician to, and Demonstrator of Morbid Anatomy at, St. Thomas's Hospital; 21, Welbeck-street, W. (C. 1886-7.)

Elected

1882 HAIG, A., M.B., 30, Welbeck-street, Cavendish-square, W.

1877 HALLOWES, FREDERICK BLACKWOOD, Redhill, Surrey.

1886 HAMILTON, DAVID JAMES, M.B., Professor of Pathology at the University of Aberdeen, 1, Albyn-place, Aberdeen.

1886 HANDFORD, HENRY, M.D., 8, Regent-street, Nottingham.

1882 HARBINSON, ALEXANDER, M.D., County Lunatic Asylum, Lancaster.

1848 HARE, CHARLES JOHN, M.D., Consulting Physician to University College Hospital; Berkeley House, 15, Manchester Square, W. (C. 1852-4. V.-P.1874-7.)

†1856 HARLEY, GEORGE, M.D., F.R.S., 25, Harley-street, Cavendish-square, W. (C. 1862-5. V.-P. 1878-80.)

1872 HARRIS, HENRY, M.D., Trengweath-place, Redruth, Cornwall.

1879 HARRIS, VINCENT DORMER, M.D., Demonstrator of Physiology, St. Bartholomew's Hospital, Senior Assistant Physician, Victoria Park Hospital; 31, Wimpole-street, Cavendish-square, W.

†1858 HART, ERNEST, 38, Wimpole-street, Cavendish-square, W. (C. 1867-8.)

1870 HAWARD, JOHN WARRINGTON, Surgeon to St. George's Hospital; 16, Savile-row, W. (C. 1879-81.)

1886 HAWKINS, FRANCIS HENRY, M.B., Physician to St. George's and St. James's Dispensary; 22, Henrietta-street, Cavendish-square, W.

1856 HEATH, CHRISTOPHER, Holme Professor of Clinical Surgery in University College, and Surgeon to University College Hospital; 36, Cavendish-square, W. (C. 1866-7. V.-P. 1879-81.)

1881 HEBB, RICHARD G., M.D., Westminster Hospital, S.W.

1884 HEBBERT, CHARLES ALFRED, Westminster Hospital.

1878 HELLIER, JOHN B., M.B., Headingley, Leeds.

1879 HENDERSON, GEORGE COURTENAY, M.D., Kingston, Jamaica, West Indies.

1869 HENSLEY, PHILIP J., M.D., Assistant Physician and Lecturer on Forensic Medicine, St. Bartholomew's Hospital; 4, Henrietta-street, Cavendish-square, W.

1884 HERRINGHAM, WILMOT PARKER, M.B., Assistant Demonstrator of Anatomy at St. Bartholomew's Hospital, and Assistant Physician to the West London Hospital; 22, Bedford-square, W.C.

O.M. HEWETT, SIR PRESCOTT G., Bart., F.R.S., Consulting Surgeon to St. George's Hospital; Chesnut Lodge, Horsham, Sussex. (C. 1846-52. V.-P. 1854-7. *Pres.* 1863-4. V.-P. 1865-8.)

1855 HEWITT, GRAILY, M.D., Consulting Obstetric Physician to University College Hospital; 36, Berkeley-square, W. (C. 1865-7.)

1864 HICKMAN, WILLIAM, M.B., Surgeon to the Samaritan Free Hospital; 1, Dorset-square, N.W.

1860 HILL, M. BERKELEY, M.B., Surgeon to University College Hospital, and Surgeon for Out-Patients to the Lock Hospital; 66, Wimpole-street, Cavendish-square, W. (C. 1874-5.)

1875 HITCHCOCK, HARRY KNIGHT, M.D., Christowell, Branksome-park, Bournemouth, Hants.

1880 HOBSON, JOHN MORRISON M.D., 65, Lower Addiscombe-road, Croydon.

Elected

1854 HOLMES, TIMOTHY, Surgeon to St. George's Hosp tal; 18, Great Cumberland-place, Hyde-park, W. (C. 1862-3. S. 1864-7. C. 1868. V.-P. 1869-71.)

1850 HOLT, BARNARD WIGHT, Consulting Surgeon to the Westminster Hospital; 14, Savile-row, W. (C. 1853.)

O.M. HOLTHOUSE, CARSTEN. (C. 1852-4, V.-P. 1874-5.)

1878 HOOD, DONALD WILLIAM CHARLES, M.D., Physician to the North-West London Hospital, Physician to the West London Hospital; 43, Green-street, Park Lane, W.

1864 HOOD, WHARTON P., M.D., 11, Seymour-street, Portman-square, W.

1870 HOPE, WILLIAM, M.D., 56, Curzon-street, Mayfair, W.

1882 HOPKINS, John, Medical Superintendent, Central London Sick Asylum, Cleveland-street, W.

1879 HORROCKS, PETER, M.D., Assistant Obstetric Physician to Guy's Hospital, 9, St. Thomas's-street, S.E.

1883 HORSLEY, VICTOR, M.B., B.S., F.R.S., Assistant Surgeon to University College Hospital, Professor of Pathology, University College, London, Superintendent of the Brown Institution, Wandsworth-road; 80, Park-street, Grosvenor-square, W.

1877 HOUGHTON, WALTER B., M.D., late Assistant Physician to Charing Cross Hospital; Church Villa, Warrior-square, St. Leonards-on-Sea.

1880 HOVELL, T. MARK, Aural Surgeon to the London Hospital; 3, Mansfield-street, Portland-place, W.

1875 HOWSE, HENRY GREENWAY, M.S., Surgeon to Guy's Hospital, and to the Evelina Hospital for Sick Children; 59, Brook-street, Grosvenor-square. W. (C. 1878-81.)

1884 HUDSON, CHARLES LEOPOLD, Pathologist and Curator of the Museum, Middlesex Hospital; 34, Welbeck-street, Cavendish-square, W.

†1856 HUDSON, JOHN, M.D., 11, Cork-street, Bond-street, W.

1854 HULKE, JOHN WHITAKER, F.R.S., Surgeon to the Middlesex Hospital and Surgeon to the Royal London Ophthalmic Hospital; 10, Old Burlington-street, W. (C. 1863-5. S. 1868-72. V.-P. 1873-6, 1885-6. T. 1877-9. P. 1883-4.)

1853 HUMBY, EDWIN, M.D., 83, Hamilton-terrace, St. John's Wood, N.W.

1874 HUMPHREYS, HENRY, M.D., late Physician to the Children's Hospital at Pendlebury; 16, Warrior Gardens, St. Leonards-on-Sea.

1883 HUMPHRY, GEORGE MURRAY, M.D., F.R.S., Surgeon to Addenbrooke's Hospital; Professor of Surgery in the University of Cambridge.

1852 HUTCHINSON, JONATHAN, F.R.S., Consulting Surgeon to the London Hospital and to the Royal London Ophthalmic Hospital, Moorfields; 15, Cavendish-square, W. (C. 1856-9. V.-P. 1872-3, 1881-3. P. 1879-80.)

1882 HUTCHINSON, JONATHAN, junr., 15, Cavendish-square, W.

1884 HUTTON, HENRY RICHMOND, M.B., 8A, St. John-street, Manchester.

1880 INGRAM, ERNEST FORTESCUE, Newcastle, Natal, S. Africa.

Elected

1886 JACKSON, ARTHUR MOLYNEUX, M.B., Surrey County Asylum, Tooting, S.W.

1865 JACKSON, J. HUGHLINGS, M.D., F.R.S., Physician to the London Hospital, Physician to the National Hospital for the Paralysed and Epileptic; 3, Manchester-square, W. (C. 1872-3.)

1886 JACKSON, PHILIP J., 6, Great Dover-street, S.E.

1875 JALLAND, WILLIAM HAMERTON, St. Leonard's House, Museum-street, York.

‡1853 JARDINE, JOHN LEE, Capel, near Dorking, Surrey.

1847 JAY, EDWARD, 7, Duke-street, Grosvenor-square, W.

O.M. JENNER, SIR WILLIAM, Bart., M.D., D.C.L., K.C.B., F.R.S., Consulting Physician to University College Hospital; 63, Brook-street, Grosvenor-square, W. (C. 1850-3. V.-P. 1862-4 1875-6. *Pres.* 1873-4.)

1881 JENNINGS, WILLIAM OSCAR, M.D., 8, Rue Roy, Paris.

1875 JESSETT, FREDERIC BOWREMAN, 16, Upper Wimpole-street, W.

1879 JESSOP, CHARLES MOORE, Army and Navy Club, Pall Mall, S.W.

1866 JESSOP, THOMAS RICHARD, 31, Park-square, Leeds.

1878 JOHNSON, ARTHUR JUKES, Yorkville, Ontario, Canada.

1876 JOHNSON, CHARLES HENRY, late Staff Surgeon, Turkish Contingent; Winton House, Basingstoke, Hants.

O.M. JOHNSON, GEORGE, M.D., F.R.S., Consulting Physician to King's College Hospital; 11, Savile-row, W. (C. 1846-50. V.-P. 1863-4, 1884-6. T. 1880-83.)

1881 JOHNSTON, JOSEPH, M.D., Brigade Surgeon, Army Medical Department; 24, St. John's Wood-park, N.W.

1854 JOHNSTONE, ATHOL A. W., St. Moritz House, 61, Dyke-road, Brighton.

1853 JONES, SYDNEY, M.B. (V.-P.), Surgeon to St. Thomas's Hospital; 16, George-street, Hanover-square, W. (C. 1864-6. V.-P. 1886-7.)

1862 JONES, THOMAS RIDGE, M.D., Physician to the Victoria Hospital for Children; 4, Chesham-place, S.W. (C. 1882-4.)

1858 JONES, WILLIAM PRICE, M.D., Claremont-road, Surbiton, Kingston.

1886 JULER, HENRY EDWARD, Assistant Surgeon Royal Westminster Ophthalmic Hospital, Junior Ophthalmic Surgeon to St. Mary's Hospital; 77, Wimpole-street, Cavendish-square, W.

1867 KELLY, CHARLES, M.D., Professor of Hygiene, King's College, Strand; Broadwater-road, Worthing, Sussex. (C. 1874.)

1846 KENT, THOMAS J., 89, Piccadilly, W.

1852 KERSHAW, W. WAYLAND, M.D., Kingston-on-Thames.

1879 KESTEVEN, WILLIAM HENRY, 16, Parkhurst-road, Holloway, N.

1859 KIALLMARK, HENRY WALTER, 5, Pembridge-gardens, Bayswater, W. (C. 1875-6.)

1882 KIDD, PERCY, M.D., Assistant Physician to the Hospital for Consumption, Brompton; 60, Brook-street, Grosvenor-square, W.

1867 KING, EDWIN HOLBOROW, Netley Court, Southampton.

1871 KING, ROBERT, M.B., Bargaly, Newton Stewart, N.B.

Elected

1852 Kingdon, J. Abernethy, Surgeon to the City Dispensary, and to the City of London Truss Society; 2, New Bank-buildings, Lothbury, E.C.

1878 Klein, Edward Emanuel, M.D., F.R.S., Joint Lecturer on Physiology at St. Bartholomew's Hospital; 94, Philbeach-gardens, Warwick-road, Earl's Court, S.W.

1875 Lacy, C. S. De Lacy, M.B., 31, Grosvenor-street, W.

1878 Lancereaux, Etienne, M.D., 44, Rue de la Bienfaisance, Paris.

1882 Lane, William Arbuthnot, M.B., M.S., Demonstrator of Anatomy at Guy's Hospital; Assistant Surgeon to the Hospital for Sick Children, Great Ormond-street; 14, St. Thomas's-street, S.E.

1865 Langton, John, Surgeon to, and Lecturer on Anatomy at, St. Bartholomew's Hospital, and Surgeon to the City of London Truss Society; 2, Harley-street, Cavendish-square, W. (C. 1882-4.)

1886 Lankester, Herbert Henry, M.B., St. Thomas's Hospital, S.E.

1869 Larcher, O., M.D. Par., Laureate of the Institute of France, of the Medical Faculty and Academy of Paris; 97, Rue de Passy, Paris. [M. Kliensieck, Libraire, Rue de Lille, 11, Paris, per Messrs. Longmans.]

1884 Larder, Herbert, Medical Superintendent, Whitechapel Infirmary, E.

1873 Latham, Peter Wallwork, M.D., Physician to Addenbrooke's Hospital, and Downing Professor of Medicine, Cambridge University; 17, Trumpington-street, Cambridge.

1876 Law, William Thomas, M.D., 9, Norfolk-crescent, Hyde-park, W.

1883 Lawford, John Bowring, M.D., C.M., Assistant Ophthalmic Surgeon to St. Thomas's Hospital; 6, Upper Wimpole-street, W.

1853 Lawrence, Henry John Hughes, The Club, Tenby. (C. 1873-5.)

1859 Lawson, George, Surgeon Oculist to H.M. the Queen, Surgeon to the Middlesex Hospital, and Surgeon to the Royal London Ophthalmic Hospital, Moorfields; 12, Harley-street, Cavendish-square, W. (C. 1870-1. V.-P. 1884-5.)

1879 Laycock, George Lockwood, M.B., 12, Upper Berkeley-street, Portman-square, W.

1875 Lediard, Henry Ambrose, M.D., Surgeon to the Cumberland Infirmary; 41, Lowther-street, Carlisle.

1852 Lee, Henry, Consulting Surgeon to St. George's Hospital; 9, Savile-row, W. (C. 1860-2. V.-P. 1875-6.)

1879 Leech, Daniel John, M.D., 96, Mosley-street, Manchester.

1877 Lees, David B., M.D., Physician to St. Mary's Hospital, and Assistant Physician to the Hospital for Sick Children; 22, Weymouth-street, Portland-place, W.

1867 Lees, Joseph, M.D., 21, Brixton-road, S.W.

1877 Leeson, John Rudd, M.D., C.M., 6, Clifden-road, Twickenham.

1868 Legg, John Wickham, M.D., Hotel Bourséjour, Cannes. (C. 1874-5.)

1884 Leonard, Henry James, M.B., 279, Camden-road, N.

Elected

1861 LICHTENBERG, GEORGE, M.D., 47, Finsbury-square, E.C.

1875 LINGARD, ALFRED, 49, Palace-road, Albert Embankment, S.E.

1877 LISTER, Sir JOSEPH, Bart., D.C.L., LLD., F.R.S. (V.-P.), Professor of Clinical Surgery at King's College, and Surgeon to King's College Hospital; 12, Park-crescent, Regent's-park, W. (C. 1880-2. V.-P. 1887.)

1878 LITTLEJOHN, SALTER G., M.B., C.M., Central London District Schools, Hanwell.

†1862 LITTLE, LOUIS S., China. [18, Park-street.]

1874 LIVEING, EDWARD, M.D., 52, Queen Anne-street, Cavendish-square, W.

1863 LIVEING, ROBERT, M.D., Physician to the Skin Department and Lecturer on Dermatology at the Middlesex Hospital; 11, Manchester-square, W. (C. 1876.)

1882 LOCKWOOD, C. B., Demonstrator of Anatomy at St. Bartholomew's Hospital; 19, Upper Berkeley-street, W.

1876 LONGHURST, ARTHUR EDWIN TEMPLE, M.D. (C.), 22, Wilton-street, Grosvenor-place, S.W. (C. 1885-7.)

1881 LUBBOCK, MONTAGU, M.D., Assistant Physician to Charing Cross Hospital, and to the Hospital for Sick Children, Great Ormond-street; 19, Grosvenor-street, W.

1873 LUCAS R. CLEMENT, M.B., M.S., Senior Assistant Surgeon to Guy's Hospital, and Surgeon to the Evelina Hospital for Sick Children; 18, Finsbury-square, E.C. (C. 1883-5.)

1880 LUND, EDWARD, Consulting Surgeon to the Royal Infirmary; 22, St. John-street, Manchester.

1879 LUNN, JOHN REUBEN, Resident Medical Officer, New Marylebone Infirmary; Rackham-street, Ladbroke-grove-road, Notting-hill, W.

1887 LYON, THOMAS GLOVER, M.D., 77, Lambeth Palace-road, S.E.

1871 MCCARTHY, JEREMIAH, M.A., Surgeon to the London Hospital,; 15, Finsbury-square, E.C. (C. 1878-80.)

1873 MCCONNELL, J. F., Professor of Pathology, Medical College, Calcutta. [Per Grindlay & Co., Parliament-street.] 14, St. Sames's-square, S.W.

1871 MAC CORMAC, Sir WILLIAM, Surgeon to St. Thomas's Hospital; 13, Harley-street, W. (C. 1878-80.)

1873 MACKELLAR, PETER H., M.B., Medical Officer, Fever Hospital, Landor-road, Stockwell, S.W.

1882 MACKENZIE, FREDERIC MORELL, 29, Hans-place, S.W.

1870 MACKENZIE, GEORGE WELLAND, 13, William-street, Lowndes-square, S.W.

1885 MACKENZIE, HECTOR GAVIN, St. Thomas's Hospital, S.E.

1870 MACKENZIE, JOHN T., Bombay, India. [East India United Service Club, 14, St. James's-square.]

1864 MACKENZIE, Sir MORELL, M.D., Physician to the Hospital for Diseases of the Throat, and Lecturer on Diseases of the Throat at the London Hospital; 19, Harley-street, Cavendish-square, W.

Elected

1878 MACKENZIE, STEPHEN, M.D., Physician to, and Lecturer on Medicine at, the London Hospital; 26, Finsbury-square, E.C.

1879 MACLAGAN, THOMAS JOHN, M.D., 9, Cadogan-place, Belgrave-square, S.W.

1865 MACLAURIN, HENRY NORMAND, M.D., 187, Macquarie-street, Sydney, New South Wales.

1879 MACMAHON, JAMES THOMAS, 25, West-hill, Dartford, Kent.

1876 MACNAMARA, CHARLES, Surgeon to the Westminster Hospital, and to the Royal Westminster Ophthalmic Hospital; 13, Grosvenor-street, W.

1879 MACREADY, JONATHAN FORSTER, 51, Queen Anne-street.

1885 MAGUIRE, ROBERT, M.D., 4, Seymour-street, Portman-square, W.

1877 MAKINS, GEORGE HENRY, Assistant Surgeon to the Evelina Hospital for Children; 2, Queen-street, May Fair, W.

1887 MALCOLM, JOHN DAVID, M.B., C.M., Surgeon in charge of out-patients, Samaritan Free Hospital; 24, Bryanston-street, Portman-square, W.

1876 MALLAM, BENJAMIN, Rose Bank, Blackall-road, Exeter.

1876 MAPLES, REGINALD, Kingsclere, near Newbury.

1857 MARCET, WILLIAM, M.D., F.R.S., Flowermead, Wimbledon-park, S.W. (C. 1869-71.)

1868 MARSH, F. HOWARD, Assistant Surgeon to St. Bartholomew's Hospital, Surgeon to the Hospital for Sick Children; 36, Bruton-street, Berkeley-square, W. (C. 1876-7.)

1846 MARSHALL, JOHN, F.R.S., Consulting Surgeon to University College Hospital, 10, Savile-row, W. (C. 1861.)

1856 MARTIN, ROBERT, M.D., Consulting Physician to St. Bartholomew's Hospital; 51, Queen Anne-street, Cavendish-square, W. (C. 1871-2.)

1867 MASON, PHILIP BROOKES, Burton-on-Trent.

1884 MAUDSLEY, HENRY CARE, M.D., Sydney, New South Wales.

†1852 MAY, GEORGE, Jun., M.B., Surgeon, Royal Berkshire Hospital, Reading.

1881 MAYLARD, ALFRED ERNEST, M.B., Lecturer on Anatomy, Western Medical School, Glasgow; 4, Berkeley-terrace, Glasgow.

1874 MEREDITH, WILLIAM APPLETON, M.B., Surgeon to the Samaritan Hospital; 6, Queen Anne-street, Cavendish-square, W.

1859 MESSER, JOHN COCKBURN, M.D., Assistant Surgeon R.N.

1866 MICKLEY, GEORGE, M.A., M.B., St. Luke's Hospital, Old-street, E.C.

1877 MILNER, EDWARD, Surgeon to the Lock Hospital; 32, New Cavendish-street, Portland-place, W.

1882 MONEY, ANGEL, M.D., Assistant Physician to University College Hospital, and to the City of London Hospital for Disease of the Chest, Victoria-park; 24, Harley-street, Cavendish-square, W.

1879 MOORE, NORMAN, M.D. (C.), Assistant Physician to St. Bartholomew's Hospital, and Demonstrator of Morbid Anatomy and Warden of the College; The College, St. Bartholomew's Hospital. (C. 1885-7.)

1881 MOORE, THOMAS, 6, Lee-terrace, Blackheath, S.E.

Elected

1847 MORGAN, JOHN, 3, Sussex-place, Hyde-park-gardens, W. (C. 1856-8.)

1875 MORGAN, JOHN H. (C.), Assistant Surgeon to the Charing Cross Hospital, and to the Hospital for Sick Children, Great Ormond-street; 68, Grosvenor-street, W. (C. 1886-7.)

1874 MORISON, ALEXANDER, M.D., C.M., Dunnottar, 115, Green-lanes, Highbury, N.

1880 MORISON, BASIL GORDON, M.B., C.M., 70, Marquess-road, Canonbury, N.

1869 MORRIS, HENRY, M.A., M.B., Surgeon to, and Lecturer on Surgery at, the Middlesex Hospital; 2, Mansfield-street, Portland-place, W. (C. 1877-9, 1884-6. S. 1881-3.)

1879 MORRIS, MALCOLM ALEXANDER, Surgeon to the Skin Department at St. Mary's Hospital; 8, Harley-street, Cavendish-square, W.

1875 MORTON, JOHN, M.B., Guildford.

1884 MOTT, FREDERICK WALKER, M.D., Lecturer on Physiology, Charing Cross Hospital; Meadowlead, Gayton-road, Harrow.

1879 MOULLIN, CHARLES W. MANSELL, M.D., Assistant Surgeon to the London Hospital; 69, Wimpole-street, Cavendish-square, W.

1878 MUMFORD, WILLIAM LUGAR, M.D., 1, Bartlett's-passage, Holborn-circus, E.C.

1876 MUNRO, WILLIAM, M.D., C.M., 102, Carl-street, Lower Broughton-road, Manchester.

1885 MURRAY, HUBERT MONTAGUE, M.D., Assistant Physician to Charing Cross Hospital, 27, Savile-row, W.

1864 MYERS, ARTHUR B. R., Surgeon to 1st Battalion Coldstream Guards; 3, Park-terrace, Windsor. (C. 1872-3.)

1882 MYERS, A. T., M.D., Medical Registrar, St. George's Hospital; 9, Lower Berkeley-street, Portman-square, W.

1887 MYERS, W. H., Fort Wayne, Indiana, U.S.A.

1874 NANKIVELL, ARTHUR WOLCOT, St. Bartholomew's Hospital, Chatham.

1873 NETTLESHIP, EDWARD, Ophthalmic Surgeon to St. Thomas's Hospital, and Assistant Surgeon to the Royal London Ophthalmic Hospital; 5, Wimpole-street, Cavendish-square, W. (C. 1882-4.)

1875 NEWBY, CHARLES HENRY.

1865 NEWMAN, WILLIAM, M.D., Stamford, Lincolnshire.

1868 NICHOLLS, JAMES, M.D., Chelmsford, Essex.

1876 NICHOLSON, JOHN FRANCIS, M.D., Physician to the Hull General Infirmary; 29, Albion-street, Hull.

1878 NOOTT, W. M., 8, Kensington-park-road, W.

1864 NORTON, ARTHUR T., Surgeon to St. Mary's Hospital; 101, Harley-street, Cavendish-square, W. (C. 1877-9.)

1883 NORVILL, FREDERIC HARVEY, M.B., Summerland, Yeovil, Somersetshire.

1856 NUNN, THOMAS WILLIAM, Consulting Surgeon to the Middlesex Hospital; 8, Stratford-place, Oxford-street, W. (C. 1864-6. V.-P. 1878-80.)

1871 NUNNELEY, Rev. FREDERICK BARHAM, M.D.

Elected

1880 O'Connor, Bernard, M.D., Physician to the North London Consumption Hospital, and Physician to the Westminster General Dispensary; 17, St. James's-place, S.W.

1873 O'Farrell, George Plunkett, M.B., Montenotte House, Cork, Ireland.

1880 Ogilvie, George, M.B., Lecturer on Experimental Physics at the Westminster Hospital; 13, Welbeck-street, Cavendish-square, W.

1880 Ogilvie, Leslie, M.B., Lecturer on Comparative Anatomy at the Westminster Hospital, 46, Welbeck-street, Cavendish-square, W.

1850 Ogle, John W., M.D., Consulting Physician to St. George's Hospital; 30, Cavendish-sq., W. (C. 1855-6. S. 1857-60. C. 1861-3. V.-P. 1865-8.)

1876 Oliver, John Ferens, M.D., 12, Old Elvet, Durham.

1860 Orange, William, M.D., Broadmoor, Wokingham, Berkshire.

1875 Ord, William Miller, M.D., Physician to, and Lecturer on Medicine at, St. Thomas's Hospital; 37, Upper Brook-street, Grosvenor-square W. (C. 1880-2.)

1879 Ormerod, J. A., M.D. (C.), Assistant Physician to the National Hospital for the Paralysed and Epileptic, Queen-square, and to the City of London Hospital for Diseases of the Chest, Victoria-park; 25, Upper Wimpole-street, W. (C. 1887.)

1881 Owen, Isambard, M.D., Assistant Physician to St. George's Hospital; 5, Hertford-street, Mayfair, W.

1865 Owles, James Allden, M.D., 106, Philbeach-gardens, South Kensington.

1883 Paddison, Edmund Howard, M.B., Assistant Medical Officer, London Asylum, Stone, Dartford.

1875 Page, Herbert William, M.A., M.C. Cantab., Surgeon to, and Joint Lecturer on Surgery at, St. Mary's Hospital; 146, Harley-street; Cavendish-square, W.

1870 Paget, Sir James, Bart., D.C.L., F.R.S. (President), Consulting Surgeon to St. Bartholomew's Hospital; 1, Harewood-place, Hanover-square, W. (P. 1887.)

1884 Paget, Stephen, 57, Wimpole-street, Cavendish-square, W.

1872 Parker, Robert William, Surgeon to the East London Children's Hospital; 8, Old Cavendish-street, W. (C. 1881-3.)

1874 Parker, Rushton, M.B., B.S., Professor of Surgery in University College, Liverpool, and Assistant Surgeon to the Royal Infirmary; 59, Rodney-street, Liverpool.

1853 Parkinson, George, 50, Brook-street, Grosvenor-square, W.

1882 Pasteur, William, MD., Medical Registrar to the Middlesex Hospital; 19, Queen-street, Mayfair, W.

1885 Paul, Frank Thomas, 44, Rodney-street, Liverpool.

1865 Pavy, Frederick William, M.D., F.R.S., Senior Physician to Guy's Hospital; 35, Grosvenor-street, W. (C. 1872-4.)

1868 Payne, Joseph Frank, M.D., Physician to, and Lecturer on Pathological Anatomy at, St. Thomas's Hospital; 78, Wimpole-street, Cavendish-square, W. (C. 1873-5, 1883-5. S. 1880-2.)

Elected

1872 PEARCE, JOSEPH CHANING, M.D., C.M., Montague House, St. Lawrence-on-Sea, Kent.

1878 PEARSE, THOMAS FREDERICK, M.D., 10, Montague-street, Russell-square, W.C.

1863 PEARSON, DAVID R., M.D., 23, Upper Phillimore-place, Kensington, W.

1884 PEDLEY, F. NEWLAND, 49, Finsbury-square, E.C.

1879 PEEL, ROBERT, 130, Collins-street East, Melbourne, Victoria.

1887 PENROSE, FRANCIS GEORGE, M.D., 50, Torrington-square, W.

1884 PEPPER, AUGUSTUS JOSEPH, M.B., C.M., Surgeon to St. Mary's Hospital; 122, Gower-street, W.

1878 PHILIPPS, SUTHERLAND REES, M.D., St. Ann's-heath, Virginia-water, Chertsey.

1871 PHILLIPS, CHARLES DOUGLAS F., M.D., 10, Henrietta-street, Cavendish-square, W.

1878 PHILLIPS, JOHN WALTER, Physician to the Benevolent Asylum of Melbourne; 30, Stanley-street, West Melbourne, Victoria.

1875 PHILPOT, HARVEY JOHN, 14, Finsbury-circus, E.C., and 74, Sutherland-avenue, Maida-vale, W.

1863 PICK, THOMAS PICKERING (V.-P.), Surgeon to, and Lecturer on Anatomy at, St. George's Hospital; 18, Portman-street, Portman-square, W. (C. 1870-1. V.-P. 1885-7.)

1867 PITT, EDWARD G., M.D.

1884 PITT, GEORGE NEWTON, M.D., Assistant Physician and Pathologist at Guy's Hospital; 9, St. Thomas's-street, Southwark, S.E.

1876 PITTS, BERNARD, M.A., M.B., Assistant Surgeon to St. Thomas's Hospital; 31, Harley-street, Cavendish-square, W.

1886 POCOCK, WALTER, 374, Brixton-road.

1883 POLAND, JOHN, Demonstrator of Anatomy at Guy's Hospital; 16, St. Thomas's-street, Southwark, S.E.

1882 POLLARD, BILTON, Assistant Surgeon and Surgical Registrar, University College Hospital; 24, Harley-street, Cavendish-square, W.

1846 POLLOCK, GEORGE D. (TRUSTEE), Consulting Surgeon to St. George's Hospital; 36, Grosvenor-street, W. (S. 1850-3. C. 1854-6. V.-P. 1863-5. P. 1875-6.)

1850 POLLOCK, JAMES EDWARD, M.D., Physician to the Hospital for Consumption and Diseases of the Chest, Brompton; 52, Upper Brook-street, W. (C. 1862-4. V.-P. 1879-81.)

1870 POORE, GEORGE VIVIAN, M.D., Physician to University College Hospital; 30, Wimpole-street, W. (C. 1883-5.)

1876 PORT, HEINRICH, M.D., 48, Finsbury-square, E.C.

1879 POTTER, HENRY PERCY, St. Mary Abbotts' Infirmary, Marloes-road, Kensington, W.

1881 POWELL, HENRY ALBERT, M.A., Elm Cottage, Beckenham.

Electea

1866 POWELL, RICHARD DOUGLAS, M.D. (V.-P.), Physician to, and Lecturer on Practical Medicine at, the Middlesex Hospital, Physician to the Hospital for Consumption and Diseases of the Chest, Brompton; 62, Wimpole-street, Cavendish-square, W. (C. 1873-5, 1881-3. S. 1877-9. V.-P. 1887.)

1865 POWER, HENRY, Ophthalmic Surgeon to St. Bartholomew's Hospital; 37A, Great Cumberland-place, Hyde-park, W. (C. 1876-7.)

1884 POWER, D'ARCY, M.B., Curator of St. Bartholomew's Hospital; 26, Bloomsbury-square, W.C.

1884 PRICE, J. A. P., M.D., 41, Castle-street, Reading.

1856 PRIESTLEY, WILLIAM OVEREND, M.D., Consulting Physician-Accoucheur to King's College Hospital, and to the St. Marylebone Infirmary; 17, Hertford-street, Mayfair, W.

1882 PRINGLE, J. J., M.B., Assistant Physician to the Middlesex Hospital and Physician to the Royal Hospital for Diseases of the Chest; 35, Bruton-street, Mayfair, W.

†1848 PURNELL, JOHN JAMES, Surgeon to the Royal General Dispensary; Woodlands, Streatham-hill, S.W. (C. 1858-61.)

1865 PYE-SMITH, PHILIP HENRY, M.D., F.R.S., Physician to, and Lecturer on Medicine at, Guy's Hospital; 54, Harley-street, Cavendish-square. W. (C. 1874-7.)

O.M. QUAIN, RICHARD, M.D., F.R.S. (TRUSTEE), Consulting Physician to the Hospital for Consumption and Diseases of the Chest, Brompton; 67, Harley-street, Cavendish-square, W. (C. 1846-51. S. 1852-6. T. 1857-68. *Pres.* 1869-70. V.-P. 1871-3.)

1859 RADCLIFFE, CHARLES BLAND, M.D., Consulting Physician to the Westminster Hospital; 25, Cavendish-square, W.

1884 RAKE, BEAVEN NEAVE, M.D., Government Medical Officer, and Medical Superintendent of the Leper Asylum, Trinidad.

1872 RALFE, CHARLES HENRY, M.D., M.A., Assistant Physician to the London Hospital; 26, Queen Anne-street, W. (C. 1877-9.)

1857 RAMSKILL, J. SPENCE, M.D., Consulting Physician to the London Hospital, Physician to the National Hospital for the Paralysed and Epileptic; 5, St. Helen's-place, Bishopsgate-street, E.C.

1848 RANDALL, JOHN, M.D., Medical Officer, St. Marylebone Infirmary; 204, Adelaide-road, N.W. (C. 1864-6.)

1857 RANKE, HENRY, M.D., Munich.

1865 RASCH, ADOLPHUS A., M.D., Physician for Diseases of Women to the German Hospital; 7, South-street, Finsbury-square, E.C.

1870 RAY, EDWARD REYNOLDS, Dulwich, S.E.

1871 RAYNER, HENRY, M.D., Lecturer on Mental Diseases at St. Thomas' Hospital, Medical Superintendent, Middlesex County Lunatic Asylum, Hanwell, W.

1858 REED, FREDERICK GEORGE, M.D., 46, Hertford-street, Mayfair, W.

Elected

1866 Reeves, Henry Albert, Assistant Surgeon to the London Hospital; 78, Grosvenor-street, W.

1875 Reid, Robert William, M.D., C.M., Lecturer on Anatomy at St. Thomas's Hospital; 75, Lambeth Palace-road, S.E.

1881 Renner, William, M.R.C.S., Wilberforce-street, Free Town, Sierra Leone.

1854 Reynolds, J. Russell, M.D., F.R.S., Consulting Physician to University College Hospital; 38, Grosvenor-street, W. (C. 1868-9.

1871 Richards, J. Peeke, Medical Superintendent, Middlesex County Lunatic Asylum, Hanwell, W.

1866 Rivington, Walter, M.S. Lond., Surgeon to the London Hospital; 22, Finsbury-square, E.C.

‡1865 Roberts, David Lloyd, M.D., Physician to St. Mary's Hospital, Manchester; 11, St. John's-street, Manchester.

1871 Roberts, Frederick Thomas, M.D., Professor of Materia Medica at University College, and Physician to University College Hospital and to the Hospital for Consumption, &c., Brompton; 102, Harley-street, Cavendish-square, W. (C. 1883-5.)

1878 Roberts, William Howland, M.D., Surgeon, Madras Army, Madras [East India United Service Club, St. James's Square].

1835 Robinson, Arthur Henry, M.D., Mile End Infirmary, Bancroft-road, E.

1887 Robinson, Henry Betham, M.B., 7, York-crescent, Lower Norwood, S.E.

1882 Robinson, Tom, M.D., 9, Princes-street, Cavendish-Square, W.

1882 Roeckel, Waldemar Joseph, 12, Upper Berkeley-street, Portman-square, W.

1858 Rose, Henry Cooper, M.D., Surgeon to the Hampstead Dispensary, Penrose House, Hampstead, N.W. (C. 1873-4.)

1876 Rose, William, M.B., B.S., Surgeon to King's College; 50, Harley-street, Cavendish-square, W.

1879 Ross, James, M.D., C.M., 335, Oxford-street, Manchester.

1875 Rossiter, George Frederick, Cairo Lodge, Weston-super-Mare.

1877 Roth, Bernard, 48, Wimpole Street, Cavendish-square, W., and Rossmore, Preston-road, Brighton.

1858 Rouse, James, Surgeon to St. George's Hospital; 2, Wilton-street, Grosvenor-place, S.W.

1881 Routh, Amand Jules McConnel, M.D., B.S., Assistant Physician Accoucheur to the Charing Cross Hospital, and Physician to the Samaritan Free Hospital; 6, Upper Montagu-street, W.

1869 Rutherford, William, M.D., F.R.S., Professor of Physiology in the University of Edinburgh; 14, Douglas-crescent, Edinburgh.

1882 Sainsbury, Harrington, M.D., Assistant Physician and Pathologist to the Royal Free Hospital, 63, Welbeck-street, W.

1853 Salter, S. James A., M.B., F.R.S. Late Dental Surgeon to Guy's Hospital; Basingfield, near Basingstoke, Hants. (C. 1861-3. V.-P. 1880-2.)

1852 Sanderson, Hugh James, M.D., 26, Upper Berkeley-street, Portman-square, W.

Elected

1854 SANDERSON, JOHN BURDON, M.D., F.R.S., Waynflete Professor of Physiology at the University of Oxford; 50, Banbury-road, Oxford. (C. 1864-7. V.-P. 1873-4.)

1875 SANGSTER, CHARLES, 148, Lambeth-road, S.E.

1877 SANKEY, H. R. O., County Asylum, Prestwich, Manchester.

‡1847 SANKEY, W. H. OCTAVIUS, M.D., Boreatton-park, Shrewsbury. (C. 1855.)

1886 SAUNDBY, ROBERT, M.D., Physician to the General Hospital, and Consulting Physician to the Hospital for Women, and to the Eye Hospital, Birmingham; 83A, Edmund-street, Birmingham.

1871 SAUNDERS, CHARLES EDWARD, M.D., 21, Lower Seymour-street, Portman-square, W.

1873 SAVAGE, GEORGE HENRY, M.D., Bethlem Royal Hospital, St. George's-road, S.E. (C. 1881-3.)

1882 SAVILL, THOMAS DIXON, M.D., Paddington Infirmary, Harrow-road, W.

1877 SEMON, FELIX, M.D. (C.), Assistant Physician for Diseases of the Throat to St. Thomas's Hospital; 39, Wimpole-street, Cavendish-square, W. (C. 1885-7.)

1852 SEMPLE, ROBERT HUNTER, M.D., Physician to the Bloomsbury Dispensary; 8, Torrington-square, W.C. (C. 1859-61.)

1872 SERGEANT, EDWARD, Medical Officer of Health, Town Hall, Bolton, Lancashire.

1876 SHARKEY, SEYMOUR J., M.B., Assistant Physician and Demonstrator of Morbid Anatomy to St. Thomas's Hospital; 2, Portland-place, W. (C. 1884-6.)

1880 SHATTOCK, S. G. (C.), Demonstrator of Surgical Pathology, and Curator of Museum, St. Thomas's Hospital; 92, Leathwaite-road, Clapham-common, S.W. (C. 1885-7.)

1885 SHAW LAURISTON ELGIE, M.D., Medical Registrar and Demonstrator of Practical Medicine, Guy's Hospital; Assistant Physician to the City of London Hospital for Diseases of the Chest, Victoria-park; 15, St. Thomas's-street, Southwark, S.E.

1884 SHEILD, ARTHUR MARMADUKE, M.B., B.S, Assistant Surgeon to the Charing Cross Hospital; 20, Stratford-place, Oxford-street, W.

1886 SHERRINGTON, C. S., M.B., Gonville and Caius College, Cambridge.

1856 SHILLITOE, BUXTON, Surgeon to the Great Northern Hospital, and to the Lock Hospital; 2, Frederick's-place, Old Jewry, E.C.

1855 SIBLEY, SEPTIMUS W., 7, Harley-street, Cavendish-square, W. (C. 1863-5. V.-P. 1879-81.)

1887 SIBLEY, WALTER KNOWSLEY, 7, Harley-street, Cavendish-square, W.

1875 SIDDALL, JOSEPH BOWER, M.D., C.M. [care of G. Siddall, Esq., Matlock, Derbyshire].

1880 SILCOCK, A. QUARRY, M.D., B.S., Surgeon in charge of Out-patients, St. Mary's Hospital, and Assistant Surgeon, Royal London Ophthalmic Hospital, Moorfields; 101, Harley-street, Cavendish-square, W.

O.M. SIMON, Sir JOHN, K.C.B., D.C.L., F.R.S., Consulting Surgeon to St. Thomas's Hospital; 40, Kensington-square, W. (C. 1846-8. V.-P. 1855-9. *Pres.* 1867-8. V.-P. 1869-71.)

Elected

1866 SIMS, FRANCIS MANLEY BOLDERO, 12, Hertford-street, Mayfair, W.

1877 SKINNER, WILLIAM A., 45, Upper Belgrave-street, S.W.

1887 SMALLPEICE, WILLIAM DONALD, 42, Queen Anne's-gate, S.W.

1875 SMEE, ALFRED HUTCHINSON, The Grange, Hackbridge, Carshalton, Surrey.

1879 SMITH, E. NOBLE, Senior Surgeon, and Surgeon to the Orthopædic Department of the Farringdon Dispensary, and Orthopœdic Surgeon to the British Home for Incurables; 24, Queen Anne-street, Cavendish-square.

1887 SMITH, FREDERICK JOHN, M.B., 7, West-street, Finsbury-circus, E.C.

1875 SMITH, GEORGE JOHN MALCOLM, M.B., Hurstpierpoint, Sussex.

1872 SMITH, GILBART, M.D., Assistant Physician to the London Hospital, Physician to the Royal Hospital for Diseases of the Chest, City-road, Visiting Physician to the Margaret-street Infirmary for Consumption; 68, Harley-street, Cavendish-square, W.

1863 SMITH, HENRY, Surgeon to, and Professor of Surgery at, King's College Hospital; 82, Wimpole-street, Cavendish-square, W. (C. 1873-4.)

1878 SMITH, HERBERT URMSON, M.B., Cape Colony.

1866 SMITH, HEYWOOD, M.D., 18, Harley-street, Cavendish-square, W.

1846 SMITH, PROTHEROE, M.D., Physician to the Hospital for Women; 42, Park-street, Grosvenor-square, W.

1873 SMITH, RICHARD T., M.D., Physician to the St. Pancras Dispensary; 53, Haverstock-hill, N.W.

1883 SMITH, ROBERT PERCY, M.D., Bethlem Royal Hospital, St. George's Road, S.E.

1869 SMITH, ROBERT SHINGLETON, M.D., Lecturer on Physiology, Bristol Medical School; 9, Richmond-hill, Clifton, Bristol.

1856 SMITH, THOMAS, Surgeon to St. Bartholomew's Hospital; 5, Stratford-place, Oxford-street, W. (C. 1867-9. V.-P. 1877-8.)

1866 SMITH, WILLIAM, Melbourne, Australia.

1870 SMITH, WILLIAM JOHNSON, Surgeon, Seamen's Hospital, Greenwich, S.E. (C. 1879-81.)

1869 SMITH, WILLIAM WILBERFORCE, M.D., 14, Stratford-place, W.

1870 SNOW, WILLIAM VICARY, M.D., Richmond Gardens, Bournemouth.

1868 SOUTHEY, REGINALD, M.D., Commissioner in Lunacy; 32, Grosvenor-road, Pimlico. (C. 1882-4.)

1887 SPENCER, WALTER GEORGE, M.B., Assistant Surgeon to Westminster Hospital; 94, Wimpole-street, Cavendish-square, W.

1868 SPRY, G. FREDERICK HUME, M.D., Surgeon-Major 2nd Life Guards, Regent's-park Barracks, N.W.

1861 SQUIRE, ALEXANDER BALMANNO, M.B., 24, Weymouth-street, Portland-place, W.

1885 SQUIRE, JOHN EDWARD, M.D., 23, Seymour-street, Portman-square, W.

1854 STEWART, WILLIAM EDWARD, 16, Harley-street, Cavendish-square, W.

1879 STIRLING, EDWARD CHARLES, Adelaide, South Australia [care of T. Gemmell, Esq., 11, Essex-street, Strand, W.C.].

Elected

1883 STOKES, GEORGE, Surgeon for Out-patients, Hospital for Diseases of the Throat and Chest, Golden-square; 25, Old Burlington-street.

1881 STOKES, HENRY FRASER, 2, Highbury-crescent, N.

1884 STONHAM, CHARLES, Curator of the Anatomical Museum, University College, London, and Assistant Surgeon to the Westminster Hospital; 62, Welbeck-street, Cavendish-square, W.

1875 STURGE, W. A., M.D., Maison Malausséna, 27, Boulevard Dubouchage, Nice.

†1871 SUTHERLAND, HENRY, M.D., 6, Richmond-terrace, Whitehall, S.W.

1864 SUTTON, HENRY G., M.B., Physician to, and Lecturer on Pathology at, the London Hospital; 9, Finsbury-square, E.C. (C. 1875-6.)

1882 SUTTON, JOHN BLAND (C.), Assistant Surgeon to, and Lecturer on Comparative Anatomy at, the Middlesex Hospital; 22, Gordon-street, Gordon-square, W.C. (C. 1887.)

‡1867 SWAIN, WILLIAM PAUL, 20, Ker-street, Devonport.

1881 SYMONDS, CHARTERS JAMES, M.S. (C.), Assistant Surgeon to Guy's Hospital, and to the Evelina Hospital for Sick Children; 26, Weymouth-street, Portland-place, W. (C. 1886-7.)

1870 TAIT, ROBERT LAWSON, Surgeon to the Birmingham and Midland Hospital for Women; 7, The Crescent, Birmingham.

1886 TARGETT, JAMES HENRY, M.B., 28, Trinity-square, S.E.

1864 TATHAM, JOHN, M.D., Physician to the Hospital for Consumption and Diseases of the Chest, Brompton; 12, George-street, Hanover-square, W.

1870 TAY, WARREN (C.), Surgeon to, and Demonstrator of Practical Anatomy at, the London Hospital; 4, Finsbury-square, E.C. (C. 1881-2.)

1885 TAYLOR, HENRY H., Hospital for Consumption, Brompton, S.W.

1871 TAYLOR, FREDERICK, M.D., Physician to, and Lecturer on Medicine at, Guy's Hospital, and Physician to the Evelina Hospital for Sick Children; 11, St. Thomas's-street, S.E. (C. 1879-81.)

1880 TAYLOR, SEYMOUR, M.D., M.C., Physician to the North London Hospital for Consumption; 16, Seymour-street, Portman-square, W.

1879 THIN, GEORGE, M.D., 22, Queen Anne-street, Cavendish-square, W.

1870 THOMAS, JOHN DAVIES, M.B., Adelaide, South Australia [care of Mr. H. K. Lewis, Gower-street].

1852 THOMPSON, Sir HENRY, Knt., Emeritus Professor of Clinical Surgery in University College; 35, Wimpole-street, Cavendish-square, W. (S. 1859-63. C. 1865-67. V.-P. 1868-70.)

1884 THOMSON, JOHN, M.B., C.M., 18, Walker-street, Edinburgh.

1874 THORNTON, JOHN KNOWSLEY, M.B., Surgeon to the Samaritan Free Hospital for Women and Children; 22, Portman-street, Portman-square, W.

1872 THORNTON, WILLIAM PUGIN, 35, St. George's-road, Canterbury.

1865 THOROWGOOD, J. C., M.D., Lecturer on Materia Medica at the Middlesex Hospital, Physician to the City of London Hospital for Diseases of the Chest; 61, Welbeck-street, W. (C. 1876-78.)

Elected

1880 TIRARD, NESTOR ISIDORE, M.D., Professor of Materia Medica at King's College, London; Assistant Physician, King's College Hospital, and to the Evelina Hospital for Sick Children; 28, Weymouth-street, Portland-place.

1884 TIVY, WILLIAM JAMES, 8, Lansdowne-place, Clifton, Bristol.

1856 TOMES, Sir JOHN, F.R.S., Consulting Dental Surgeon to the Middlesex Hospital; Upwood Gorse, Caterham, Surrey. (C. 1867-9.)

1864 TONGE, MORRIS, M.D., Harrow-on-the-hill, Middlesex.

1882 TOOTH, H. H., M.D., Assistant Demonstrator of Practical Physiology St. Bartholomew's Hospital; 34, Harley-street, Cavendish-square, W.

1886 TOTSUKA, KANKAI, 65, Lambeth Palace-road, S.E.

1872 TOWNSEND, THOMAS SUTTON, 68, Queen's Gate, South Kensington, S.W.

1881 TREVES, FREDERICK (C.), Surgeon to, and Lecturer on Anatomy at, the London Hospital; 6, Wimpole-street, Cavendish-square, W. (C. 1887.)

1851 TROTTER, JOHN W., Surgeon-Major, Coldstream Guards; Bossall Vicarage, York. (C. 1865-9.)

1859 TRUMAN, EDWIN THOMAS, Surgeon-Dentist in Ordinary to Her Majesty's Household; 23, Old Burlington-street, W.

1867 TUCKWELL, HENRY MATTHEWS, M.D., late Physician to the Radcliffe Infirmary; 64, High-street, Oxford.

1858 TUDOR, JOHN, Dorchester, Dorset.

1875 TURNER, FRANCIS CHARLEWOOD, M.D., Physician to the London Hospital; 15, Finsbury-square, E.C. (C. 1884-6.)

1882 TURNER, GEORGE ROBERTSON, Visiting Surgeon, Seamen's Hospital, Greenwich, and Joint Lecturer on Practical Surgery at St. George's Hospital; 49, Green-street, Park-lane.

1863 TURNER, JAMES SMITH, Consulting Dental Surgeon to the Middlesex Hospital; 12, George-street, Hanover-square, W.

1858 TURTLE, FREDERICK, Clifton Lodge, Woodford, Essex.

1878 TYRRELL, WALTER, 95, Cromwell-road, South Kensington, S.W.

1880 TYSON, WILLIAM JOSEPH, M.D., Medical Officer of the Folkestone Infirmary; 10, Langhorne-gardens, Folkestone.

1854 VASEY, CHARLES, 112, Cambridge-gardens, Notting-hill. W.

1867 VENNING, EDGCOMBE, 30, Cadogan-place, S.W.

†1867 WAGSTAFFE, WILLIAM WARWICK, B.A., Purleigh, St. John's-hill, Sevenoaks. (C. 1874, 1878-80. S. 1875-7.)

O.M. WAITE, CHARLES D., M.D., Senior Physician to the Westminster General Dispensary; 3, Old Burlington-street, W.

1885 WAKLEY, THOMAS, jun., 96, Redcliffe-gardens, S.W.

1881 WALLER, BRYAN CHARLES, M.D., Masongill House, Cowan-bridge, Kirkby-Lonsdale.

1873 WALSHAM, WILLIAM JOHNSON, M.B., C.M., Assistant Surgeon to, and Demonstrator of Practical and Orthopædic Surgery at, St. Bartholomew's Hospital, Surgeon to the Metropolitan Free Hospital; 27, Weymouth-street, Portland-place. (C. 1881-3.)

Elected.

1859 WALTERS, JOHN, M.B, Reigate, Surrey.

1877 WARNER, FRANCIS, M.D., Assistant Physician to, and Lecturer on Botany at, the London Hospital; 24, Harley-street, W.

1877 WATERHOUSE, CHARLES, M.B., M.C., Carl Ludwigstrasse, Währing, Vienna.

1879 WATERS, JOHN HENRY, M.D., 101, Jermyn-street, St. James's, S.W.

1880 DE WATTEVILLE, ARMAND, M.A., M.B., Physician in charge of the Electro-Therapeutical Department, St. Mary's Hospital; 30, Welbeck-street, Cavendish-square, W.

1860 WAY, JOHN, M.D., 4, Eaton-square, S.W. (C. 1873-4.)

†1858 WEBER, HERMANN, M.D., Physician to the German Hospital; 10, Grosvenor-street, Grosvenor-square, W. (C. 1867-70. V.-P. 1878-80.)

1876 WEIR, ARCHIBALD, M.D., St. Mungho's, Great Malvern.

1864 WELCH, THOMAS DAVIES, M.D.

1853 WELLS, Sir THOMAS SPENCER, Bart., Consulting Surgeon to the Samaritan Free Hospital for Women and Children; 3, Upper Grosvenor-street, W. (C. 1865-8. V.-P. 1876-7.)

†1851 WEST, CHARLES, M.D., 55, Harley-street, Cavendish-square, W. (C. 1856-7.)

1877 WEST, SAMUEL, M.D., Assistant Physician to St. Bartholomew's Hospital, Physician to the City of London Hospital for Diseases of the Chest, Victoria-park, and to the Royal Free Hospital; 15, Wimpole-street, Cavendish-square, W. (C. 1884-6.)

1867 WHIPHAM, THOMAS TILLYER, M.B., Physician to St. George's Hospital; 11, Grosvenor-street, Grosvenor-square, W. (C. 1880-2.)

1869 WHIPPLE, JOHN H. C., M.D., Army Medical Staff.

1877 WHITE, CHARLES HAYDON, 20, Shakespeare-street, Nottingham.

1881 WHITE, WILLIAM HALE, M.D., Senior Assistant Physician to, and Lecturer on Materia Medica at, Guy's Hospital; 65, Harley-street, Cavendish-square, W.

1886 WHITE, WILLIAM HENRY, M.D., Physician to the Royal Hospital for Diseases of the Chest, 43, Weymouth-street, W.

‡1868 WHITEHEAD, WALTER, 24, St. Ann's-square, Manchester.

1877 WHITMORE, WILLIAM TICKLE, 7, Arlington-street, S.W.

1870 WICKSTEED, FRANCIS WILLIAM, Chester House, Weston-super-Mare.

1879 WILCOX, HENRY, M.B., Dorchester House, Herbert-road, Woolwich.

1869 WILKIN, JOHN F., M.D., M.C., New Beckenham, Kent.

1871 WILKINSON, J. SEBASTIAN, Late Surgeon to the Central London Ophthalmic Hospital; New Zealand.

1855 WILKS, SAMUEL, M.D., F.R.S. (TRUSTEE), Member of the Senate of the University of London, Consulting Physician to Guy's Hospital; 72, Grosvenor-street, W. (C. 1857-60. V.-P. 1869-72, 1883-5. P. 1881-2.)

1879 WILLCOCKS, FREDERICK, M.D., Assistant Physician to Charing Cross Hospital, Physician for Out-patients to the Evelina Hospital for Sick Children; 14, Mandeville-place, Manchester-square, W.

Elected

1886 WILLETT, EDGAR WILLIAM, M.B., 60, Welbeck-street, Cavendish-square, W.

1869 WILLIAMS, ALBERT, M.D., 60, Kirkdale, Sydenham, S.E.

O.M. WILLIAMS, C. J. B., M.D., F.R.S., Consulting Physician to the Hospital for Consumption and Diseases of the Chest, Brompton [2, Upper Brook-street, Grosvenor-square, W.]. (*Pres.* 1846-7. V.-P. 1848-52. C. 1853-5. V.-P. 1858-61.)

‡1858 WILLIAMS, CHARLES, Surgeon to the Norfolk and Norwich Hospital; 9, Prince of Wales-road, Norwich.

1866 WILLIAMS, CHARLES THEODORE, M.D., Physician to the Hospital for Consumption and Diseases of the Chest, Brompton; 2, Upper Brook-street, Grosvenor-square, W. (C. 1875-8.)

1881 WILLIAMS, DAWSON, M.D., B.S., Elstree, Herts.

1872 WILLIAMS, JOHN, M.D., Obstetric Physician to University College Hospital; 11, Queen Anne-street, Cavendish-square, W. (C. 1878-80.)

1881 WILLIAMS, W. ROGER, Surgical Registrar to the Middlesex Hospital.

1864 WILLIAMS, W. RHYS, M.D., Commissioner in Lunacy; 13, Gloucester street, Warwick-square, S.W.

1876 WILLIAMSON, JAMES MANN, M.D., Ventnor, Isle of Wight.

1863 WILLIS, FRANCIS, M.D., The Spa, Braceborough, Stamford.

1859 WILSON, EDWARD THOMAS, M.B., Montpelier-terrace, Cheltenham.

1859 WILSON, ROBERT JAMES, 7, Warrior-square, St. Leonards-on-Sea.

‡1861 WINDSOR, THOMAS, Consulting Surgeon to the Salford Royal Hospital Woodcroft, Dudley-road, Manchester, S.W.

1874 WISEMAN, JOHN GREAVES, Dearden-street, Ossett, Yorkshire.

1865 WITHERBY, WILLIAM H., M.D., Pitt-place, Coombe, Croydon.

1850 WOOD, JOHN, F.R.S. (TREASURER), Surgeon to, and Professor of Clinical Surgery at, King's College Hospital; 61, Wimpole-street, W. (C. 1857-9. V.-P. 1872-4. T. 1884-7.)

1887 WOOD, T. OUTTERSON, M.D., 40, Margaret-street, Cavendish-square, W.

1854 WOOD, WILLIAM, M.D., Physician to St. Luke's Hospital; 99, Harley-street, W.

1876 WOOD, WILLIAM EDWARD RAMSDEN, M.A., M.D., Rockhampton, Queensland.

1883 WOODCOCK, JOHN ROSTRON, 263, Hagley-road, Birmingham.

1883 WOODHEAD, GERMAN SIMS, M.D., 6, Marchhall-crescent, Edinburgh.

1879 WOODWARD, G. P. M., M.D., Deputy Surgeon-General; Sydney, New South Wales.

1884 WORTS, EDWIN, 6, Trinity Street, Colchester.

1869 WYMAN, W. S., M.D., Westlands, 280, Upper Richmond-road, Putney, S.W.

1881 WYNTER, WALTER ESSEX, Templecombe, Twickenham.

1869 YEO, I. BURNEY, M.D., Physician to Kings College Hospital; 44, Hertford-street, Mayfair, W.

1872 YOUNG, HENRY, M.B., Monte Video, South America.

ANNUAL REPORT OF COUNCIL, 1886-87.

PRESENTED AT THE ANNUAL MEETING, JANUARY 4TH, 1887.

YOUR Council has once more the duty of reporting that the position of the Society is very satisfactory.

The total number of members is almost the same as last year. Eighteen new members have been elected. Ten members have resigned, and thirteen have died, so that the Society numbers 677 members.

Two resident members have become non-resident.

The death-list contains the following names:—A. G. Mickley, C. J. Workman, J. M. Burton, S. Sutro, J. Cooper Forster, J. F. Streatfeild, Francis Mason, H. Royes Bell, Walter Moxon, J. Samson Gamgee, C. Black, A. Wiltshire, and Henry Kingsley. Both Dr. Moxon and Mr. Cooper Forster had been *Vice-Presidents* of the Society, and in years past Dr. Moxon had contributed largely and with brilliant success to the meetings and 'Transactions.'

The exhibition of Intra-cranial Tumours, of which the announcement was made in the last Report, took place during February, and resulted in the bringing together of a large number of very valuable specimens. In order to use this material to better advantage, a Committee was appointed by your Council consisting of Drs. Beevor, Hadden, Ormerod, Mr. Shattock, and the Honorary Secretaries. The tables which they drew up, and the short report accompanying the tables, will be found in the 'Transactions.' It is hoped that they may prove useful to those pathologists and surgeons who are interested in the subject.

Dr. Goodhart and Mr. Butlin having resigned their seats on the Committee of Morbid Growths, after many years of work; Dr. Norman Moore and Mr. Clutton have been appointed to succeed them.

No change of importance has been made in the constitution or management of the Society during the past year, but a subject of grave importance will immediately occupy the attention of your new Council. For several years past the amount of material exhibited at the Society or proposed for exhibition has been too abundant to be exhibited in the course of the fifteen meetings, and the question has from time to time been raised whether any means should be taken to remedy this difficulty. Two or three propositions have been made and will be laid before the Council for their consideration at the next meeting.

The income of the Society during the past year was £583 14s. 1d. The expenditure was £594 14s. 0d., including the sum of £382 0s. 9d. for 750 copies of the 'Transactions.'

The balance at the bank is £154 1s. 5d. The sum invested is the same as last year.

THE PATHOLOGICAL SOCIETY OF LONDON,

Cr. *In Account with the Treasurer,* JOHN WOOD, F.R.S., *39th Session,* 1885–86. **Dr.**

	£	s.	d.	£	s.	d.
By *Balance* at Union Bank, Jan. 1st, 1886 ...				165	1	4
Subscriptions:						
414 Annual Subscriptions	434	14	0			
5 Ditto (in Advance)	5	5	0			
10 Ditto (Arrears)	10	10	0			
13 Admission Fees	13	13	0			
5 Ditto (Non-Resident)	10	10	0			
				474	12	0
Sale of Transactions:						
By the Society	19	11	6			
„ Messrs. Smith, Elder, & Co.	55	13	5			
				75	4	11
Dividends on Consols £1167 9*s.* 1*d.*—						
January	16	18	7			
July	16	18	7			
				33	17	2
				£748	15	5

	£	s.	d.	£	s.	d.
To *Meetings:*						
Payment to Royal Medical and Chirurgical Society for use of Rooms, Gas, &c.	78	15	0			
Refreshments, Waiters, Management, &c.	36	15	0			
Richard Coldrey (Meetings, &c.)	7	10	0			
Microscopes and Lamps	15	6	0			
				138	6	0
Transactions: Vol. XXXVII (750 copies):						
Printing, Binding, and Delivery (Adlard)	241	11	9			
Lithography and Woodcuts (Newman)	16	18	10			
Ditto (Huth)	13	10	0			
Ditto (Headington)	3	0	0			
Ditto (Typographic Elect. Co) ...	2	5	0			
Ditto (Mintern)	31	19	2			
Ditto (Danielsson)	43	3	6			
Ditto (Lapidge)	11	7	0			
Ditto (Burgess)	15	2	6			
Index (Bailey)	3	3	0			
				382	0	9
Secretariat and Treasury:						
Assistance to Hon. Secs.	28	7	0			
Posting Ledgers (McDermott)	2	2	0			
Commission on Collecting Subscriptions	17	18	6			
Petty Cash expended in Berners Street	7	17	2			
Ditto (Medical Secretary)	1	18	1			
Ditto (Surgical Secretary)	3	0	0			
				61	2	9
Stationery and Printing:						
Adlard	10	19	0			
Wodderspoon	2	5	6			
				13	4	6
Balance in hand				154	1	5
				£748	15	5

Audited, compared with the Vouchers, and found correct, ANGEL MONEY, M.D., FREDERICK TREVES, } *Auditors.*

December 31st, 1886.

LIST OF SPECIMENS AND REPORTS

BROUGHT BEFORE THE SOCIETY DURING THE SESSION 1886-87.

PAGE

ADDRESS by the PRESIDENT, Sir JAMES PAGET, Bart., F.R.C.S., D.C.L., LL.D., F.R.S. . . . 1

I. DISEASES, ETC., OF THE NERVOUS SYSTEM.

1. Meningeal hæmorrhage (Card specimen) By T. D. SAVILL, M.D. 8
2. Embolism of the basilar artery, with meningeal hæmorrhage from rupture of the posterior cerebral (Card specimen) By HENRY MAUDSLEY, M.D. 11
3. Hæmatoma of dura mater (Card specimen) By HARRINGTON SAINSBURY, M.D. 12
4. Subdural hæmatoma (Card specimen. Specimen furnished by Dr. McKinnon) By J. A. ORMEROD, M.D. 13
5. Old meningeal hæmorrhage, with cerebral softening and secondary descending degeneration By W. HALE WHITE, M.D. 13
6. Cerebro-spinal meningitis, causing an abscess in the œsophagus By W. HALE WHITE, M.D. 14
7. Recovery (?) from tubercular meningitis in chronic phthisis, with disease of knee-joints and spinal caries By R. E. CARRINGTON, M.D. 16
8. Endothelioma of the dura mater By E. HYLA GREVES, M.D. (Bournemouth) 20
9. Cholesteatoma at the base of the brain By JOHN A. P. PRICE, M.D. (Reading) 24
10. Two cases of diffuse sarcoma of the spinal pia mater [With Plates I and II] By SIDNEY COUPLAND, M.D., and WILLIAM PASTEUR, M.D. 26

PAGE

11. Fatal cerebral hæmorrhage in a boy, aged 5 years, following thrombosis of the venous sinuses of the dura mater By H. HANDFORD, M.D. 40
12. Tubercular tumour of brain By GILBERT BARLING, M.B. 42
13. Round-celled sarcoma of the spinal cord and brain (Card specimen) By W. P. HERRINGHAM, M.B., and D'ARCY POWER, M.B. 43
14. An adenoid sarcoma with cartilage originating in the pineal gland By JOSEPH COATS, M.D. (Glasgow) 44
15. Myxofibroma of the fifth dorsal nerve (left side) extending to the spinal canal, producing compression of the cord (Card specimen) By FREDERICK W. MOTT, M.D. 52
16. Case of infantile paralysis, the original attack occurring fifty-eight years before death [With Plate III] By SEYMOUR J. SHARKEY, M.B. 53
17. Fatal cases of alcoholic paralysis [With Plate IV, figs. 1 and 2] By W. B. HADDEN, M.D. 57
18. Peripheral neuritis in Raynaud's disease (symmetrical gangrene) [With Plate IV, figs. 3 and 4] By SIDNEY COUPLAND, M.D., for JOSEPH WIGLESWORTH, M.D. (Rainhill Asylum) 61
19. Peripheral neuritis (Card specimen) By W. HALE WHITE, M.D. 68
20. Multiple neuro-fibromata in connection with molluscum fibrosum [With Plates V and VI] By J. F. PAYNE, M.D. 69
21. On the falling out of the teeth in locomotor ataxy By W. HALE WHITE, M.D. 79
22. Case of hemiatrophia facialis (Case shown at meeting) By FREDERIC S. EVE 81

II. DISEASES, ETC., OF THE ORGANS OF RESPIRATION.

1. Hyperplastic syphilitic laryngitis By FELIX SEMON, M.D., for ERNEST JACOB, M.D. 83
2. Epithelioma of larynx By SAMUEL WEST, M.D. 85

PAGE

3. Tubercular ulceration of trachea (Card specimen) By W. B. HADDEN, M.D. 89
4. Ulceration of the trachea and rupture of aorta (Card specimen) By HENRY MAUDSLEY, M.D. 89
5. Localised bronchiectasis caused by the invasion into a bronchus of a caseating bronchial gland (Card specimen) By LAURISTON SHAW, M.D. 90
6. Rapidly fatal hæmoptysis from ulceration of a large branch of the pulmonary artery in a child (Card specimen) By W. PASTEUR, M.D. 91
7. Disseminated fibrosis of lungs By W. B. HADDEN, M.D. 92
8. Quiescent tubercle (disseminated fibrosis) of lung (Card specimen) By R. G. HEBB, M.D. 94
9. Lung from a case of chronic pleurisy (Card specimen) By W. PASTEUR, M.D. 94

III. DISEASES, ETC., OF THE ORGANS OF CIRCULATION.

1. Two cases of congenital malformation of heart. Perforation of septum ventriculorum; undefended space open (Card specimen) By FREDERICK WILLCOCKS, M.D. 96
2. Bullet wound of the left ventricle (Card specimen) By R. MAGUIRE, M.D. 97
3. Aneurysm of heart; cerebral tumour; idiocy By ANGEL MONEY, M.D. 97
4. Aneurysm of sinus of Valsalva By NORMAN MOORE, M.D. 100
5. Interstitial aneurysm of the interauricular septum By ROBERT MAGUIRE, M.D. 100
6. Ruptured aneurysm of the heart (syphilis) By J. F. GOODHART, M.D., for Mr. WITHERS GREEN 102
7. A case of diffuse syphiloma of the heart [With Plate VII] By W. PASTEUR, M.D. 103
8. Fatty tumour (lipoma) of the heart By H. HANDFORD, M.D. 108

PAGE

9. Right-sided malignant endocarditis (Card specimen) By W. Hale White, M.D. 114
10. Endocarditis with necrosis of the mitral valve (Card specimen) By F. Charlewood Turner, M.D. 115
11. Aneurysm of the mitral valve in a child By W. B. Hadden, M.D. 116
12. Stenosis of mouths of coronary arteries; anginal symptoms (Card specimen) By Harrington Sainsbury, M.D. 117
13. Aneurysm of aorta (transverse part of arch) rupturing into the œsophagus; no previous œsophageal symptoms (Card specimen) By H. Handford, M.D. 118
14. Aneurysm of arch of aorta rupturing into pericardial sac (Card specimen) By J. F. Goodhart, M.D., for A. Withers Green 119
15. Aneurysm of arch of aorta communicating with superior cava (Card specimen) By G. Gulliver, M.B. 120
16. Spontaneous cure of thoracic aneurysm in anæsthetic leprosy (Card specimen) By Beavan N. Rake, M.D. (Trinidad) 120
17. "Macro-angiosis" of left upper extremity By Richard Barwell, F.R.C.S. 121
18. A case of syphilitic arteritis (Card specimen) [With Plate VIII] By Seymour J. Sharkey, M.B. 124

IV. DISEASES, ETC., OF THE ORGANS OF DIGESTION.

1. Ulcerative stomatitis in a child; miliary tuberculosis By Jonathan Hutchinson, jun. 127
2. Stricture of œsophagus; secondary growths in lung (Card specimen) By H. Handford, M.D. 128
3. Broncho-œsophageal fistula consequent upon malignant growth (squamous epithelioma) of œsophagus; Meckel's diverticulum in the same subject (Card specimen) By H. Handford, M.D. 129
4. Retro-œsophageal abscess By H. H. Clutton 130

PAGE

5. A case of hour-glass constriction of the stomach
By LEOPOLD HUDSON 133
6. Fibrous contraction with hour-glass stricture of the stomach By F. CHARLEWOOD TURNER, M.D. 138
7. Stomach with numerous superficial erosions following after an extensive burn (Card specimen)
By G. N. PITT, M.D. 140
8. Ulcers of stomach in a child the subject of general tuberculosis By THOMAS BARLOW, M.D. 141
9. Colloid cancer of stomach (Card specimen)
By LEOPOLD HUDSON 143
10. Perforation of intestine four days after accident (Card specimen) By J. H. TARGETT 143
11. Chronic perforating ulcer of duodenum with erosion of pancreatic artery (Card specimen)
By W. H. ALLCHIN, M.B. 144
12. Congenital occlusion of the jejunum (Card specimen)
By F. CHARLEWOOD TURNER, M.D. 145
13. Perforation of large intestine in enteric fever (Card specimen) By W. B. HADDEN, M.D. 145
14. Cystic tumour of the cæcum
By HARRINGTON SAINSBURY, M.D. 146
15. Carcinoma of cæcum with extreme narrowing (Card specimen) By W. B. HADDEN, M.D. 148
16. Imperforate anus; (A) male, (B) female (Card specimen)
By D'ARCY POWER, M.B. 149
17. Malarial disease of liver and spleen with tuberculosis
By NORMAN MOORE, M.D. 149
18. Primary scirrhus of liver of tubular type with secondary growths in liver, lung, vertebra, Douglas's pouch, &c.; prostatic calculi [With Plate IX]
By G. N. PITT, M.D. 151
19. Two cases of gall-stone causing obstruction of the bowels
By P. H. PYE-SMITH, M.D. 160
20. Cirrhosis of pancreas in diabetes (Card specimen)
By W. B. HADDEN, M.D. 163

V. DISEASES, ETC., OF THE GENITO-URINARY ORGANS.

PAGE

1. Kidneys, with old ascending nephritis, which has produced numerous large cysts and extensive local destruction and shrinking (Card specimen) By G. N. Pitt, M.D. 164
2. Urinary tuberculosis with multiple renal calculi (Card specimen) By E. Hurry Fenwick 165
3. Encephaloid cancer of right kidney (Card specimen) By E. Hurry Fenwick 166
4. Great dilatation of one ureter and pelvis of kidney secondary to urethral stricture (Card specimen) By W. Hale White, M.D. 168
5. Slight unilateral hydronephrosis due to stricture of the ureter (Card specimen) By G. N. Pitt, M.D. 168
6. Atrophied kidney and dilated ureter from a female child aged 2 years (Card specimen) By W. R. Dakin, M.D., B.S. 169
7. Ectopia vesicæ By Samuel G. Shattock 170
8. Frozen section of an hypertrophied bladder removed from a case of stricture of the urethra By E. Hurry Fenwick 172
9. Extra-peritoneal wound of bladder without extravasation (Card specimen) By J. H. Targett 176
10. Subperitoneal rupture of bladder (Card specimen) By W. Bruce Clarke, M.B. 177
11. Sacculated bladder with calculus fixed behind prostate (Card specimen) By C. Mansell Moullin 178
12. Tumour (papillomatous) removed by supra-pubic cystotomy (Card specimen) By Sydney Jones 179
13. A case of villous tumour of the bladder (Card specimen) By Frank Henkley and E. Hurry Fenwick 179
14. Double epithelioma of the bladder By W. Bruce Clarke, M.B. 181
15. Encephaloid disease of apex of bladder (Card specimen) By E. Hurry Fenwick 182

PAGE

16. Chondrifying sarcoma removed, together with multiple papillomata, from the male urinary bladder (Card specimen) By SAMUEL G. SHATTOCK 183
17. Acute tubercular exfoliating cystitis (perforation) (Card specimen) By E. HURRY FENWICK 187
18. Purpura hæmorrhagica of the bladder (Card specimen) By E. HURRY FENWICK 188
19. Bladder, kidney, and dura mater from a case of purpura (Card specimen) By F. CHARLEWOOD TURNER, M.D. 189
20. Urinary organs from a case of Bilharzia hæmatobia (Card specimen) By REGINALD HARRISON 191
21. Spontaneous disintegration of vesical calculus By W. M. ORD, M.D. 191
22. Calculus formed round an india-rubber umbrella ring (Card specimen) By E. HURRY FENWICK 193
23. Large vesical calculus with hair-pin as nucleus (Card specimen) By SYDNEY JONES 194
24. A case of carcinoma of the right lobe of the prostate By E. HURRY FENWICK 195
25. A case of metastatic carcinoma of the prostate By E. HURRY FENWICK 196
26. A case of carcinoma of the left vesicula seminalis and adjoining lobe of prostate By E. HURRY FENWICK 199
27. Thickened capsule of testicle (Card specimen) By G. N. PITT, M.D. 200
28. Cystic tumours of the testicle [With Plate X, and Table of Cases] By FREDERIC S. EVE 201
29. Cases of small round-celled sarcoma of testicle and spermatic cord By F. SWINFORD EDWARDS 221
30. A dermoid cyst of the right testis By D'ARCY POWER, M.B. 224
31. Tuberculosis of the uterus (Card specimen) By R. G. HEBB, M.D. 226
32. A specimen of early pregnancy in the fimbriated extremity of a Fallopian tube, with retro-uterine intraperitoneal hæmatocele, and a decidual cast of the uterine cavity By W. S. A. GRIFFITH, M.B. 227
33. Note on the pathology of tubal pregnancy By LAWSON TAIT 230

PAGE

34. Additional note on the pathology of extra-uterine pregnancy By Lawson Tait 236
35. A pair of chronically inflamed uterine appendages, illustrating the development of tubo-ovarian cyst By Alban Doran 241
36. Two cases of hydrosalpinx (Card specimen) By G. N. Pitt, M.D. 244
37. Fibro-myoma of the ovarian ligament By Alban Doran 245
38. Uterus extirpated on account of large fibroid in pelvis interfering with the functions of the rectum and bladder (Card specimen) By Sydney Jones 247
39. Large uterine fibroid and the uterus with a smaller submucous fibroid (Card specimen) By Peter Horrocks, M.D. 249
40. Ulcer of vagina (Card specimen) By G. N. Pitt, M.D. 249

VI. DISEASES, ETC., OF THE OSSEOUS SYSTEM.

1. A neglected point in the pathology of Colles' fracture By D'Arcy Power, M.B. 250
2. Colles' fracture repaired with forward displacement of the lower fragment (Card specimen) By Samuel G. Shattock 260
3. Osteomyelitis of scapula; separation of its coracoid epiphysis; pyæmia (Card specimen) By John Poland 261
4. A case of osteitis deformans associated with a sarcomatous tumour of cerebellum By A. H. Robinson, M.D. 262
5. Case of disease of the humerus By John R. Lunn 266
6. Case of acute necrosis of the fourth cervical vertebra in a man of forty-eight By Samuel West, M.D. 268
7. Two specimens of osteomalacia, showing metaplasia of the osseous substance into fibrous tissue By Samuel G. Shattock 270
8. Case of infantile scurvy (Card specimen) By T. Colcott Fox, M.B. 275

PAGE

9. Extensive disease of the bones from a case of congenital syphilis associated with rickets
By William Henry Battle 279
10. Tubercle of the skull leading to perforation
By Bilton Pollard 284
11. A new growth, apparently springing from the periosteum of the right clavicle, and extending into the triangles of the neck, &c. (Card specimen) By J. R. Lunn 287
12. Sarcoma of clavicle (Card specimen)
By William Bull, for Mr. Rouse 287
13. The sequel of a case of central sarcoma of the femur (Card specimen) By D'Arcy Power, M.B. 288
14. Sarcoma (?) of the lower end of the femur
By Jonathan Hutchinson, F.R.S., and J. Hutchinson, jun. 288
15. Cystic enlargement of metatarsal bone; sarcoma (Card specimen) By John H. Morgan 294
16. Congenital dislocation of the hip
By Anthony A. Bowlby 295
17. Congenital dislocation of hip (Card specimen)
By John H. Morgan 298
18. Congenital (?) displacement of the hip (Card specimen)
By D'Arcy Power, M.B. 299
19. Bilateral dislocation of the hip-joints, probably congenital (Card specimen) By Samuel G. Shattock 299
20. Remarks on congenital displacement or so-called dislocation of hip-joint [With Plates XI to XVIA]
By Wm. Adams 300
21. Two specimens of fœtus, illustrating absence of the margin of the acetabulum, with and without displacement of the head of the femur By C. B. Lockwood 303
22. Destructive inflammation of knee-joint without suppuration By Jonathan Hutchinson, F.R.S. 312
23. Senile arthritis By Thomas Smith 313
24. Microscopic sections from six cases of tubercular arthritis (Card specimen) By Samuel G. Shattock 316
25. Drawings of multiple joint affection in a case of locomotor ataxy [With Plate XVII]
By A. H. Robinson, M.D. 319

VII. DISEASES, ETC., OF ORGANS OF SPECIAL SENSE.

PAGE

1. A rhinolith (Card specimen)
By D'Arcy Power, M.B. 321
2. Microphthalmos on the left side in a newborn child (Card specimen) [With Plate XXV, fig. 1]
By Samuel G. Shattock 321

VIII. MORBID GROWTHS AND TUMOURS.

1. Multiple, painful, fatty tumours of arms (Card specimen) By Frederic S. Eve 323
2. Subpleural lipoma of diaphragm
By Francis W. Clark 324
3. Soft fibroma of palm of hand By Sydney Jones 324
4. Multiple angiomata of leg with multiple enchondromata and a sarcoma By Frederic S. Eve 326
5. Sarcoma of the back with fibrous nodules over it (Card specimen) By J. H. Targett 330
6. Sarcoma of pelvic fascia By Leopold Hudson 331
7. Sarcoma of pelvis simulating pelvic hæmatocele during life (Card specimen) By William Collier, M.D. 334
8. Sarcoma of dorsal vertebræ; intraspinal hæmorrhage; (?) secondary (Card specimen)
By Herbert W. Page, for Thomas F. Raven (Broadstairs) 335
9. A case of alveolar sarcoma
By G. R. Turner and S. Delépine, M.B. 335
10. Recurrent? melanotic sarcoma of the breast [With Plate XIX, fig. 1] By Henry T. Butlin 343
11. Adeno-sarcoma of tongue with calcifying nodule in the centre [With Plate XVIII]
By Rickman J. Godlee, M.S. 346
12. Tumours of the palate [With Plate XIX, fig. 2, and Plate XX] By Stephen Paget 348

PAGE

13. Melanotic sarcoma of the hard palate (With Plate XXII, fig. 1] By FREDERICK TREVES 350
14. Horny papilloma of hand [With Plate XXI] By WALTER EDMUNDS, M.D. 352
15. Horny growth from the neck (Card specimen) By ALBAN DORAN 354
16. A case of a horn growing from the glans penis, associated with epithelioma (With Plate XXIII, fig. 1] By A. PEARCE GOULD 355
17. Unilateral papilloma of tongue (Card specimen) By FREDERIC S. EVE 358
18. Large parotid tumour (Card specimen) By SYDNEY JONES 358
19. Multilocular cystic tumour of the lower jaw By ANTHONY A. BOWLBY 359
20. Malignant cysts of the neck [With Plate XXII, figs. 2 to 4] By FREDERICK TREVES 360
21. Three cases of cystic epithelioma of the neck By A. QUARRY SILCOCK, B.S. 374
22. Recurrent epithelial tumour of foot (Card specimen) By S. PAGET, for Mr. THOMAS SMITH 376
23. Carcinoma myxomatodes (Card specimen) By WALTER EDMUNDS, M.D. 377
24. Some intra-bursal growths By G. H. MAKINS 377
25. Further specimens of intermuscular synovial cysts [With Plate XXIII, fig. 2] By D'ARCY POWER, M.B. 381
26. Ranula and cysts in the neighbourhood of the hyoid bone By J. BLAND SUTTON 386
27. Large dermoid cyst over the sternum By H. H. CLUTTON 393
28. Congenital sacral tumour containing bone (Card specimen) By J. H. TARGETT 395

IX. DISEASES, ETC., OF THE DUCTLESS GLANDS.

PAGE

1. Cancer of the thyroid By G. Stoker 396
2. Malignant disease of thyroid (round-celled sarcoma) (Card specimen) By Stephen Paget 397
3. Sarcoma of left lobe of thyroid growing round œsophagus, and invading left internal jugular vein and left vagus. *Ante-mortem* clot on right side of heart containing growth (Card specimen) By G. N. Pitt, M.D. 398
4. A case of simple diffuse goitre, with secondary tumours of the same structure in the bones of the skull [With Plate XXIV] By Joseph Coats, M.D. (Glasgow) 399
5. Tubercular mass in suprarenal capsule By Harrington Sainsbury, M.D. 406
6. Genito-urinary tuberculosis, with caseation of both suprarenal capsules (Card specimen) By S. Coupland, M.D. 408
7. Morbus Addisonii (Card specimen) By William Pasteur, M.D. 409

X. DISEASES OF THE SKIN.

1. Tubercular disease of the skin (Card specimen) By Samuel G. Shattock 410

XI. SPECIAL COMMUNICATIONS.

1. Cultivation-experiments with new growths and normal tissues, together with remarks on the parasitic theory of cancer [With Plate XXV, figs. 2, &c.] By Charles A. Ballance and Samuel G. Shattock 412

XII. MISCELLANEOUS SPECIMENS.

PAGE

1. Bacilli of leprosy (Card specimen) By BEAVAN RAKE, M.D. 439
2. Case of included ovum By SEYMOUR TAYLOR, M.D. 440
3. "Lithopædion" (Card specimen) By C. STONHAM 445
4. Trunk of an infant, showing a persistent fœtal condition of the peritoneum (Card specimen) By C. STONHAM 445
5. Congenital abnormality of lower lip associated with cleft palate (Card specimen) [With Plate XXVI] By H. H. CLUTTON 446
6. Congenital malformation of hand (Card specimen) By SYDNEY JONES 447
7. Hydatid of the breast (Card specimen) By C. J. SYMONDS, M.S. 448
8. Hammer toes (Card specimen) By SAMUEL G. SHATTOCK 449
9. The parts after removal of the ovary six months previously (Card specimen) By SAMUEL G. SHATTOCK 450

XIII. DISEASES, ETC., OF THE LOWER ANIMALS.

1. Diseases of the genito-urinary organs in animals [With Plate XXVII] By J. BLAND SUTTON 451
2. A curious effect of rickets on the skulls of young lions By J. BLAND SUTTON 456

XIV. DISEASES, ETC., OF VEGETABLES.

1. Vegetable tumours in relation to bud formation; with a new theory of neoplasia By W. ROGER WILLIAMS 460

REPORTS OF THE COMMITTEE ON MORBID GROWTHS.

PAGE

1. On Mr. Hutchinson's specimen of sarcoma (?) of the lower end of femur (J. F. Payne, S. Coupland, A. A. Bowlby, and C. J. Symonds) 292
2. On Mr. Butlin's specimen of recurrent (?) melanotic sarcoma of the breast (with Plate XIX, fig. 1) (R. W. Parker and S. G. Shattock) . . . 345
3. On Dr. Edmunds's specimen of horny papilloma of the hand (R. W. Parker and S. G. Shattock) . . 353

LIST OF PLATES.

		TO FACE PAGE
I.	Diffuse Sarcoma of Spinal Pia Mater. (Dr. COUPLAND and Dr. PASTEUR.) (Page 26) . .	28
II.	Microscopical Characters of Diffuse Sarcoma of Spinal Pia Mater. (Dr. COUPLAND and Dr. PASTEUR.) (Page 26) . . .	30
III.	Lesions in Infantile Paralysis. (Dr. SHARKEY.) (Page 53)	55
IV.	Figs. 1 and 2. Lesions in Alcoholic Paralysis. (Dr. HADDEN.) (Page 57) Figs. 3 and 4. Peripheral Neuritis in Raynaud's Disease. (Dr. WIGLESWORTH.) (Page 61)	60
V. VI.	Neuro-fibromata in connection with Molluscum Fibrosum. (Dr. PAYNE.) (Page 69) . .	72
VII.	Diffuse Syphiloma of Heart and Liver. (Dr. PASTEUR.) (Page 103) . . .	105
VIII.	Syphilitic Arteritis. (Dr. SHARKEY.) (Page 124).	126
IX.	Primary Scirrhus of Liver. (Dr. PITT.) (Page 151)	156
X.	Cystic Disease of Testis. (Mr. EVE.) (Page 201)	206
XI. to XVIA	Osseous Lesions in Specimens of Congenital Displacement of Hip-joint. (Mr. W. ADAMS.) (Page 300)	302
XVII.	Charcot's Joint Disease. (Dr. A. H. ROBINSON.) (Page 319)	320
XVIII.	Adeno-sarcoma of Tongue. (Mr. GODLEE.) (Page 346)	347
XIX.	Fig. 1. Recurrent Melanotic (?) Sarcoma of Breast. (Mr. BUTLIN.) (Page 343) Fig. 2. Tumour of the Palate. (Mr. S. PAGET.) (Page 348)	349
XX.	Tumours of the Palate. (Mr. S. PAGET.) (Page 348)	349
XXI.	Horny Papilloma of Hand. (Dr. EDMUNDS.) (Page 352)	~~352~~ 356

TO FACE PAGE

XXII. Fig. 1. Melanotic Sarcoma of Palate. (Mr. TREVES.) (Page 356)
Figs. 2 to 4. Malignant Cysts of Neck. (Mr. TREVES.) (Page 360) — 363

XXIII. Fig. 1. Horn on Penis with Epithelioma. (Mr. PEARCE GOULD.) (Page 355)
Fig. 2. Intermuscular Synovial Cysts. (Mr. D'ARCY POWER.) (Page 381) — 384

XXIV. Simple Diffuse Goitre with Secondary Tumours of the Skull. (Dr. COATS.) (Page 399) . 402

XXV. Fig. 1. Microphthalmos. (Mr. SHATTOCK.) (Page 321)
Figs. 2 to 7. Micro-organisms in Cultivation-Experiments with Cancer and Healthy Tissues, in which Accidental Contamination had occurred. (Mr. BALLANCE and Mr. SHATTOCK.) (Page 412) — 438

XXVI. Congenital Abnormality of the Lip. (Mr. CLUTTON.) (Page 446) 446

XXVII. Fig. 1. Renal Calculus in Coati. (Mr. SUTTON.) (Page 451)
Fig. 2. Ovarian Disease in Deer. (Mr. SUTTON.) (Page 451) — 452

WOODCUTS.

PAGE

—13. Diagrams showing site of endothelioma of dura mater (Dr. Hyla Greves) . . 21, 22
4. Adenoid sarcoma of pineal gland (Dr. Coats) . . 46
5. Syphilitic laryngitis (Dr. Jacob) . . . 84
6. Hour-glass constriction of stomach (Mr. L. Hudson) . 135
7. Ectopia vesicæ (Mr. Shattock) . . . 171
8. Hypertrophy of the bladder (Mr. E. H. Fenwick) . 174
9. Tubo-ovarian cysts (Mr. Doran) . . . 242
10—13. Congenital malformation of hip (Mr. Lockwood) 304—307
14. Fibroma of palm of hand (Mr. S. Jones) . . 326
15. Section of tongue, showing lingual duct (Mr. Sutton) . 388
16. Malformed hand (Mr. S. Jones) . . . 447
17. Skull of rickety monkey; horizontal section (Mr. Sutton) 457
18. Base of skull of rickety monkey (Mr. Sutton) . . 458
19. Skull of rickety lion (Mr. Sutton) . . . 459
20—29. Illustrating development of vegetable tumours in relation to bud formation (Mr. W. R. Williams) 466—490

ADDRESS

BY THE PRESIDENT, SIR JAMES PAGET, BART., F.R.C.S., D.C.L., LL.D., F.R.S.

DELIVERED AT THE FIRST MEETING AFTER THE ANNUAL GENERAL MEETING, JANUARY 18TH, 1887.

GENTLEMEN,—I thank you heartily for the honour you have conferred on me by electing me to be your President. It is a great compliment that I should still be thought fit to be President of a Society of which the most active members are much younger scientific men, some of whom are studying pathology in subjects and with methods almost unknown to me. If I can be at all fit for the office, it may be because, in my very imperfect knowledge of many of the numerous methods in which pathology is now studied, I can look with full respect upon them all; and, indeed, there are few things in relation to our science of which I am more sure than of this: that every possible method of studying it should be by all possible means promoted. And while I am your President this shall be my object, so far as I may have power.

I hope I shall not prove myself unwise if I do not take for the subject of my address that kind of knowledge in which alone I might claim superiority over my hearers, namely, the personal memories of the far distant past. It would be very pleasant to me to tell some of them, and might be amusing and flattering to those who can compare the best modern knowledge with that which it has displaced. But it may be more useful to think and speak of what may next be done, and how to do it. For every increase of knowledge brings before us a larger and clearer view of the immeasurable quantity which is still to be gained. The more we know, the more can we see, if we will, how much more there is that we do not know.

I wish I could indicate all or many of the ways in which new knowledge is to be gained; but I cannot. It is characteristic of

modern pathology that, as it certainly surpasses all other sciences in the variety and complexity of its problems, so it offers work sufficient for the employment of every variety and opportunity of the scientific mind. Pathology, as distinguished from practical medicine, used to be regarded as scarcely more than morbid anatomy; but now there is in it work not only for the anatomist and physiologist, but for the clinical observer, the experimentalist, the minutest microscopist, the statistician, the chemist, the naturalist, the historian, the psychologist, and yet more. I cannot pretend to be all these; and I will not pretend to decide who has done the best work or is most likely to do it in the future. Only, it is certain that complete pathology must be constructed from the works of all these; they are all mutually dependent, mutually corrective; none can alone suffice, and none can safely be neglected.

But, of all the methods of study, there are only two with which I have been much occupied—those, namely, of pathological anatomy and of clinical pathology in active practice. I can therefore speak of the future employment of only these two, But I will hope they may suffice, especially as the greater part of the members of the Society are engaged in them, and because we may justly believe that practice and pathological anatomy, if they be studied with the scientific mind and methods, will still contribute largely to the progress of the whole science of pathology.

I say practice studied with the scientific mind, because practice is often spoken of as if it were altogether distinct from science and inconsistent with it. We hear science and practice spoken of as in opposition, and sometimes as if they were mutually distrustful. I will not deny that strange contrasts of the practical and the scientific may be found among us; but these contrasts are constantly becoming more rare, and it is an excellent influence of this Society that it tends to cultivate the scientific mind, and to maintain it in the practical life. For what practice may be depends, in all respects, much more on the person engaged in it than on its own subject-matter. It may be for one a noble profession, for another a vile trade; and in equal contrast it may be a mere useful art practised by one who has neither love nor knowledge of any science, or to the man of scientific mind it may be a thoroughly scientific study, as well as an applied science. I could name many living in active practice, of whose work a great part is as definitely scientific as is that done in any other section of biology. And so

are the works of many who are gone. For example, I know no reasonable definition of science which would exclude the researches by which Bright obtained the knowledge of the disease which bears his name; or which, in a just history of pathology, would separate, as if they were of different merits, the clinical and the experimental researches from which we have our knowledge of the diseases of arteries and veins. Surely, it would be hard to name a discovery in biology which more deserves the name of scientific than does Jenner's discovery of vaccination; and yet it was made in the plainest practical manner while he was a country practitioner. But, observe, Jenner was a thorough naturalist, trained by John Hunter; and I suspect it will be found that all the best advances in clinical pathology, the best not only in their utility, but in their fitness for adjustment among the largest principles of our science, have been made by practitioners who were either by nature or by cultivation men of scientific mind. And it is as sure as anything of the kind can be that similar studies by men of similar mind will still attain as good results.

Practice is full of opportunities for science. Let me suggest only one group of them. Reflection on any day's work in practice may convince us that we have been using a good deal of knowledge or belief which we cannot explain by its relation with other knowledge, whether in pathology or any other branch of science. We may have given what are called specific medicines, or have advised some one in the belief that he was predisposed to some disease, or may have talked of functional diseases. Yet I doubt whether in any of these things there are more than unexplained facts; and if there are not, then we may be sure that the facts are very hopeful beginnings for scientific study by those engaged in practice. I may illustrate this by the example of the use of some of the specific medicines, such as that of quinine in malarial diseases, of mercury and iodide of potassium in syphilis, of arsenic in many cases of psoriasis, or of bromide of potassium in some cases of epilepsy. Here are sure facts, practical and useful, as sure as anything in therapeutics. I would not call them scientific; for, so far as I know, they are isolated facts, and separate from what may be called general laws in biology. They are, indeed, the chief of those facts which, in some minds, bring our clinical pathology into discredit; for being only useful and not scientific, they are cited as examples of unscientific practice. They are called empirical, and the

empiric is deemed equivalent with the quack. Let me say, as in parenthesis, that I think we have here an example of the common fate of words in our language—that if a word acquires a discreditable meaning, its better meaning is gradually lost, and only the worse remains with it. For the empiric and the experimentalist are, I think, synonymous; and yet in pathology the one, having a degraded name, is now deemed a hopeless hindrance to progress, and the other is its hero.

But, however this may be among these empirical facts, modern scientific work in practice may win great riches for pathology; for the medicines I have named are not only remedies, but diagnostic tests; they prove differences among diseased conditions that in other things appear alike. The epilepsy which is averted by the habitual use of bromide of potassium cannot depend on the very same conditions as that which is not so averted; the ulcer which heals under the influence of mercury cannot be of the same kind as that which looks like it, but does not so heal. Thus, as we all know, these medicines are tests; and we may guess that each of them detects the presence of some material belonging only to the disease which it cures. Here, then, is work for the scientific practitioner; he may find the material and more, if he will observe the facts in practice much more minutely, and record and collect them, and bring to bear on them as much light as possible from other sections of pathological science. They will yield more knowledge, and his practice will be promoted to a better title than "empirical."

Let me again refer to some facts which I have already mentioned, and which are now accepted in the largest principles of pathology. I remember that during my apprenticeship, more than fifty years ago, in a *post-mortem* examination of one who had died with dropsy, a young Guy's man cut across one of the kidneys and said, "Dr. Bright, of Guy's, says there is a form of dropsy which is always associated with disease of the kidneys." This was accepted by the practitioners standing by as a singular fact, and nothing more. I should find it difficult to tell now into what, with fifty years of scientific culture, that singular fact has grown. Or, again, could any fact stand more alone than did that of the use of vaccination as first observed by Jenner? And now it may be honoured as the first knowledge attained in all that wide range of pathology in which Pasteur's great work has been done, and to which Power

and Klein have lately annexed their admirable discovery of the true source of the milk-scarlatina.

There are many more of this group of facts of which we have better knowledge in practice than we have in morbid anatomy or any other section of pathology. We are sure, for instance, that there are certain conditions which are justly called predispositions to disease; but in what many of these consist we are, I suppose, quite ignorant. There are diseases or disorders which we must be content to call functional, though I suppose none of us would hold that there can be any change in the working of a part without a change in its structure or composition. We know that certain disorders, such as typhoid and scarlet fever, are apt to be followed by certain other disorders, which we call their sequels; but we have not yet shown the changes of which the sequence is a necessary consequence. We know that different morbid conditions may be combined, as in diseases which we may call hybrid or mongrel; we can recognise many of these combinations during life; they are things to be "attended to," as we say, in treating cases; but of the allied varieties of morbid changes of structure or composition, and of the lessons they would teach, we know, I think, at present very little.

How may these defects be remedied? Surely the best way will be by study and minute scientific work in practice. I say emphatically minute work, for I think it can be proved by the example of other sciences that the more minute the inquiries and the facts obtained by them, the more sure and complete will the fusion of pathology become with the whole body of biological science, and the more will it thence gain.

Now, these more minute investigations may be made not only in the records of clinical observation,—which may be far more minute than they are now,—but, I venture to think, even in microscopic examinations, especially if these be made, whenever it is possible, on the living as well as on the dead morbid structures. I would not, in any degree, depreciate the value of the knowledge gained by examining the well-defined structures which are shown in microscopic specimens prepared with hardening and staining and other fixing processes. They ensure a more exact diagnosis, and they may be studied deliberately and with comparison; but while they have all the value, they have also some of the defects, of botanical specimens dried and flattened in an herbarium. These are essential

to accuracy in descriptive botany, and to the diagnosis of species and varieties, but the vegetable physiologist must study living things. The herbarium tells little of the true plant-life, and of many processes in which that life is expressed, such as the minute intracellular movements and others of the like kind. Things of this kind, and important differences among them, may be found if the method of examining still living tissues can be improved, and if it be the rule to examine each morbid growth or product both directly after its removal from the living body, while it may be deemed still alive, and after it has been prepared for repeated examining by staining or other like processes. I venture to expect that by methods such as these, and with improving microscopic power, the sight may often reach far beyond the boundary of what has yet been seen and will detect differences of structure or of movement in what we are at present obliged to call structureless. And, even beyond this, I would hope that the microscope, with microscopic chemical tests, will detect differences which must be referred to differences of composition rather than of anything that can be called structure, and yet not less decisive of distinctive properties.

But I will not go on thus hoping, and perhaps only guessing. Let me only add one warning suggested by that word "structureless." It suggests the recollection that we are all apt at times to submit to the fascination of promises of finality; to find comfort in believing that we have really reached a boundary; that something is really structureless; or that there is a protoplasm which is the same always and everywhere, at least in the same species; or that in apparently similar substances there may be differences of potentiality; as if in things material there could be differences of power or property without differences of structure or of composition. We should get rid of these idle-making fallacies. The protoplasm in every structure, or of every embryo, must be as essentially different from that of every other, as is the structure or the creature which in due time it may become; and these differences will be discovered by our successors if we—I mean you—do not discover them. And one caution more. Let us never be content with present utility. Glad of it we may well be, and even proud, for science cannot be degraded by being useful in good things, and I suppose that of all utilities none can minister more happiness to those who most need it than ours may; but we must not be content with it as it is; it will be increased by every increase of our real knowledge.

Let me, before I end, again express my regret that I have been obliged to limit myself thus narrowly in speaking of pathology. Let me repeat that it is only because I have too little knowledge of other methods of study to speak of them definitely or even safely. But I earnestly hope that in our meetings we shall have contributions from them all, for all are essential to the progress of our science; and it will be a singular pleasure to me if, in my office as President, I can promote them. To do so will make my office very happy and very useful to me in helping me to avert that sad defect of old age, the indifference or dislike to the changes which come of the increase of knowledge. One sees that, as men grow old and wish for rest, they are prone to ask, Where are we to stop? I do not know more than this: that we must not stop where we are; we must go on and on, and we may be sure that they who work to find the truth will not work in vain—sure that with true work true good will come. So I will hope that it may be here during my presidency.

REPORT.

SESSION 1886-87.

I. DISEASES, ETC., OF THE NERVOUS SYSTEM.

1. *Meningeal hæmorrhage.* (*Card specimen.*)

By T. D. Savill, M.D.

The right hemisphere of the brain of a woman, E. B—, aged 69. The dura mater, which was healthy, has been removed, and shows an extensive hæmatoma over the whole of the convex surface. The outer surface of the hæmatoma is rough, more or less organised, and was adherent to the dura mater. Its inner surface is smooth, and is the seat of more recent hæmorrhage. About the thickness of a piece of wash-leather, it is thickest opposite the middle of the superior temporo-sphenoidal lobe, where it is connected with the brain by five or six small vessels. The brain-substance generally is healthy, but there is a hæmorrhage of probably two or three months' standing in the grey matter of the superior temporo-sphenoidal lobe at its middle. There were a few small hæmorrhages at other places on the inner surface of the dura mater.

The arteries of the brain showed no thickening or aneurysmal dilatation. The ventricles, cerebellum, and basal ganglia were normal.

The heart wall showed some fatty change, but otherwise this and the other organs were normal.

The patient's family history was very good, and in her previous history she had never had any illness. She had been very abstemious, and had not had syphilis. Three or four months before admission she had tripped on the curbstone and fallen, but she had suffered no inconvenience therefrom, either at the time or subsequently.

Five weeks before admission, when in her usual health, she fell down quite suddenly, and became completely unconscious. There were no convulsions, but she remained unconscious for forty-eight hours, and on recovery was found to have lost the power in the left arm and leg, the power of speech, and to have incontinence of urine. Before admission she had completely recovered, except for weakness of the left side.

On admission (August 5th, 1886) she seemed to be deaf, more so with the right ear, and her mind was confused, but she could talk rationally when roused. She could move both hands and both legs, and she could walk fairly well for her age, though there was some weakness on the left side. No anæsthesia or rigidity anywhere.

Some retention of urine, which was of good specific gravity, and contained no albumen.

The other organs were normal.

For three weeks after admission she remained in this condition, though her sleep used to be disturbed by a sort of muttering delirium, which gradually increased, and she had some degree of incontinence of urine and fæces; however, she used to get up daily. The nocturnal delirium then gradually increased, and she became somewhat incoherent by day, with well-marked delusions, and at the end of four weeks she took to bed again.

Eight weeks after admission the left arm was found to be completely paralysed, œdematous, tender, and painful on movement.

Ten days later than this she became very drowsy, and in the course of forty-eight hours passed into coma. She died fifteen weeks after the original attack.

The temperature during the illness had been normal, but three days before death it began to rise, and at her death reached 105°. Never at any time were there any convulsions.

Remarks.—The attack, five weeks before admission, was doubtless produced by the hæmorrhage on to the surface of the brain, which appeared to be situated between the parietal layer of the arachnoid and the dura mater; the later attack was due to a subsequent hæmorrhage.

The cause of the hæmorrhage here is exceedingly obscure. It is unlikely to have been connected with the fall, because the symptoms occurred after a considerable interval of health. The most careful examination of the arteries of the brain failed to detect the slightest sign of degeneration or aneurysm; indeed, the arteries

and tissues of the body generally were unusually healthy for a person of sixty-nine. There was no history of syphilis or intemperance. The hæmorrhage could scarcely have been preceded by a membranous formation on the inner surface of the dura mater, as described by Virchow, or, if so, the presence of this latter was unattended by any symptoms.

It is curious, bearing in mind the signs of irritation which were to be found in the cortex of the brain, that there were never any convulsions, either before or after her admission.

November 16*th*, 1886.

---

2. *Embolism of the basilar artery, with meningeal hæmorrhage from rupture of the posterior cerebral.* (*Card specimen.*)

By Henry Maudsley, M.D.

The specimen was taken from the body of a middle-aged woman five days after death, which accounts for the softened condition of the brain. The woman was unknown, but she was seen walking in the street half an hour before she was found dead.

The basilar artery at its bifurcation is occupied by a firm, white embolon, which extends into the right posterior cerebral as far as the posterior communicating, and completely obstructs this posterior cerebral; the left posterior cerebral is only partially obstructed. The right posterior cerebral, where it is joined by the posterior communicating, is ruptured, and the opening into the distal end of the vessel can be distinctly seen. The basilar artery and the other vessels at the base of the brain present no signs of atheroma or other degeneration.

Occupying the base of the brain, and extending along the Sylvian fissures to the vertex and round the medulla into the fourth ventricle, was a very extensive clot. The mitral valve was somewhat thickened and the left ventricle was hypertrophied.

The kidneys were of normal size, slightly granular on surface, and one presented several cysts, and a triangular depression suggestive of an infarct. The aorta showed no signs of atheroma.

November 16*th*, 1886.

3. *Hæmatoma of dura mater.* (*Card specimen.*)

By Harrington Sainsbury, M.D.

The specimen is shown for the fact of an extensive blood-clot covering the fronto-parietal region of the right hemisphere, and extending into the anterior and middle fossæ of the right side. The dura mater was adherent to it, in places somewhat firmly. From the surface of the brain it slid off on the separation of the dural adhesions.

The blood-clot is placenta-like in shape; its thickest part corresponds to the base of the second frontal convolution. Here the surface of the brain is depressed; it is also redder at this spot, apparently, however, from imbibition.

No source for the hæmorrhage, either from the surface of the brain or from the dura mater was discovered; the dura mater over the left hemisphere was to all appearances perfectly healthy.

The specimen represents an early stage of hæmatoma of the dura mater; it is from a woman, J. M—, aged 42, admitted into the Royal Free Hospital, under Dr. Samuel West, on December 1st, 1886.

On admission there was a semi-comatose condition, which persisted more or less till death, on January 2nd, 1887. Obscure paralytic symptoms were present, referable chiefly to the right side.

The woman was a drinker, and had recently drunk heavily. She was reported to have had a fall four days before admission; there was bruising over the right hip-bone.

No albumen in the urine. *January 4th*, 1887.

4. *Subdural hæmatoma.* (*Card specimen. Specimen furnished by Dr. McKinnon.*)

By J. A. Ormerod, M.D.

On the inner side of the dura mater, covering the left cerebral hemisphere, is a flattened, oval-shaped mass, measuring five inches by three and a quarter inches and one inch in thickness.

The dura mater passed over the outer surface of this mass, and was lightly adherent to it. The inner surface was lined by a membrane as thick as the dura, and not unlike it in appearance. Both surfaces were smooth, and before section the appearance presented was that of a cyst.

The section showed a yellowish-white substance, fairly firm for the most part, but in parts almost gelatinous. At the posterior (thickest) part of the mass was an old hæmorrhage.

The left ascending frontal and parietal convolutions and left superior parietal lobule were pressed upon and flattened. Upon the anterior surface of the frontal lobes were two small cysts, one on each side. With these exceptions the convolutions were well developed, and appeared quite normal. There was *slight* atheroma of the arteries at the base.

The patient was a cabman, of middle age. Had been in Bethnal House Asylum for dementia for three years. History previous to admission not known. Said yes or no, generally yes, to every question put to him. Had forgotten everything except a snatch of a song, which he was constantly repeating. No paralytic symptoms. He had albuminuria. *March* 15*th*, 1887.

---

5. *Old meningeal hæmorrhage, with cerebral softening and secondary descending degeneration.*

By W. Hale White, M.D.

Mary G—, aged 36. Seven years ago she fell whilst skating. Eighteen months ago she caught cold, the right arm and leg gradually became weak, and she completely lost the use of these

limbs; but after four months she could again walk with assistance. She gradually sank and died from a fæcal fistula, in connection with an old femoral hernia, the production of which she attributed to the fall whilst skating.

Autopsy.—Much wasted. The superior longitudinal sinus contained a quantity of *ante-mortem* clot, which extended into the right lateral sinus (she always lay on her right side). The cranial bones and cerebral arteries were normal. On the left side, over the ascending frontal and ascending parietal convolutions, the back part of a little of the first and third frontal and posterior third of the second frontal convolutions, was some soft, yellowish-white material, evidently very old blood-clot. The grey matter corresponding to the above area was quite gone, there being a distinct depression in the brain-substance filled up by the material just mentioned; the white substance immediately underneath was a little altered; no distinct degeneration could be seen in the internal capsule or pons, but the pyramidal tract in the medulla and the crossed and direct tracts in the cord were decidedly grey, translucent, and hard looking. The lateral column on the affected side was certainly the smaller. The kidneys were granular.

I have only brought this forward, as it is rare for a meningeal hæmorrhage to be so localised, and still more rare for it to be followed by secondary descending degeneration. The microscopes in the next room show that the degeneration occupies the usual tracts, both in the cord and in the medulla, and that histologically it accords with well-known descriptions. *April 5th*, 1887.

---

6. *Cerebro-spinal meningitis, causing an abscess in the œsophagus.*

By W. Hale White, M.D.

Elizabeth H—, aged 24, admitted April 21st, 1886, for general malaise, retraction of the head, and pyrexia. Rheumatic fever at sixteen and twenty-one years of age. Family history of phthisis. Fourteen days before admission she returned from work complaining of pain in the back; the next morning she vomited, and the head

became retracted. This continued till admission, when it was noted there was extreme lordosis; the head was drawn back to more than a right angle with the trunk; the abdomen was greatly retracted; there was severe headache.

She was in the hospital exactly a month. During this time the head remained retracted; the patient presented undoubted signs of meningitis, and she gradually wasted. About eighteen hours before death a quantity of pus began to pour from the mouth. A gag was inserted, but nothing beyond the extremely prominent anterior tubercle of the atlas could be felt. The pus trickled down into the lungs, and the patient died.

Post-mortem examination.—The cranial and spinal bones, dura mater, and blood-vessels were all quite healthy, without any trace of tubercle. There was a deposit of purulent lymph over the diamond-shaped space, and over the pons; the cerebral vessels contained a moderate amount of turbid fluid. The brain was quite firm; over the lower half of the cord, on the posterior surface, was a copious deposit of purulent lymph in the meshes of the pia mater, beneath the arachnoid. Opposite the cricoid cartilage, on its posterior surface, was an oval ulcer, with its long diameter vertically measuring an inch and a quarter from above downwards. It led down to the exposed cricoid, and had involved the perichondrium, but the cartilage itself was quite healthy on both surfaces. Opposite this ulcer was another one, on the posterior wall of the pharynx, more superficial.

There was some bronchitis; the mitral valve was a little thick. Everything else in the body, including the joints, was normal.

This case is brought forward on account of what is, to the best of my knowledge, a unique complication of cerebro-spinal meningitis, namely, the formation of an abscess over the cricoid cartilage in the wall of the œsophagus; for, in the absence of any other explanation of the source of the pus, I suppose we may take it that it came from an abscess which formed there, discharged its pus, and after death appeared as an ulcer. From a careful examination of the parts it appeared that the long-continued extreme retraction of the head, throwing the cervical vertebræ forwards and the cricoid cartilage backwards, together with the movements of the latter during respiration, caused an abscess in both the anterior and posterior walls of the pharynx. Probably the reason why this complication is not more frequently seen is that such extreme retraction

of the head, and such a long duration of the illness, are both of them very rare in cerebro-spinal meningitis.

Although I only show this case on account of the peculiar condition of the œsophagus, it is very interesting from an etiological point of view. It certainly belongs to the group described by Dr. Goodhart as meningitis of obscure origin ('Clin. Soc. Trans.,' vol. xix), and lends support, as the patient had had rheumatic fever, to the view that some, at least, of such cases are rheumatic.

November 16th, 1886.

---

7. *Recovery* (?) *from tubercular meningitis in chronic phthisis with disease of knee-joints and spinal caries.*

By R. E. Carrington, M.D.

Of course I am very well aware that the case I have the honour of bringing before the Society to-night may well excite criticism. Still, however, I venture to think that it must have occurred to many, if not to most of us, to have seen cases in which we have felt sure that we have had to deal with meningitis, in some cases probably of tubercular origin, but in which we have been led to doubt the correctness of our diagnosis by the recovery of the patient.

Now, it seems to me that if we lay down the rule that tubercular meningitis is of necessity fatal, we beg the question, and therefore that any case bearing upon the point of prognosis of meningitis, tubercular or not, is worthy of discussion by the Society.

I propose first to give an account of the history of the case and of the autopsy, and then to make a few remarks upon the various points which commend themselves to me, as at all events suggesting that this was a case of recovery from tubercular meningitis.

The history of the patient was as follows:

He was a boy sixteen years of age, who was three times admitted into Guy's Hospital, under the care of Mr. Durham, to whom I am indebted for permission to record the case.

His father, mother, and two brothers and three sisters were alive

and well, but he had lost three sisters in infancy from causes which were not ascertainable. His health had always been good up to eighteen months prior to his first admission, on July 4th, 1885. At that time he was knocked down by a tricycle, which struck him on the right knee. He only kept in bed a week and then went to his work as a clerk; but the knee continued to swell, and in the course of about a year movement became much impaired. Then, about fifteen months after the accident, the left knee became swollen, and subsequently its motility much diminished. There was little or no pain throughout.

Under treatment—by strapping with Scott's ointment, blistering, and splints—he became much improved, and was discharged on November 2nd, 1885. He had regained considerably the use of the left leg, but the right was still under treatment.

He attended the hospital fortnightly up to the last week of 1885, but after that, not until January 26th, 1886, when it was found that he had developed a posas abscess on the right side, and he was readmitted. There was still a good deal of swelling and immobility in each knee, but his back was absolutely free from either tenderness, weakness, or deformity. The abscess burst on February 20th, and was shortly afterwards incised with antiseptic precautions, about a pint of laudable pus escaping. On March 25th a Sayre's jacket was applied. The amount of discharge from the abscess diminished daily, and the patient improved so that he was sent home on April 24th, 1886, still, however, wearing the jacket.

The highest temperature recorded was on February 26th, when it was 99·6° in the morning and 101° in the evening. During the rest of his stay it averaged 98·4° to 98·6°, only exceeding 99° on two or three occasions, and then only by one or two tenths of a degree.

On October 2nd, 1886, the patient was again admitted into the hospital. He was now greatly emaciated and very anæmic. The abscess was discharging freely very offensive pus, and there was now a swelling in the left groin. He had been wearing a Sayre's jacket the whole time. The urine was of sp. gr. 1020, and contained a trace of albumen and a little pus, but no other abnormal constituent.

The further history of the case is that the boy got progressively worse. On October 11th diarrhœa set in, which continued to the

end; and about this time a large psoas abscess developed on the left side.

On October 19th a bedsore appeared, and he gradually sank and died on October 21st, 1886.

The temperature was 100·2° on two occasions towards the end, and on one was 100°, otherwise it rarely exceeded 99°.

The autopsy was made by myself thirteen hours after death, in rainy temperate weather. The body was much emaciated; rigor mortis was well marked. There was no dropsy. There was a small superficial bedsore over the sacrum, not, however, leading down to the bone. The cranial bones were healthy. The dura mater and sinuses and cerebral arteries were healthy. The arachnoid and pia mater were much thickened all over, both at base and vertex. The anterior and both sylvian fissures were matted together by firm fibroid adhesions, and on examining the membranes in these situations they looked quite granular, and here and there small yellow grains of the size of millet seeds or smaller could be sparsely made out.

Microscopic examination showed that these were undoubtedly tubercles, being small rounded masses of cells, oftentimes with a structureless granular centre. Two of the slides which I hand round show these bodies obviously to the naked eye; and further, a small dark spot may be seen in the centre corresponding, doubtless, to the caseous focus. There was no recent lymph about the membranes at any part. The brain was healthy in all its parts; it weighed 50 oz. There was caries of the fourth and fifth lumbar vertebræ, and complete destruction of the intermediate cartilage. From this point a large psoas abscess extended down into the thigh on each side. The pia arachnoid of the cord was generally thickened over the lower third on the posterior surface. It looked as though there was a deposit of purulent lymph, but none could be made out. There was no connection with the bedsore through the bone, neither was any tubercle here discovered. Except that the spinal cord was of soft consistence it was healthy throughout. On the whole, however, it appeared probable that the spinal meningitis was much more acute than the cerebral. There were ancient tubercular scars and small caseous masses at the apex of each lung, otherwise these organs were healthy. The pleuræ were healthy. The left ventricle of the heart was a little thickened; the muscle was good, and the valves were healthy, as were also the great vessels. The peritoneum, mouth, pharynx, œso-

phagus, stomach, pancreas, adrenals, large intestine, and liver were healthy; the latter organ weighed 52 oz. The small intestine was lardaceous. The spleen weighed 10 oz.; it was markedly lardaceous, being a typical "sago spleen." The kidneys weighed 11 oz., and were coarse in texture, but otherwise looked quite healthy. The bladder and testes were healthy. The right knee-joint was completely disorganised, the cartilage having nearly if not quite disappeared.

I admit that the case is open to question, but still I venture to think there are many cogent reasons that the case may be regarded as one of old tubercular meningitis which at one time had undergone recovery.

I should perhaps lay most stress on the association of old meningitis, old tubercular phthisis, caries of the spine, and chronic disease of both knees, as evidence of the tubercular nature of the whole. But, in addition, I think the naked-eye and microscopic appearances of the membranes were equally distinctive.

Probably the spinal meningitis was of more recent origin, and directly due to the caries; for I think it could not have owed its origin to the bedsore.

No doubt it may be said that the origin of the disease lay in the blow on the knee; but this only confined the patient to bed for one week, after which he went back to his work as a clerk, and continued at it up to his admission into Guy's Hospital eighteen months after. There could have been no meningitis at that time. Further, the second knee was not affected for fifteen months afterwards, and then without further injury.

Again, I think it is pretty well admitted that latent tuberculosis may be excited by traumatic causes.

On the whole, I venture to suggest that this was a case of tubercular meningitis which at some distant period had been recovered from. Certainly there was evidence of very old obsolescent phthisis. Were the two diseases coincident? *January 4th*, 1886.

8. *Endothelioma of the dura mater.*

By E. Hyla Greves, M.D. (Bournemouth).

The specimen which I have the honour to bring before your notice is, I think, an endothelioma arising from the dura mater. The subject from whom it was taken was an old lady about sixty years old. Her history, briefly, is as follows: Her previous health had been excellent. She had been married and had a large family. There was no hereditary history of tumours. She first began to suffer from attacks of headache in September, 1883; it affected the right side, the pain being most intense over the anterior inferior angle of the parietal bone, which spot was also tender on percussion. Two or three months after the onset of the headache she began to experience attacks of spasm of an epileptiform character in the left arm and hand—the lower part of the left half of the face was also involved in the spasms. Sometimes she lost consciousness, but not always. The leg on the same side ultimately became similarly affected. She gradually lost power in her left side, but was not completely hemiplegic. She also suffered from giddiness and vomiting. There was slightly marked double optic neuritis. Her memory became greatly impaired, and she became gradually exhausted, and died on December 9th, 1884, *i. e.* about fifteen months after the onset of the symptoms. (I may mention that on account of the marked symptoms of localised cortical irritation, together with the other symptoms indicative of cerebral tumour, the question of operative interference was suggested to both the patient and friends, but they unfortunately would not countenance the idea, as the tumour ultimately proved one that could have been easily removed.)

Post-mortem report.—Permission to examine the head only was obtained.

On removing the skull-cap the dura mater was unduly adherent to the inner surface of the right parietal bone, over an area about the size of a shilling; at this spot the external surface of the membrane was rough and thickened, and the inner surface of the bone was eroded and slightly thinned over a corresponding area. There was slight bulging of the membrane around the roughened area. On raising the dura mater, it was found to be adherent to the centre

of the external surface of a tumour which lay immediately beneath it (Woodcut 1). The adherent portion of the dura mater corre-

WOODCUT 1.

Lateral surface (right).

sponded to the roughened and thickened area seen on its outer surface; elsewhere this membrane was freely separable from the surface of the growth. A branch of the middle meningeal artery crossed over the centre of the growth through the infiltrated portion of the dura mater, the walls of the vessel being evidently implicated at this spot. (This piece of artery was unfortunately lost.)

Viewed from the surface, the tumour was seen to lie deeply embedded amongst the convolutions in the immediate neighbourhood of the fissure of Rolando, which were much displaced and depressed, but nowhere actually implicated by the growth, which was perfectly circumscribed and freely separated from the brain substance (Woodcuts 2 and 3). In shape the tumour was hemispherical, about equal in size to half a small orange, its plane surface was external, lying in (immediate) contact with the internal surface of the dura mater, which was, as already described, adherent to its central portion, which was slightly depressed and "umbilicated." The margin of the growth was distinctly "crenated" Its diameter was two and three eighths of an inch, its depth one and a

half inches. On section it felt firm and tough, and looked somewhat fibrous, but not of a dense nature. There was no area of softening.

WOODCUT 2.

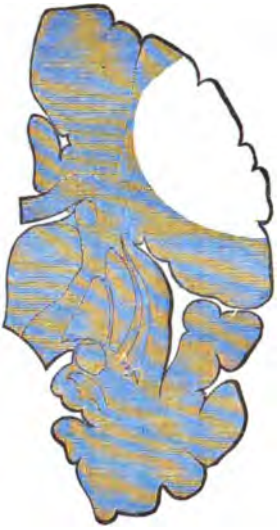

Frontal section.

WOODCUT 3.

Parietal section.

It was of a greyish colour, and slightly blood-stained in the centre. A delicate membrane separated it everywhere from the neighbouring convolutions, probably the pia mater.

On microscopical examination, the tumour is seen to be composed of "cell nests" and reticulated strings and bands of cells, with a small amount of fibrous tissue. The "cell nests" closely resemble those found in ordinary cutaneous epitheliomata, but they are of less size, and the cells of which they are composed are also much smaller. The "cell nests" are aggregated in groups throughout the tumour, these groups being separated from each other by strands of tissue which, at first sight, appear to be of a fibrous nature, but which, on closer examination, are found to consist of flattened cells arranged in reticulated layers. The growth contains numerous blood-vessels filled with blood, which do not appear anywhere to possess their usual true walls or coats, but rather to exist as channels between the tissue elements; this lumen being bounded, so to speak, by one or more layers of flattened cells circularly

arranged. This I think is one of the most striking structural peculiarities of the growth. Occasionally slight bulgings of the walls of the blood-vessels into shallow ampulla-like cavities may be seen, but I have not been able to detect their becoming detached from the main channel and forming separate buds, as described by Cornil and Ranvier in growths of a similar nature.

From the above description it will be seen that in structure this tumour closely corresponds to that form of sarcoma described by Zeigler[1] "as an *endothelioma.*" In speaking of sarcomata of a peculiar type, he says, "The way in which the alveolar structure (referring to 'alveolar sarcomata') is developed can often be clearly made out, especially in tumours of the central nervous system. The normal intervascular tissue is transformed into masses of sarcoma cells (which occasionally have an *epithelial type*), while septa are formed between the cell masses by the fibrous tissue lying along the course of the vessels. In other cases it looks as though a plexus of pre-existing or newly-formed vessels took on as it were an investment of cells, and this grew thicker and thicker, till at length the intervascular spaces were entirely filled up; accordingly we find this form of growth described as a *plexiform angio-sarcoma.*" It has also been described not infrequently as an *endothelioma;* on this view the "cell nests" arise by proliferation from endothelial cells. This certainly happens when masses of cells are formed from the endothelial covering of the subarachnoid network of the pia mater, the cells afterwards grouping themselves into nests. The vessels of the brain, lymphatic glands, serous membranes and testis, possess what is called a perithelium, *i. e.* the adventitia is invested with endothelial cells. Proliferation begins in the cells of this perithelium and the vessel is thus invested with a stratified covering.

This form of tumour is evidently similar if not identical with that described by Cornil and Ranvier as an *angiolithic sarcoma,* which only occurs in the cranio-vertebral canal, the parietal and visceral arachnoid, the pia mater, and the dura mater. They are sharply distinguished from all true epitheliomata by the fact that their blood-vessels are in direct relation with the cells, a condition which never exists in epithelial elements, either in the physiological or pathological state. The walls of the blood-vessels, whatever be their thickness, are entirely composed of cells similar to those

[1] 'Textbook of Pathological Anatomy' (Macalister's translation, vol. i, p. 220).

which constitute the entire morbid mass. The cells, feebly adherent to each other, are easily pushed aside by the blood-current so as to form vessels. Hollow buds are often seen communicating with the vascular channel; these buds in growing become pedunculated, while the cells which form the wall of the bud get flattened, arranged in concentric layers, and often become encrusted with calcareous salts. Sometimes the proliferous endothelial cells are aggregated into small spherical nodules of a peculiar lustrous appearance; this happens especially in the pia mater. Such growths have been designated *cholesteatomata*, or pearly tumours. Neither of these changes was observed in this particular tumour, nor have I been able to satisfy myself of the origin of the "cell nests" by budding from the vessels in the manner described by Cornil and Ranvier.

Eppinger has suggested that tumours of this description may possibly belong rather to the *dermoid* tumours.

As regards the question as to the innocency or malignancy of the growth, it is to be regretted that permission to examine the head only was obtained, so that I was unable to search for secondary growths; but during life there were no symptoms pointing to the implication of any other organ. The mere presence of "cell nests" affords no proof whatever of the malignancy of a new growth; on the contrary, they have been found (according to Thiersch) under various circumstances, *e. g.* "in lupus, in the hyperæmic borders of cicatrices, in sebaceous tumours, and in the epithelial covering of the gums." *February* 15*th*, 1887.

---

9. *Cholesteatoma at the base of the brain.*

By John A. P. Price, M.D. (Reading).

L. F—, a widow, aged 39, attended my out-patients' at the Berkshire Hospital during December, 1886, and January, 1887, complaining of peculiar feelings in her head.

Her illness commenced about five years ago, and she has gradually and slowly got worse. Four years ago she lost the sight of her right eye, and she now thinks the sight in the left is getting

weaker. She describes attacks as though of *petit mal*. She would suddenly feel queer in her head, sometimes fall if not supported, drop any article in her hand at the time, not lose consciousness, everything around her seemed strange, and her water would be discharged involuntarily.

Her complexion was dark, with a melancholy expression; her mental faculties were feeble, and it was difficult to elicit a clear account of her past history. There was no history or evidence of either syphilis or alcoholism.

The right optic disc was perfectly white and atrophied, the left was very pale, and the vessels of the fundus in both eyes were small and thin. The knee-jerk was present in both legs.

The patient gradually got worse, her attacks became more frequent, and on the morning of the 28th of January last she was found dead in her bed, the right side of the face and the right hand being quite purple, as was also the left hand.

The *post-mortem* examination was made on January 29th, at 4 p.m. Rigor mortis well marked.

On removing the skull-cap the vessels of the dura mater were seen to be distended with dark blood, and the dura mater itself, in the neighbourhood of the superior longitudinal sinus, thickened.

On removing the brain a large tumour was seen occupying the greater part of the base; it was extremely brittle, and, despite great care, kept splitting and crumbling into small portions; the dura mater and bone beneath the tumour were quite healthy.

On examining the tumour it may be seen to extend from the medulla oblongata posteriorly to the optic chiasma and optic nerves anteriorly, whilst laterally it presses outwards the temporo-sphenoidal lobes, which appear to encapsule some of the nodules of the growth. Posteriorly can be seen an irregular nodular portion of the tumour, with the characteristic mother-of-pearl lustre on its surface; the same lustre may be observed on the surface of the lateral nodules. An incision has been made into that on the right side, showing a definite capsule, which appears to be continuous with the pia-arachnoid membrane; the surface of the brain beneath the tumour appears free from any infiltrating growth. There seem to be no vessels running into and through the tumour. Lying on the medulla is a small cyst containing a sebaceous-looking substance.

On microscopical examination can be seen numerous crystals of

cholesterin, with the outlines of several cells devoid of nuclei. Here and there are a few dark granular masses.

The right optic nerve was removed, and appeared to be thinner than that of the opposite side, the apices of the lungs showing old scars, and in the left apex were two or three caseating masses. Some of the bronchial glands were extremely calcareous.

The heart, liver, spleen, and kidneys were healthy; other viscera were not examined.

Dr. Goodhart, who has kindly made a further examination of the specimen, reports as follows:—"The large mass on the right side has pushed the brain-substance before it to a considerable extent, and thus, on horizontal section, appears beneath the middle of the lateral ventricle outside the ganglia, upon which one would have thought it must have pressed. It is everywhere separated by membrane from the brain-substance, which appears to be quite healthy; and the tumour shells out, leaving the membrane behind, as belonging to the brain. There is also a nodular protuberance into the posterior part of the third ventricle, due to another portion of the basal tumour growing inwards. There is no doubt, I think, that the growth has formed in the membranes, but those of the ventricles appeared to be perfectly healthy."

A very full description of a similar though smaller tumour is given in the fifth volume of the 'Transactions' of this Society. The account of its minute anatomy by Dr. Bristowe, with a plate, constitutes the clearest and fullest description I have been able to obtain of such tumours of the brain. I have ventured to bring this specimen, even in its mutilated condition, before the Society, as it is exceptional, both in kind and size. *March 3rd*, 1887.

---

10. *Two cases of diffuse sarcoma of the spinal pia mater.*

By Sidney Coupland, M.D., and William Pasteur, M.D.

[With Plates I and II.]

Case 1.—Emily K—, aged 22, single, nursery governess, comes of a neurotic family. She had rheumatic fever in 1882, but with this exception has always enjoyed good health. She suffers from habitual constipation.

Her last illness began in June, 1885, with "bilious headaches," and frequent morning sickness. Towards the middle of July she complained of pain in the right shoulder and arm, which subsequently extended to the fingers. She was incapacitated thereby from lifting heavy weights. She left her situation on September 5th, and on that occasion walked a mile without much fatigue. At this time she was sick once or twice during the night, and suffered from pain all along the spine, but especially between the shoulders. She took to her bed on September 8th.

Her case was diagnosed as rheumatism, with "reflex vomiting," and was treated accordingly. At the beginning of October (1885) she was removed to the Chelsea Hospital for Women for a supposed displacement of the uterus. Here, however, the true nature of the illness being recognised, she was transferred to the Middlesex Hospital, under the care of Dr. Coupland, on October 7th.

State on admission.—A fairly-nourished, dark-haired girl, with unduly prominent eyes, complaining of constant pain in the occipital region, which radiates thence over the right scapula to the extensor aspect of the right arm. Skin dry, but not harsh. No eruption. No scars. All joints healthy.

Nervous system.—Memory of remote events is good, but her recollection of what has taken place within the last three months is imperfect. She answers questions correctly and without hesitation, but tends to ramble in an incoherent manner if her attention is not arrested to a fresh question. On the day of her admission she thought one of the clerks was her brother, and was convinced that one of the other patients was her mother.

Special senses.—Smell, taste, and hearing are normal. There is marked impairment of vision. With the right eye she can read large type easily, but with the left everything is blurred and indistinct. The pupils are equal and widely dilated. Both react fairly well to light, and the right slightly in accommodation. There is intense double optic neuritis. There is complete paralysis of both external rectus muscles, with simple diplopia. The voice has a slightly nasal twang, but no definite paralysis of the soft palate can be made out. The tongue is red and dry; the lips are covered with sordes. The breathing is regular, and sighing in character.

General sensibility.—Good everywhere. The scalp is very tender in the occipital region, and the patient complains of severe "numb" pain in the right arm, which is much aggravated by any attempt to

use the limb. During the last day or two she has also complained of shooting pains in the left thigh.

There is marked painful hyperæsthesia along the whole spine and over the right scapula. The patient is unable to lie on her back on account of the pain.

Motor apparatus.—The movements of both arms and legs are preserved, but there is a marked diminution of muscular power. The grasp of the right hand is hardly appreciable; that of the left very feeble. The patient is unable to stand without support, and drags both feet feebly along the floor in attempting to walk. The plantar reflex is present on both sides. The knee-jerk is absent on both sides. There is no ankle-clonus. The sphincters act normally. There have been no convulsions.

Progress and termination.—October 8th.—Patient was very restless and delirious in the early part of the night, but slept well after a morphine hypodermic.

October 9th.—Was very noisy and restless yesterday evening, and appeared to be in great pain. Morphine was again administered. After this patient slept quietly through the night, but towards morning gradually passed into a state of coma, and died at 5 p.m.[1]

Autopsy, nineteen hours after death.—Rigor mortis present. Body well nourished. Thoracic, abdominal, and pelvic organs healthy. No enlarged prævertebral glands.

Brain: Meninges over vertex perfectly natural. No signs of basic meningitis. On removing the brain, numerous gelatinous-looking nodules were seen on the inner surface of the dura mater in the posterior fossa near the foramina of exit of several cranial nerves.

Similar elevations were observed on the meninges overlying the body of the sphenoid, reaching backwards from the posterior clinoid processes almost continuously to the foramen magnum. These outlying masses of new growth were very soft and transparent, and easily detached. There was perhaps a slightly excessive quantity of cerebro-spinal fluid.

The medulla and pons were uniformly invested with a layer of jelly-like growth, in which both sixth nerves were completely embedded (Plate I). On transverse section the nervous tissue presented normal naked-eye appearances. On looking into the spinal

[1] It is not unlikely that the second dose of morphine accelerated the fatal issue.

DESCRIPTION OF PLATE I.

To illustrate the paper of Dr. Coupland and Dr. Pasteur on Diffuse Sarcoma of the Spinal Pia Mater. (Page 26.)

From drawings by Mr. Burgess.

It represents a portion of the spinal cord (lower cervical and upper dorsal regions), with the dural sheath laid open by a posterior median incision, and reflected. The cord appears to be greatly swollen, an appearance due to thickening and infiltration of the pia mater by new growth. The growth is most abundant on the posterior surface of the cord, as seen in the transverse sections taken from the upper and lower extremities of the portion of cord displayed.

The cauda equina is also represented. It exhibits a moniliform appearance of its nerve-trunks, from the presence of numerous small sarcomatous growths in their sheaths.

A portion of the base of the brain is also shown, displaying an extension of the pia matral growth over the medulla, pons, and crura cerebri, and the nerve-roots in connection therewith.

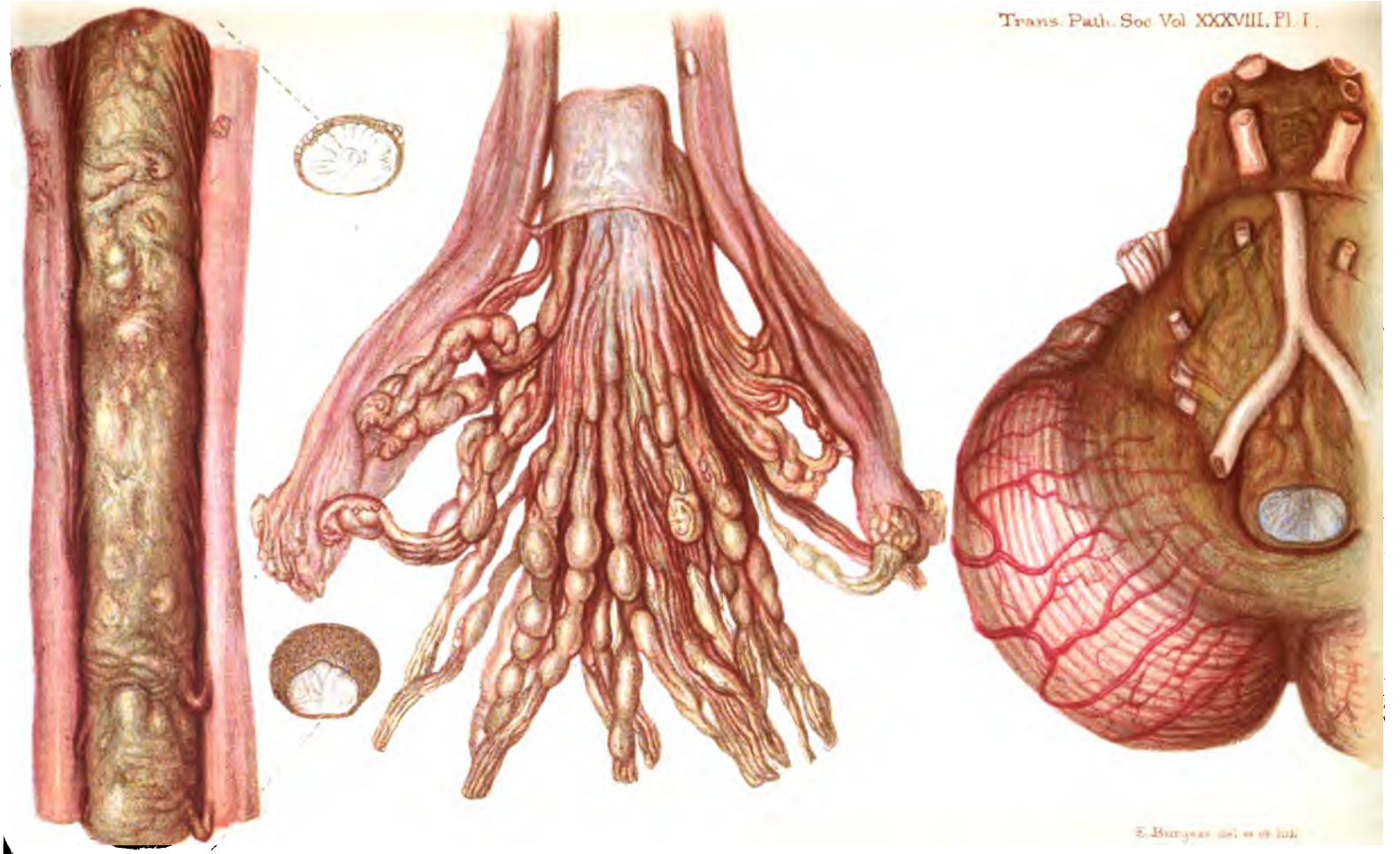

E. Burgess del et de lith.

canal from above, the cord looked larger than usual and the inner surface of the dural sheath was irregularly mammillated. The spinal cord was considerably larger than natural, and almost completely filled the vertebral canal. The outer surface of the dura mater was normal, and nowhere adherent. The vertebræ were healthy. On slitting up the dura mater it was found to be adherent to the cord at one or two spots in the upper cervical region, but otherwise quite natural. The cord itself was uniformly ensheathed in its whole extent by a semi-translucent, softish growth, which was most developed on its posterior and lateral aspects. It attained a maximum thickness of at least half an inch in the lower dorsal region (Plate I). On the anterior surface the investment was less complete, the growth being here distributed in the form of very numerous nodules between and around the nerves and nerve-roots. In the upper part of the lumbar region there was a small hæmorrhage in the growth posteriorly.

All the nerves of the cauda equina were found more or less completely surrounded by thin sheaths of new growth, which at intervals expanded into small tumours, the largest of which measured half an inch in length and one third of an inch in thickness (Plate I). Some of the tumours were situated on the outside of the nerves, whilst others were placed centrally, widely separating the component bundles of fibres. There were from two to five tumours on each nerve. Except in the upper cervical region the arachnoid was not adherent to the dura mater. In this region, however, the membranes were fused together over two or three small areas.

The growth in the vertebral canal was semi-translucent, of a greyish-white colour with a faint lemon-yellow tinge.

The tumours on the cauda equina were more translucent and much firmer than those found in the posterior fossa of the skull. The cord itself retained its normal shape and appearances throughout. The brain was normal.

Microscopical examination.—The histological characters of the new growth are remarkably simple Sections were made of the spinal cord at various levels, of the carotid artery at the base of the skull, the optic nerves, and the nerve-trunks of the cauda equina so as to include the nodular swellings on these trunks. In all, the structure of the new formation consisted in closely aggregated, small rounded cells, which stained deeply and uniformly with carmine, possessing only a minute central nucleus visible only

under very high powers, and closely resembling the elements of granulation tissue or leucocytes. These cells were embedded in a stroma, which was in most parts completely obscured by the luxuriance of the cell-growth. In no part was there any evidence of spindle-cell formation or fibrillation, nor was there to be found anywhere any indication of caseation or other necrotic process. The growth, then, was of the simplest cell type, meriting the name "granuloma" quite as much as that of "small round-celled sarcoma," to which we presume it belongs.

As regards the spinal cord, the pia mater in all parts was greatly and unequally thickened by the cell infiltration, the cells staining deeply with carmine, and thereby contrasting strongly with the tissue of the cord and the nerve-roots which were closely invested by them. The growth was closely incorporated with the white matter of the cord, which it invaded at several points and to the same depth, mostly along the lines of the normal trabecular ingrowths of the pia mater; but also in places presenting islets of cell-masses isolated in the midst of the neuroglia, the nuclei of which seemed under high powers to be abnormally numerous. It should be remarked that the nerve-elements of the cord have for the most part disappeared, so that the neuroglia was unusually evident. We attribute this to post-mortem disintegration; for it was equally marked in all parts of the cord from the failure of the hardening fluid to penetrate into the cord-substance through the thickened pia mater. (The nerve-tubules and axis-cylinders of the spinal nerve-roots which were embedded in the thickened pia mater were, on the contrary, well preserved.) The growth in the pia mater was traversed by blood-vessels, and closely invested the vessels of the membrane itself. It also surrounded the nerve-roots, penetrating between the nerve-bundles, and in places infiltrating the perineurium itself (Plate II, fig. 1). No corpora amylacea were met with.

On the cauda equina the tumours on the nerve-trunks proved to have caused a more extensive invasion of the nerves than the above. For the new growth in this situation not only completely infiltrated the epineurium and invaded the perineurium, but in the case of some, especially the outermost bundles, had penetrated the endoneurium, separating individual nerve-tubules more or less widely, as seen both in transverse and longitudinal sections (Plate II, figs. 2 and 3).

DESCRIPTION OF PLATE II.

To illustrate the paper of Dr. Coupland and Dr. Pasteur on Diffuse Sarcoma of the Spinal Pia Mater. (Page 26.)

From drawings by Dr. Coupland.

FIG. 1.—Microscopical section of posterior spinal nerve-root in dorsal region. There is an infiltration of small round granulomatous cells separating the nerve-bundles. About 300 diam.

p. Perineurium.
e. Endoneurium.

FIG. 2.—From a nerve of the cauda equina. Longitudinal section in region of one of the moniliform swellings shown in Plate I. The nerve-fibres are seen to be separated by abundant small-cell infiltration. About 50 diam.

FIG. 3.—From a nerve of the cauda equina. Transverse section. About 50 diam.

ep. Epineurium.
p. Perineurium.
e. Endoneurium.

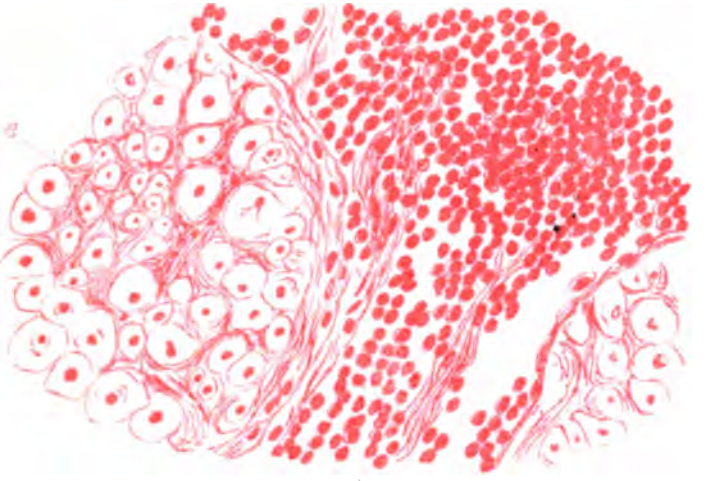

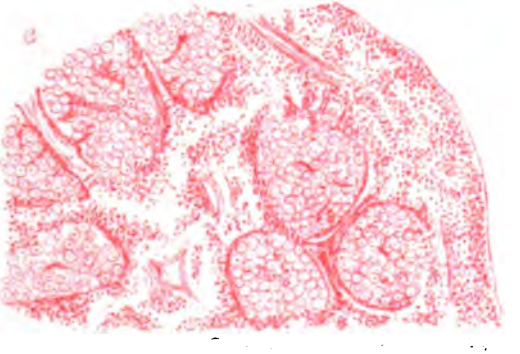

As regards the carotid artery, its outer coat was densely infiltrated, the cell-growth being permeated by the vasa vasi.

The optic nerves presented a normal appearance.

CASE 2.—For the notes of the following case we are indebted to the kindness of Dr. Charlton Bastian.

The patient was a girl 4½ years old. The family history is unimportant. The symptoms dated from a fall down a flight of fifteen steps two months before admission to University College Hospital (February 25th, 1880). She did not lose consciousness, but in a few days became very cross and irritable, in marked contrast with her previous disposition. At the end of two or three days a squint developed, and at the end of a month the child was unable to walk. She complained chiefly of pain in the upper part of the back and head. Throughout the illness there was a tendency to constipation. In bed she usually lay with the hips flexed, and the knees extended. Fourteen days before admission she suddenly became blind.

State on Admission.—No signs of rickets. Child quite conscious and answers intelligibly. Very irritable, but quiet if left alone. Pupils widely dilated and insensitive. Ocular movements perfect. Quite blind. No facial paralysis. Swallowing perfect. Tongue protruded in the median line. Lies in bed on either side, but begins to cry as soon as she is put on her back. Complains of pain in the back.

Ophthalmoscope: Discs grey and indistinct. No physiological cup. Right pupil contracted during examination. Other cranial nerves normal.

Motor apparatus.—Muscles of back weak. Head nods about if unsupported. Arms very weak, but retain their movements. No noticeable muscular wasting. Carries food to her mouth in a jerky, irregular manner. Can sit up with support, but is quite unable to stand. Tactile sensibility normal in arms and legs. Tâche cérébrale moderately distinct. Plantar reflex present.

March 12th.—There is pain and tenderness over the upper and back part of the head.

18th.—Frontal veins and veins of eyelids distended. Dusky pallor of face. Feeble cough and bronchitic râles over chest. Pupils equal and moderately contracted (during sleep). Does not raise the upper eyelids well. Increasing weakness of trunk muscles. Both arms seem totally paralysed. Can feel in the

hands, but not in the feet. Died without convulsion towards evening.

Autopsy.—The dura mater is rather tense. The convolutions are much flattened and the sulci partly obliterated, the arachnoid presenting a dull appearance with a greasy sticky feeling. Vessels in sulci rather unnaturally full. On removing brain, a large quantity of clear fluid (some 8 oz.) escaped from the ventricles.

Base of Brain: There is a layer of greyish material covering the under surface of the cerebellum (beneath the arachnoid), which extends back from the fourth ventricle over the middle and part of the lateral lobes. It is of variable thickness, and on section is found to penetrate for some half inch into the nervous tissue. A section through the middle lobe showed this to be almost entirely replaced by soft grey vascular growth. No ordinary signs of meningitis at base. Arachnoid over medulla and pons normal. There is a thin layer of new growth on the left side of the optic chiasma and optic nerve, and a similar patch on the under surface of the left lower temporal convolution, about the size of a pea. The lateral ventricle is greatly distended. Thalami and corpora striata of normal aspect.

Spinal Cord: Upper part distinctly swollen on section, with evidence of small scattered hæmorrhages in the grey matter. Anteriorly and posteriorly there is a layer of new growth beneath the arachnoid one sixth of an inch in thickness in the latter situation.

The growth here is whiter and less vascular than in the cerebellum. The cord is softer than usual, as is evidenced by the way in which it protrudes when sections are made through it at various levels. The posterior aspect of the cord is covered throughout by new growth, and in the lumbar region, where it is thickest, it ensheaths the lateral aspects also. The thickness of the new growth in the dorsal and lumbar regions varies from one quarter to one fifth of an inch.

On microscopical examination the new growth presents the characters of an encephaloid sarcoma, though the amount of stroma varied in different parts of the growth. The cells are mostly uniform in size, and bear a close resemblance in size and appearance to white blood-corpuscles.

A case presenting many points of similarity with ours is recorded by R. Schultz.[1] The patient, a female, aged 16, was admitted on

[1] 'Arch. f. Psych.,' 1885, p. 542. Abstracts of this case will be found in

March 31st, 1884. Her mother and sister had died of phthisis. Her maternal grandfather had been ill for some years with disease of the spinal cord, and her paternal uncle had died of gliomatous hypertrophy of the pons. The patient, who had suffered from pain in the back for three months, had not been really ill until within three weeks of coming into hospital. She then experienced very severe pains in the back, numbness and formication in the hands and arms, with gradually increasing weakness in the arms. A week before admission her arms became completely paralysed, and for two days she had formication in the feet, with gradually increasing weakness in the legs. For a week there had been difficult micturition, and throughout there was constipation.

Consciousness was fully retained. Latterly she had headache and sensations of cold and heat. She was well nourished and healthy looking, and sat in her chair with her arms hanging, scarcely being able to raise them. She was unable to walk more than a couple of steps, her gait being paretic. She could stand with the eyes shut without falling. The hands were red and swollen. There was tenderness on pressure over the main nerve-trunks of the upper limbs.

Next day her condition was much worse. As she lay in bed all the limbs were paralysed, but the legs could be moved slightly, and also the left arm. The sensorium was unaffected and the cerebral nerves intact. She complained of severe pains in the back. There was complete anæsthesia of both upper limbs as high as the shoulders. The hands were red, hot, and swollen. Tactile sensibility lost on the feet, but a needle-prick, which excited reflex contractions, could be perceived. The cutaneous sensibility on the thighs was similarly impaired. The knee-jerk on the right side was absent, on the left weak. Abdominal reflex absent on both sides. Muscular sense normal on both sides. Marked tenderness over the whole of the spine. Constipation; retention of urine.

On April 2nd she was worse, and could only move a few toes and fingers. The head was rigidly fixed—turned to the right. Breathing was slow and difficult. Death took place the same evening.

Diagnosis.—Acute meningo-myelitis.

At the *post-mortem* examination the cranium and its contents were found to be healthy. The vertebræ were normal. The

'Neurolog. Centralbl.' (Mendel), March 15, 1886, and 'Brain,' part xxxvi, Jan., 1887, p. 568.

spinal dura mater, beyond deep injection in the lower part, was of normal thickness and free from adhesions; but on laying it open the whole of the cord bulged out, presenting a sausage-like appearance. It was then found that the subarachnoid space in its whole extent, from the cervical region to the cauda equina, was occupied by a greyish-red mass of new growth covered by the delicate normal arachnoid. The new growth was nodular and lobulated, partly firm, in places soft and studded with hæmorrhages. It surrounded the spinal cord like a ring, the cord itself being soft, particularly so in the cervical region. In the lumbar and lower dorsal regions the growth completely ensheathed the cord, whilst in the upper dorsal region it only covered the posterior part. At one part, where the cord was much softened (upper dorsal region), the growth had penetrated into its substance.

Microscopically, the growth was found to be made up of large endothelial cells, traversed by numerous capillaries, which gave it an alveolar character. It was described as an alveolar sarcoma. There could be no doubt that the growth originated in the pia mater, where it could be seen spreading, even in parts which to the naked eye seemed normal (*e. g.* lower end of medulla). The condition of the cord was not that of myelitis, the changes induced in it being attributable to pressure; in places the medullary sheaths were broken up and the axis-cylinders swollen, or the neuroglia meshes were empty, and numerous corpora amylacea were present; but normal nerve-fibres were intermingled with these changes.

Schultz remarks on the comparative rarity of new growths of the spinal pia mater, and the extreme rarity of tumours which are spread over the whole length of the cord. Indeed, he had up to the time of writing found only one parallel case, recorded by Ollivier, the particulars of which are appended below. As regards his own case, Schultz points out the neuropathic tendencies in the family of the patient, and the clinical resemblance to acute meningo-myelitis, the rapid progress of the symptoms giving no ground for believing that the case was one of tumour. At the same time he thinks the disease must have lasted at least three months,—the time during which the patient had suffered pain in the back,—and, if so, the case illustrates the power of accommodation possessed by the nervous system. He regards the case in its origin as unique, the growth probably starting in the lumbar region and extending

upwards, whereas in Ollivier's case there was a primary tumour of the cerebellum, and the spinal lesion was less extensive.

Ollivier's case[1] is as follows:

A boy, 11 years old, previously healthy with the exception of pleurisy in 1823, was attacked towards the end of 1824 with very violent headaches, which recurred paroxysmally for six months, and were associated with retraction of the head. The symptoms then became more severe, with convulsions and vomiting, and on June 1st, 1825, he was admitted into hospital. In addition to headache and retraction of the head there was amaurosis and dilated pupils. The limbs were painful, but could be moved. Next day he suffered from acute pain in all parts of the body, but especially in the back. Pupils dilated but contractile. Sensibility and mobility perfect. He answered questions addressed to him. Pulse frequent; breathing irregular. Nausea, but no vomiting. Constipation. Death took place the same day after convulsions.

As regards the spinal cord, we may quote the author's description:

"À l'ouverture du canal rachidien, les membranes parurent distendues par un peu de serosité. Après avoir enlevé la moelle épinière avec ses membranes nous trouvâmes la dure mère saine, l'arachnoïde saine, mais au dessous de celle-ci, dans toute la longueur de la moelle, à sa partie postérieure seulement existait, sous forme de demi-canal cylindrique, une couche d'un tissu accidentel formant une demi-enveloppe bornée à la partie postérieure de la moelle. Elle avait l'epaisseur d'une ligne dans la plupart des points, dans quelques autres elle était un peu plus épaisse; sa consistence était celle du tissu encéphaloïde non ramolli; elle était assez ferme, résistante et parcourrue par de petits vaisseaux. Elle présentait partout une teinte uniformément rosée. Cette couche de tissu accidentel s'amincissait sur les parties latérales de la moelle et semblait se confondre avec l'arachnoïde. Le tissu de la moelle paraissait généralement moins consistant que dans l'état normal, surtout à la fin de la region dorsale." M. Ollivier remarks on the rarity of the case and the almost total absence of spinal symptoms, but suggests that the pains in the limbs may be explained by the presence of the growth on the posterior surface of the cord.

[1] 'Traité des Maladies de la Moelle Épinière,' 3ième ed., 1837, obs. cxxxviii, T. 2, p. 490.

Remarks.—These cases of diffuse spinal sarcoma, rare though they be, present features both of pathological and clinical importance. They would seem to form a group apart from other kinds of growth in the spinal membranes. Limiting our view to the three cases in which it may be presumed that the growth was primary in the spinal pia mater—for Ollivier's case, although resembling the rest, so far as the character of the spinal growth goes, was yet obviously an extension of disease from a primary growth in the cerebellum—we may summarise their special features as follows:

1. The extreme diffusion of the new growth. In each case it involved the spinal pia mater in its whole extent, and in two transgressed this limit, reaching to the base of the brain.

2. In harmony with its continuous and diffuse growth is the type of tissue of which it is composed. In our two cases this was of the simplest kind—in Schultz's case it is termed "alveolar sarcoma;" but at any rate the type is that which closely approximates to inflammatory tissue, from which, however, it is sharply distinguished by the absence either of further development into organised tissue or of retrogressive changes. The type of tissue is retained in the old as well as in the recent parts.

3. The limitation of the growth to the spinal pia mater, as exemplified in one case (Schultz's), and in the other two cases its extension from what may be fairly assumed to be its starting-point. In the one this extension was to the cerebellum; in the other, to the pons and medulla, in direct continuity of the growth from below. This case is also of interest as illustrating the infective character of the growth. It will have been noticed that, in addition to the main mass of the tumour (in Case 1), which was strictly subarachnoid, there occurred at the base of the skull and at the upper extremity of the vertebral canal, scattered growths upon the parietal arachnoid. There can, we think, be little question that these outgrowths were produced by infection through contact of the arachnoidal layers, in a manner similar to the infection of the parietal pleura in cases of cancer of the lung, which has reached the serous surface. The presence of these secondary nodules is additional evidence of the malignant character of the new formation. Again, this form of tumour-growth differs from others in the same region, in the remarkably uniform diffusion along the whole tract of the membrane. Isolated tumours of the spinal pia

mater are well known, and occasionally primary tumours of this membrane are multiple.

Secondary sarcomatous tumours, widely disseminated, have been recorded by Lancereaux[1] and by Dr. Hughes Bennett.[2] In the former the primary growth was cerebral (pia mater), in the latter it was in the medulla oblongata. In Lancereaux's case, which was one of spindle-celled sarcoma, the cauda equina was the seat of nodular formations, as in our first case; in Dr. Bennett's, the spinal nerve-roots were in parts similarly invested by the sarcoma (round-celled) tissue, and clinically the case simulated tabes dorsalis. Why in some cases the tumour formation should be diffused and in others circumscribed we are unable to say, but it is the character of a diffuse infiltrating growth which is common to the cases we have in view, that separates them from the usual type of neoplasm, and approximates them to the type of inflammatory exudation.

4. Lastly, we may be permitted, without exceeding the limits of this Society, briefly to indicate the leading clinical features of interest exhibited by these cases.

α. The subject of each case was young, and in otherwise good health. Sarcoma is, of all forms of malignant tumour, the most prone to appear in youth.

β. There was well-marked evidence of traumatism in our second case, and as an etiological factor in his case, Schultz mentions that an uncle died of gliomatous hypertrophy of the pons.

γ. In all the duration of symptoms was remarkably brief. It is evident that the disease is one which makes insidious progress, and that symptoms are not developed until it is fairly advanced. The growth rather displaces the nerve-elements than destroys them, and their functional integrity is preserved until interfered with by the pressure of the accumulating cell-masses.

δ. The deficiency in or absence of the knee-jerks and other reflexes, is of interest in connection with the involvement of nerve-roots, to which also may be attributed the pain and disordered sensibility.

ε. In no case was there convulsions.

η. In all constipation was a prominent symptom.

[1] 'Atlas d'Anatomie Path.,' obs. cclxxi, pl. 45; also 'Traité d'Anat. Path.,' ii, p. 449.

[2] 'Clin. Soc. Trans.,' vol. xviii, p. 168.

θ. It is noteworthy that in two cases in which the brain was involved there were undoubted changes in the fundus oculi.

κ. The strabismus present in our first case was explained by the involvement of the sixth pair in the new growth at the base of the brain, and we infer likewise that the paretic affection of the limbs was due to the compression of the spinal nerve-roots. It may be noted that in Schultz's case, where the limbs became absolutely paralysed, the cord was found to be softened.

λ. In each case death was induced by interference with respiration—aided, we fear, in our case by morphine poisoning.

May 3rd, 1887.

P.S.—June, 1887.—At the meeting at which this paper was read Dr. Ormerod remarked that a somewhat similar case had been recorded by Dr. Long Fox ('Bristol Medico-Chirurgical Journal,' vol. i, 1883, p. 104), and an abstract of this case may be usefully appended to the foregoing.

The subject was a male, aged 29, of previous good health, who three months before coming under observation began to suffer from shooting pains in the arms, especially at night. The fingers, first of right, then of left hand, gradually became flexed, and later there was numbness and pricking sensation in the feet, commencing on right side; the numbness extending gradually upwards. When admitted he had girdle-pain, difficulty in micturition, frequent priapism. There was no pain in the back. The special senses, with the exception of sight, were good. Anæsthesia in the legs, thighs, abdomen, and chest to the level of the third rib. Plantar reflexes normal. No voluntary power in the lower extremities; can move arms, but not use the fingers. He survived two months, with gradually increasing motor and sensor paralysis. At the necropsy the spinal pia mater in the cervical region was found to be the seat of a spindle-celled sarcoma one and a half inches long by three quarters of an inch in diameter on the left posterior aspect of the cord, which was much softened around it. The cord was enlarged on all sides in its whole length by a belt of yellowish-grey substance; least opposite the tumour, and separable from the cord. The pia mater over the pons and medulla was much thickened, and studded with masses of exudation, extending along the vessels as far as the Sylvian fissure.

Dr. Long Fox records this case as one of leptomeningitis, com-

plicating a tumour of the membrane; and we are inclined to adopt this view, for the case differs from ours in (1) the existence of a circumscribed tumour; and (2) in the absence of evidence that the diffuse infiltration investing the cord was of sarcomatous nature.

We are further indebted to Dr. Payne for reference to a case recorded in the 'Pathological Transactions' (vol. xx, p. 319) by Mr. W. Adams and Dr. Lockhart Clarke. The case was one of "atrophic scirrhus" of the breast, which terminated in "paraplegia dolorosa." There was no disease of the vertebræ, but the dura mater presented patches of lymph on its surface; and the nerves of the cauda equina were glued together by greyish translucent lymph. Dr. Clarke's report, which is illustrated by several figures, states that there was softening of the cord in the lower cervical region, but that elsewhere the arachnoid and pia mater were greatly thickened and inseparably adherent, the thickening increasing vastly in amount in the lower dorsal and lumbar regions, the nerve-roots being embedded in this hypertrophied tissue, which is described as abounding in round or oval nuclei, and as penetrating into the substance of the nerve-bundles.

This case is a very remarkable one, and may either be regarded as one of diffused new growth of the pia mater, probably secondary to the growth in the breast, although, according to Mr. De Morgan's report (on behalf of the Morbid Growths Committee), this consisted of a dense fibroid material, in which no cells could be detected; or else as an independent chronic leptomeningitis, analogous to, but far more extensive than, the case recorded recently by Dr. Hadden ('Pathological Transactions,' xxxvi, p. 13).

The occurrence of such cases points to the liability of morbid processes to involve the whole extent of the spinal pia mater, owing, doubtless, to its special anatomical relations; and it also demonstrates the difficulty of deciding between inflammation and new growth when the latter is so situated as to become widely diffused instead of maintaining its more usual circumscribed character.

11. *Fatal cerebral hæmorrhage in a boy, aged five years, following thrombosis of the venous sinuses of the dura mater.*

By H. Handford, M.D.

The patient's illness began a week before his admission, under my care, into the Nottingham General Hospital, on March 1st, 1887, with headache, constipation, and frequent vomiting. There was no definite history of previous illness.

On admission he was found to be well nourished, but had a coated tongue and flushed face, and a general appearance of serious illness. The temperature never passed 99° F.; his respiration was slightly quickened; pulse full, 80 per minute usually, but varied from that to as slow as 50. The urine contained a marked amount of albumin. The pupils were equal, and there was no paralysis of any kind, but some slight photophobia. The patient lay curled up with his head buried in the pillow, was very irritable, and cried whenever he was touched. He complained greatly of pain in the head, frequently exclaiming, "Oh, my head!" He was very drowsy. Tubercular meningitis was suspected. At 3 a.m. on March 3rd his breathing was noticed to be stertorous, and at 6 a.m. he died, forty-two hours after admission, and ten days from the beginning of his illness.

At the inspection, thirty-four hours after death, the head was opened first. No bruising or sign of injury to the scalp or cranium was found. The membranes at the base of the brain were clear, and there was no appearance of leptomeningitis, tubercular or other. There was slight excess of subarachnoid fluid. The large venous sinuses of the dura mater were all thrombosed; the superior longitudinal and both lateral sinuses contained decolourised and partially adherent clots.

The vessels of the pia mater, on the surface of the hemispheres, were much congested, and the large superficial cerebral veins opening into the sinuses were distended with firm thrombi, many of them decolourised. On passing the finger over them many of the veins felt quite hard, like whipcord. The upper part of the left ascending parietal convolution was covered by a hæmorrhage, which at first sight appeared to be superficial. A large throm-

bosed vein passed over the patch. On further examination the hæmorrhage was found to extend to a depth of one inch or more, and was most extensive at the deeper parts, showing that its origin had not been on the surface but in the substance of the brain, or in the membranes at the bottom of the sulci. The ruptured vessel could not be found after very prolonged and careful search, macroscopic and microscopic. There were no miliary aneurysms. There appeared to have been several foci from which bleeding had taken place, and not only one.

On the right side a large hæmorrhage had ploughed up the posterior part of the temporo-sphenoidal lobe. It extended to the depth of an inch and a half, but did not open into the lateral ventricle. The bottom of the cavity was occupied by diffluent brain-substance. The inferior temporo-sphenoidal convulution had wholly escaped injury, and the superior was not destroyed in quite the whole of its thickness, but the posterior half of the middle convolution was entirely destroyed.

The search for the origin of the hæmorrhage was here equally thorough but equally negative in its results.

There were several smaller hæmorrhages scattered over the surface of both hemispheres.

Of the other viscera I need say little. There was no valvular or other lesion of the heart. Many of the larger pulmonary veins were blocked with firm thrombi, which could be pressed out as round, black cylinders. There was no tubercle. The other organs were normal. No affection of the ears could be found.

As I have stated, the diagnosis during life was meningitis, probably tubercular. The thrombosis of the venous sinuses was not suspected, as nothing was discovered pointing in that direction, neither was there any cause for the thrombosis found after death. There had been no discharge from the ears, and the boy, though drowsy, was not noticeably deaf, and no disease of the ears was detected after death. There was an obscure history of sore-throat three weeks previously, but it was too indefinite to warrant the supposition of scarlet fever. Enteric fever was suggested, but there was no lesion of the intestine at the inspection.

I am inclined to think that at the time of the boy's admission, forty-two hours before death, the venous sinuses were thrombosed, but that no extensive hæmorrhage had then taken place. The chief hæmorrhages I suppose to have taken place during the night,

shortly before he was found to be breathing stertorously, that is, three or four hours before death.

Lastly, as to the immediate cause of the hæmorrhage. Though several hours were spent in washing away the damaged brain-substance, and examining the vessels with the naked eye and under the microscope no source of the hæmorrhage could be found.

The fact that there were numerous hæmorrhages on the surface of both hemispheres, and that in the two main effusions there were several foci of bleeding, and that all these vessels ruptured about the same time, point to the cause being the increased vascular tension from the previously obstructed venous sinuses, and not any disease of the vessels that gave way. The hæmorrhage was too extensive to be due to capillary rupture, but must have been caused by the giving way of vessels of moderate size. Whether these were arteries or veins must, I think, remain an open question. I am inclined to think the latter, for "the cerebral veins are remarkable for the extreme thinness of their coats." The obstruction was on the venous side of the circulation, but it is doubtful if the venous blood-pressure could be raised sufficiently to cause the extensive ploughing up of brain-tissue that was found in this case.

May 17*th*, 1887.

---

12. *Tubercular tumour of brain.*

By Gilbert Barling, M.B.

This specimen was removed *post mortem* from the brain of a boy aged 12, who was under the care of the late Dr Russell in the General Hospital, Birmingham, in 1859, since when the tumour has been preserved in dilute spirit.

The patient came under treatment for ascites and general anasarca, the urine being albuminous and containing casts. Three weeks after admission he had two fits of an epileptic character, followed by mental dulness. A fortnight later, there was a constant succession of "epileptiform fits," some severe, others slighter, and consisting of convulsive movements of right side, without insensibility, but followed by sleep.

After continuing for five days the fits ceased, when partial paralysis was noted in the right arm with some jerking movements. The right leg and right side of face were also partially paralysed. The paralysis increased, as did the jerking movements, and the evacuations were generally passed involuntarily. Five weeks later the patient died, only one fit having occurred, and it was noted that he had recovered some power in his right leg.

Post-mortem.—An irregular caseous mass lay at the upper part of the left cerebral hemisphere, "at the junction of the anterior and middle lobes," the upper surface appearing beneath the pia mater. It separated easily from the surrounding brain-tissue, which was not softened, and proved to be about the size of a large walnut.

A similar smaller mass lay in the lower part of the middle lobe, appearing on the under surface of the brain, which was softened around it.

The only other lesion noted in the *post-mortem* record is adhesion between the layers of the pericardium.

The tumour was stained with fuchsin and methylene blue by Ehrlich's method. In its greater part it was caseous, but some remnant of the cortical layers of the brain were found on the surface. Tubercle bacilli were generally found in all parts of the tumour, usually single, and without any definite relationship to the cells. *February 1st*, 1887.

---

13. *Round-celled sarcoma of the spinal cord and brain.* (*Card specimen.*)

By W. P. Herringham, M.B., and D'Arcy Power, M.B.

The specimen was removed from the body of a woman aged 29. The leading symptoms in the case may be briefly summarised as follows:

January, 1886.—Numbness and anæsthesia of the legs, followed by pain in the back of the legs, afterwards reaching to hips and loins.

February.—Paraplegia with paralysis of the sphincters.

June 24th.—Slight optic neuritis.

July 30th.—Pain in head.

August 7th.—Delirium.

13th.—Death.

The growth occupies, in the spinal cord, the cauda equina and lumbar swelling, slightly eroding the bodies of the vertebræ, and spreading down the nerves.

In the brain there are growths in the corpus callosum, third ventricle, anterior horn of the lateral ventricle, and optic chiasma.

There are also many small nodules in the cerebellum, and in each internal auditory meatus. *December 6th*, 1886.

14. *An adenoid sarcoma with cartilage originating in the pineal gland.*

By Joseph Coats, M.D., Glasgow.

The tumour which I present for your observation occurred in a patient in the Western Infirmary, under the care of Dr. McVail, who has kindly furnished me with the following notes of the clinical facts.

The leading facts in the clinical history of James M—, aged 13, as observed in the Western Infirmary, are as follows:

He was admitted in a drowsy condition on September 30th, and died on October 13th, 1886. He walked some little distance to the infirmary—with help from the woman who brought him. With an effort he could rouse himself to speak for a minute or two, or to take a drink of milk, but almost at once again fell into a sleepy condition. Occasionally he would spontaneously so far awake as to languidly half open his eyes and look for a little about the ward. From the woman who brought him, and who had known him only for about a week, and from himself, it was ascertained that he had been becoming somewhat sleepy for about five months, although he had been doing some work at a kiln within a week or two of admission. So far as they knew, there had been no fits, but during the week he lodged with her he had wakened in the night scream-

ing with fright, and had to be brought into her room to be reassured. Both parents were dead, but no information regarding the causes could be obtained.

From the time of his admission until his death, the only food he could be got to take—and that unwillingly—was a little milk, and if disturbed in any way after drinking it he vomited, and occasionally he vomited even when not disturbed.

The face and surface generally were a good deal flushed, full, and puffy, and the finger-nail stroked anywhere on the surface brought out long-continuing broad, red, pulsating lines. Doubtful if there was a little weakness of right internal rectus, and a slight droop of left eyelid. Mouth seemed slightly drawn to left, and a very little lessening of right oro-nasal groove. Tongue not apparently affected, but he would protrude it only a very little way. Limbs of both sides alike as regards power. When roused and taken out of bed and put on the floor five days after admission, he could only walk if supported on both sides, and then only stiffly and inco-ordinately. Began to wet bed five days after admission. On second and fourth days after admission he had an epileptic fit.

Temperature only twice rose as high as 99·8° F. Pulse 58°. No evidence of cardiac, pulmonary or renal complications.

Gradually the drowsy condition deepened, until he sank into coma, and died on October 13th.

Sectio cadaveris.—The brain presented nothing worthy of note externally, but on separating the hemispheres it was seen that the corpus callosum was raised and impinged on by a massive tumour growing from beneath. The ventricles were distended.

The following note was made of the appearance of the tumour:—The tumour is a bulky mass consisting of two portions, each of generally rounded form, and adherent to or incorporated with each other. The one is right and the other left, but the right one is nearer the middle line than the left. The right mass measures $1\frac{7}{8}$ in. from before backwards, $1\frac{3}{8}$ in. transversely, and $1\frac{1}{4}$ in. in thickness, while the left is $1\frac{3}{8}$ in. by $1\frac{1}{4}$ in. by $1\frac{1}{4}$ in.; the combined tumour having thus a total transverse measurement of three inches. The tumour is irregularly lobulated and somewhat soft to the touch. The corpus callosum and fornix adherent to the tumour are considerably softened and destroyed. The choroid plexus and velum interpositum are stretched over it. The relations of the tumour have been made out partly by the removal of

brain-substance and partly by a section made in the middle line through the brain and tumour. This latter section is shown in a partially diagramatic form in Woodcut 4. By these methods it is shown that, for the most part, the tumour is surrounded by a loose connective-tissue capsule, and can be easily enucleated. In fact, after the longitudinal section, the portion of the right mass left with the right half of the brain dropped out of itself from its bed. The tumour is, however, attached deeply in the transverse fissure, its attachment corresponding in general with the middle line at a point exactly corresponding with the normal position of the pineal gland (*b*, in Woodcut 4). In the neighbourhood of this place of

WOODCUT 4.

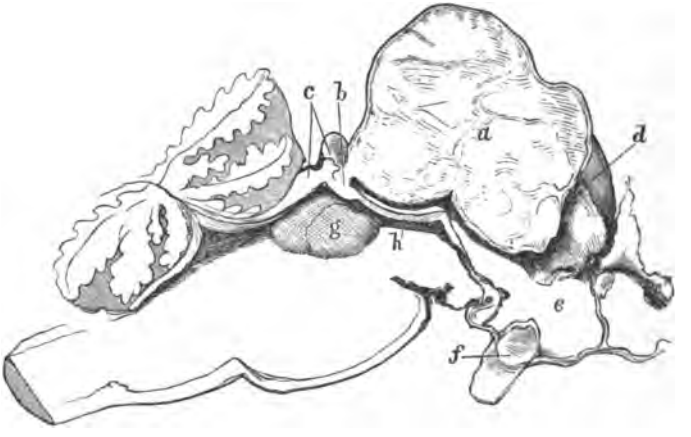

Longitudinal section of tumour of the pineal gland and parts adjoining:—*a*. Tumour. *b*. Attachment in position of pineal gland. *c*. Corpora quadrigemina pushed backwards. *d*. Thalamus opticus, pushed forwards and outwards. *e*. Third ventricle. *f*. Optic nerve. *g*. Portion of tumour in aqueduct of Sylvius and fourth ventricle.

attachment the tumour is distinctly redder in colour, and microscopic examination shows it to be more vascular. Having its attachment here, the tumour has grown into the third ventricle chiefly, but a portion has grown backwards on the left side into the aqueduct of Sylvius and anterior part of the fourth ventricle (*g*, in Woodcut 4). While adherent only at this one place, the tumour by its growth has caused considerable dislocation and distortion, as well as probably atrophy, the parts so altered being those which

are normally in anatomical relation to the pineal gland. The peduncles are separated, and distorted on both sides; but the principal pressure and displacement concern the thalami optici and the corpora quadrigemina. Growing forwards and upwards the tumour has pushed both thalami outwards and forwards, and these ganglia are flattened against the tumour so as to provide a concave bed for it. They appear also to be greatly atrophied. The corpora quadrigemina are in contact with the posterior and upper aspect of the tumour, and they are pushed backwards and greatly flattened (*c*, in Woodcut 4).

The microscopic structure is exceedingly remarkable. I have placed under the microscope sections stained with alum-carmine, so as to illustrate the principal points. It is seen at once that the tissue is very cellular, and the nuclei are mostly elongated, so that in its general characters the tissue is that of the spindle-celled sarcoma. But in the midst of this there are frequent glandular or epithelial structures. They consist of canals or spaces lined with well-formed nucleated epithelium, generally more or less columnar in shape. These canals sometimes branch, but there are no proper terminal acini visible. The enclosed spaces are sometimes dilated, so as to give a considerable calibre to the canals, and the contents in this case are usually clear and colourless; epithelial cells are sometimes vaguely visible in these spaces, but the nuclei are not stained. These cells have in a few cases an arrangement which suggests the laminated capsules of epitheliomas. In some places the proper epithelial lining of the dilated canals showed the character of goblet-cells. The dilatation in all cases is moderate in extent, and there are no proper cysts visible to the naked eye. Sometimes the epithelium is not quite regularly glandular in its arrangement, being more in irregular masses, which might stand for cancer masses, but are probably an earlier stage in the gland formation. Even when distinctly glandular, the epithelium is sometimes in several layers. These latter appearances, however, are exceptional, and are not sufficient to give character to the tissue.

Another very striking feature is the presence of small pieces of cartilage. These are much less frequent than the glandular structures, but several are to be found in every section, and they are occasionally somewhat close together. The cartilage is hyaline in character, and the cells are unusually abundant in it. The matrix has generally a slightly yellow colour, and the cells have the regular

capsule of ordinary cartilage, there being frequently two or more cells in one capsule.

Looking more closely at the general spindle-celled stroma, there are two facts that come out. In the first place, the elongated nuclei already mentioned frequently suggest those of smooth muscle, being rod shaped rather than spindle shaped; they run also in parallel bundles, and it is noticed that the bundles have frequently the appearance of being inserted into the pieces of cartilage; they also, in some cases, surround the glandular structures. In addition to the rod-shaped nuclei there are distinctly spindle-shaped ones, and also some round. The second fact is that the spindle-cell tissue is frequently opened out, so that the cells are separated by a transparent, slightly granular material; but whether this represents an œdema of the tissue or a mucous degeneration I cannot say.

The blood-vessels are not specially abundant, except near the attachment of the tumour, and they have no special characters.

There are very few calcareous masses (brain-sand) in the tumour, but I found several particles in sections made near the deep attachment.

In its general appearance a section of this tumour is very suggestive of the ordinary adenoid sarcoma of the mamma, the spindle-cells and the glandular structures being in both the prominent features. We have, however, in this case, the addition of cartilage and perhaps of smooth muscle. Perhaps, in view of the more important constituents, the tumour may be called an adenoid chondroid sarcoma.

There can be no reasonable doubt that this tumour has originated in the pineal gland. The only place of attachment and the undoubted place of origin corresponds precisely with the position of this gland, and the tumour in its growth has pushed upwards the velum interpositum, outwards the thalami optici, backwards the quadrigemina, and downwards the upper surface of the pons, the parts which are most directly in relation to that body. There is the additional fact that the tumour contained brain-sand, which is constantly present in the pineal body, and this was found alongside its other constituents.

Tumours of the pineal gland are very uncommon. Most of the text-books refer to enlargements of the gland containing the

characteristic calcareous particles or brain sand, under the name of psammoma, and mention also cysts as taking origin in the pineal body. Tumours such as the one described have, however, been recorded; and I am able to refer to four cases, which I believe belong to the same class.

There is first a case by Weigert, published in 1875,[1] which he designates a teratoma of the pineal gland. This was a somewhat bulky tumour, measuring one and three eighth inches from before backwards, and one and one eighth inches vertically. The posterior part projected into the aqueduct of Sylvius and the fourth ventricle, distending these into a considerably cavity, The corpora quadrigemina were pushed upwards and backwards. The anterior part of the tumour separated the thalami optici from each other, flattening them outwards. The tumour itself was covered by a distinct capsule. On section it presented numerous cysts, and was found on microscopic examination to have a very complex structure, containing "epidermoid structures, hairs, hair-follicles, sebaceous glands, cartilage, fat, smooth muscular-fibres, cylindrical epithelium, and perhaps nerves." Weigert claims this as a tumour of the pineal gland on the grounds that in a part of the tumour there were the cell-nests and sand grains of the pineal gland, and that it lay not on the corpora quadrigemina, but beneath and in front of it.

A case which more nearly resembles the present one was recorded by Falkson in 1879,[2] under the designation "a chondro-cysto-sarcoma in the third ventricle." In almost all respects it closely agrees with the tumour shown, except that the glandular structures had in some places expanded into cysts. It was a tumour measuring two and a quarter by one and three quarters by one and a quarter inches. It had a markedly lobulated appearance. It distended the third ventricle, pressing aside the thalami optici, and pushing backwards the corpora quadrigemina. Under the microscope the chief constituents were spindle-shaped sarcoma cells, but there were small isolated pieces of cartilage, and cysts, more or less developed, and lined with epithelium, usually of flattened cylindrical shape. The cysts were usually small, but one had a diameter of nearly an inch (20—25 mm.) The illustrations given with the paper of the microscopic structure of this tumour

[1] 'Virchow's Archiv,' vol. 65, p. 212, 1875.

[2] Ibid., vol. 75, p. 550, 1879.

might with very little alteration stand for mine, except that a part of the wall of a large cyst is shown. The author of this paper recognises that the tumour took origin in the region of the pineal gland, but is doubtful whether it has sprung from the choroid plexus alone, or whether it has taken origin partly from the pineal gland as well.

Ziegler, in his well-known Lehrbuch,[1] has figured and described a tumour which obviously belongs to this group, but strangely enough he does not refer it to the pineal gland, and in another page refers Weigert's teratoma by mistake to the pituitary body. The figure representing a frontal section of the brain is described as showing a papillary carcinoma of the choroid plexus of the third ventricle. There is no systematic description of the case, but the whole account of the carcinomata of the ventricles is obviously based on the observation of the tumour figured. It is a tumour distending the third ventricle, and pressing to one side the left thalamus. It contains spaces lined with cylindrical epithelium, which frequently dilate into cysts. The solid tissue, to judge from the very diagrammatic representation of the microscopic appearances, is sarcomatous. This tumour, distending the third ventricle, and consisting of sarcomatous tissue with cylindrical epithelium and cysts, obviously belongs to the same class as ours. From the description of it given by Ziegler, I would hesitate to call it a carcinoma.

The last case is one contributed by Dr. Charlewood Turner to this Society in the year 1885.[2] It is again a lobulated tumour, projecting into the third ventricle, but also into the left lateral ventricle. It compressed the left thalamus, and to a less degree the corpora quadrigemina. The bulk of the tissue here consists of spindle-cells, and there is in addition glandular tissue sometimes with cylindrical epithelium. There are also columns of cells which Dr. Turner describes as cancerous; and he also describes and figures cells as ganglionic nerve-cells.

The embryonic structure and homologies of the pineal gland may perhaps account for the occurrence of tumours having such a

[1] Ziegler, 'Lehrbuch der Path. Anatomie,' fourth edition, vol. ii, p. 613, Macalister's translation, part 3, p. 319.

[2] 'Transactions of the Pathological Society of London,' vol. xxxvi, p. 27.

structure as those four which I have given in abstract, and of that which forms the subject of this communication.

In regard to the embryological relations I find that the pineal gland is described as taking origin in a hollow outgrowth of the roof of the thalamencephalon. According to the observations of Mihalkovics,[1] which were made on fowls and rabbits, the gland at an early period forms saccules or follicles filled with fluid and lined with cylindrical cells. In fowls the pineal gland retains in the adult animal much of the same structure, namely, saccules whose lumen is filled with coagulated albumen and lined with small cylindrical cells.

In mammalia the same structure exists in the embryo, but the follicles are considerably smaller, and therefore more difficult to distinguish. The structure changes quickly, however, in mammals. The cylindrical cells disappear, and the follicles are converted into collections of round cells, resembling lymph follicles. Mihalkovics concludes that the pineal gland is, according to its development, an epithelial structure, developing from the surface of the mesencephalon, very much as the pituitary body developes from the epithelium of the mouth.

In the late Prof. Balfour's work on 'Embryology,'[2] mention is made of the view of Götte, according to which the pineal gland is a product of the point where the roof of the brain remains latest attached to the external skin. This view is not favorably entertained by Balfour, and I see that it is regarded by Baldwin Spencer as a mistake which has since been corrected. Balfour, however, remarks, as to the structure of the pineal body, that "it appears to possess in all forms an epithelial structure, but, except at the base of the stalk (infrapineal process) in mammalia, in the wall of which there are nerve-fibres, no nervous structures are present in it in the adult state."

The more recent researches in regard to the "pineal eye," which are fully given in Baldwin Spencer's paper in the 'Quarterly Journal of Microscopical Science' for October, 1886, may possibly throw still further light on the peculiarly complex character of this class of tumours. The pineal gland is obviously an aborted or rudimentary organ, and the observations referred to seem to prove that it is related to a median eye, which in the reptilia still shows

[1] 'Mihalkovics, 'Centralblatt f. d. med. Wissensch.,' 1874, p. 241.

[2] Balfour, 'A Treatise on Comparative Embryology,' 1881, vol. ii, p. 356.

sufficient structure to be recognisable. The eye is of the invertebrate type, having the rods and cones in front of the expansion of the nerve instead of behind it as in the vertebrata. It seems to be undecided whether the pineal gland in man and higher animals represents the eye with its stalk, or whether it represents the stalk or nerve alone. If it represents both, then we may perhaps understand in some measure how tumours originating here should have such a complex structure. *April 5th*, 1887.

---

15. *Myxofibroma of the fifth dorsal nerve (left side) extending to the spinal canal, producing compression of the cord. (Card specimen.)*

By Frederick W. Mott, M.D.

George L—, aged 37. The patient, a healthy man, following a healthy occupation, suffered for four years with pain in the sixth intercostal space of the left side, without any other symptoms. Then gradually symptoms of slow compression of the cord came on, as evidenced by numbness in the feet, followed by muscular weakness in the lower extremities, eventually ending in complete paraplegia, and death from bedsores and asthenia.

On making an autopsy, a cystic tumour about the size of a filbert was found lying beneath the arachnoid on the posterior and left side of the cord. This cyst was found continuous with the posterior root of the fifth dorsal nerve of the left side, which was swollen up to three times its natural size, and of a soft gelatinous consistence.

Microscopical examination showed the infiltration of the nerve to be of a myxo-fibromatous character. The cyst on the cord was filled with a grumous fluid, probably having been formed by rupture of one of the numerous blood-vessels in the growth. The cord was in no way affected by infiltration, but completely disorganised at the seat of compression. No secondary deposits were found in any of the organs. *February 15th*, 1887.

16. *Case of infantile paralysis, the original attack occurring fifty-eight years before death.*

By Seymour J. Sharkey, M.B.

[With Plate III.]

The case I am about to relate presents nothing that is novel, or particularly worthy of being presented for discussion to the Society. I offered it to the Secretary as a card specimen, but deferred to his suggestion that I should bring it forward in the ordinary way. It is interesting only as a fairly complete specimen, pathologically considered, of the final stage of infantile paralysis. As will be presently seen, it is very deficient from the clinical point of view, for I have not been able to obtain accurate details of the condition of affairs during life, or of the patient's original illness. He came into St. Thomas's Hospital under the care of Dr. Harley, on September 11th, 1886, prostrated with a fatal intrathoracic disease, and he died on October 14th, 1886. Curiously enough, the condition of the legs was only observed at the *post-mortem* examination. This is probably accounted for by the fact that the man was too ill to attempt to walk when he was admitted, and he let drop no remark which called attention to his very defective powers of locomotion, although this incapacity was of many years' standing.

On asking the steward of the hospital for the address of his friends I found he had none and that he had been buried by the parish. I went to the house where he lodged and questioned the landlady, from whom I got some scanty information, which proved to be incorrect. Finally, this morning I received a letter from his sister, saying that the old man, E. P—, aged 60, was a strong, healthy child until he reached two years of age, when he was suddenly taken ill with what was called "rheumatic fever." On recovery he was quite paralysed in the lower extremities. For this affection he was under constant medical care during childhood, but without any noteworthy result. From the age of fourteen to twenty-one he gradually regained power in the left leg and in the upper part of the right. He was a writer at the time of his death, and used to live just opposite St. Thomas's Hospital, from

which place he managed to walk daily to his work at Whitehall. During the last two years of his life he had done this with great difficulty. He died one month after his admission into St. Thomas's Hospital. It is unnecessary to go into the details of his last illness as they have no bearing on the pathological specimens which are shown here.

Post-mortem examination showed that the old man had died of an epitheliomatous ulcer of the œsophagus, which had invaded and entirely blocked the left bronchus, and given rise to empyema of the corresponding side of the chest. The panniculus adiposus was unusually thick, and large accumulations of fat were found in the omentum and around the viscera.

The legs were unequal in size, the right being somewhat the smaller, and flexed at the knee; the left was plumper, but not of abnormal dimensions. On dissection all the muscles of both legs were represented by masses of fat, showing numerous pinkish streaks running longitudinally through them.

The spinal cord was very small in the lumbar region, and the position of the lumbar enlargement was scarcely indicated, being little, if at all, larger than the upper lumbar region. To the naked eye the anterior cornua appeared to be greatly reduced in size, but symmetrical in shape.

Microscopical examination.—1. Lumbar enlargement of spinal cord: This portion of the spinal cord was, as has already been stated, very small. The microscope showed innumerable corpora amylacea, which were far more numerous in the grey than in the white matter; they reached their maximum number in the anterior grey cornua. The latter were small, and contained only here and there representatives of the large stellate nerve-cells which abound in health. Those which still remained were small, pigmented, and granular. A great many nuclei were scattered thickly over the field, and the groundwork of the anterior cornua was of a fine fibrillar texture.

The vessels presented a hyaline condition of their walls, and the perivascular spaces were abnormally large.

As regards the white substance, the sections of nerve-tubes abounded, but great numbers were reduced to very small dimensions, and appeared on section almost like nuclei. All the white columns were shrunken, but the antero-lateral strands seemed to have undergone greater diminution than the others.

Fig. 1.

Fig. 2.



Fig. 3.



Hage del. Mintern Bros. sc.

DESCRIPTION OF PLATE III.

To illustrate Dr. Sharkey's case of Infantile Paralysis. (Page 53.)

From drawings by M. H. Lapidge.

FIG. 1.—Muscle in earlier stage of atrophy. Some of the muscular fibres still remain separated by thick strands of connective tissue and empty sarcolemmata.

FIG. 2.—Final stage of muscular atrophy. The muscular fibres have all disappeared, leaving parallel strands of empty sarcolemmata and connective tissue.

FIG. 3.—Final stage of muscular atrophy, in which a few fibres still survive, and the connective tissue has been infiltrated with fat.

2. The nerve-trunks in the legs: In the large nerve-trunks of the lower limbs the perineurium was somewhat thickened, and the transverse section of the nerve-bundles showed many patches of deeply-stained tissue in the midst of perfectly normal nerve-tubes. These patches at first looked like connective tissue which had increased in amount; but on examination with higher powers they could be seen to be made up of transverse sections of very small, atrophied nerve-fibres. The close approximation of the small, easily-stained axis-cylinders and the disappearance of the white sheath of Schwann gave an appearance of "sclerosis" to these portions of the nerve-bundles, though what they really represented was atrophied fibres. The general network of connective tissue which pervaded the bundles was, however, coarser than in the normal state.

3. Muscles: On examining sections of the masses of fat representing the muscles a considerable number of muscular fibres were seen running through the fat. Most of them were beautifully striated and quite healthy, though they were not all as large as in the normal state (Plate III, fig. 3). Here and there a non-striated, granular fibre was seen. In most places the nuclei of the connective tissue were increased in numbers, and this was especially so where there were still muscular fibres present, and where changes may be presumed to have been going on, if anywhere.

Remarks.—This patient's sudden illness, which quickly resulted in paralysis of the lower limbs at the age of two, must, in the face of the pathological changes just described, be put down as an attack of infantile paralysis. In the spinal cord, in the nerves, and in the muscles, the most striking change is atrophy. There are but two large cells left in the anterior cornua, numbers of nerve-fibres in the nerve-trunks are reduced to very small proportions, and there are only here and there muscular fibres in the muscles. This represents the final state of things in a person attacked with the disease fifty-eight years before his death. In addition to the sections of cord, nerve, and muscle from this case I have placed under microscopes muscle in the earlier stage of the disease (Plate III, fig. 1), and muscle (fig. 2) in as advanced a condition of atrophy as that from the case which is under discussion. In the specimen from the earlier stage will be seen great increase of nuclei, especially in sarcolemma, and gradual atrophy of muscular fibre, either with or without degenerative changes.

When the process of muscular atrophy is complete the collapsed sarcolemmata lie side by side, and their long rows of nuclei meet, and often look like strings of beads. The shortening of the muscle gives rise to waves in these parallel lines. This represents the final stages of the disease where no infiltration with fat occurs, while the specimen from the case I am now bringing before the Society is one where the connective-tissue cells have received an amount of fat which has swelled them out and increased the size of the muscular masses. The patient was unusually fat for his age, notwithstanding that he died of malignant disease of the œsophagus. At what age he became stout we cannot say, nor can we tell whether his legs became larger at that time than they had been previously. The same condition of muscle occurs in pseudo-hypertrophic paralysis and in disuse, but the proof that the present case is not an instance of either of these affections is the condition of the spinal cord.

The probable sequence of events in infantile paralysis is as follows: The patient is attacked, usually suddenly, with paralysis of some of the voluntary muscles, owing to an affection of the spinal cord, which, without being confined to the anterior cornua, attains its maximum intensity in them. Generally the affection is inflammatory, and temporarily cripples or permanently destroys the large motor cells. The motor fibres passing from there to the limbs degenerate, the white sheath being broken up, and its place being taken by a substance which stains with logwood. This substance is gradually absorbed, and then an atrophied axis-cylinder enveloped in its neurilemma alone remains. It is astonishing how long such ghosts may be seen in affected nerves occupying a place among the healthy survivors. It is a question, indeed, whether they ever disappear.

At the same time that these changes are occurring in the motor cells and nerves the muscles supplied by the latter alter. The nuclei of the sarcolemma and surrounding connective tissue proliferate, the contractile substance atrophies, sometimes retaining its normal striæ, sometimes undergoing degeneration. If the nerve-cells and fibres do not recover, the muscular bundles are finally represented only by collapsed sarcolemmata lying in long parallel rows, the muscular substance itself having disappeared. In many cases this is the final stage; but in others, owing to causes little understood, fat is deposited in the connective-tissue cells, and then

we find the condition of things represented in the specimen which I have shown to-night. *January* 18*th*, 1887.

---

17. *Fatal cases of alcoholic paralysis.*

By W. B. HADDEN, M.D.

[With Plate IV, figs. 1 and 2.]

THE first patient was a married woman, aged 27, who was admitted under Dr. Ord, on February 1st, 1886, and died on February 10th.

There was a history of alcoholic excess for four years, and it was admitted that she drank whisky before breakfast. Her arms and legs began to grow weak a year before admission.

Her condition may be summed up briefly as follows: The lower limbs were wasted, and there was great loss of power, especially evident in the extensors. The limbs were bent at the knees, and any attempt to straighten them caused her to cry out with pain. Sensation was impaired. The knee-jerks were absent; the plantar reflexes apparently diminished. The muscles gave no response to strong faradic or galvanic currents. The arms also were very feeble, and the extensors of the fingers contracted readily on mechanical stimulation. The muscles everywhere were acutely tender. She occasionally rambled. There were evident signs of phthisis, and there was moderate pyrexia.

At the *post-mortem* examination several small cavities were found in the upper lobe of the left lung, and both organs were studded with miliary tubercles. The liver was large and fatty. There were tubercles on the surface and in the cortex of both kidneys. Two small tubercular ulcers were found in the cæcum. The brain and spinal cord were injected on the surface, but otherwise natural. The sciatic nerve with popliteals, the anterior crural, the rectus femoris on the right side, seemed healthy to the naked eye; as also the following on the left side, the anterior tibial, the musculo-spiral, the tibialis anticus, and the extensor carpi ulnaris.

On microscopical examination the nerves were seen to be markedly degenerated. The myelin had broken up into a finely granular

material, which quite obscured the axis cylinder. Many of the nuclei of the fibres were enlarged. The nerve tubes were irregular in shape, in some places being bulged from the local accumulation of the granular matter, in other places being much reduced in consequence of the removal of the degenerative products.

Sections of the right rectus femoris and of the left tibialis anticus displayed the following changes. The striation was preserved, although in a few places the fibres were slightly granular. The sarcolemma nuclei and the nuclei of the interstitial tissue exhibited proliferation, so that local accumulations of small round cells were seen, in some places obscuring the muscular fibres and apparently causing their atrophy.

The various regions of the spinal cord were healthy. No change was present in the medulla oblongata. The liver showed the ordinary appearances of fatty degeneration, and in addition there were scattered patches of early cirrhosis.

Under the microscope I have placed sections of the tibialis anticus, musculo-spiral nerve, and of the lumbar cord. In the last, the motor cells and anterior roots will be seen to be quite healthy.

The next patient was a married woman, aged 44, who was admitted under Dr. Ord on June 10th, 1886, and died on June 25th.

There was a distinct history of alcoholic excess. Her legs began to get weak, stiff, and painful a fortnight before admission. On examination, the signs of phthisis were very evident. Both legs were weak, and she was unable to stand. Flexion and extension at the ankle-joints were very feeble. The knee-jerks were absent, and the plantar reflexes brisk. The arms were weak, but less so than the legs. The hands were tremulous when held out, and the grasp, especially on the left side, feeble. The extensor muscles contracted readily when tapped. The elbow and wrist-jerks were said to be exaggerated. The muscles everywhere were flabby and tender. There was no loss of sensation. The muscles of the legs gave no response to the interrupted current. She slept badly, and there was some mental impairment. There was moderate fever throughout.

At the *post-mortem* examination the greater part of the upper lobe of the right lung was solid from mixed broncho-pneumonia and tubercle. There was one small, rather recent cavity at the apex. A few scattered patches of broncho-pneumonia were found in the

upper part of the lower lobe. The left lung was in a more advanced state, there being several small, inter-communicating cavities in the upper lobe, and several caseous areas scattered through the lower lobe. The liver was in a condition of early cirrhosis, and there were a few small yellow tubercles, mainly on the surface. The brain and spinal cord seemed healthy. No change was obvious in the following, on naked-eye examination: On the right side, the anterior tibial and tibialis anticus, the great sciatic and biceps, the musculo-spiral and common extensor of the fingers; on the left side, the anterior crural and rectus femoris and the posterior tibial nerve.

On microscopical examination I could discover no change in the spinal cord. The extensor communis digitorum and the tibialis anticus, showed an increase in nuclei, and in some places the nuclei were arranged in groups. The musculo-spiral and posterior tibial nerves exhibited early degenerative changes, and the endoneurium was thickened. I could not satisfy myself that there was any alteration in the biceps femoris.

The last case is that of an army officer, aged 56, who was in St. Thomas's Home from September, 1884, to March, 1885.

There was no doubt about his intemperate habits. On admission, he was delirious, calling out for the waiter and ordering brandy. He could not stand, and could only move his legs a little when lying in bed. I gather also from a memorandum supplied to me by Dr. Edmunds, that there was some impaired sensation. Later on he was found to have tenderness of the soles. He gradually improved, and when he left could stand and walk.

Eight months after he was discharged from the Home he was admitted into the Hospital under Mr. Croft. He was found to have a deeply excavated ulcer on the dorsum of the left foot, and another smaller one on the ball of the great toe. He said that he had suffered from corns for years, and that during the last four months they had become very painful, and had begun to discharge. He had noticed that his gait had lately become feeble and staggering. The reflexes of the lower extremities were absent. Sensation was much affected, in some places being absolutely lost, in others delayed. His mental condition was much impaired, and he had constant delusions and hallucinations.

At the *post-mortem* examination I found that the muscles and tendons were exposed on the floor of the ulcer on the dorsum of

which place he managed to walk daily to his work at Whitehall. During the last two years of his life he had done this with great difficulty. He died one month after his admission into St. Thomas's Hospital. It is unnecessary to go into the details of his last illness as they have no bearing on the pathological specimens which are shown here.

Post-mortem examination showed that the old man had died of an epitheliomatous ulcer of the œsophagus, which had invaded and entirely blocked the left bronchus, and given rise to empyema of the corresponding side of the chest. The panniculus adiposus was unusually thick, and large accumulations of fat were found in the omentum and around the viscera.

The legs were unequal in size, the right being somewhat the smaller, and flexed at the knee; the left was plumper, but not of abnormal dimensions. On dissection all the muscles of both legs were represented by masses of fat, showing numerous pinkish streaks running longitudinally through them.

The spinal cord was very small in the lumbar region, and the position of the lumbar enlargement was scarcely indicated, being little, if at all, larger than the upper lumbar region. To the naked eye the anterior cornua appeared to be greatly reduced in size, but symmetrical in shape.

Microscopical examination.—1. Lumbar enlargement of spinal cord: This portion of the spinal cord was, as has already been stated, very small. The microscope showed innumerable corpora amylacea, which were far more numerous in the grey than in the white matter; they reached their maximum number in the anterior grey cornua. The latter were small, and contained only here and there representatives of the large stellate nerve-cells which abound in health. Those which still remained were small, pigmented, and granular. A great many nuclei were scattered thickly over the field, and the groundwork of the anterior cornua was of a fine fibrillar texture.

The vessels presented a hyaline condition of their walls, and the perivascular spaces were abnormally large.

As regards the white substance, the sections of nerve-tubes abounded, but great numbers were reduced to very small dimensions, and appeared on section almost like nuclei. All the white columns were shrunken, but the antero-lateral strands seemed to have undergone greater diminution than the others.

Fig. 1

Fig 2.

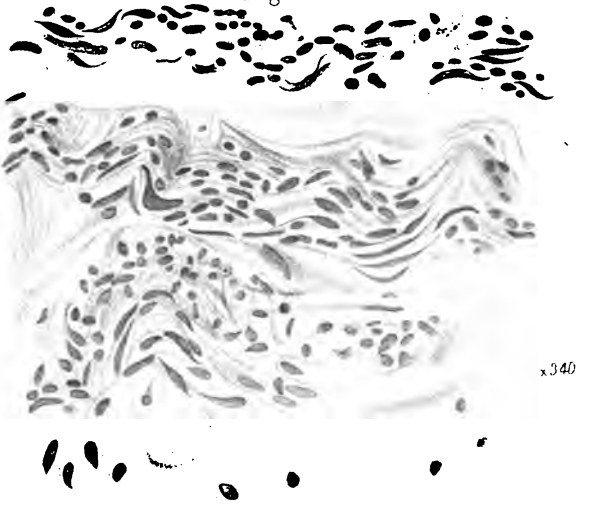

Fig 3



M H Lapuise del.

Mintern Bros sc

DESCRIPTION OF PLATE III.

To illustrate Dr. Sharkey's case of Infantile Paralysis. (Page 53.)

From drawings by M. H. Lapidge.

FIG. 1.—Muscle in earlier stage of atrophy. Some of the muscular fibres still remain separated by thick strands of connective tissue and empty sarcolemmata.

FIG. 2.—Final stage of muscular atrophy. The muscular fibres have all disappeared, leaving parallel strands of empty sarcolemmata and connective tissue.

FIG. 3.—Final stage of muscular atrophy, in which a few fibres still survive, and the connective tissue has been infiltrated with fat.

2. The nerve-trunks in the legs: In the large nerve-trunks of the lower limbs the perineurium was somewhat thickened, and the transverse section of the nerve-bundles showed many patches of deeply-stained tissue in the midst of perfectly normal nerve-tubes. These patches at first looked like connective tissue which had increased in amount; but on examination with higher powers they could be seen to be made up of transverse sections of very small, atrophied nerve-fibres. The close approximation of the small, easily-stained axis-cylinders and the disappearance of the white sheath of Schwann gave an appearance of "sclerosis" to these portions of the nerve-bundles, though what they really represented was atrophied fibres. The general network of connective tissue which pervaded the bundles was, however, coarser than in the normal state.

3. Muscles: On examining sections of the masses of fat representing the muscles a considerable number of muscular fibres were seen running through the fat. Most of them were beautifully striated and quite healthy, though they were not all as large as in the normal state (Plate III, fig. 3). Here and there a non-striated, granular fibre was seen. In most places the nuclei of the connective tissue were increased in numbers, and this was especially so where there were still muscular fibres present, and where changes may be presumed to have been going on, if anywhere.

Remarks.—This patient's sudden illness, which quickly resulted in paralysis of the lower limbs at the age of two, must, in the face of the pathological changes just described, be put down as an attack of infantile paralysis. In the spinal cord, in the nerves, and in the muscles, the most striking change is atrophy. There are but two large cells left in the anterior cornua, numbers of nerve-fibres in the nerve-trunks are reduced to very small proportions, and there are only here and there muscular fibres in the muscles. This represents the final state of things in a person attacked with the disease fifty-eight years before his death. In addition to the sections of cord, nerve, and muscle from this case I have placed under microscopes muscle in the earlier stage of the disease (Plate III, fig. 1), and muscle (fig. 2) in as advanced a condition of atrophy as that from the case which is under discussion. In the specimen from the earlier stage will be seen great increase of nuclei, especially in sarcolemma, and gradual atrophy of muscular fibre, either with or without degenerative changes.

When the process of muscular atrophy is complete the collapsed sarcolemmata lie side by side, and their long rows of nuclei meet, and often look like strings of beads. The shortening of the muscle gives rise to waves in these parallel lines. This represents the final stages of the disease where no infiltration with fat occurs, while the specimen from the case I am now bringing before the Society is one where the connective-tissue cells have received an amount of fat which has swelled them out and increased the size of the muscular masses. The patient was unusually fat for his age, notwithstanding that he died of malignant disease of the œsophagus. At what age he became stout we cannot say, nor can we tell whether his legs became larger at that time than they had been previously. The same condition of muscle occurs in pseudo-hypertrophic paralysis and in disuse, but the proof that the present case is not an instance of either of these affections is the condition of the spinal cord.

The probable sequence of events in infantile paralysis is as follows: The patient is attacked, usually suddenly, with paralysis of some of the voluntary muscles, owing to an affection of the spinal cord, which, without being confined to the anterior cornua, attains its maximum intensity in them. Generally the affection is inflammatory, and temporarily cripples or permanently destroys the large motor cells. The motor fibres passing from there to the limbs degenerate, the white sheath being broken up, and its place being taken by a substance which stains with logwood. This substance is gradually absorbed, and then an atrophied axis-cylinder enveloped in its neurilemma alone remains. It is astonishing how long such ghosts may be seen in affected nerves occupying a place among the healthy survivors. It is a question, indeed, whether they ever disappear.

At the same time that these changes are occurring in the motor cells and nerves the muscles supplied by the latter alter. The nuclei of the sarcolemma and surrounding connective tissue proliferate, the contractile substance atrophies, sometimes retaining its normal striæ, sometimes undergoing degeneration. If the nerve-cells and fibres do not recover, the muscular bundles are finally represented only by collapsed sarcolemmata lying in long parallel rows, the muscular substance itself having disappeared. In many cases this is the final stage; but in others, owing to causes little understood, fat is deposited in the connective-tissue cells, and then

we find the condition of things represented in the specimen which I have shown to-night. *January* 18*th*, 1887.

---

17. *Fatal cases of alcoholic paralysis.*

By W. B. Hadden, M.D.

[With Plate IV, figs. 1 and 2.]

The first patient was a married woman, aged 27, who was admitted under Dr. Ord, on February 1st, 1886, and died on February 10th.

There was a history of alcoholic excess for four years, and it was admitted that she drank whisky before breakfast. Her arms and legs began to grow weak a year before admission.

Her condition may be summed up briefly as follows: The lower limbs were wasted, and there was great loss of power, especially evident in the extensors. The limbs were bent at the knees, and any attempt to straighten them caused her to cry out with pain. Sensation was impaired. The knee-jerks were absent; the plantar reflexes apparently diminished. The muscles gave no response to strong faradic or galvanic currents. The arms also were very feeble, and the extensors of the fingers contracted readily on mechanical stimulation. The muscles everywhere were acutely tender. She occasionally rambled. There were evident signs of phthisis, and there was moderate pyrexia.

At the *post-mortem* examination several small cavities were found in the upper lobe of the left lung, and both organs were studded with miliary tubercles. The liver was large and fatty. There were tubercles on the surface and in the cortex of both kidneys. Two small tubercular ulcers were found in the cæcum. The brain and spinal cord were injected on the surface, but otherwise natural. The sciatic nerve with popliteals, the anterior crural, the rectus femoris on the right side, seemed healthy to the naked eye; as also the following on the left side, the anterior tibial, the musculo-spiral, the tibialis anticus, and the extensor carpi ulnaris.

On microscopical examination the nerves were seen to be markedly degenerated. The myelin had broken up into a finely granular

the case of the fingers which had been removed before the patient's admission.

The patient died on May 10th, 1886, her death occurring rather suddenly after an epileptic fit.

Autopsy, thirteen hours after death.—Cerebrum: Slight thickening of arachnoid and pia mater, which everywhere stripped very readily; vessels of pia mater moderately injected; slight excess of subarachnoid fluid. Slight wasting of gyri. Cortex apparently normal. Basal ganglia normal. Ventricles not dilated. Weight of brain, 1176 grammes. Cerebellum, pons, and medulla normal.

Spinal cord and peripheral nerves apparently normal to naked eye.

Lungs: Right, 18½ oz.; left, 16 oz., both moderately congested, with emphysematous edges.

Heart, 9 oz. Slight general hypertrophy, with considerable hypertrophy of left ventricle. Valves competent, and fairly healthy. Muscle good.

Liver, 40 oz., normal. Spleen, 4½ oz., normal.

Kidneys: Right, 2½ oz.; left, 2¾ oz. Capsules very adherent, leaving, on stripping, a decidedly granular surface; cortices presented a mottled and indefinite structure, with numerous cysts.

A word as to the supposed pathology of this affection.

Raynaud described the disease as a neurosis, characterised by an exaggeration of the excito-motor centre in the cord which presides over the vaso-motor nerves.

He divided the disease into three stages:

1. That of local syncope, indicated by whiteness of the parts.

2. That of local asphyxia, in which the affected parts become purplish, black, or slate coloured. (This, like the first stage, may pass off entirely.)

3. That of local gangrene. The local mischief is attributed to cramp-like contractions of the arterio-capillaries.

The resemblance which the case herein described presented to those cases of trophic lesions dependent upon irritative affections of the nervous centres, with which modern neurology has rendered us familiar, led to the idea that some irritative process in the spinal cord or peripheral nerves might well be the origin of the disease; and, so far as I am aware, the changes now to be described have not hitherto been recorded in a case of this affection.

Microscopical examination.—The spinal cord was hardened first in Müller's fluid, and then in spirit. Sections were taken from the cervical, dorsal, and lumbar regions, and stained with eosin and logwood.

Slight changes were found. The nerve-cells of the anterior cornua appeared practically normal, although in some of them the angular outline was not so sharp as usual. The cells of the posterior vesicular columns of Clarke were, however, decidedly rounded, in many cases approaching sphericity of outline, with ill-defined processes. As regards the white substance, there was no localised sclerosis, but the neuroglia appeared to be thickened in a very slight degree. The nerve-tubules generally appeared healthy, but there might have been slight atrophy of some of them.

Peripheral nerves.—Portions of the following nerves were selected:—Sciatic, internal popliteal, external popliteal, posterior tibial, median, and ulnar, on each side, and the right musculo-spiral; in all, therefore, thirteen different nerves were examined. They were all prepared in exactly the same way, being hardened first in Müller's fluid and subsequently in spirit, and stained with eosin and logwood. The sections were chiefly cut transversely. I may here remark that, owing to the fact of the nerves not having been stretched during hardening, the nuclei over portions of the nerve-bundles present an oval outline in the transverse section. The great majority of the nerves examined presented well-marked changes, and none of them were wholly unaffected. The changes found may be described in brief as overgrowth of the fibrous elements of the nerve with atrophy and degeneration of the nervous elements. These conditions were unequally developed in different nerves, but from their similarity in kind it will be unnecessary to describe each section in detail; one or two of the best-marked examples will be taken. Of the nerves of the lower extremities the left posterior tibial seems to be the one chiefly affected (Plate IV, fig. 1). The nerve, as a whole, is distinctly diminished in size, and the overgrowth of the fibrous framework is well shown. The epineurium is much thickened in all its parts; the perineurium is also greatly thickened, forming a series of richly nucleated concentric laminæ, which in many cases encroach considerably upon the nerve-bundles. [In the drawing the artist has not, I think, made the perineurium appear quite thick enough.] The perineurial lymph space is in many bundles distinctly broadened; the endo-

neurium shares in the general hyperplasia, and exhibits also a decided increase in the number of nuclei.

The nerve-tubules generally appear more or less atrophied and degenerated, the atrophy appearing to affect chiefly the myeline sheath.

The other nerves of this (left) extremity, external popliteal, internal popliteal, and sciatic, also present these changes well marked, but they appear to be proportionally most advanced in the posterior tibial. The corresponding nerves of the right lower extremity are affected in an exactly similar way, though in a slightly less marked degree; and here, as on the left side, the posterior tibial seems to be the most affected.

The nerve-tubules especially are unequally atrophied, portions of some of the bundles appearing fairly normal. It is to be noted also that in some of the sections some of the vessels are filled with red blood-globules, and the walls of many of the vessels are decidedly thickened, but this latter peculiarity is doubtless connected with the renal disease from which the patient suffered.

The left median nerve may be looked upon as the most diseased of the nerves of the upper extremities (fig. 2). Here again we note that the epi-, peri- and endo-neurium are all much hypertrophied, with considerable increase of nuclei. The chief characteristic of this section, however, is the great widening of the perineurial lymph-spaces caused by shrinkage of the nerve-bundles. This condition cannot be due to the method of preparation, which was exactly the same for all the nerves, as it is very unequally developed in different sections, many of the nerve-bundles scarcely showing it at all. These lymph spaces are more or less filled with a loose, spongy, sparsely nucleated connective tissue, which has taken a light blue colour with the logwood; this spongy tissue is seen in many of the bundles to be connected with thickened bands of the endoneurium. The nerve-tubules are clearly much atrophied and degenerated. This dilatation of the perineurial lymph space with loose connective tissue contents is much more marked in this nerve than in any other, but most of the other nerves present more or less evidence of it.

The right median nerve is much less affected than the left, and the condition of the ulnars approximates to that of the right median; the left ulnar appears to be slightly the more affected of the two. Of all the nerves examined the right musculo-spiral is

decidedly the least affected; the characters previously described are, however, present, although less marked; thus the epineurium is slightly though distinctly thickened, and the perineurium, if not thickened, at least shows abnormal distinctness of its nuclei; there is also slight thickening of the endoneurium with excess of nuclei, and slight atrophy of the nerve-tubules.

As far as the examination goes, therefore, it would appear that the changes described are a little more marked on the left side than the right, though the difference is in general but slight. The disease also appears to be more advanced at the distal than at the central ends of the nerves; at least this may be said of the nerves of the lower extremities, by comparing the posterior tibials with the sciatics. The sections of the median and ulnar nerves were, indeed, only taken from one place, viz. a little above the wrist-joint, and the cords of the brachial plexus were not examined; but if the condition of the musculo-spiral nerve may be taken as a guide, they would have been found to be much less affected; add to which the fact that the spinal cord presented only very slight changes. On the whole, then, I should be disposed to conclude that the disease had its starting-point at or near the periphery, and travelled upwards, but a sufficient number of sections were not made to prove this absolutely.

What is the nature of the disease? Is it to be looked upon as a chronic interstitial inflammation, which has gradually invaded the nerve-bundles and caused them to dwindle, or have we to deal with a primary degenerative atrophy of the nerve-tubules, with sequential hyperplasia of their fibrous framework? The evidence does not seem sufficient to enable one to decide. The appearances, however, presented by the left median nerve would seem to suggest a primary atrophy, for here the nerve-bundles have obviously shrunk out of proportion to the fibrous overgrowth, and the space thus left is occupied by a loose connective tissue, which may be looked upon as representing the earliest phase in the development of the concentric laminæ of the thickened perineurium. This condition might, however, be the local expression of a secondary degeneration, due to destruction of nerve-tubules by neuritis elsewhere. Whichever be the correct explanation we shall doubtless be safe in concluding that the localised symmetrical gangrene was directly dependent on the changes in progress in the nerves; and should this observation be confirmed by others it will

tend to take Raynaud's disease out of the category of neuroses by giving it a tangible material lesion to rest upon. It is possible, however, that the cases at present included under the head of Raynaud's disease may not all own exactly the same pathology, and it is conceivable that the milder forms of the affection may be dependent upon a functional derangement of those parts which in the severer forms are the seat of organic change.

January 4th, 1887.

I must express my obligations to Dr. Southey for referring me to the literature of the subject. The principal cases recorded in this country will be found in the following publications:

Southey, Dr.—'St. Bartholomew's Hospital Reports,' 1880.

" 'Transactions of the Clinical Society,' vol. xvi.

" 'Transactions of the Pathological Society,' vol. xxxiv.

Smith, Thomas, Mr.—'Transactions of the Clinical Society,' vol. xiii.

Barlow, Dr.—'Transactions of the Clinical Society,' vol. xvi.

I am indebted to Dr. Southey's first paper for my quotation of Raynaud's views.

---

19. *Peripheral neuritis.* (*Card specimen.*)

By W. Hale White, M.D.

The microscopical slides exhibited this evening show the parenchymatous form of peripheral neuritis, especially in the large nerve in which, whilst there are some healthy axis-cylinders, the majority are degenerated.

There is also some interstitial change, as is shown by the increased amount of interstitial tissue. It is a very chronic process, there being no accumulation of leucocytes or great dilatation of the vessels. The finer nerves seen in sections of the skin also show considerable degeneration. *April 5th*, 1887.

20. *Multiple neuro-fibromata in connection with molluscum fibrosum.*

By J. F. Payne, M.D.

[With Plates V and VI.]

The person from whom these specimens were taken, Grace M—, became a patient at St. Thomas's Hospital in the department for diseases of the skin, on May 13th, 1880, being then thirty-seven years old. The surface of her body was almost covered with small tumours, some projecting on the surface, some pendulous, some just under the skin. The size varied from that of a pin's head to that of a hazel nut, but only one or two were of the latter size. The majority were the size of a pea, or smaller. They were soft, mobile, and had almost the consistence of adipose tissue. In addition there was a general darkening of the skin, and a large number of pigmented spots like dark freckles, which were seen on covered as well as uncovered parts of the body. The tumours (which had precisely the characters of what is called molluscum fibrosum) were most numerous on the face, shoulders, and upper parts of the arms. Some small ones were seen on the neck and chest; there were none on the palms of the hands or soles of th feet.

No connection of the tumours with any other skin structures could be traced. They were all covered by unbroken epidermis, the only difference between this and other parts of them being that the skin over the tumours appeared to be thinner.

There was no opening in the tumours, or any apparent connection with sebaceous glands or hairs. It is true that black sebaceous plugs or comedones were present in some parts where the tumours were found, especially on the shoulders, but they were irregularly arranged, and appeared to form no necessary part of the growths.

The smallest masses showed no comedones, while on the surface of the larger there might be several, so that their distribution was quite accidental.

The tumours had lasted all the patient's life, so far as she could

remember, but were thought to be becoming gradually more numerous.

The patient was lame of the right leg, and walked with a crutch under the right arm. The lameness was due to a false joint at the hip, which was said to have existed since she was a child; but there was no active disease. She had tolerably good health, and nothing wrong was discovered with any of the bodily functions. She was short and dark; her face had the expression of pain characteristic of cripples, but she was strongly made. She was never married. Family history offered nothing remarkable.

While under treatment the patient complained of nothing else very notable, except of neuralgia.

June 3rd.—Soon after she began to attend she complained of a lump in the left axilla, and on examination one the size of a walnut was felt, which was first taken for an enlarged lymphatic gland, but on subsequent examination turned out to be a tumour attached to the brachial plexus. This tumour went on slowly increasing in size, and was very painful. It gave rise to neuralgia felt all down the arm to the fingers, but did not produce any paralysis. No other tumour was known to exist in the body.

The patient continued to attend as an out-patient for six years. During the first part of this time the skin tumours appeared to be getting more numerous; but they varied, some wasting or almost disappearing, while new ones were formed. There was no change in their character, but the skin became gradually more darkly pigmented and more generally freckled.

Of course no hope was held out to the patient that recovery was possible, or treatment of much use; nevertheless, she attended regularly, chiefly to be treated for the neuralgia, which was much alleviated by quinine and iron. A lotion of lead and opium was also used to the axillary tumour when it was very painful. About the beginning of 1886, however, the patient declared that the lumps in the skin were going away, and on inspection it was evident that they were less numerous than before. From this time on there was a marked though slow retrogression in the disease, few or no new tumours appearing, while the original ones wasted, and in some cases disappeared. I need hardly say that I do not attribute this in any way to treatment. However, the patient was convinced she was being cured.

The state of things continued nearly the same during the greater

part of 1886, the tumours being, on the whole, less prominent, and apparently less numerous than formerly, but still present and in very large numbers.

On September 7th I was told that she had died on the 5th, after two days' violent diarrhœa and sickness; there were apparently no other symptoms, and she died rather suddenly.

I made a *post-mortem* examination on September 7th at the home of the deceased under considerable difficulties.

Post-mortem examination fifty-four hours after death in warm weather.—Body well nourished. The skin much pigmented and freckled; the skin nearly covered with small pendulous fibrous tumours, amounting to some hundreds in all; the trunk was nearly covered with them, most thickly on the shoulders; they were also numerous on both upper and lower extremities, and a few on the face; there were also numerous subcutaneous tumours, agreeing with the external ones in appearance and in size; they varied generally from the size of a small shot to that of a pea, a few only being larger; the largest were seen in the upper part of the left arm, where was one as large as a hazel nut, near the insertion of the deltoid. The external tumours were collapsed and flabby.

Thorax: Each pleura contained a few ounces of serum. The lungs natural, rather pale. No hyperæmia or consolidation. Pericardium contained two or three ounces of clear serum.

Heart: Right ventricle nearly empty, containing no clots; walls thin and flabby. Left ventricle contained a little clot; walls likewise thin and flabby; valves quite natural The condition of the heart showed the mode of death to have been from syncope, not from asphyxia.

Stomach: Mucous membrane quite natural in appearance, without any inflammation or congestion. Intestines, discoloured from decomposition, were not opened.

The liver was much decomposed, but appeared natural.

Kidneys too much decomposed to be properly examined, but showed no obvious disease. Spleen extremely soft.

Head not opened.

In the left axilla was found a considerable hard tumour, closely connected with the inner part of the brachial plexus, but not with the vessels. It was removed with the nerves for further examination. There was nothing similar to it in the right brachial plexus,

which appeared natural to the naked eye. It was not possible to dissect any other nerves.

On the whole, death seemed attributable to syncope from failure of the action of a weak, thin-walled heart, consequent on severe diarrhœa. There was no suspicion of any other cause of death, and the appearance of the stomach was not suggestive of any irritant substance.

The tumour and nerves were placed in the museum of St. Thomas's Hospital, and have been very skilfully dissected by Mr. Shattock.

The tumour, which is the size of a large walnut, is seen to be closely connected with the inner cord of the brachial plexus, and appears to arise from its fibrous sheath. There were also found on dissection numerous other smaller tumours connected with other parts of the plexus, which can be better understood by the figure (Plate V, fig. 1) than by any lengthened description; but they were really even more numerous than appears from the figure. The smaller tumours appeared before dissection as if, in some cases, they might be swellings of the nerves; but the more minutely they were dissected the more they appeared to be outside the nerve-bundles, and to be connected with the perineurium and the interfascicular fibrous tissue. This condition was confirmed by the microscopical examination of one of the smallest tumours, of which transverse sections were made by Mr. Shattock, of which one is represented in fig. 2. These sections were stained with osmic acid and with logwood. The former reagent did not colour the nervous structures uniformly, probably owing to imperfect preservation of the specimen, which, not being intended for microscopical examination, had been kept in weak spirit; but in sections coloured with logwood numerous sections of nerve-tubes are seen scattered through fibrous tissue, and especially accumulated on one side of the section (see Plate V, fig. 2). The remainder of the tumour consisted of nucleated fibrous structure, precisely like that of an ordinary fibroma, and clearly originating in the connective tissue of the nerve. There was no appearance of new formation of nerve-tubes, but, if anything, rather of wasting of these structures. The whole tumour was, then, as in other specimens of this kind, a fibroma of nerve or neuro-fibroma.

Structure of the skin tumours.—Sections were made of several portions of skin taken from the chest and the left arm, containing

DESCRIPTION OF PLATE V.

Illustrating Dr. Payne's case of Multiple Neuro-fibroma in connection with Molluscum Fibrosum. (Page 69.)

From drawings by H. C. Payne and M. H. Lapidge.

FIG. 1.—View of the left brachial plexus, dissected to show the tumours on the nerves.

A. Large fibrous tumour, recognised during life.

B., B., B. Smaller tumours, exposed by dissection.

FIG. 2.—Section across one of the smallest tumours, showing thickening of the perineurium and great increase of the endoneurium; the nerve-fibres being separated by it, so that a fibrous tumour is produced.

t. Connective-tissue corpuscles.

n. Nerve-tubes.

Fig. 1.

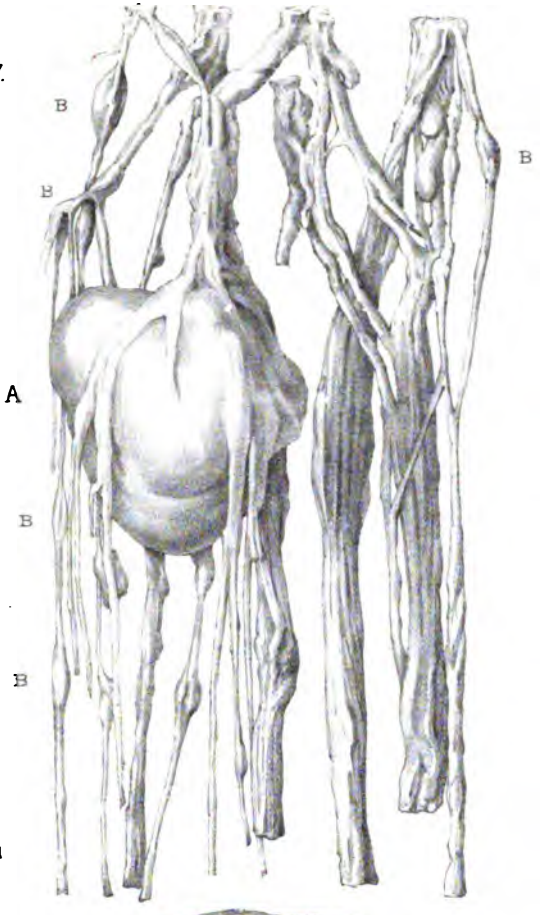

H. C. Payne del.

Fig. 2.

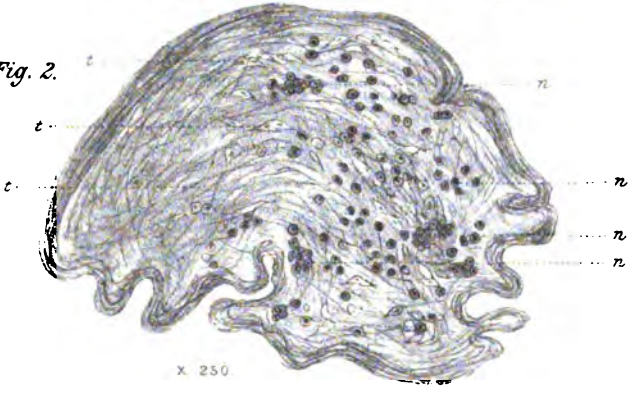

M. H. Lapidge del.

F. Huth, Lith^r Edin^r

DESCRIPTION OF PLATE VI.

Illustrating Dr. Payne's case of Multiple Neuro-fibroma in connection with Molluscum Fibrosum. (Page 69.)

Shows section of skin passing through a very small Tumour of Fibroma Molluscum. (Prepared by Dr. Acland.)

From drawings by M. H. Lapidge.

FIG. 1.—General view, under low power. The new growth is shown by a mass of nucleated fibrous tissue, the central axis of which is evidently the duct of a sweat-gland, while it extends laterally both above and below the level of the surface, at which point it is constricted.

A. Projecting part of tumour, covered with epidermis.

a. Deep layer of epidermis, showing great excess of pigment.

b. Uppermost layer of corium, unaffected by the new growth.

c. Nucleated new growth, extending in a horizontal direction.

S. Section of sweat-gland, the connective tissue surrounding which is in a condition of nuclear or small-celled infiltration.

d., d., d. Portions of sweat-duct cut through by the section, and seen to be surrounded by nucleated growth.

F. Fibrous tissue of deep part of corium and subcutaneous tissue.

H. Section of two hair-bulbs and an accompanying sebaceous gland, partially surrounded by nucleated new growth continuous with the large mass.

N. Section of a nerve, which is normal in structure, and the sheath of which is unaffected by the new growth.

O. Orifice of a sweat-duct, with commencement of another focus of new growth.

FIG. 2 shows the structure at O of Fig. 1, more highly magnified.

o. Orifice of sweat-duct.

e. Epidermis.

p. Its deep layer, with great excess of pigment.

d., d., d. Sweat-duct, cut at several points. Its sheath is surrounded by nucleated fibrous tissue of new formation, which extends in horizontal strands through the corium, at *c*, and elsewhere.

The general conclusion is that the new growth started, in this case, from the fibrous sheath of the sweat-glands and their ducts; and that the sheaths of other cutaneous structures, such as hairs, sebaceous glands, and nerves, were secondarily affected, if at all.

Fig. 1.

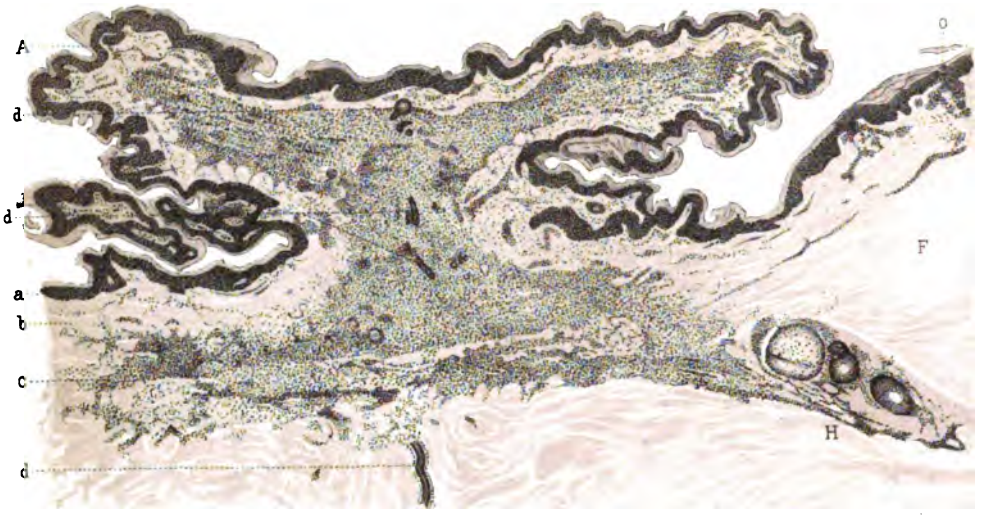

Fig. 2.

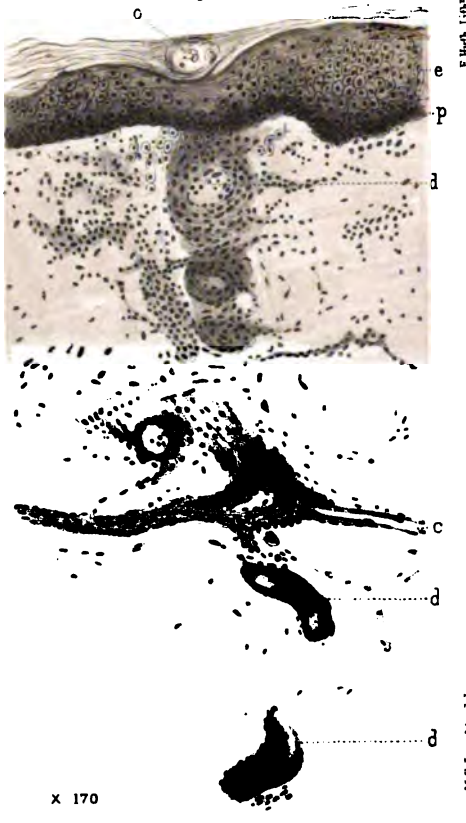

× 33.

× 170

F Huth Lith^r Edin^r

M H Lapidge del.

small molluscum growths, and stained with osmic acid and with logwood.

The appearances were as follows:—The epidermis was seen passing over the tumour quite unbroken, and presenting no notable thickening or other change. Over the tumours the papillæ and interpapillary processes were not well marked, but otherwise the epidermis was normal. There was a well-marked pigment layer, in some parts very thick.

The tumours themselves consisted of fibrous connective tissue with numerous nuclei. This fibro-nucleated growth evidently started from the corium and from its deeper layers. There was a zone of fibrous tissue immediately under the Malpighian layer of epidermis, in which few nuclei could be seen. Thus the papillary layer was comparatively unaffected.

The new growth was formed by bundles, which passed upwards from the horizontal strands in the deep part of the corium, and projected above the level of the skin, carrying the unchanged epidermis with them; they extended horizontally to some extent, and were continuous with collections of nucleated tissue around certain structures of the skin, about which normally the connective tissue is thickened, especially around the sweat-glands and ducts, and, to a less extent, around the sebaceous glands and hair-follicles.

There was very little accumulation of nucleated tissue round the blood-vessels, and the growths were not at all perivascular, as is the case with infective granulomata of the skin.

The relations of the growth to the nerves were carefully observed. Nerve-fibres were seen in a few specimens when stained with osmic acid, but their sheaths were not thickened or altered, and they had no special connection with the new growths.

While the growths generally might be considered as starting with an overgrowth of the corium generally at certain spots, there was in some specimens a more definite connection with the fibrous sheaths of the sweat-glands and their ducts (see Plate VI).

In some minute tumours the outline of the duct of the sweat-gland could be seen running through the very centre of the tumour, the duct being surrounded by nuclear infiltration, which was continuous with the growth. There was also a similar collection of nuclei with fibrous hyperplasia among the convoluted tubules of the gland itself. Hence the commencement of the tumours, instead of representing a papillary hypertrophy, was rather *interpapillary*.

In larger tumours, which would include the area of many sweat-glands and papillæ, these relations were naturally not well marked.

Hair-follicles and sebaceous glands were in several instances included in the growths. The hairs were abortive, or represented by plugs of amorphous matter, as was observed also during life, when sebaceous plugs or comedones were seen to be scattered irregularly over some of the tumours. But these structures never formed the centre of the small tumours, and evidently were not their starting-point, though there was sometimes, as has been said, a little fibro-nucleated overgrowth around them.

Nothing could be said about the relations of the lymphatic vessels or spaces. The tissue was so much contracted by the action of spirit as to appear very dense, but was evidently much laxer in its consistency during life.

Touch corpuscles (or Pacinian corpuscles) were in two instances seen, but had no special relation to the growths.

Summary.—The molluscum growths or fibromas of the skin had their origin in the corium and in its deeper layers, or even in the superficial part of the subcutaneous connective tissue. They were connected especially with the fibrous tissue surrounding the inward prolongations of epidermis which form sweat-glands, and, in a less degree, the prolongations which form sebaceous glands and hair-follicles.

There was no special connection with the blood-vessels, nor with the nerves or any nervous structures. There was no enlargement of the papillæ or papillary growth.

Comparing these skin growths with the fibromata of nerves the structure was essentially the same. Both classes of tumours were composed of fibrous tissue with an excess of nuclei, forming the well-known type of fibrous tumour or fibroma.

Relation between the skin tumours and nerve tumours.—The fact that in this case multiple fibromata or molluscum tumours of the skin coincided with multiple fibromas of the nerves cannot be regarded as accidental.

The connection between these two diseases, which appear at first sight so unlike, was pointed out by von Recklinghausen[1] in his admirable monograph, where he described two cases of the well-known skin affection called "molluscum fibrosum," in which there

[1] 'Die Multiplen Fibrome der Haut und ihre Beziehung zu den multiplen Neuromen,' Berlin, 1882.

were also tumours on various nerves. In one case the conclusion was confirmed by a very minute *post-mortem* examination; in the other, beside the molluscum skin affection, tumours connected with nerves were felt under the skin during life.

It is true that before this time *subcutaneous* tumours had been observed in cases of which the prominent feature was the occurrence of multiple fibroma of the nerves.

Such a case is represented in the classical work of R. W. Smith,[1] where a figure is given of a patient with numerous subcutaneous tumours in addition to tumours on nerve-trunks.

Moreover, Dr. I. E. Atkinson, of Baltimore, had described a case of molluscum fibrosum, in which there were numerous "subcutaneous tumours, generally about the size of a coffee bean, and evidently false neuromata." Some of these were evidently connected with nerves, and the histological structure of one (not, however, quite evidently a nerve tumour) was found to be strictly fibrous.[2]

We have then three cases already; and this makes the fourth in which multiple fibrous tumours of the nerves and of the skin have been combined.

It is possible that in the cases where superficial skin tumours have been observed, there may have been more deeply situated nerve tumours which have escaped observation. But the converse is hardly likely, that is to say, in the recorded cases of multiple nerve fibroma, any condition of the skin resembling molluscum must have been noted if it had been present.

Some explanation seems to be required of the simultaneous occurrence of cutaneous and nervous fibroma, and the most obvious one would be that the skin tumours were growths of the connective-tissue sheaths of the cutaneous nerves, as the others were of the sheaths of larger nerves. All would then be neuro-fibromata. This hypothesis was suggested by Professor von Recklinghausen in his case, but, as he admits, was too "one sided." He was able to trace numerous subcutaneous neuro-fibromata, arranged in a

[1] 'Treatise on the Pathology, Diagnosis, and Treatment of Neuroma,' folio, Dublin, 1849.

[2] 'New York Medical Journal,' December, 1875. I owe this reference to Dr. R. W. Taylor, of New York, who has written two memoirs on molluscum fibrosum in the 'Journal of Cutaneous and Venereal Diseases,' New York, February and May, 1887.

plexiform manner, but was unable to demonstrate the same connection in the case of the strictly cutaneous tumours.

He found that the original seats of tumour formation were "the fibrous sheaths of the various channels and nerves running in the cutis;" those of blood-vessels, nerves, sweat-ducts, sweat-glands, and, in a subordinate degree, the connective tissue surrounding the hair-follicles. He found also the papillary layer quite unaffected by the new growth. In my case nearly the same was true, except that a connection with the sheaths of cutaneous nerves could not be clearly traced, and that with the sheaths of blood-vessels was comparatively unimportant. Von Recklinghausen suggests, without regarding it as proved, that those cutaneous tumours which were devoid of nerves might have originated in nerves which had degenerated and disappeared through the pressure of the fibrous growth.

This hypothesis appears somewhat strained; and I should feel inclined to state the analogy between the two kinds of fibrous growths in a somewhat different way.

We have here the same affection of the connective tissue in two parts of the body, namely, of the tissue supporting or underlying the epidermis on the one hand; of that supporting and surrounding nerve-tissue on the other hand.

The cutaneous tumours start from the corium generally, not from the tissue connected with any one structure of the skin. The neuro-fibromata are formed from the connective tissue of nerves generally, that surrounding and that penetrating the nerve-bundles, —*perineurium* or *endoneurium*.

Moreover, the process of new growth in both cases is one which if not quite congenital started in early life, and shows some error or peculiarity of development in the formation of both these structures. Without necessarily adopting Cohnheim's hypothesis that residual embryonic germs remained undeveloped and became the starting-point of the new growth, it is clear that both these connective-tissue masses retained a considerable power of germination, and had some structural peculiarity which fitted them to be the seat of new growth. The clinical history of this and of other cases clearly shows that no irritation or injury, or any cause acting in after-life could be the cause of such a growth.

These considerations carry us back to the origin of the epidermic and nervous tissues, and lead us to inquire whether there is

anything in the development of the epidermis and the nervous system which would explain the similarity of growths starting from the tissues respectively connected with them.

Modern embryology has shown that the nervous system as a whole arises from the epiblast, which also produces the epidermis or general investment of the body, which again by involution gives rise to the cutaneous glands and appendages of the skin. The skin and the nervous system, therefore, have a deep-lying connection in development which makes them homologous parts. This homology is not often thought of, perhaps because there is no striking structural resemblance between skin and nerve-tissue. Nevertheless, there are points of analogy of structure between the cortex of the brain, the retina, and epidermis, as shown in their laminated structure, the presence of pigment in the associated tissues, &c. Psychologically also the homology is very significant, since the skin and nervous system together constitute the means by which our consciousness is placed in relation with the external world.

Pathologically, no instance of the homology of these parts has, so far as I know, yet been pointed out. If, however, the comparison is a valid one, it is evident that the corium will be homologous to the connective tissue of nerves, *i. e.* to perineurium and endoneurium. If so, the two pathological processes of skin and nerves may be regarded as one process, which might be defined somewhat as follows:

Irregular hyperplasia leading to tumour formation in the (mesoblastic) connective tissue which lies next to the epiblastic tissues, without any participation of these epiblastic tissues themselves. When in connection with epidermis the products of this process are called molluscum fibrosum (fibroma molluscum); but might be called dermato-fibromata; when in connection with peripheral nerves, they are called false neuromata or neuro-fibromata.

The process, if it do not originate congenitally, is one dependent on a developmental peculiarity in the tissues concerned, and generally shows itself first in childhood.

To make the analogy complete there should be similar formations in the membranes of the brain and spinal cord, in pia mater or dura mater, with which structures the two parts of the fibrous investment of nerves are, according to Recklinghausen and others, homologous. No such general tumour formation in these membranes has, so far

as I know, ever been observed; but the point would be worth examining when *post-mortem* examinations of cases of dermato- or neuro-fibromata occur. In my own case the autopsy was unavoidably incomplete.

There are not wanting facts, however, which point to some affection of the central nervous system in persons suffering from molluscum fibrosum. Hebra has observed that such individuals are always arrested in development, and more or less mentally weak (geistig verkümmert). This is often but not always the case. The individual described in this paper had the physical characteristics of a cripple, and was certainly of low intelligence, though able to earn her living and go through the ordinary duties of life. But another woman under my care, with the same affection, was quite ordinarily gifted. However, cases undoubtedly occur with deficient intelligence. Dr. Barlow has kindly drawn my attention to a family of children, several of whom are affected in the same way, and who are almost idiotic, and show progressive weakening of the intellect. So that there is very probably some structural deficiency or disease of the brain or its membranes. Observations to the same effect, in cases of multiple neuro-fibroma, are, so far as I know, wanting.

Bibliography.[1]—The literature of these cases of skin and nerve

[1] I should also mention a paper by Lahmann ('Virchow's Archiv,' vol. 101, p. 263, 1885), who examined a case of typical molluscum fibrosum, and a case of multiple fibrous tumour attached to nerves. In the first he found no nervous elements in the tumours, but found the small fibrous tumours to originate in the connective-tissue sheaths of the sebaceous glands, sweat-glands, hair-follicles, and blood-vessels. Taking into account the previous observations of Lionel Beale, who traced the tumour formation to the hair-follicles, and Hilton Fagge, who referred it in his case to the sebaceous glands ('Med.-Chir. Trans.,' liii, 217), and those of Recklinghausen above referred to, Lahmann draws the only conclusion which it seems to me the facts warrant, that these cutaneous fibromata may start from various fibrous structures in the skin. The neuro-fibromata arise in like manner from the fibrous sheaths of nerves. This conclusion substantially agrees with what I have stated above. Only I would rather state it as follows:—The tumours originate in the fibrous tissue of the corium at those parts where it is thickened to form the fibrous sheaths around the various structures contained in it, and especially around those processes of epidermis which are, in course of development, intruded into it. Lahmann further attempts to identify the molluscum fibrosum with molluscum contagiosum, evidently without having examined the latter. These two forms of new growth, however, differ from one another *in toto*, having absolutely no point of resemblance except that of forming

tumours is very fully given by von Recklinghausen in the memoir referred to. I would only draw attention to a case of neuro-fibroma in our 'Transactions,' which has escaped his notice, and where the arrangement and structure of the nerve tumours was very similar to what is here described. (Van der Byl and Snow Beck, 'Trans. Path. Soc.,' vol. vi, p. 49, plates 3 and 4.)

For cases of molluscum fibrosum, see vol. vi, p. 313, plate 14 (Dr. Lionel Beale); xiv, 278 (Dr. Murchison); xxvi, 219 (Mr. Pollock). *May 17th*, 1887.

---

21. *On the falling out of the teeth in locomotor ataxy.*

By W. Hale White, M.D.

N. Y—, aged 40. Family history unimportant; the only previous illness of importance is gonorrhœa with a chancre at eighteen years old. Eight years ago he had an attack of diplopia lasting three or four months. Since then he has always had more or less of a headache. Twelve months ago a second attack of diplopia. Is often sick and has no appetite; is much troubled with his bowels, sometimes constipated, sometimes diarrhœa Twelve months ago noticed numbness and dragging of the legs. Nine months ago pins and needles, sensitiveness, and lightning pains in the abdomen, difficulty in holding his water, and girdle-pains about the abdomen.

On admission.—Special senses all good, except that taste is impaired. There is a patch of anæsthesia on the front of the chest, and numbness in various parts of the body, and the girdle-pain just mentioned. All tendon-reflexes absent; cremasteric well marked. Respiratory and cardiac systems normal. Has loss of sexual power and difficulty in holding his water, urine normal. He complains of much sickness and irregularity of the bowels. The teeth are very good except that they are ground down. Two

prominent tumours on the surface of the skin. Dr. Lediard has just described ('Lancet,' 1887, vol. ii, p. 62) a case of molluscum fibrosum, combined, as it often is, with diffuse fibrous hypertrophy of one part of the skin, in which there was marked intellectual deficiency.

years ago the tooth exhibited this evening fell out without any previous symptoms indicating decay. It will be seen that it is a wisdom tooth and appears quite healthy. The patient remained in the hospital five weeks; he had some gastric crises. He was put upon large doses of iodide of potassium, and ordered to take the medicine when he went out. Under this treatment he improved. I have brought this case before the members of the Pathological Society in order, if possible, to find out whether there is any foundation for the statement of some authors that the teeth are particularly liable to fall out in patients affected with tabes dorsalis.

Richardière[1] has recorded a case of tabes dorsalis, in which there was disease of the metacarpo-phalangeal joint of the thumb and in which the teeth fell out. The patient thus described this occurrence. A year before admission to the hospital the eyes and face swelled, and one by one the teeth fell out without any caries; after this a few pieces of bone fell out from the palate. On admission to the hospital it was discovered that the gums were healthy, that the upper teeth were gone, but that the lower were all there. Hoffman[2] mentions a man, aged 48, who, without any apparent cause, lost all the teeth of the upper jaw two years after the first tabetic symptoms began. Dr. Lewis[3] and other authors have also described cases in which the teeth fell out.

So many symptoms are constantly described as belonging to tabes dorsalis that their very multitude, together with their rarity, makes one very sceptical whether they are not mere accidental occurrences. It will be very interesting if both dentists and physicians will note whether there is any real foundation for the statement that teeth are particularly liable to fall out in locomotor ataxy, considering how frequently they fall out from other causes. I am at present rather doubtful on the matter.

February 15*th*, 1887.

[1] 'Rev. de Méd.,' No. 2, 1886, p. 170.

[2] "Zur Casuistik der trophischen Störungen bei der Tabes Dorsalis," 'Berl. klin. Woch.,' 1885, No. 12.

[3] 'Amer. Journ. of Nervous and Mental Disease,' No. 2, 1885.

22. *Case of hemiatrophia facialis.* (*Case shown at meeting.*)

By Frederic S. Eve.

Mrs. D—, aged 42, came to consult me about her child, among the out-patients at the London Hospital. My attention was attracted by the peculiar condition of the right side of her face. This consisted in atrophy of the integuments over the right half of the lower jaw, so that the outline of the bone was clearly mapped out by a well-defined depression, commencing above at the zygoma and extending to a point half an inch from the middle line. The masseter muscle had, as regards palpation, disappeared. Well-marked atrophy of the structures in the submaxillary region, including the mylo-hyoid muscle, also existed; the lower half of the neck appeared natural. Further examination showed less advanced wasting in the temporal fossa immediately behind the external angular process of the frontal bone, and probably slight wasting over the whole temporal region. The hair on the same side was somewhat thinner and more abundantly shot with grey than on the other.

The skin over the affected region was sallow, the orifices of the hair follicles being unusually distinct, and the lanugo exceedingly small and downy, but not absent. The atrophy involved the skin, subcutaneous tissue, and certainly some of the muscles supplied by the fifth nerve, viz. the masseter, mylo-hyoid, and probably the temporal. Atrophy of the lower jaw itself could not be definitely made out either by palpation or measurement.

Sensation in the skin was unaltered, and there was apparently no muscular paralysis. Right eye normal; no ptosis or sinking of globe. Pupils equal and active. Vision $\frac{20}{20}$. Tongue and palate unaffected.

She has lost the molar and most of the bicuspid teeth, and the alveoli of the corresponding parts are wasted, but not more so on the right side than the left. Most of the teeth were pulled out when she was very young on account of caries with pain.

History.—The wasting was first noticed at the age of seventeen or eighteen, and its appearance was coincident with a severe attack of neuralgia, for which a lower (?) tooth on the right side was

drawn. The wasting progressed for some time, but has now long been stationary. She continued to suffer occasionally from neuralgia until the last eight or nine years; is unable to exactly localise the pain, but it was on the right side.

Throughout life she has suffered and still suffers fortnightly or monthly with well-marked migraine on the right side, the pain being especially severe over the eyebrow. The attacks are usually accompanied by vomiting. With these exceptions she has good health. No constipation. Has had no severe illness, but twelve years ago she was in St. Thomas's Hospital for disease of the womb. Is married, and has had five children; four are living and healthy; one died at ten months of age of tabes mesenterica (?).

Remarks.—This peculiar affection, although exceedingly rare, is so well recognised that an extended reference to the literature[1] of the subject would be superfluous. Its pathology is not precisely known, but the wasting has generally been referred to a trophoneurosis affecting the fifth nerve or the ganglia connected with it.

It is of much interest to the pathologist as an example of simple atrophy from nerve disturbance; and to the physiologist as furnishing some grounds for the supposition that trophic nerves exist.

The case itself is of its kind peculiar, in that the atrophy, as far as can be judged, is strictly confined to cutaneous and muscular structures supplied by the third division only of the fifth nerve; and in this relation it may be well to call to mind that the integuments of the temporal region are supplied by the auriculo-temporal nerve, and the temporal muscle by the deep temporal nerve, both branches of this division of the fifth. The disease is more common on the left than the right side, that involved in this case. Neuralgia of the nerves of the affected parts is commonly associated with it, but I am not aware that hemicrania has been before observed.

October 19th, 1886.

[1] See Romberg, 'Klinische Ergebnisse,' Berlin, 1846, and Eulenberg, 'Lehrbuch der functionen Nervenkrankheiten,' Berlin, 1871; also Buzzard, 'Trans. Clin. Soc.,' vol. v, 1872, p. 146; Jessop, 'St. Bart. Hosp. Rep.,' 1882; and Payne, 'Path. Trans.,' vol. xxxii, 1881, p. 306 (with plate).

II DISEASES, ETC., OF THE ORGANS OF RESPIRATION.

1. *Hyperplastic syphilitic laryngitis.*

By Felix Semon, M.D., for Ernest Jacob, M.D.

A. M—, aged 5 months, was admitted to the Leeds Infirmary on November 1st, under the care of Dr. Eddison, to whom I am indebted for permission to publish these notes. The child was suffering from congenital syphilis, the symptoms having appeared about a fortnight after birth.

The child had been previously an inmate for about a fortnight in June last, suffering from a roseolous and squamous eruption of a very severe type, and after mercurial treatment was discharged greatly improved.

On admission the child appeared very ill. She was suffering from a slight cough and huskiness of voice of ten days' duration. This quickly increased, with signs of laryngeal obstruction, and tracheotomy was performed by Mr. Littlewood, the resident surgical officer, the same night, under circumstances of considerable difficulty.

The next day the child was fairly well, but the obstruction to respiration did not seem entirely removed. Râles became audible in the chest. No dulness was detected, but the child became pallid and died the same day.

At the autopsy there was no very marked change, either in the epiglottis or the upper part of the larynx, or the vocal cords. Below the cords, however, the opening to the trachea was seen to be practically obstructed, and on making a horizontal section through the cricoid cartilage the lumen was found to be reduced to a mere chink by swelling and thickening of the mucous membrane. This hypertrophied condition extended for about three quarters of an inch below the cords, being much greater on one side than the other. (This is well shown in Woodcut 5.) The growth on

section was of a deep red colour. The limits were well defined, and there was an abrupt change from the healthy mucous membrane below.

WOODCUT 5.

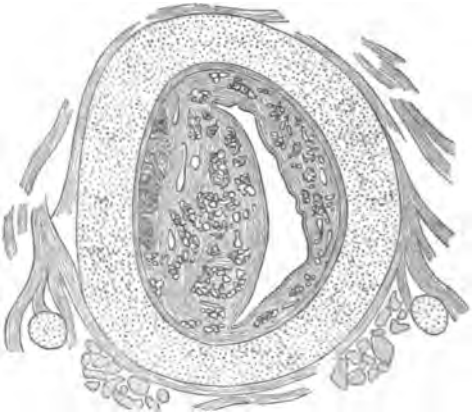

Microscopically, the projecting material consists of a mucous membrane greatly thickened by interstitial deposit, connective tissue, as well as by hypertrophy of the gland tissue. On the side where the hypertrophy is most marked there seems to be a mass of serous glands lying against the cartilage, the most superficial glands being of the ordinary mucous type. The vessels are very greatly distended, corresponding to the deeply injected macroscopic appearance.

The lungs showed a few patches of lobular pneumonia.

The liver presented to the naked eye an appearance only slightly differing from health, but the substance was extremely tough, and showed microscopically an increase of connective tissue and some small aggregations of leucocytes.

The case agrees in some points with those reported by Dr. Semon ('Path. Trans.,' xxxi), in the presence of great hypertrophy of the mucous membrane, but differs considerably in the fact of there being no ulceration, and in the apparently healthy appearance of the vocal cords, which in Dr. Semon's cases were greatly ulcerated. The dyspnœa seems to have been caused solely by the congestive swelling of the subglottic hypertrophied mucous membrane, which may have been produced by the attack of bronchitis which preceded the laryngeal affection. *February* 15*th*, 1887.

2. *Epithelioma of larynx.*

By SAMUEL WEST, M.D.

GEORGE P—, aged 43, a clerk in the Customs, was admitted into the Chest Hospital with great dyspnœa and the signs of tracheal obstruction.

He gave the following history: he was well until nine months ago, when he began to lose his voice gradually. In a few weeks he was unable to speak except in a hoarse whisper. He was able to continue at work up to six weeks ago, and felt all right except for the loss of voice. Fourteen days ago he first noticed a wheezing in the chest, with pain along the sternum, which was worse on exertion. A barking cough came on, and there was some sticky expectoration. The pain and difficulty in breathing grew so much worse that he came to the hospital.

On admission, he was a spare but not wasted man. He sat up in bed on account of the dyspnœa. The respirations were long-drawn, laboured, and stridulous, twenty in the minute. He could talk without pain or much distress for a short time.

On June 19th a complete examination was made. The stridor was extreme, hardly any air appeared to enter the lung, but the stridor masked all sounds. The lungs were in a condition of extreme emphysema, but otherwise normal. The lower intercostal spaces were drawn in on inspiration. The neck seemed normal; there was no swelling or tenderness round the larynx, and both larynx and trachea were freely movable.

With the laryngoscope the arytenoid cartilages and folds were seen to be red and greatly swollen. The left cartilage and cord were fixed in the middle position, the vocal cord itself was white; in the middle third was a conical projection, white like the rest of the cord, and above this an irregular slough in the position of the false cord and neighbouring parts. The right true cord was red, but moved readily, the false was much swollen.

The diagnosis was made of specific laryngitis, with probably perichondritis of the left arytenoid cartilage; but the possibility of new growth was borne in mind.

Active antisyphilitic treatment was instituted, but on the 21st the symptoms became so urgent that tracheotomy became necessary,

and was performed with marked and immediate relief. The operation was quickly recovered from; the temperature was raised for two days after it, but then fell to normal, and in a few days a soft tube was inserted instead of the silver one.

The antisyphilitic treatment was pushed, internally with iodide of potassium and mercury, and locally by means of insufflations of calomel and morphia. The general condition greatly improved, but the local conditions remained much the same, for the ulcer did not heal, and the patient could not do without the tube for long. The patient, however, gained weight, and as there was no glandular enlargement the chances were thought to be against new growth.

The tube was daily removed for cleansing, and on several occasions the exuberant granulations which had formed were touched with nitrate of silver or snipped off.

For the next three months the patient remained *in statu quo*, eating and sleeping well, and suffering but little discomfort from the tube. The question of relief by operation now raised itself, and the patient was seen for me by Mr. Butlin in the early autumn; he advised further antisyphilitic treatment first.

In October the thyroid region began to swell and to become painful and tender. I proposed to have an opening made into a swelling at the side of the thyroid where fluctuation seemed to be felt, but before this was done it became smaller with the discharge of somewhat offensive pus from the tube. A considerable amount of brawny induration persisted round the thyroid, and one or two of the glands in the neighbourhood swelled a little. The question of operation was again raised, but decided against.

From this time, *i. e.* from November, the patient began to fail, at first not rapidly, but about Christmas time he began to waste, partly from the pain and distress of the throat, and partly from want of food, which became distasteful to him, both on account of loss of appetite and of the pain which swallowing caused. For some weeks the throat had been almost impossible to examine, for the epiglottis hung over the glottis, and would not rise; but, so far as could be seen, the conditions had not changed.

Early in January the patient began to suffer from dyspnœa, and died at the end of the month from exhaustion and gradual suffocation.

Post-mortem examination.—The body was much emaciated. There was a good deal of swelling round the thyroid, which

extended down to the tracheotomy hole. The larynx could, however, be moved freely from side to side. It was removed together with the tongue and trachea, and laid open from the back.

The whole interior of the larynx was occupied by an ulcer which extended from the middle of the epiglottis to the first ring of the trachea. From its surface numerous cauliflower vegetations, for the most part of small size, projected into the interior. The parts of the thyroid and cricoid cartilages were completely destroyed, and no trace of them were to be found. On the left side the only remains of the thyroid was a loose fragment about three quarters of an inch square, but of the cricoid the greater part remained. Of the arytenoid on this side there was no trace. All the cartilages were left on the right side at the lateral and posterior parts. The base of the epiglottis and the root of the tongue immediately below it were involved in the ulceration. There were some vegetations round the tracheotomy hole, but there was no direct continuity of ulceration towards the front; the infiltration had not reached the subcutaneous tissue, but it lay immediately beneath the superficial muscles, and on the left side was torn on removing the larynx, so that the cavity in the larynx was opened. It was in this place that fluctuation had been felt, and from which pus had seemed to come. The upper part of the thyroid body was involved here.

There was no enlargement of glands, one gland only at the upper side of the larynx on the left was the size of a small nut.

Microscopical examination showed the ulcer to be malignant. The structure was that of an epithelioma with well-marked birds' nests. There was also a very considerable amount of small-celled infiltration, which may be associated with the inflammatory condition observed during life.

The clinical interest of the case lies chiefly in the difficulties of diagnosis. The possible alternatives were syphilis, tubercle, and new growth. The decision was quickly made as against tubercle; as between syphilis and new growth the laryngoscopic appearances were not sufficient to decide. In favour of syphilis was the age of the patient, a possible history of syphilis, and the rapid improvement in general health after tracheotomy. As against new growth was the absence of any glandular enlargement. As against syphilis was the failure of response to antisyphilitic treatment and the progressive course of the disease. The case was further complicated

by the occurrence of extensive inflammatory symptoms, due to widespread and progressive perichondritis. This might occur in either of the two affections, and was therefore of no assistance in diagnosis. It was a very serious complication, and was the cause of much of the patient's subsequent distress. The marked improvement after tracheotomy and the long absence of cachexia seemed to some extent opposed to new growth, and even rapid failure at the last could be accounted for by the perichondritis, so that, although the diagnosis was made of new growth early in the case, it was felt to be only a probable diagnosis, and by no means certain. Nor was the *post-mortem* appearance conclusive, for the conditions found might have been the result of perichondritis simply, whatever its prime cause. It was only on microscopical examination that the nature of the case was settled. The sections showed typical epitheliomatous structure with well-formed birds' nests.

The pathological condition was in itself interesting, for the growth had spread superficially, and in spite of its great extent it was still strictly confined to the larynx, and had not involved the neighbouring parts, so that the larynx was still freely movable, and no glands had enlarged. The only gland enlarged was a very small one, immediately above the tracheotomy opening, and this was so small that it could only be detected on careful dissection. This absence of lymphatic affection may be associated with the absence of cachexia, for emaciation and cachexia did not occur till quite late in the disease; in fact, until about a couple of months before the patient's death.

The total duration of the case was sixteen months.

The question of operation presented itself early in the case, but it was at that time decided against on account of the uncertainty of the diagnosis, which seemed to suggest the propriety of trying the effect of treatment by drugs first. By the time antisyphilitic remedies had had their trial and failed the progress of the disease rendered complete examination impossible, and the occurrence of perichondritis had further complicated matters. It is clear from the *post-mortem* appearances that even at the last it would have been possible to remove the disease entirely, but the general condition of the patient had long put out of question such a serious measure.

The limitation of so extensive a growth to the interior of the

larynx is very instructive, although this suggests the possibility of an operation in the earlier stage of the disease; still its great extent makes it probable that at the time when the operation was considered there might have been much more extensive disease than could be ascertained by the laryngoscope, and that therefore the operation was, after all, rightly decided against.

December 7th, 1886.

---

3. *Tubercular ulceration of trachea.* (*Card specimen.*)

By W. B. Hadden, M.D.

The trachea is extensively ulcerated. The rings are ossified, and many of them are laid bare. The ulceration extends a little way into the left bronchus, but not into the right. There is also extensive ulceration of the larynx, chiefly on the back of the epiglottis, and just below the vocal cords.

Taken from the body of a man aged 66, who died of advanced phthisis. *December 7th*, 1886.

---

4. *Ulceration of the trachea and rupture of aorta.* (*Card specimen.*)

By Henry Maudsley, M.D.

An inch below the cricoid cartilage, on the posterior and lateral surfaces of the trachea, occupying about three fourths of its circumference, is an irregular ulcer, about the size of half-a-crown. The floor of the ulcer is covered by whitish slough, and parts of two necrosed cartilages are exposed. The anterior surface of the trachea is on a level with this ulcer, and the rest of its surface to just above the bifurcation is occupied by irregular, puckered, scar tissue. At the end of this scar tissue, at the bifurcation in the anterior wall, is a perforation, the mucous membrane around which is healthy,

but undermined by blood-clot. The perforation is occupied by clot. The aorta is atheromatous and dilated, and in the transverse arch where it crosses the trachea is a small slit, which communicates with the opening in the trachea. The lymphatic glands by the side of the trachea are slightly enlarged.

The specimen was taken from the body of a woman aged 42, who had suffered from symptoms of lung disease for about seven months. Her symptoms for three months before her death were dyspnœa, stridulous cough, orthopnœa, and copious expectoration of purulent sputum. For four days before her death the sputum was sanguineous. She died of asphyxia, not from hæmorrhage.

There was no history of syphilis, and no syphilitic lesions were found in any of the organs.

There was purulent bronchitis and some dilatation of the bronchial tubes, but no ulceration. At the apex of the left lung there was a caseating mass about the size of a walnut, which showed under the microscope the structure of tubercle. There was no tubercle elsewhere. The larynx was healthy.

January 19*th*, 1887.

---

5. *Localised bronchiectasis caused by the invasion into a bronchus of a caseating bronchial gland.* (*Card specimen.*)

By Lauriston Shaw, M.D.

From a male child, aged 2 years, admitted into Guy's Hospital with urgent dyspnæa and pyrexia, simulating diphtheria and broncho-pneumonia.

The patient was the subject of congenital syphilis, having ulceration of the skin of the face, and of the pharynx and larynx, and inflammation of the capsules of the liver and spleen.

Most of the glands in the mediastinum were in an advanced condition of caseation. One of these, close to the right main bronchus, had broken down and formed by ulceration a channel into one of the primary divisions of the bronchus. Through this channel a piece of the caseating gland, about one third of an inch in diameter, had evidently passed into the bronchus, and was found there at the autopsy. The tubes beyond were dilated and formed

a single cavity, the portion of caseating gland having apparently acted as a foreign body in the bronchus.

The bronchiectasis was surrounded by lung consolidated by inflammation of recent date, which inflammation was the immediate cause of death. *May 17th*, 1887.

---

6. *Rapidly fatal hæmoptysis from ulceration of a large branch of the pulmonary artery in a child.* (*Card specimen.*)

By W. Pasteur, M.D.

The right lung of a boy, 5 years of age, who was admitted into the North-Eastern Hospital for Children with signs of consolidation of the whole of the right lung, and during his stay in hospital developed cavity-signs in the second right costal interspace. He died quite suddenly from profuse hæmoptysis; the amount of blood lost being roughly estimated at from 8 to 10 oz.

Both layers of the pleura are greatly thickened, and intimately blended in parts. In some places, notably around the lower margin of the lung and on the outer aspect of the lower lobe, the two layers were separated by a small quantity of clear serum. The whole lung has undergone extensive fibroid change secondary to the pleurisy, and is thickly studded with tubercle which has begun to soften in small isolated foci at the apex, and at the posterior apex of the lower lobe. Towards the anterior margin of the lung, corresponding with the second, third, fourth, and fifth interspaces, is a small localised empyema which communicates directly with an irregular sinuous cavity. At the bottom of this is laid bare one of the large branches of the pulmonary artery just above its subdivision, and a large bronchus with which the cavity freely communicates. There is a longitudinal rent in the artery about one third of an inch in length, and the wall of the vessel has all but given way in two other places.

Judging by the stage of advancement of the tubercular processes in the remainder of the lung, it is probable that the great extent, as well as the somewhat unusual position of the cavity, is to be accounted for by its origin in a caseating bronchial gland.

Its general direction may also have been, to some extent, determined by the fact that the portion of lung in contact with the empyema was not invested by the tough layer of pleura which covered the remainder of the organ.

The left lung was riddled with tubercle of more recent date.

October 19*th*, 1886.

---

7. *Disseminated fibrosis of lungs.*

By W. B. Hadden, M.D.

The patient from whom the specimens were taken was a man aged 60, a mason. He came into the hospital extremely ill, and died the next day. No history could be obtained from him except that he had had an injury to the chest a short time previously. I have since tried to discover his friends, but have not succeeded. On admission he had urgent dyspnœa, the signs of bronchitis and albuminuria. Nothing else of importance was made out. At the *post-mortem* examination the eighth and ninth ribs on the right side and the ninth and tenth on the left were fractured near their angles, and the pleura over the broken ends was lacerated. The right pleura contained a pint and a half of thin pus, and the left a pint. On the left side the pus had made its way out of the pleural cavity through a small opening near the fractured ninth rib, and had burrowed between the muscles of the back on the left side, reaching nearly to the crest of the ilium. Scattered throughout both lungs were numerous small, pigmented, hard nodules. On the surface they appeared as small round white dots, surrounded by a ring of pigment. On section it was found that the white dot was really thickened pleura, and that the pigmented ring corresponded to a small round and hard nodule, situated in the lung tissue just beneath the pleura, but intimately adherent to the latter. All the nodules, on microscopical examination, were found to consist simply of fibrous tissue with abundant pigment. There was no indication of caseation, and there were no giant-cells. In some sections the fibrous change was found to involve the lung-tissue for some distance beyond the circumscribed

nodules, whereas in other sections healthy tissue was seen in their immediate neighbourhood. At the apex of the right lung there was a large, hard, pigmented mass, and at one spot a small calcareous nodule was found. On close examination the large mass, in some parts, was seen to be made up of small round nodules, resembling those already described. The pleura at the apex was much thickened, as in the case of the discrete nodules seen on the surface of the lungs, but it was also firmly adherent to the parietal layer. Microscopical examination showed the same fibrous condition, with pigmentation, as seen in the small nodules. A search was made for tubercle bacilli, but none were found. The lung-tissue generally was somewhat pigmented, crepitant, but not emphysematous. There was no sign of caseation or of excavation. The bronchial glands were large, pigmented, and in parts calcareous. As regards the other organs, the liver and kidneys were finely granular and rather firm; in the spleen, on section, a small, round, firm, yellowish nodule was found.

I am inclined to consider this case as one of mason's phthisis, although I am aware that the fibrous change in this class of industrial disease is more diffuse than that seen in the present case. I do not think that it is possible to exclude syphilis with certainty, although the absence of caseation in the nodules, and the non-existence of gummata in the liver, seem to point against it. The interstitial change in the liver and kidneys was diffuse, thus differing from the condition in the lungs. So we can scarcely look on the pulmonary condition as being part of a general fibrous change. In the third and last volume of Ziegler's 'Pathological Anatomy' (p. 164), I find described and figured a condition of "nodular cirrhosis of lung," occurring in masons. The affection seems in every respect identical with that which I have described.

December 7th, 1886.

8. *Quiescent tubercle (disseminated fibrosis) of lung. (Card specimen.)*

By R. G. Hebb, M.D.

C. M—, aged 62, mason, admitted to Westminster Hospital for chronic renal disease under Dr. Allchin.

No history of illness previous to one month before admission for dropsy.

Urine: sp. gr. 1015, albumen $\frac{1}{4}$.

Post-mortem.—Lungs studded with shotty nodules, most frequent beneath pleura and at apices. No breaking down.

Microscopical examination shows tubercles in various stages of development, but without presence of bacilli.

May 17th, 1887.

---

9. *Lung from a case of chronic pleurisy. (Card specimen.)*

By W. Pasteur, M.D.

The left lung of a man aged 57. His morbid history dates from May, 1885, when he had an attack of acute pleurisy with effusion lasting five weeks, from which he never recovered completely. He has suffered ever since from shortness of breath. In July, 1886, the legs became œdematous, and a few days later there was fluid in the peritoneum.

When admitted into the Middlesex Hospital in August there was marked contraction of the left side of the thorax sixteen and a half inches as against nineteen at the nipple level. There was absolute dulness on percussion all over the left chest with very appreciable diminution of vocal fremitus and vocal resonance. On auscultation the breathing was loud and cavernous (suggesting excavation) in the upper two left interspaces and tubular breath-sounds were audible over the remainder of the lung, but very weak below the angle of the scapula. There were no adventitious sounds. The position of the heart's apex beat could not be determined.

At the autopsy the greatest difficulty was experienced in removing the left lung. The heart, which was intimately bound up with it, was removed at the same time.

The structures occupying the mediastinum to the left of the median line were firmly matted together by dense fibrous tissue. Several enlarged glands were encountered in the upper part of the thoracic cavity; none of them showed signs of caseation.

The left lung was completely collapsed, measuring about three and three quarter inches vertically by one and a half inches in the transverse diameter. It was closely invested by a layer of tough, glistening, semi-cartilaginous pleura of a uniform thickness of one sixth inch. There was no trace of fibrous offshoots from this into the lung-substance, which felt quite soft, and was of putty-like consistence throughout. There was no naked-eye evidence of tubercle in either lung.

The parietal layer of the pleura was also greatly thickened one sixth to a quarter inch, and inseparably blended with the structures in contact with it, periosteum, &c. The two layers were separated by a space some three quarters of an inch across, which was lined and bridged over by innumerable bands of soft friable lymph, the interstices being filled with clear yellow serum.

Towards the base the meshes were filled with a finely granular, creamy-looking gravitation deposit, of lymph débris.

The pericardium was universally adherent, and the heart completely invested by fibrous tissue. There was very slight enlargement of the right cavities, but no valvular lesion.

The visceral and parietal peritoneum was thinly sprinkled with grey fibroid tubercle, most numerous on the anterior wall in the hypogastric region. Glands not appreciably enlarged. No signs of caseation.

The following points call for remark:

1. The unusual amount of collapse, due no doubt to a sudden large effusion with little or no absorption before secondary changes had begun in the pleura.

2. The complete absence of fibroid change in the collapsed lung.

3. The short duration of symptoms, sixteen months, when compared with the amount of fibroid change.

December 7th, 1886.

III. DISEASES, ETC., OF THE ORGANS OF CIRCULATION.

1. *Two cases of congenital malformation of heart. Perforation of septum ventriculorum; undefended space open.* (*Card specimen.*)

By Frederick Willcocks, M.D.

Case 1.—This specimen is taken from a male child, who first came under observation at the Evelina Hospital for Sick Children in February last, when he was three weeks of age.

A loud rasping systolic murmur was audible all over the front of the sternum, being most intense between the third costal cartilages. There was considerable dyspnœa, and the skin had a general yellowish aspect. Cyanosis was not always present, though the child "turned all manners of colour" at times, according to the mother's statement. No clubbing of the fingers.

At the *post-mortem* examination a perforation was found through the undefended space, immediately below the aortic valves, and the opening led directly into the sinus of the right ventricle.

The foramen ovale and ductus arteriosus were normal.

Case 2.—This specimen is taken from a child, aged 8 years, who died of cerebral embolism and right hemiplegia, and in whom congenital heart disease was not suspected.

When she first came under observation she had had a previous attack of rheumatic fever, and both a systolic and præsystolic bruit were audible at the apex. There was no severe cyanosis, but the fingers and toes were somewhat bulbous and congested.

At the *post-mortem* examination numerous recent vegetations were found on both aspects of the mitral valve, and also on the aortic valves, The undefended space exhibited a triangular opening, and one of the aortic cusps projected backwards into it. On

the aspect of the orifice looking towards the left ventricle some other recent vegetations were also present, These were probably induced by the friction of the neighbouring aortic segment. The foramen ovale and ductus arteriosus were both normal.

April 19th, 1887.

---

2. *Bullet wound of the left ventricle.* (*Card specimen.*)

By R. Maguire, M.D.

The track of the bullet was almost directly backwards. It pierced the left ventricle, the inlet being clean, the exit jagged. The septum ventriculorum was uninjured. It then went through the lung, the vertebral column, and the spinal cord, and was found beneath the skin of the back.

There was a clot of blood in the pericardium the size of a fist, and a smaller amount of blood in the left pleura.

March 14th, 1887.

---

3. *Aneurysm of heart; cerebral tumour; idiocy.*

By Angel Money, M.D.

E. L—, female, aged 5, was brought to the Hospital for Sick Children on June 21st, 1883, under the care of Dr. Dickinson. She had never been right from birth; had never sat up, or walked, or spoken. Had had measles at the age of eighteen months.

There were twelve children in the family. No miscarriages. Patient was the ninth child. Ten of the number were living. Two died, one of scarlet fever, aged sixteen months, one of measles, aged eleven weeks. The father's sisters and brothers died from consumption. Syphilitic history was probable, but not conclusive. The eldest girl had abscesses after vaccination, on the bottom, on chest, and arms. Some had thrush but not snuffles. The father was healthy and steady. One child has rickets.

Present state.—The head and face have an unusual appearance; the forehead is covered with hair over more than its upper half. The child makes an odd snoring noise, and screamed for half the night. There appears to be a total absence of intellect.

The head is distinctly small, its circumference eighteen inches; from external meatus to internal meatus over the vault measures twelve inches; the bridge of the nose is fairly formed. There is much sweating about hairy part of head. The orbicularis oris seems a very powerful muscle. The upper incisors are worn nearly level with the gums from constant grinding of teeth. Ears and nose not badly shaped. Wrists not thick, nor ankles. Anterior fontanelle open an inch and three quarters wide and an inch and a quarter from before back. Skull not natiform; frontal eminences too pronounced. The brow is overhanging. No large glands anywhere.

Always rolling head from side to side, and the body is constantly wriggled about, Perhaps a trifling squint in left eye. Lower front region of chest bulges forwards too much. Slight bilateral recession during inspiration at level of sixth and seventh ribs, more marked on right side. There is a loud systolic murmur over præcordia. Nothing definite in lungs. Belly full; no visceral enlargement. No beading of ribs. Bowels not open. Temperature 98° last night, 100·4° this morning.

June 23rd.—Temperature 103° this morning and 104° this night. Death, June 24th, 4 a.m.

Necropsy.—Body weight 13¾ lbs.; body length thirty-one inches. Frontals and parietals show some vascular thickening at the usual sites; also the orbital plates. Diploë is thick and vascular. The outer and inner tables show a marking or irregular network of dry chalky appearance.

Firm yellow spherical mass size of Tangerine orange, situate about the parietal lobule; section of it shows a kind of nucleus and faint concentric laminations. The convolutions are lost gradually on its edges. Clearly the tumour is in the brain. Rest of brain *nil.* Vessels and sinuses *nil.* Nothing in eyes; no tubercles; no neuritis. Only "gum water" in tympanic cavities. No perforation or necrosis.

Heart: Aneurysmal pouch of "undefended" part of ventricular septum hanging into right ventricle; its mouth opens into left ventricle. A hole with round, smooth edge, about two millimetres in

diameter, is seen near its apex. The walls of the aneurysm are formed by the septal flap of the tricuspid valve. The cavity of the aneurysm seems to be formed by the opening up of the potential space between the laminæ forming the septal flap of the valve.

All the tricuspid valve is decidedly thickened and tough, and there is a perforation in one of the cusps. The valve has a "pouchy" look, especially the septal flaps; they are actually convex; the mitral valve is in a similar condition. The larger flap of the mitral is very convex towards the cavity of the ventricle. Larynx and trachea natural. A few ill-defined fibroid nodules exist in the front part of the upper lobe of right lung. Both the lungs are small and flat; the right weighs only 3 oz., and the left 2¼ oz.; the right is adherent throughout by fairly firm but not wholly resistant adhesions. The alimentary tract was normal from mouth to rectum.

Liver soft, congested; weight 10¼ oz. No tubercle. Pancreas *nil.* The bronchial glands a little enlarged; hard, fibroid, with a few areas of cheesiness.

Kidneys, together, weighed 2¾ oz.; cortices pale and soft; no tubercles. Rest of urinary tract healthy.

Spleen: Weight 1¼ oz., natural.

Slight beading of visceral aspect of seventh and eighth ribs; not orthodox rickets. No scars about mouth or anus, and no other signs of syphilis.

The skull from base to vault is very deep. The tumour formed the hinder end of the right hemisphere, as seen when calvaria first removed. In both hemispheres the occipital lobule was bent downwards, so as to be in front of the hinder extremity of the right hemisphere. The skull was brachycephalic as well as high. There would seem to be some relation between its shape and the curving forwards of the hinder ends of the cerebral hemispheres.

December 21*st*, 1886.

4. *Aneurysm of sinus of Valsalva.*

By NORMAN MOORE, M.D.

A HEART showing an aneurysm of the sinus of Valsalva. The orifice of the aneurysm was behind the middle aortic valve at the lowest part of the sinus of Valsalva, and was one third of an inch in diameter. The edge of the orifice was thick, rounded, and without growths upon it. The aortic valves were all fringed with soft ragged growths, and partly destroyed. The aneurysm projected as a three-lobed tumour, about a quarter of an inch broad, into the right auricle on the upper surface of the tricuspid valve. Between its orifice in the sinus of Valsalva and the tricuspid valve the aneurysm extended downwards between the layers of the upper part of the undefended space, and into the substance of the tricuspid valve. The interior of the aneurysmal sac was roughened and partly filled with fibrin.

The edge and all the cords of the mitral valve were thickened, and the two flaps adherent to one another at their edges, so that well-marked mitral stenosis was present. The cords of the tricuspid valve were all thickened, though much less than those of the mitral valve. The edge of the tricuspid valve was slightly thickened, and its flaps were adherent at their edges, causing a slight degree of tricuspid stenosis. The pulmonary valves were normal. The left ventricle was much dilated and slightly hypertrophied. The heart weighed 15¼ oz.

The patient was a man aged 21 years, who died after six attacks of rheumatic fever.

The destruction of the aortic valves and the soft ragged growths upon them pointed to the probability of the aneurysm being an acute one. *November* 16*th*, 1886.

---

5. *Interstitial aneurysm of the interauricular septum.*

By ROBERT MAGUIRE, M.D.

THE patient from whom the specimen was taken, was brought to St. Mary's Hospital in a moribund condition, and died a very short time after admission. No clinical history could be obtained.

At the *post-mortem* examination the heart was found greatly enlarged, the enlargement mainly affecting the left ventricle. The cavities of both sides contained *post-mortem* and a little *ante-mortem* blood clot. The muscular tissue of the left ventricle was greatly thickened, but of normal colour and consistence. The cavity of the ventricle was slightly dilated. The aortic orifice was extremely narrowed, so much so as to admit only the tip of a finger. Its cusps were thickened, rigid, and in part calcareous. On the upper surface of the valve large masses of inflammatory material were found occupying the junctions of the various cusps, and to some extent narrowing the orifices of the coronary arteries. The masses had for the greater part undergone calcareous change, but were covered by a recent deposit of fibrin. They projected markedly towards the aorta, but slightly towards the ventricle. On the edges of the aortic cusps, and in a few small patches below them, the endocardium showed a slight deposit of fibrin, and in some of the spots ulceration was seen. The aorta above the valves was comparatively healthy.

The portion of the auricular septum below and anterior to the foramen ovale was observed to bulge markedly into both auricular cavities. The bulging was soft, and on incision was found to consist of a cyst, lined with a layer of whitish, non-laminated fibrin, and filled otherwise with dark, somewhat disintegrated blood-clot. The cavity of the cyst was of about the size of a pigeon's egg. At first no communication whatever could be found between the sac and the surrounding heart cavities. I was therefore uncertain whether it was an aneurysm, the opening of which had closed, or, which seemed the more likely, whether it was the result of an interstitial hæmorrhage. One or two such hæmorrhages have been described and attributed to disease or thrombosis of the coronary arteries. On further examination, however, a small ulceration was found covered by fibrinous deposit, and situated immediately below the junction of the two posterior aortic cusps, communicating by means of a small opening with the blood-sac described. It was clear, therefore, that the cyst was an interstitial aneurysm, which had commenced as an ulceration of the endocardium, piercing the auricular septum. The opening below the aortic valve was very small compared with the size of the aneurysm, and it is possible that the aneurysm was really formed by an ulceration in the neighbourhood of one of the inflammatory masses

above the valve, and had secondarily ulcerated into the ventricle below the valve, the primary ulceration and opening being closed by the heaping up of inflammatory matter. This, however, appears somewhat improbable, since, although the opening below the valve was very small, the tension in the ventricle must have been excessive as shown by the great muscular hypertrophy, while above the valve the tension must have been comparatively low.

The more recent patches of endocarditis were examined for micrococci, but none were found. The tissue surrounding the aneurysm showed granular and slight fatty degeneration.

The specimen is of interest in that it presents a very rare condition in a locality which very seldom shows pathological change. As far as I can find, no other specimen of the kind has been reported. *May 3rd*, 1887.

---

6. *Ruptured aneurysm of the heart (syphilis.)*

By J. F. Goodhart, M.D., for A. Withers Green.

History of Case.—The case I have brought before you this evening is that of a young barrister, aged 30, who was found, on the morning of December 8th, 1886, dead, as if he had been sleeping, in his armchair. He had left his friends early the evening before, after dining with them, apparently well and cheerful to go home to some work. Occasionally he drank hard, but was thought by his friends to have had good health.

In his pocket was found a prescription for a mixture of mercury and iodide of potassium, dated October, 1885. The medical man who gave this prescription tells me that the deceased had a sore-throat and eruption, also later a node on the tibia.

Post-mortem.—The *post-mortem* was made thirty-hours after death. On opening the thorax the pericardium was distended with black clot. The heart was about of normal size. Bulging from the middle of the left ventricle, and running round the outer side to the posterior wall, was a soft fawn-coloured bulging which, towards the posterior aspect, projected downwards into an auricular-

shaped sac. The sac was thin walled, and had ruptured its posterior inferior part and communicated with the left ventricle by an aperture half an inch in diameter. The mass or swelling in front was composed of yellowish-white gummatous-looking material, confirmed by microscopic examination. Valves were healthy. The aorta was good. The cavity of the ventricle was not dilated except for the local swelling or bulging. The posterior coronary artery, or a branch of it, was involved in the disease and apparently obliterated, but the remainder appeared healthy.

Remarks.—The two points about this case which made me bring it before you were—(1), as a good specimen of ruptured aneurysm, and (2) as containing a clear history of syphilis.

In looking over the 'Pathological Transactions' I fail to find many cases of a clear association of aneurysm and syphilis. Dr. Thomas Barlow (vol. xxvi, p. 65) and Dr. Sharkey (vol. xxxvi, p. 133) each relate a case. Dr. Mahomed (February, 1877), in a paper on a case of ruptured aneurysm of the aorta in a syphilitic subject, aged 39, points out that although the aneurysm occurs more often in syphilitic than in non-syphilitic subjects, the relation between syphilis and aneurysm is not yet decided (vol. xxvii, p. 347).

The present case seems to me to be one of clear relationship.

January 4th, 1887.

---

7. *A case of diffuse syphiloma of the heart.*

By W. Pasteur, M.D.

[With Plate VII.]

The heart which forms the subject of this communication was removed from the body of a woman, some thirty years of age, who was found dead in the streets and brought to the Middlesex Hospital.

The woman had belonged to the lower orders, and, judging by her general appearance, was not improbably a prostitute. The fact that the body was not identified lends some weight to this supposition. Her antecedents, as will be inferred, are absolutely unknown. It will save time if I state, at the outset, that the most careful

search was made at the *post-mortem* examination for the ordinary signs of syphilis without success. The heart was the only organ which presented any obvious naked-eye signs of disease. The spleen was healthy, the kidneys, to all appearance, typically normal. There was no disease in the mediastinum, and nothing was found to suggest tubercle. The liver was somewhat enlarged and presented on section a peculiar marbled appearance, to which I shall refer again.

The parietal layer of the pericardium was healthy, but there was recent lymph on the surface of the left ventricle.

The heart itself was enlarged, weighing 13 oz. The cavities contained black clot, but there were no adherent thrombi.

The left ventricle was dilated and hypertrophied, and the intraventricular septum was considerably thickened (seven eighths of an inch in its central portion), and encroached somewhat on the cavity of the ventricle.

The outer wall of the ventricle and the septum were thickly studded with opaque or semi-opaque yellowish-grey patches of all shapes and sizes, the largest of which measured more than an inch in length. Their distribution was quite irregular. In places the outer muscular layers were chiefly affected, whilst in others, notably towards the apex, the inner layers had suffered most, and the endocardium was involved. The greater portion of the intraventricular septum was infiltrated by disease. The outer wall of the ventricle had suffered about equally in every part. At a rough estimate, at least one half of the ventricle was diseased.

The right ventricle was affected in the same way, but to a much smaller extent.

The aorta and large vessels were perfectly healthy, and the orifices of the coronary arteries free from disease.

The diseased patches protruded slightly from the surface of the section, and felt firm and elastic; and the outer zone, which merged insensibly into the surrounding muscular tissue, was more translucent than the central portions. Wherever the endocardium was implicated it presented an opaque, milky appearance, which was very striking. Its surface was not appreciably roughened but slightly mammillated. It was also noticed that the milky patches were of considerably greater extent than the disease patch in contact with them; this being probably due to the greater affinity of the disease for the fibrous structures. There was one very extensive

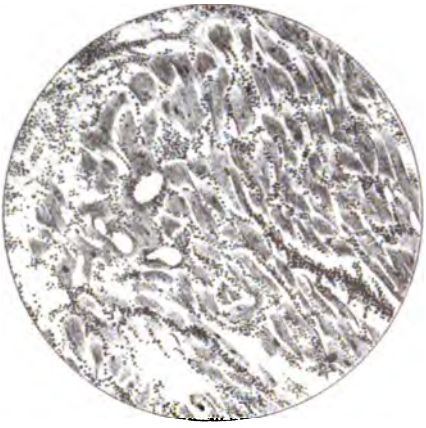

Fig. 1.

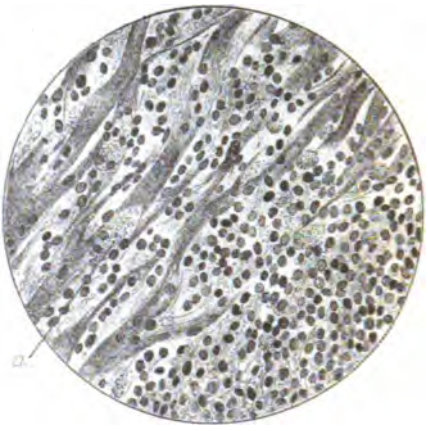

Fig. 2.

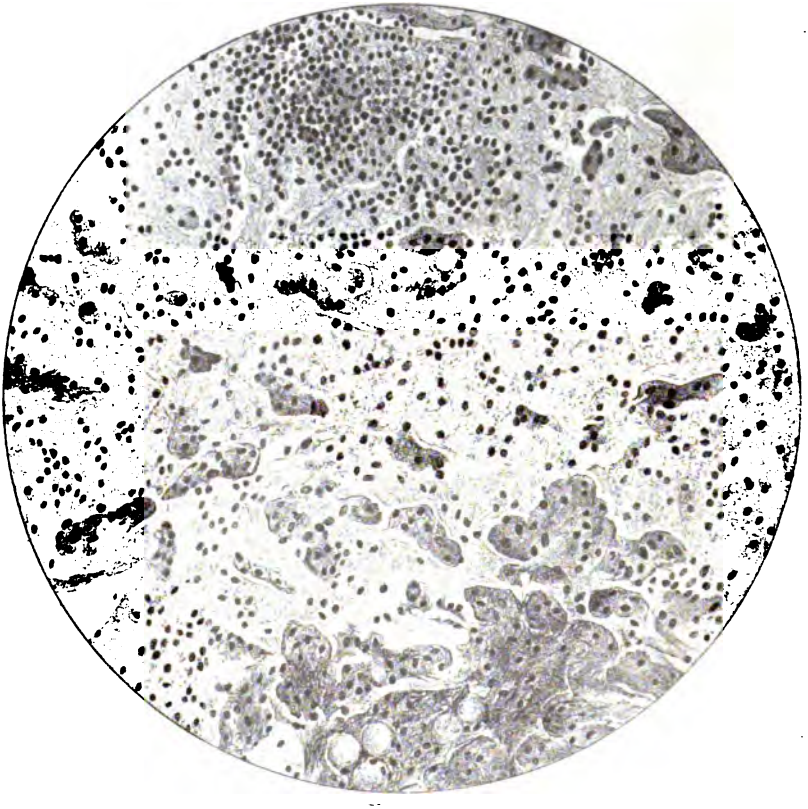

Fig. 3.

DESCRIPTION OF PLATE VII.

To illustrate Dr. Pasteur's case of Diffuse Syphiloma of the Heart. (Page 103.)

From drawings by H. Danielsson.

FIG. 1.—A section taken at the edge of a disease-patch, showing infiltration of the muscular tissue. Logwood preparation. Hartnack, obj. 4, oc. 3.

FIG. 2.—Showing infiltration and atrophy of muscular fibres at the spreading margin. The striation of many fibres is preserved, and there are numerous dilated capillaries (*a*). Logwood and picro-carmine preparation. Hartnack, obj. 7, oc. 3.

FIG. 3.—Showing diffuse interstitial change, with destruction and atrophy of liver-cells. Logwood and picro-carmine preparation. Hartnack, obj. 7, oc. 3.

milky patch on the intraventricular septum, and the whole of the lower two thirds of one of the pillars of the mitral valve was affected by the disease. The valves themselves and their tendinous attachments had entirely escaped and presented normal appearances. Similarly the heart-muscle, where it was not infiltrated, was healthy, both to the naked eye and on microscopical examination.

At the *post-mortem* examination the points which especially arrested the attention were the extent of the disease, the peculiar colour of the affected areas, and the absence of all naked-eye traces of degeneration (caseation, &c.) and hyperæmia.

Microscopical examination of sections cut after hardening in Müller's fluid revealed the following facts:

The morbid process consists in an actively infiltrating corpuscular growth, with a marked tendency to spread along the course of the vessels and connective tissues, and giving rise to marked thickening of the endocardium wherever it becomes involved. The outer zone or spreading margin is extremely vascular. Here the nuclei are round and plump, and the matrix almost invisible. In the more central parts few, if any, vessels are met with, the nuclei are less plump and stain less readily, whilst an intermediate finely granular material is found which takes the carmine stain faintly; in other words, evidence of early degenerative changes. There is nowhere any fibrosis or any tendency to fibroid change.

The invasion of the muscular tissue is well seen at the spreading margin of each patch. The muscular fibres everywhere—even when completely surrounded by the new growth—show well-marked striation and a well-conditioned nucleus, evidence it would seem that they do not actively participate in the primary morbid process, but undergo gradual and passive atrophy from pressure and impaired nutrition. (Pl. VII, figs. 1 and 2.)

Some sections show infiltration of individual muscular fibres, and in one or two spots there was noticed an unusual coarse longitudinal fibrillation of some already partly atrophied muscular fibres.

It should be added that in the central portions of the disease-patches all trace of the normal elements has disappeared, the whole field being occupied by a densely packed nucleated tissue.

Many of the vessels in the diseased areas showed well-marked periarteritis, but no occluded vessels were met with, nor any clear evidence of endarderitis, although in one or two places appearances were met with suggesting proliferation of the endothelium.

Liver: There was slight uniform enlargement of the liver, without thickening or scarring of the capsule, or peritoneal adhesions. The surface of the cut section presented a peculiar marbled appearance, which became much more pronounced after washing.

The microscopical appearances varied considerably in different parts. There were numerous accumulations of round-cells in the neighbourhood of the portal vessels, but no portal cirrhosis properly so called. In many lobules the parenchyma was normal, whilst in the immediate neighbourhood of such healthy tracts areas of disease were met with in which the liver-cells were to a large extent atrophied and destroyed, their place being occupied by granular débris and blood-cells, in which were distributed large numbers of nuclei, either singly or in agglomerated masses. (Plate VII, fig. 3.) There was also a slight general fatty change, and in places some atrophy of the liver-cells from passive congestion. The condition closely resembled that found in some cases of diffuse inherited syphilis of the liver.

Remarks.—It is matter for regret that circumstances have deprived this case of the completeness which, in view of its great interest and comparative rarity, it should have possessed.

In attempting to arrive at a reasonable hypothesis regarding the probable nature of the disease, certain causes may at once be set aside as incompatible with the *post-mortem* appearances. Such are pyæmia, extension inwards of a rheumatic pericarditis, tubercle, leucocythæmia, and disease in the mediastinum. This practically narrows down the issue to alcohol and syphilis.

The absence of signs of arterial disease in the larger vessels and the healthy appearance of the kidneys militate strongly against the view that the change is secondary to disease of the branches of the coronary arteries, such as may occur in advanced general arterial degeneration. At the same time there is a strong probability that what there is of early portal cirrhosis and fatty change in the liver is due to chronic alcoholism, but the diffuse interstitial change met with in that organ can hardly be attributed to the same cause. Again, the undoubted similarity of the change in the two organs under consideration suggests their dependence on the same cause, and the anatomical characters of the new formation (granuloma), and the fact that both the ventricles are affected, point to syphilis as that cause.

The total absence of fibrous elements or of tendency to fibrosis is to be accounted for by the very early stage and acute nature of the morbid process. And had not sudden death cut short the disease almost in its infancy, it is not unreasonable to suppose that softening or fibrosis of the affected patches would have been likely to occur, giving rise in the one case to the gummatous myocarditis of Lancereaux, in the other to patchy fibrosis.

Literature.—Four cases are recorded in the 'Pathological Transactions' which have some bearing on that now under consideration.

In Dr. Burney Yeo's case (vol. xxvi) there is a close resemblance in the microscopical appearances. The points of difference are the following:—In Dr. Yeo's case the disease was very limited; the matrix of the granuloma was occasionally fibrillated or even fibrous. The endocardium was not implicated. The new growth was not vascular, or, to use the words of Drs. Moxon and Wagstaffe, who reported on the specimen, "there was an absence of anything like inflammatory extension; the growth, if such it can be termed, invaded the outer muscular spaces, but anything like inflammatory contagiousness was absent."

In that case, as in the present one, there was no collateral evidence of syphilis. It was recorded as an infiltrating granuloma, probably of syphilitic origin.

In vol. xxxiv Dr. G. C. Henderson has recorded a case of syphilitic gumma of the heart, in which he describes atrophy of muscular fibres without signs of degeneration. In this case the evidence of syphilis was fairly good.

In Dr. Coupland's case of congenital syphilis of the heart and liver (vol. xxvii) the infiltration process of the heart-muscle was not unlike that which I have described. And the same may be said of Dr. Cayley's case (vol. xxvi), as far at least as one can infer from the very concise account given of the microscopical appearances.

December 21*st*, 1886.

8. *Fatty tumour (lipoma) of the heart.*

By H. HANDFORD, M.D.

LIPOMA is recognised by Ziegler[1] as one of the true tumours which may attack the heart primarily. He gives no instances, but refers to Orth's 'Handbook of Pathological Anatomy,' where it is stated that small lipomata are sometimes found (subpericardially), especially towards the apex.

Schrötter, in 'Ziemssen's Cyclopædia,' 1876, says, "In the whole literature of the subject we find an account of only one lipoma embedded in the muscular tissue. This is described by Albers."

Cornil and Ranvier[2] make no mention of lipoma of the heart.

So far as I can learn, no specimen has been shown at the Pathological Society of London; and after communicating with the curators of nineteen pathological museums in different parts of the three kingdoms I can only hear of three doubtful specimens. One is No. 2911, in the museum of the College of Surgeons of England. It is a sheep's heart, and appears to be an extreme example of fatty overloading, with burrowing of the fat into the muscular substance, and its projection in places into the cavities of the heart.

Another is No. 1293 in the museum of St. Bartholomew's Hospital. It is the heart of a girl, and "embedded in the middle of the posterior wall of the left ventricle are several small masses of a yellowish, firm substance. Some of them are prominent in the cavity of the ventricle; but the largest, which is darker and firmer than the others, projects externally, and is situated at the bottom of a recess in the wall of the heart, like the sac of an aneurysm. The muscular substance of the heart is wasted around the largest mass, and a thin layer or capsule of fibro-cellular tissue invests it. The pericardium was adherent to its surface and to the adjacent part of the surface of the ventricle. The patient had for a long time before her death complained of nearly constant pain about the heart, but presented no other sign of cardiac disease. She died suddenly." The specimen is classed amongst "the tumours of uncertain origin."

The third is in the museum of Queen's College, Birmingham. It

[1] 'Text Book of Pathological Anatomy,' part ii, 1884, p. 57.

[2] 'Manual of Pathological Histology,' 1882.

is labelled "Fatty growth in the heart," but Professor Windle informs me that he considers it an example of "fatty deposition and probably infiltration of an extensive kind." [1]

In looking into the literature of the subject I can only find records of three cases, one of which is rather doubtful.

The first is by Albers, of Bonn, and is contained in 'Virchow's Archiv,' Bd. 10, p. 215, 1856. It is called a lipoma, with in places some excess of fibrous tissue in the muscular substance of the heart, and a second tumour with atheromatous contents on the bulbus aortæ. The specimens were taken from the body of a man, aged 77, whose clinical history was unknown. The heart was somewhat atrophied. The two layers of the pericardium were firmly adherent for a space of about two inches near the apex of the left ventricle. When this adhesion had been separated by the knife a tumour the size of a hen's egg was discovered beneath embedded in the muscular substance, and rising about three and a half lines above the surface, so as to form a projection, readily noticeable through the pericardium. There was no capsule, but the growth was sharply limited from the surrounding muscular substance, a layer of which, about a line in thickness, separated the growth from the cavity of the ventricle. The growth was yellow on the surface, but rather whiter on section; to the touch it was quite firm. There were several "milk spots" on the surface of the heart.

On the aorta, just below the origin of the innominate artery, was a second growth, covered by the pericardium, and extending down towards the heart, but not adherent to it. In appearance it was yellow and resembled the growth in the ventricular wall, but it was somewhat softer, and in the centre contained some atheromatous material.

The microscopic examination of sections of the larger growth (*i.e.* the one in the ventricular wall) showed that it was quite

[1] I append the list of museums, the curators of which have most courteously replied to my inquiries: The College of Surgeons of England, Guy's, St. Bartholomew's, St. Thomas's, University College, the London Hospital, St. George's, the Middlesex, St. Mary's, Charing Cross, Edinburgh University, the College of Surgeons (Edinburgh), Trinity College (Dublin), the College of Surgeons of Ireland, the Owens College (Manchester), Queen's College (Birmingham). I have also been reliably informed that no specimen is mentioned in the catalogues of the two museums in Glasgow. Professor Hamilton tells me there is no specimen in the museum of the University of Aberdeen; and Professor Roy that there is no specimen at Cambridge.

sharply separated from the muscular substance, and that there were no muscular fibres in the tumour, which consisted in greater part of fat-cells, with, however, an excess of fibrous tissue. The smaller growth on the aorta was of similar character. It was quite clear that the growth in the ventricular wall was a genuine lipoma, and could not in any way be considered as an instance of fatty overloading of the heart, in which, as occasionally happens, the fat had burrowed between the fibres of the muscular walls.

The second case is also from 'Virchow's Archiv,' Bd. 42, p. 534, 1867, and is contributed by Gernet. It is called "A case of infectious lipoma." The nature of this growth is doubtful, and the description corresponds more, in most respects, with a sarcoma. The patient was a woman, aged 46, who had had a swelling on the left thigh, near the external condyle, for five or six years or longer. She died a few days after the removal of this growth, which was encapsuled, and was white and vascular on section. There was a secondary growth the size of an apple in the left psoas muscle. It presented the same character as the primary growth.

There were also two secondary growths in the heart, which was of normal size, with muscular walls of average thickness, but with a large amount of subpericardial fat, which was unequally distributed. In the septum, between the ventricles and projecting into the right ventricle, was a growth the size of a pigeon's egg, white in colour, and of somewhat hard consistence. The second of the two growths in the heart was on the outer surface of the right ventricle, between the anterior wall of the aorta and the lowest part of the left side of the right auricle. It was of irregular shape, and consisted of an accumulation of fat in the tunica adventitia of the aorta. It was connected with the pericardial fat, and displaced inwards somewhat the muscular substance of the right ventricle. Microscopic examination showed the primary growth to consist largely of fat-cells, with, in addition, fibrous tissue, spindle-cells, and cells with many processes.

The growth in the psoas had a similar structure, but showed less fibrous tissue.

The growth in the septum ventriculorum presented the same appearance, but the connective tissue was in greater proportion.

The growth on the front of the aorta was of the usual yellow colour of fat, and the cells resembled ordinary fat-cells.

The growth on the thigh was not considered to be a lipoma at the time of operation, and the white medullary appearance on section suggested that it was a sarcoma. Notwithstanding this the microscopic examination left no doubt that the greater part of the growth consisted of fat-cells, and the author considered the most suitable name for the growth to be a medullary lipoma.

The third case is recorded by Dr. Banti in 'Lo Sperimentale,' Tom. lviii, September, 1886. The patient was a woman, aged 52, with very abundant panniculus adiposus, who died of general paralysis of the insane in May, 1886. The heart was examined several times, the last occasion being a few days before death. There was no evidence of increase of size; there was no murmur, and the sounds were clear; the second sound in the aortic region was accentuated. There were never any symptoms referable to the heart.

At the necropsy the heart was of normal size, and was covered with a layer of fat, which attained its greatest thickness, viz. 4 to 6 mm., on the anterior surface of the right ventricle. On opening the heart in the usual manner there was seen on the posterior wall of the right auricle a rounded tumour of yellow colour, and as large as a cherry. It was situated between the tricuspid orifice and the opening of the inferior vena cava. The base was somewhat contracted, but the growth could not be said to be pedunculated. The surface of the tumour was smooth and shining, regular, and translucent (*non opaca*). The new growth was attached to the wall of the auricle, and could not during life have interfered with the free course of the blood through the auriculo-ventricular orifice. The visceral pericardium corresponding to the attached surface (base) of the tumour was thickened and opaque, and several small points of adipose tissue could be seen in it. The rest of the heart —cavities, valves, and muscular substance—was normal. Exact measurements of the size of the openings and the thickness of the walls are given. The coronary arteries had their walls thickened and somewhat rigid, but nowhere calcified, and their lumen was not encroached upon. After careful search no other tumours could be found in the body.

Microscopic examination showed the tumour to consist of fat-cells supported by a framework of fibrous tissue, which was not excessive in amount. There were no muscular fibres in the growth, and the division between the tumour and the muscular substance

was sharp and clear, though there was no distinct capsule. The author considered the origin of the tumour to be the subendocardial connective tissue. It was specially noted that the tumour could not have been a growth inwards of the subpericardial fat, for this was not very abundant over the auricle, and, moreover, a layer of muscular tissue intervened between the tumour and the subpericardial fat.

Such is the literature of the subject so far as I have been able to ascertain it. The extreme rarity of fatty tumour of the heart must then be my excuse for bringing before you a specimen which has unfortunately been very much damaged before it came into my possession. Such as it is I show it; and I do so with the greater confidence because I had an opportunity of seeing and examining it when it was quite recent, and I can therefore vouch for the accuracy of a good deal of the description. I did not see the patient during life nor was I present at the necropsy, but am indebted for the description of the patient, the account of the necropsy, and the opportunity of showing the specimen, to my friend, Mr. Evan Powell, Medical Superintendent of the Nottingham Borough Asylum.

The patient was a woman aged 76, admitted in November, 1884, for acute melancholia. The heart-sounds were clear though feeble. She died November 26th, 1884, during sleep, apparently from failure of the heart's action.

Necropsy eight hours post mortem.—A fair but not excessive amount of subcutaneous fat. No fatty tumour or excess of fat anywhere except round the heart, which was large and flabby, and had an excess of fat overloading the surface. The right auricle and ventricle were dilated and full of recent clot; the left auricle and ventricle contracted and empty. The muscular substance of the heart was very pale and of a yellowish colour—it felt greasy and looked streaky to the naked eye. In the interauricular septum was a hard, round substance about the size of a small pigeon's egg. It was distinctly limited but had no definite capsule. When cut it had all the appearance of an ordinary fatty tumour.

The heart weighed 14 oz., the valves were all much thickened, especially the mitral and tricuspid. The arteries were much degenerated. The liver was fatty; the gall-bladder full of stones. All the other organs were apparently healthy.

Unfortunately the heart was not preserved, but only the tumour

with a portion of the interauricular septum.[1] I saw the specimen a few days later and there could be no doubt of the distinctness of the growth or of its fatty nature. From the appearance of the tumour, from its position in the septum between the auricles, and from the observation of Mr. Powell at the necropsy, I entertain no doubt that it is not an instance of the burrowing inwards of the subpericardial fat. A microscopic examination shows that the tumour consists of fat-cells with a few degenerating muscular fibres scattered here and there.[2]

The tumour probably originated in the intermuscular connective tissue, and its growth was facilitated by the fatty disintegration of the muscular fibres which provided pabulum, which was stored up locally instead of being taken up into the general circulation and then deposited. It was not simply a fatty disintegration of the auricular wall; there was increase of thickness and a distinct tumour indicating new growth, and a storing up of fat. In true fatty disintegration the fatty particles, when set free, are taken up chiefly by migratory leucocytes and partly by the small blood-vessels and by the lymphatics.[3] Reactive inflammation begins, and ultimately fibrous tissue develops from the granulation tissue built up by the leucocytes, and perhaps by the multiplication of the fixed tissue-cells of the surrounding parts. In this way the connective-tissue basis of a lipoma might be produced, and the fatty infiltration of it would be facilitated by the abundance of fatty particles in the immediate neighbourhood.

January 18*th*, 1887.

Note.—It is possible that the white appearance of the fatty growths in Gernet's case may have been due to a fatty degeneration of a lipoma.[4] "To the naked eye the tissue is then opaque, grey in colour, and of a peculiar consistence, resembling that of a sarcoma or carcinoma undergoing fatty degeneration."

[1] Before it came into my possession the preparation was allowed to get dry and was much spoiled.

[2] A microscopic section of the tumour was shown.

[3] 'Ziegler,' vol. ii, p. 46, 1884.

[4] Cornil and Ranvier's 'Pathological Anatomy,' vol. i, p. 171, 1882.

9. *Right-sided malignant endocarditis.* (*Card specimen.*)

By W. Hale White, M.D.

Charles L—, aged 39, a wheelwright. Family history and personal history unimportant. He first felt ill four months ago, when he began to have attacks of giddiness; these gradually became more severe, and finally assumed the form of definite rigors, coming on at no particular time, and being separated by an interval varying from one to three days. On admission he was pale and anæmic looking, and had a basic systolic bruit heard only over the pulmonary area; there were a few pus-corpuscles in the urine, which contained one tenth albumen; there was a large patch of choroidal atrophy in one eye. He was in the hospital fifteen days before his death. During this time he gradually got weaker and weaker; the rigors continued, the temperature at times reaching 105°. Quinine, thallin, and antipyrin were used as antipyretics, the last with most advantage. A few moist sounds developed in the lungs. The basic murmur remained loudest over the pulmonary area, and was definitely conducted more up towards the left than in any other direction, therefore the diagnosis of malignant endocarditis of the pulmonary valve was made. There was a faint functional systolic apex-bruit.

Post-mortem examination.—The pericardium contained a little clear fluid. On inspection it was evident that the right ventricle was hypertrophied and dilated. There were friction patches on both ventricles. The mitral and aortic valves were a trifle thick but quite competent. There was an old firm ovoid mass of vegetation, with a slightly calcareous layer on the surface, projecting into the pulmonary artery from the left portion of the right anterior pulmonary valve. It was whitish in colour, and had adherent to its extremity a *post-mortem* clot which extended into the pulmonary artery. There was no evidence of recent acute inflammation about this mass. It was one and one eighth inches long and half an inch thick, and narrow towards its free end; recent clot joined it to the left valve. The right part of the right anterior valve was thickened, and this thickening extended below the attachment of the valve, which was ulcerated where it joined the arterial wall; by this ulceration an aperture was formed

through which a No. 12 catheter could be passed. The left anterior valve was thickened, but not elongated; it was partially ulcerated at its attachment to the artery. Wherever the vegetation had come in contact with other valves it had caused erosion. Except that the liver was fatty and the spleen enlarged, weighing 20 oz., the whole of the body was healthy.

It is to be noted that there had been recently two other cases of malignant endocarditis at Guy's Hospital.

December 7th, 1886.

---

10. *Endocarditis with necrosis of the mitral valve.* (*Card specimen.*)

By F. Charlewood Turner, M.D.

The heart of a sailor, aged 22, with the mitral orifice stenosed. On the auricular surface of the left extremity of the smaller curtain of the mitral valve there is an adherent mass of fibrinous coagulum, with a base about the size of a fourpenny piece, which is of an ashy grey colour, and where its edge has been separated from the valve beneath, this is seen to be of the same colour, and partly disintegrated. The ventricular surface of this area is dull and ashy grey, but without roughening or deposit. The auricular surface of the larger curtain contiguous to the mass of vegetation is similarly dull and discoloured, and the ventricular surface of the flap in this situation is covered by a layer of fibrin, and discoloured and in a state of commencing disintegration, as beneath the layer of coagulum. The valvular tissue is greatly thickened at this part. The necrotic area does not reach the free edge of the valve.

There is fibrous thickening of the corpora Arantii of the aortic curtains, but there are no recent granulations on either valve.

The specimen was obtained from a well-developed and fairly nourished Swede, who was brought to the London Hospital from a sailors' home after a few days' illness, and died the second day after admission with symptoms of septic blood-poisoning.

The endocardium and lining membrane of the aorta were deeply

stained. The pericardium over the auricles was studded with small fibrous nodules. The lungs were congested and œdematous. On section of them numerous areas of deep injection were seen, slightly elevated and of increased consistence, but no points of suppuration. The mucous membrane of the trachea and bronchi was deeply injected. The spleen was much enlarged, weighing 18¾ oz., and its tissue softened. There was a wedge-shaped necrotic tract in it. The kidneys were rather large, their surface smooth and stippled with points of vascular injection. There was some seropurulent fluid at the base of the brain, none over the cord. In the right epididymis was a small collection of pus.

May 17*th*, 1887.

---

11. *Aneurysm of the mitral valve in a child.*

By W. B. Hadden, M.D.

The patient was a female child, aged 2 years and 3 months. The father was a sailor, and said to be quite healthy. The mother had had seven children, five of whom were alive. One of the other two died of phthisis. There was no history of syphilis or acute rheumatism in the family. The child herself had never had rheumatic fever, nor, indeed, any definite illness She was said to have become blue in the face at times.

On January 7th of the present year the child became feverish and began to cough. She was brought to St. Thomas's Hospital in the evening of that day, and was seen by the house physician, who found the signs of bronchitis. No cardiac murmur was heard. The patient seemed to be going on well until the evening of January 9th, when she suddenly became worse. She was at once brought to the hospital, and died in the casualty room.

At the *post-mortem* examination I found much blood-stained mucus in the larynx and bronchi. There was extensive bronchopneumonia, and in the upper part of the right lower lobe a small, yellow, caseous mass was found, but no miliary tubercles. The other organs were healthy except the heart. Both auricles and the right ventricle were dilated and hypertrophied. On the posterior

flap of the mitral valve there was an aneurysmal sac, bulging forwards and to the left, the convexity being towards the auricle. The diameter of the aneurysm was half an inch. There was a rounded perforation near the centre, and the edges of this perforation, on the auricular aspect, especially below and to the left, were fringed with pale, firm vegetations. The aneurysm did not extend quite up to the free edge of the valve. The anterior flap and the chordæ tendineæ were quite healthy; the other valves were normal. The only points of interest in the case are the early age of the patient and the apparent absence of any exciting cause. I think it is clear that there had been a localised endocarditis, but whether this arose during intra-uterine life or after birth I cannot say. I have brought the case forward simply with the view of eliciting information as to the etiology of the affection. *February 15th*, 1887.

---

12. *Stenosis of mouths of coronary arteries; anginal symptoms. (Card specimen.)*

By Harrington Sainsbury, M.D.

The heart was found diastolic and flaccid. In the right auricle a small quantity of dark, feebly clotted blood; right ventricle nearly empty; left auricle moderately filled with dark, soft clot; left ventricle nearly empty; valves on both sides healthy. In the aorta, just above the semilunar valves, a ring of gelatinous-looking atheroma involving mouths of coronaries; of these, the posterior just admits a fine bristle; the anterior is also much contracted. Main trunks of both coronaries of normal calibre and healthy appearance. Walls of left and right ventricles of normal thickness; no macroscopic fatty changes.

Microscopically, numerous, very granular fibres with disappearance of the cross striæ; but in the majority of fibres striation was well preserved.

The patient applied at the Royal Free Hospital on July 6th, suffering from thoracic pain of anginal character. On August 30th, after an absence of more than a month, he returned and whilst

being questioned fell forwards, complaining of great pain in the back. Death occurred in from one to two minutes.

December 7th, 1886.

---

13. *Aneurysm of aorta (transverse part of arch) rupturing into the œsophagus; no previous œsophageal symptoms. (Card specimen.)*

By H. Handford, M.D.

Specimen taken from a man, aged 34, a waterman, who was admitted into the Nottingham General Hospital, under Dr. Ransom, in August, 1886.

Earliest symptom was loss of voice eight months previously. On admission he had an almost incessant "brassy" cough, great dyspnœa, but no pain or difficulty in swallowing, and no vomiting. His face was very cyanotic, and he used to lie most comfortably well over on the left side with the left arm extended, and resting on the elbow. Right radial pulse visible but small. Absence of pulsation in left radial and brachial. Visible pulsation in episternal notch. Apex-beat in sixth space in nipple line; no murmur; no pulsation or dulness attributable to the aneurysm to be detected on the chest wall.

On August 15th, at 11.30 p.m., smart hæmorrhage from nose and mouth.

August 16th, at 3 a.m., *i. e.* three and a half hours later, passed about two pints of blood by bowel. At 1.30 p.m. again passed blood by bowel. At 2.30 p.m., *i. e.* fifteen hours after first hæmorrhage, free hæmorrhage from mouth and nose, and speedy death.

Necropsy twenty-four hours post mortem.—Pericardium contained 1½ oz. of clear fluid; cavities of heart empty, walls contracted; aortic valves competent; first part of aorta moderately atheromatous, no calcareous plates. Œsophagus distended with blood-clot so as to resemble a sausage. Stomach greatly distended; weight, with contents, 4 lbs. 6½ oz. It contained a huge blood-clot; weight of stomach, when emptied and washed, 7 oz. The intestines contained about two pints of dark fluid blood. The first and second

parts of the arch of the aorta were somewhat dilated. In the middle of the posterior wall of the transverse arch was an irregular rounded opening with smooth margins, about one inch in transverse diameter and one and a half inches in vertical, leading into a cavity that would contain a walnut. The innominate artery was unaltered in its origin and course. The left carotid arose from the dilated aorta, but quite free from the saccular aneurysm. At a distance of one and a half inches from the aorta its lumen was patent and of average size, but at its origin the opening was reduced to a small, elongated, oval slit. The left vertebral arose from the aorta; at its origin it was closed with old blood-clot; half an inch along its course its lumen was only half obliterated. The left subclavian arose from the dilated aorta half an inch anterior and superior to the upper margin of the orifice of the saccular aneurysm; it was thus quite free from the aneurysm. Nevertheless, at its origin the lumen was reduced to the size of a small pin's head. The margins were thick and sclerosed, smooth, and not covered by clot. The small orifice led into a canal about half an inch long, above which point the artery was closed with firm fibrous tissue.

The saccular aneurysm had pressed upon the trachea one and a half inches above the bifurcation, and had diminished its calibre by one third. The interior of the aneurysm was empty, except at its posterior part, where an irregular clot plugged an opening one inch by one and a quarter inches, leading into the œsophagus about one inch before it crosses the left bronchus.

January 18*th*, 1887.

---

14. *Aneurysm of arch of aorta rupturing into pericardial sac.* (*Card specimen.*)

By J. F. Goodhart, M.D. for A. Withers Green.

The aneurysm seems to have grown downwards, and ruptured on its posterior surface. The pericardium was full of blood. The heart is hypertrophied, and there are only two aortic valves. It comes from a young man, aged about 35 years. He was doing his work as usual, and was not known to be ill, except that he

complained sometimes of shortness of breath. His death was quite sudden. He was known to drink freely, but was not known to have had syphilis. His occupation was carriage or cart driving.

March 3rd, 1887.

---

15. *Aneurysm of arch of aorta communicating with superior cava.* (*Card specimen.*)

By G. Gulliver, M.B.

The arch of the aorta is much dilated and diseased. At the top of the ascending part is a circumscribed aneurysmal dilatation, which communicates with the superior cava by a circular aperture of the size of a goosequill. The left internal jugular is entirely closed by clot, and the innominate at its termination has its lumen entirely obliterated by pressure from the aneurysm, and its opening into the superior cava is quite invisible. The latter vessel is elongated, being stretched by the aneurysm.

May 17th, 1887.

---

16. *Spontaneous cure of thoracic aneurysm in anæsthetic leprosy.* (*Card specimen.*)

By Beavan N. Rake, M.D. (Trinidad).

Louise K—, a German, was admitted into the Trinidad Leper Asylum on November 9th, 1886, with anæsthetic leprosy of several years' duration and recent pneumonia. She had been a hard drinker. She died November 14th. The necropsy showed a sacculated aneurysm springing from the ascending and transverse aorta. It was slightly flattened against the manubrium, which it had eroded to the extent of one third of an inch. It was three inches in diameter, and was filled with regular layers of distinctly laminated clot. This was breaking down into grumous débris near

the centre. The opening into the aorta was filled with two rounded bosses of fibrin. The aorta was covered with small patches of atheroma.

There was advanced grey hepatization at the left base, the lung being sodden with pus. There were firm pleuritic adhesions on the right side. The other viscera were healthy. The fingers were short and incurved, and there was an ulcer on the left foot. There was an abscess over the right wrist and swelling and redness of the right leg.

It seems a fair question whether the leprosy had anything to do with the cure of the aneurysm. Danielssen and Boeck ('Traité de la Spédelskhed,' pp. 296, *et seq.*) and Hillairet ('Ann. de Dermat. et Syphilog.,' Tome v, No. 3) in eleven analyses of the blood in anæsthetic leprosy, found the fibrin increased from ·2 to ·3, ·4 and ·6 per cent.

I have not been able to find any record of aneurysm co-existent with leprosy. *December* 21*st*, 1886.

---

17. "*Macro-angiosis*" *of left upper extremity.*

By Richard Barwell, F.R.C.S.

William A—, aged 21, admitted into Albert Edward Ward under my care 9th March, 1886. He had had a wound about six years ago on the index of left hand, which had bled profusely, but under Mr. Bryant's care had healed. Three weeks before admission he knocked the scar slightly; it ulcerated, then scabbed over. A few minutes before admission he brushed the scab off, and a profuse hæmorrhage set in, which he partly controlled by compressing the brachial at the bend of the elbow. As soon as this pressure was in any way relaxed blood spurted out seven or eight inches in a stream, said to be the size of the little finger. No tourniquet nor the Esmarch cord suppressed the hæmorrhage. Bandaging each finger separately and elevation only restrained it. It could only be suppressed by binding a firm pad in the palm, with the fingers flexed over it, and raising the limb

perpendicularly. In about twenty-four hours signs of approaching gangrene were noticeable, yet on the least relaxation of the pressure bleeding was copious, nor would any other position avail.

13th.—As the gangrene was spreading to other parts of the hand, and no control of the bleeding save by the local pressure appeared possible, I determined to amputate, but, fearing that I might cut into a plexus of vessels which would bleed the man to a dangerous extent before they could be secured, I first tied the subclavian. The parts over that vessel were quite healthy, nor did the artery appear to be in any appreciable degree enlarged.

The man did perfectly well. The specimen is here, and I hand round some photographs taken a few hours before the limb was removed.

Clinical conditions.—The veins of the arm and forearm were enormously enlarged and tortuous. Each of these pulsated strongly, both to sight and to touch; they also thrilled with very well-marked fremitus; but there was no buzz or hum (*frémissement cataire*). On placing the ear to the largest vein at the bend of the elbow a murmur could be heard, and the heart-sounds, more especially the second, were very distinctly audible.

All the arteries were large; the pulse of the brachial occupied so broad a space that it was deemed to be not a single artery but to have divided into a plexus. The radial at the bend of the wrist seemed excessive; the ulnar appeared not so exaggerated. The whole palm pulsated, and pressure on the vessels at the wrist only mitigated the pulsation.

The limb was not discoloured, neither were there anywhere on the surface nævoid angiomata. There was no hypertrophy; the skin was normal in all ways, neither was there any of that exaggeration of papillæ and of hair growth which so generally accompanies interparietal communications between the arteries and veins.

This case acquires additional interest from the fact that it can be traced back a good many years. The condition was congenital, but there is no record of any injury or of hæmorrhage until he was fourteen years old, when he scratched an itching part of his finger, an ulcer formed, and on attaining a certain depth bled profusely. He came under the care of Mr. Bryant (1879), who succeeded in checking the bleeding by bandaging each finger separately and elevating the limb. He subsequently mentioned the case in the fourth edition of his 'Manual of Surgery,' vol. i, p. 520, as a

case of arterio-venous aneurysm, "in which the seat of communication was about the axilla. The boy, aged fourteen, was admitted under my care in 1879 for bleeding from an open ulcer on his left index finger, the ulcer having followed an injury eighteen months previously. The injured finger was spongy from vascular tissue, and the palm of the hand had the appearance of cutaneous nævus. The veins of the whole limb were unusually distended and thrilled very remarkably; the buzzing murmur generally present in these cases was very characteristic."

It will be remarked that there are several points in which the case had become modified between the time when Mr. Bryant saw the boy in 1879 and when I saw him seven years afterwards. The arm is amputated six inches above the elbow-joint. Throughout the part now shown there is no interparietal communication between artery and vein. The first striking appearance is the enormous dilatation of the superficial veins; this chiefly affects, in the dissection, the cephalic system; but I fear there must have been an error, because in the photograph the veins on the inner side of the arm are much enlarged; they appear not to have taken the injection, for there is a comparatively small basilic severed about the middle of the arm. Above this and all about the inner condyle is a mass of very large veins. All the cephalic system of veins is enormous in size; the veins at the back of the hand, about the size of a cedar pencil, pass across the back to the outer side and front of the forearm; they gather at the bend of the elbow into two great vessels, which cross the lower part of the upper arm to its inner side. The largest of these is about the size of a common iliac vein; the smaller ones, lower down, vary, but none are less than the axillary at its lower part. The venæ comites are not abnormally large. There is a very remarkable venous plexus on the median nerve, just above the wrist.

The brachial artery is at least as large as a normal common iliac; it is so contorted that in its S-shaped curve the sides of the bent vessel are almost in contact. Of its two branches the ulnar is the larger; the recurrents are bigger than a normal ulnar artery. The muscular branches also are enormous, and the muscles are crowded with exaggerated capillaries. There is a small aneurysm-like enlargement on the radial, just at the giving off of the superficialis volæ; that vessel and the branches from the ulnar that form the superficial palmar arch are very large and tortuous. A contorted

and serpentine arrangement of big arteries is found on the inner side of the ulna, just above the wrist.

This evidently is not an example of either aneurysm varix or of varicose aneurysm; the conditions during the life of the limb, the large size of the arteries below any possible place of communication, together with absence of thickening in the venous coats, negative any such assumption, whereof no anatomical proof exists. Neither is it a cirsoid aneurysm, for it lacks that close intimate inosculation of enlarged contorted arteries and veins characteristic of that condition. There are two singular vascular plexuses, but one is made up entirely of veins, the other solely of arteries; they both occupy a relatively small portion of the limb, the affection of which is general, involving the whole extremity.

As far as my knowledge goes, this specimen is *sui generis*, not only as regards the size of the vessels, but in the coincidence of this vascular enlargement with the absence of hypertrophy. I called the specimen in the advertised announcement "cirsoid aneurysm" for want of a term sanctioned in pathology; but that term does not describe the condition; indeed, it is misleading, and the only name which appears fitting and applicable to the case is *macro-angiosis*.

March 3rd, 1887.

---

18. *A case of syphilitic arteritis.* (*Card specimen.*)

By Seymour J. Sharkey, M.B.

[With Plate VIII.]

E. C—, aged 25, was admitted into St. Thomas's Hospital under the care of Dr. Harley on March 22nd, 1886, and died two days after.

She has been married four years, and had had two miscarriages. Two or three months after marriage she had a sore-throat and an eruption on her body. In 1883 she had been under Dr. Harley's care for pelvic cellulitis.

During the three months preceding her admission into hospital she had had slight attacks of loss of speech and numbness in right

leg lasting for a few minutes. When she woke on the morning of March 15th she found that she had lost power over her right side, and could not speak or control her evacuations.

On admission she was suffering from right hemiplegia and aphasia. Temperature was 102·4° F., respiration 56, pulse 136. The pupils were equal and acted well to light. No oculo-motor paralyses, no loss of consciousness. Sensation impaired on affected side, but not lost. Urine normal. The temperature was always above the normal (101° F. to 103° F.), and finally reached 105° F. and 106°.

Post-mortem examination.—Body well made and well nourished. Heart healthy.

Lungs much congested in dependent parts, and semi-solid owing to broncho-pneumonia.

Spleen, kidneys, liver healthy.

The left ovary was attached to a cyst of the size of a largish marble, which contained clotted dark-red blood, and had originated in the substance of the ovary.

Brain much congested. Dura mater healthy. Pia mater at base generally somewhat thickened and milky looking, the opacity being due to old disease. The left hemisphere was distinctly softer than the right, though not very soft. The right middle cerebral artery was opaque white, somewhat thickened and tortuous, but not the seat of marked disease. The left, at the spot where the first branches come off, was quite hard, and firmly adherent to the walls of the fissure of Sylvius. On section a dense, pale pink thickening of the intima was seen, which had all but completely obliterated the lumen of the vessel. The left nucleus caudatus and nucleus lenticularis were altered in colour, though not much in consistence; they were opaque yellow, and brilliantly mottled with red vessels.

Microscopical examination.—The left Sylvian artery presented the following changes. The external coat was somewhat thicker than normal, but apart from a slight excess of nuclei there was no evidence of active changes going on in it. The middle coat was unaltered. The brunt of disease had fallen upon the intima causing great thickening; the latter was unsymmetrical, being greater at one part of the circumference of the vessel than at others. The endothelium could be seen limiting the intima towards the lumen of the vessel. The space between the endothe-

lium and the internal elastic lamina was occupied by new, ill-developed connective tissue. Just below the endothelium the latter was more fibrous than elsewhere, and the nuclei were longer. Towards the internal elastic lamina it assumed a more indefinite appearance consisting of a network of a hyaloid-looking material, the meshes of which were small, and occupied by roundish nuclei. The trabeculæ here, on the contrary, were broad. These changes are seen in Plate VIII, fig. 1, which represents the earlier stages of the process. Where the latter is more advanced (fig. 2) the whole new growth is fibrous. In a still later stage the new growth presents signs of caseation which affects the whole wall of the vessel; the internal elastic lamina then swells and gets irregular in appearance.

In vol. xxxiv of the 'Pathological Transactions' I recorded a case of syphilitic arteritis affecting the middle cerebral artery, and presenting changes which were most marked in the external coat. In the present instance the disease affects mainly the intima, and this appears to be the commoner condition of the two.

January 18*th*, 1887.

DESCRIPTION OF PLATE VIII.

To illustrate Dr. Sharkey's paper on Syphilitic Arteritis. (Page 124.)

FIG. 1.—Showing enormous thickening of the intima, and a lesser degree of the external coat.

a. Lumen of vessel, lined by endothelium.
b. Internal elastic lamina.

FIG. 2.—Showing almost complete obliteration of the vessel by the growth of intima.

a. Thickened intima.
b. Internal elastic lamina.
c. Middle coat.
d. Thickened external coat.

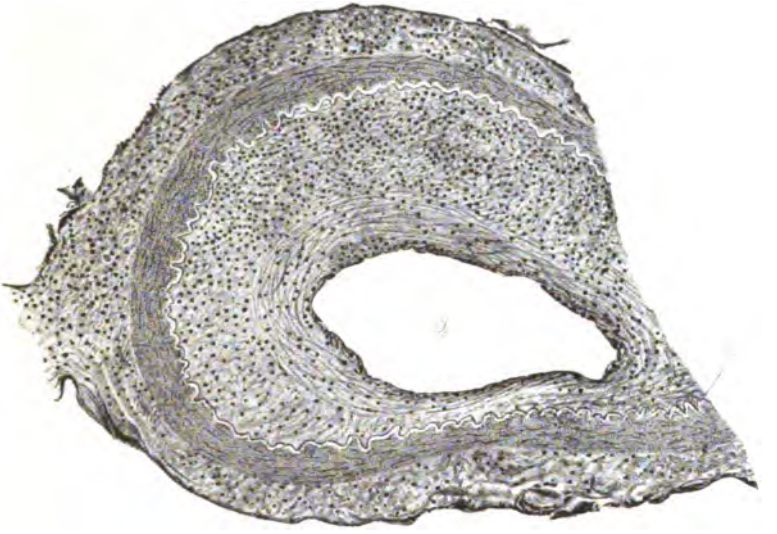

Fig 1

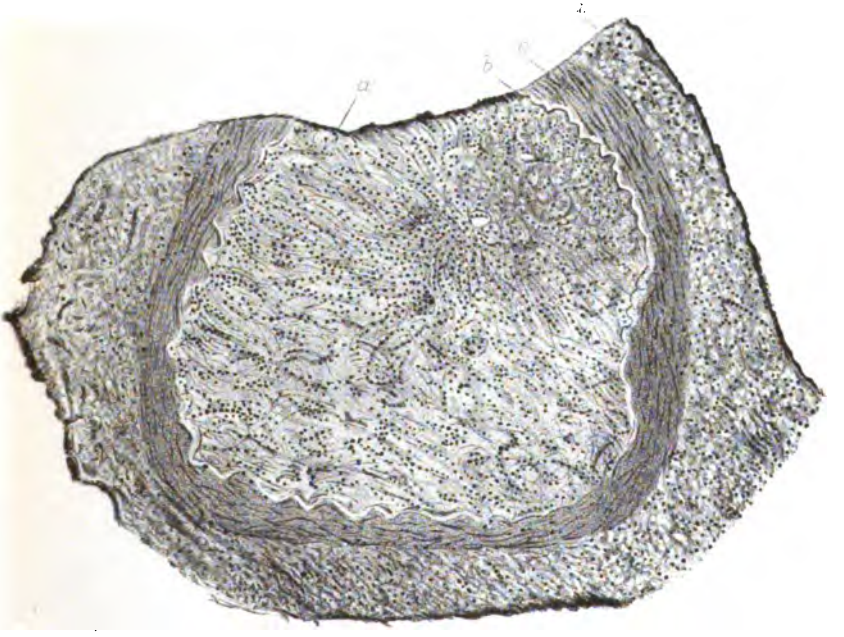

Fig 2

M. H. Lapidge del.

Lamb sc. & lith.

IV. DISEASES ETC., OF THE ORGANS OF DIGESTION.

1. *Ulcerative stomatitis in a child; miliary tuberculosis.*

By Jonathan Hutchinson, jun.

In the 'Lancet' of May 1883, Messrs. Lingard and Batt described micro-organisms (long bacilli forming bundles and staining well with magenta), which were found freely present in cases of ulcerative stomatitis of calves. They found the same appearances in a case of noma or cancrum oris. Since children affected with ulcerative stomatitis nearly always recover, the present case was reported more because it gave an opportunity for the study of the nature of the ulceration than because of the connection with tuberculosis, which seems to be a rare complication. The specimens were obtained from a child who was admitted, under Dr. Stephen Mackenzie, into the London Hospital in an exhausted condition, dying two days after admission. At the age of twelve months she had had measles, and subsequently ulcers formed along the alveolar margin, causing loss of several teeth from the lower jaw, and invading the adjacent surface of the lower lip. She became very cachectic, and died nine months after the occurrence of measles.

Sections showed that for a considerable depth below the sloughy surface the tissues were in a necrotic condition, the muscular fasciculi of the lip being matted together, and the cells and other elements of the gum being rendered very indistinct. In this layer were found micrococci in considerable numbers; they were quite evident in the deeper part due to the inflammatory cell effusion which marked the limit of the necrosis. Tubercle bacilli were sought for but were not found, nor was there any resemblance to the appearance described by Lingard, already referred to. This fact, together with the clinical evidence that ulcerative stomatitis in children never seems to pass on into noma, would point to the two diseases being quite distinct. Both, however, occur, as a rule,

in early life, and they both frequently follow measles or scarlet fever.

It is worthy of note that Bergeron states that he has inoculated himself from a case of ulcerative stomatitis in a child.

In the present case the peritoneum and abdominal viscera were studded with miliary tubercles, most of them one tenth of an inch in diameter. Microscopical examination showed the presence of giant-cells and bacilli; the tubercles appeared to be of very recent origin, only a few showing slight caseation.

Although it is possible that tubercle infection occurred through the ulceration of the mouth, it seems equally probable that the two diseases had no direct connection, as I can find hardly any cases recorded having a similar ending. *April 5th*, 1887.

---

2. *Stricture of œsophagus; secondary growths in lung.* (*Card specimen.*)

By H. Handford, M.D.

The specimen was taken from a man, aged 59, who was admitted into the General Hospital, Nottingham, July 7th, 1886, under my care, complaining of a difficulty of swallowing. Thirty-nine days previously inability to swallow solids or liquids came on suddenly. The previous day he could swallow as well as usual. An obstruction was found eight and a half inches from the teeth, and a No. 4 gum elastic catheter was passed through it, by means of which he was fed. Later no instrument could be passed, and on July 29th gastrostomy was performed by my colleague, Dr. A. C. Taylor. The patient died on the ninth day after the operation, a little more than ten weeks after the commencement of symptoms.

Necropsy twenty hours post mortem.—Marked button-hole mitral constriction. (There had been no murmur during life.) In the lower lobe of the left lung two whitish secondary deposits, each about the size of a small chestnut. (N.B.—The lymphatics of the œsophagus anastomose with the pulmonary lymphatics.) In the œsophagus, about two inches from the cricoid cartilage, was a tight stricture involving the whole circumference and admitting a probe with difficulty. Length of stricture one and three quarter inches,

surface rough but not papillomatous. Second growth, flattened, and with a smooth surface, about one and a half inches long, on the right side of the pharynx, extending from the corner of the hyoid bone down to the œsophagus. Beneath the first part of the sternum, the trachea, œsophagus, and the vessels of the neck were matted together by an infiltrating growth in which enlarged lymphatic glands were embedded.

There was no general peritonitis, and the opening in the stomach was firmly united to the abdominal parietes.

On microscopic examination the growth had a marked alveolar structure, the cells were of the squamous epithelial type, and there were very numerous "cell-nests." The secondary deposits in the lung were more richly cellular and contained no "cell-nests."

January 18*th*, 1887.

---

3. *Broncho-œsophageal fistula consequent upon malignant growth (squamous epithelioma) of œsophagus; Meckel's diverticulum in the same subject.* (*Card specimen.*)

By H. Handford, M.D.

Specimen taken from a man aged 34, a butcher by trade, admitted under my care into the Nottingham General Hospital in April, 1886, complaining of cough, sickness, and pain about the level of the diaphragm on both sides. Symptoms began eight months previously. Patient had marked signs of lung disease on both sides. He never complained of any difficulty in swallowing, but said that frequently during a meal he began to cough, and then vomited. On such occasions he undoubtedly brought up food from the stomach, and not only what had collected in the œsophagus. More frequently than not he completed his meal without cough or sickness. He died of inanition July 31st, 1886. At the necropsy, twenty-four hours *post mortem*, in both lungs was found extensive pneumonic consolidation, due in great part to the irritation of foreign particles (food). There were also scattered caseous nodules. The œsophagus was constricted where it is crossed by the left bronchus. The stricture would not quite admit the tip of the little finger.

There was a rounded opening about a quarter of an inch in diameter, with smooth margins, opening into the left bronchus half an inch from the bifurcation of the trachea. Length of œsophagus (after five months hardening in spirit) eight and a half inches; width, when laid open just above the stricture, two and seven eighth inches; width, just above cardia, two inches nearly. Length of strictured portion three inches; surface rough and papillomatous. Some of the polypoid excrescences were one inch long. Fistulous opening one inch from commencement of stricture, which began three inches below cricoid cartilage and terminated two and a half inches above cardia.

Nature of growth:—Epithelioma. There was slight glandular enlargement between the trachea and œsophagus, and along the lesser curvature of the stomach. There were no secondary growths. The stomach was unaffected.

In the small intestine, thirty-five inches from the ileo-cæcal valve, was a diverticulum (Meckel's) about one and a half inches long.

January 18*th*, 1887.

---

4. *Retro-œsophageal abscess.*

By H. H. Clutton.

On Monday, September 14th, 1885, a man, aged 24, was admitted under Dr. Gulliver into St. Thomas's Hospital, with the following history and symptoms:

He had been subject to epileptic fits, especially at night, for the last six or seven years, and the day before his admission, whilst sitting in a chair, had a very severe one, and immediately after felt pain and swelling in his neck. He was quite certain that previous to this fit he had nothing the matter with his neck, but at the same time it is only fair to say that he could not give an intelligent account of himself, and we have to trust to his mother's opinion. She, however, was sure that he had never made any previous complaint. His symptoms rapidly increased, and on admission into the hospital the following day was spitting up a quantity of very offensive muco-purulent fluid tinged with blood.

His temperature was 101·4° F. on the evening of his admission,

and he was unable to swallow. The expectoration did not appear to come from the lungs, for there were no râles below the larynx; but it was thought that an abscess had opened into the pharynx, as pus could be seen behind the pillars of the fauces, and the matter could be ejected without much effort. I was asked to see the case, and found him sitting up in bed with his head thrown back, and a swelling in front of his neck in the position, as I thought at the time, of the thyroid body. The difficulty in swallowing seemed to be due to the inability of the larynx and trachea to move in the action of deglutition, but respiration was not in any way impeded. The swelling was hard and brawny, occupying chiefly the central portion of the neck, but was slightly larger and more prominent on the right side than on the left. It was evidently deeply placed, as the skin and superficial structures were quite free from infiltration and freely movable. The larynx was fixed, but the hyoid bone and thyroid cartilage could be distinctly felt in front, whilst their lateral boundaries were merged in the surrounding swelling. He had already begun to improve, but was transferred to the surgical side for further treatment. All his symptoms very rapidly subsided, and he was able to swallow, but as the general swelling diminished an obscure sense of fluctuation could be detected over the right carotid on a level with the larynx. This spot was soft and flaccid, but a long way from the surface, and as it was distinctly getting smaller every day, and the pus had evidently made an opening for itself into the pharynx or œsophagus, it was thought undesirable to open it. He left the hospital with a very small swelling in the position indicated above, on October 4th, and attended as an outpatient less than three weeks from the commencement of all his symptoms.

On October 6th there was scarcely anything to be seen on inspection of the neck, but on careful digital examination in the position of the former abscess some crackling on pressure could be felt. This crackling or crepitation, which felt like air in an abscess cavity, could be made to disappear by pressure, but it again reappeared, when he was directed to cough and strain with the mouth and nose closed. Dr. Semon, who was kind enough to examine him, reported that the larynx was quite normal, but that below the vocal cords was a small red swelling, which might be the means of communication between the air-passages and the small cavity in the neck.

13th.—The cavity had completely disappeared, and could not be made to fill with air. He had become quite fat and strong, and was as well as ever he was in his life. He had had no more fits, and thought the abscess had done him good.

On the 23rd he was readmitted, under Dr. Harley, with broncho-pneumonia and died on November 3rd.

The only noticeable feature in his case, besides the lung symptoms and the presence of high temperature (103° to 105°), was the fact that recent hæmorrhages were seen in both retinæ by Dr. Mackenzie. No swelling was at this time detected in his neck. The urine contained a small quantity of albumen, but no casts.

The *post-mortem* was made by Dr. Sharkey, to whom I am indebted for the following notes:—"Body well developed and well nourished. Tonsils both diseased, the left being chronically enlarged and hard, the right containing a deepish abscess cavity, limited, however, to the tonsil, and not in communication with the abscess in the neck. The latter was a perfectly smooth, thin-walled cavity, extending across the neck from side to side, and situated in the prævertebral tissues, just posterior to the œsophagus. It ran from the level of the pharynx above to the level of the clavicles below. It was almost empty, containing merely a little curdled pus. The vertebræ were quite healthy, and the origin of the abscess was uncertain. It opened by three roundish, perfectly smooth edged orifices, all placed close together, into the upper part of the œsophagus, and it was also connected by one orifice with the trachea just below the larynx, which was acutely inflamed and the mucous membrane œdematous. The cavity also opened into the posterior border of the right lung, and had there set up a gangrenous pneumonia. The latter was confined to the tissue surrounding the opening, but the whole of the lower lobe of both right and left lung was the seat of a lobular pneumonia. The spleen was large and soft. Kidneys, heart, and liver were all unusually large, but not evidently diseased."

The specimen was still further examined by Mr. Shattock and myself to see if we could find out any cause for the abscess. After a most careful search no trace of any old or recent enlargement of glands could be discovered. The lining of the abscess cavity was so smooth and definite in outline, and the openings into the œsophagus so well formed, that we thought it possible it might

have originated as a pouch from the œsophagus; but, on microscopical examination of the most likely parts, no trace of epithelium could be discovered. Unless it started from the abscess in the right tonsil, with which, however, it had no communication after death, it would appear as if it were a simple abscess of the areolar tissue around the œsophagus, for which no reasonable explanation can be given. That it was of a very chronic nature, and had been in existence for a long time before he came under observation, there can be no doubt. But this increases the difficulty of explaining the origin of the first attack, for which he was admitted into the hospital. I think that some food must have gained an entrance and caused acute inflammation of the sac, or that from some accidental cause the fluid, which it ordinarily secreted and discharged into the œsophagus, was prevented from escaping, and caused the swelling and difficulty of swallowing for which he was admitted.

His temperature during the first attack was never very high, reaching only 101·4° soon after admission, and during the following week the evening temperature only varied from 99° to 100·6°, and after this it was normal. This is scarcely what one would expect in acute inflammation of such an abscess cavity. And it must be remembered that in three weeks there was only a small swelling left on the right side of the neck, and that in four weeks there was nothing abnormal to be felt after a prolonged and careful examination.

The second attack is more easily explained. An extension of the inflammation to the lung must have recently taken place and caused the acute septicæmia from the symptoms of which he was suffering at the time of his admission on October 23rd.

February 15*th*, 1887.

---

5. *A case of hour-glass constriction of the stomach.*

By Leopold Hudson.

The patient from whom this specimen was taken was a single woman 59 years of age, a nurse, who was admitted into the Temperance Hospital on August 24th, 1886, under the care of Mr.

Pearce Gould. She had an atrophic scirrhous cancer of the left breast, with secondary deposit in the axilla. She was in an extremely exhausted condition, and complained of much pain over the right hypochondriac region; the hepatic dulness was not increased, and no swelling could be felt here. A week after admission she had four severe attacks of vomiting during the day (for the treatment of which she was transferred to the care of Dr. Robert J. Lee), and these attacks continued daily, with two exceptions, until her death, which took place on October 4th.

The *post-mortem* examination, made thirty-six hours after death, revealed secondary deposits in the lungs and liver; the latter organ also showed a deep vertical constriction or groove midway between the falciform ligament and the left free border, dividing almost completely the left lobe into two equal segments, the hepatic tissue at the point of constriction being nowhere more than a quarter of an inch in thickness.

The stomach presents a typical instance of hour-glass contraction, which divides it into two unequal parts, the cardiac being the larger.

In form the cardiac sac is roughly pear shaped, having its apex at the contraction, its base being the greater cul-de-sac. The pyloric sac is almost crescentic, the horns being formed respectively by the pylorus and the constriction, the upper slightly concave border by the smaller curvature, and the lower very convex border by the greater curvature.

The gastric wall in the pyloric sac is of normal thickness, while the cardiac segment is much thinner than it should be, and is also dilated, the fibres of the oblique and circular muscular coats being separated from one another. The bands of longitudinal fibres are very prominent along the smaller curvature.

The viscus being moderately distended, the length of the strictured part, is found to be one inch, and the point of maximum contraction in it (as indicated in the drawing kindly made for me by my friend Mr. Osmond) is nearer the pyloric end. Its distance from the cardiac orifice is six inches, and from the pyloric five and a half inches, measured along the lesser curvature. Similar measurements give fifteen inches and nine and three quarter inches respectively, when taken along the greater curvature, which latter has contributed almost entirely to form the constriction. The external circumference of the stricture is three inches, of the pylorus

two and a half inches, of the largest part of the cardiac sac eleven and a quarter inches, of the pyloric sac six inches.

The stomach being laid open, the rugæ are seen to be only faintly marked along the greater curvature. The stricture is found to barely admit the thumb; there is no thickening whatever of the gastric walls opposite to it, and no morbid change demonstrable in the mucous membrane lining it; the mucous coat is also perfectly healthy elsewhere, except in two places, which will be noticed in detail.

WOODCUT 6.

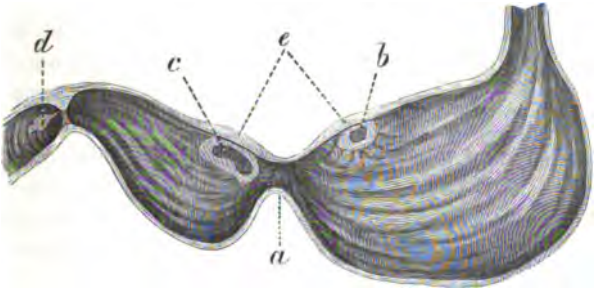

(From a drawing by Mr. E. B. Osmond.)

The stomach is represented as bisected in a vertical transverse plane. *a*. Point of maximum contraction. *b*. Cicatrix on cardiac side of constriction. *c*. Callous ulcer on pyloric side. *d*. Pedunculated polypus growing from duodenal aspect of pyloric valve. *e*. Thickenings due to fatty deposit round the vessels of the small omentum.

In the cardiac sac, situated on the lesser curvature, an inch and a quarter from the point of maximum contraction, is a small oval cicatrix, measuring one sixteenth by one eighth of an inch; the mucous membrane around it is normal, and is thrown into a few very faintly-marked radiating folds. From it, running downwards and to the left, is a band of well-developed oblique muscle-fibres; its base is attached to the muscular coat: there is some thickening of the wall of the viscus opposite to, or rather to the cardiac side of it; but this is found on dissection to be due to a deposit of adipose tissue around the vessels running in the small omentum.

The vertical circumference of the stomach, measured opposite the middle of this cicatrix, is five inches.

In the pyloric sac, likewise seated on the lesser curvature, is an

indolent, callous-looking ulcer, with smooth, pale base, and rather thickened edges. It is of irregularly oval shape; its long diameter runs parallel with the smaller curvature, and it measures one and a quarter by three quarters of an inch. Its cardiac extremity is half an inch from the point of maximum constriction. The circumference of the stomach, taken in a vertical plane through the middle of this ulcer, measures also five inches.

There is a second thickening in the coat of the stomach opposite to this ulcer, but it proves on examination to be due to the same cause as the first.

The pyloric valve is of normal size and shape. Projecting from the upper and posterior part of its circumference, on its duodenal aspect, is a small pedunculated polypus. This was found hanging into the duodenum, and in no way obstructed the pyloric lumen. The intestinal tract in the rest of its extent was normal.

The descriptions by the older anatomists of this condition of stomach are obscure and incomplete. A case recorded by Dr. Palmer[1] contains the first description I can find of the condition of the mucous membrane lining the stricture. Two instances came under the notice of Professor Struthers,[2] of Edinburgh. Dr. Carrington[3] gives details of three cases, and refers to six others recorded in previous volumes of the 'Transactions,' and to one by Dr. Jago, of Truro.[4]

Mr. Roger Williams[5] has described and made drawings of six additional cases with copious references to the previous literature of the subject. Since this paper I can find only one other case by Dr. Hale White.[6]

By excluding one of Dr. Carrington's cases (where the contraction was obviously due to disease external to the stomach), and adding my own, a total is obtained of twenty instances of hourglass contraction, either existing alone or associated with gastric ulcer. A further analysis of these gives the following results:

There were no scars or signs of ulceration whatever in nine, or 45 per cent., while in two there was only very slight superficial erosion.

[1] 'Medico-Chirurgical Journal,' January, 1816.
[2] 'Anat. and Physiol. Observations,' Edinburgh, 1854.
[3] 'Path. Soc. Trans.,' vol. xxxiii, p. 130.
[4] 'Med. Times and Gazette,' Oct., 1872.
[5] 'Journal of Anat. and Physiol.,' vol. xvii, p. 460.
[6] 'Path. Soc. Trans., xxxv, p. 196.

From this we are justified in concluding that in more than half the cases the contraction is independent of ulceration. That this is so also in my own case I am convinced, for the following reasons: firstly, because in the plane of the greatest contraction there is no ulceration whatever or evidence of previous inflammatory or other lesion; secondly, because in the plane of the ulceration there is no evidence of special contraction, the measurements I have given proving this clearly. The narrowing of the stomach is gradual and regular from the eleven and a quarter inches of circumference at the largest part of the cardiac sac down to the three inches circumference at the contraction; measurements of the pyloric sac show the same thing. There is no proportionately greater diminution of the calibre opposite to the ulcers, such as one would expect to find if the contraction were secondary to them.

As there was in this case also a vertical constriction of the left lobe of the liver, I was inclined, at first, to adopt Soemmering's suggestion that both conditions had been induced by tight-lacing. On careful inquiry, however, into the previous history of the patient I abandoned this hypothesis.

Finally, I conclude that the constriction, both of liver and stomach, is congenital, and due to an arrest of development. I believe it to be a condition strictly analogous to the so-called "partial intra-uterine amputation" of limbs; like, for example, that described by Mr. J. H. Morgan,[1] in which a congenital circular deficiency of skin above the level of the patella produced a constriction of the thigh. It was associated with arrest of development of the upper extremities.

Mr. Erichsen[2] describes and figures a similar condition affecting several of the fingers of both hands, and there is an account of another case, with drawings, in an earlier volume of the 'Transactions' of this Society.[3]

The middle portion of the stomach undergoes a temporary contraction during digestion, and has often been observed in cases of sudden death after a meal. The "hereditary impress" of this physiological constriction may have something to do with the localisation of the congenital malformation.

That the condition is really one of atavism I doubt; it has never

[1] 'Proceedings of Med. Soc. Lond.,' vol. ix, p. 155.

[2] 'Science and Art of Surgery,' 8th ed., vol. ii, p. 508.

[3] 'Path. Soc. Trans.,' vol. xxxii, p. 190.

been met with in the higher apes, and it is a great transition from this simple division into two similar cavities to the highly differentiated many-cavitied stomach of ruminants, cetaceans, and rodents.

The ulceration I regard as secondary, and due perhaps (as Dr. Carrington has suggested) to the irritation and abrasion produced by the stomachic contents when set in motion by disordered peristalsis, the normal and even movements of the organ being interfered with by the constriction. *November 16th*, 1886.

---

6. *Fibrous contraction with hour-glass stricture of the stomach.*

By F. Charlewood Turner, M.D.

This specimen is the stomach of a man aged 60, who was admitted into the London Hospital under the care of Dr. Sutton at the beginning of February, 1886, in an epileptic fit. A few weeks later he complained of his food becoming arrested behind the sternum, and a No. 15 bougie met with resistance at the cardiac orifice of the stomach, though No. 13 passed without difficulty. In April he no longer complained of dysphagia, but vomited his food, bringing up large quantities containing portions of several meals, and there was evidence of dilatation of the stomach. He lost flesh, and died at the end of May.

The organ has been laid open along its greater curvature from the cardiac opening to within an inch of a tight stricture situated about two inches from the pylorus, which does not admit a glass rod a little more than one eighth of an inch in diameter. The organ is contracted (beyond the stricture completely so), and its walls are much thickened and fibrous, especially along the lesser curvature, and near the stricture, where the muscular coat is very conspicuous in the transverse section. The mucous membrane is superficially ulcerated along the lesser curvature from the point of stricture to within a short distance of the cardiac orifice, and on the anterior wall, a short way from the constriction, is an older chronic ulcer as large as a shilling. The mucous membrane is

seamed throughout with interlacing fibrous tracts. Along the lesser curvature it is wholly fibrous and adherent to the submucous tissue, which is seen to be contracted and thrown into fine folds where exposed by ulceration. Over the whole circumference near the stricture it is fibrous and adherent, excepting defined areas of rounded outline, where the natural and freely movable mucous membrane forms soft elevations. Near the cardiac orifice, and in a less degree around the older ulcer, the mucous membrane is roughened by small papillary outgrowths. At the pylorus it appears quite healthy. The peritoneal surface is roughened by loose fibrous adhesions. It is much puckered in the greater curvature at the seat of constriction.

The autopsy showed no notable lesions of the other abdominal viscera. The arch of the aorta was exceedingly calcareous and dilated. The descending aorta was slightly atheromatous, the cœliac axis and coronary artery normal. A portion of the frontal bone, in the upper part of the forehead, and to the right of the middle line, was depressed, and fixed by osseous union; and the pia mater over the anterior part of the hemisphere was thickened and opaque. This had been caused by the falling of a beam on his head twenty years before. He had had epileptic attacks at long intervals since the accident. There had been no attack for between three and four years before his admission to the hospital, and none occurred after that.

This specimen is of interest as an instance of an extreme and fatal degree of hour-glass contraction of the stomach, and owing to the lesion to which it is attributable. This condition is for the most part met with incidentally in cases where death has occurred from other causes. In the majority of the instances recorded in the 'Transactions' (discussed in a paper by the late Dr. Carrington in vol. xxxiii) the condition appears to have been congenital, without any evidence of structural lesion of the part, and in none of the cases, excepting one referred to from another source, does this lesion appear to have been the cause of death, nor was there a degree of stricture such as is shown in the present case.

Hour-glass contraction of the stomach in the cases collected by Dr. Carrington was either a congenital condition, or due to contraction from ulceration.*

* In vol. xxxv Dr. Sharkey has recorded a case of stricture of œsophagus and stomach from scirrhus carcinoma.

In this specimen the fibroid thickening, to contraction of which the stricture was due, is associated with chronic ulceration. But so extended a lesion with seaming of the whole mucous surface cannot, I think, be attributed to the effect of ulceration. The interlacing fibrous tracts in the mucous membrane were most probably due to fibroid degeneration of an irritative growth of the connective tissue of the submucous tissue, associated with the general thickening of the gastric walls, and with the warty roughening of the mucous membrane about the cardiac orifice. The superficial ulceration extending along the lesser curvature from the point of stricture is of quite recent origin, and the older ulcer may have been also of secondary origin as in some of the cases referred to by Dr. Carrington.

In the clinical history it is notable (1) that the symptoms were at first those of impediment at the cardiac orifice of the stomach, attributable to muscular spasm; and (2) that although there was evidence of dilatation of the stomach during life, a contracted state of the organ was found after death which may be looked upon as the result of a recuperative action of the organism.

May 17*th*, 1887.

---

7. *Stomach with numerous superficial erosions following after an extensive burn.* (*Card specimen.*)

By G. N. Pitt, M.D.

There are numerous superficial erosions, varying in size from one eighth of an inch to one third of an inch, from which the epithelium is absent. They do not extend deeply, and the margins are in the majority not abrupt. They are not limited to any area of the stomach, and are not *post-mortem* changes.

When the specimen was fresh they were much more obvious than they are now. There was no thickening of the tissue round them.

I have not been able to find a similar condition following a burn described in any accounts, but the specimen (1805[72]) from the Guy's Hospital museum, shows a stomach with multiple follicular ulcers which occurred in the second week after a burn.

Possibly the specimen shown may be the earliest stage of such a condition.

The patient, J. D—, aged 64, burnt his legs extensively with the flames from a paraffin lamp he had upset. He was admitted under Mr. Durham on the 3rd of November, and his urine, when examined, contained blood and albumen. He vomited on November 4th, and this continued till his death on the 6th from asthenia.

December 7th, 1886.

---

8. *Ulcers of stomach in a child the subject of general tuberculosis.*

By Thomas Barlow, M.D.

The specimen shown is the stomach of a female child, aged 1 year and 9 months, who was a patient of mine at the Hospital for Sick Children in November, 1886.

There is nothing abnormal on the peritoneal surface, but on examining the mucous membrane several small lesions can be discovered. On the anterior wall at the cardiac end, close to the great curvature, there is an oval ulcer measuring a quarter of an inch by one eighth of an inch. The edges are undermined, and the loss of substance extends nearly to the peritoneum. There is no surrounding thickening, and no evidence of tubercular deposit on the floor or in the immediate vicinity.

There are two smaller ulcers in the great curvature about the middle zone of the stomach and two others near the pylorus.

In the line of the great curvature, about three inches from the pylorus, there is an elevation under the mucous membrane, which is pale, opaque white in colour, measures about the sixteenth of an inch in diameter, and presents the appearance of a miliary tubercle.

There was abundant tubercular deposit, in all forms, extensively distributed throughout the body, viz. in the pia mater of the brain, in the superficial parts of the cerebellum, in the choroids, the cervical, bronchial, and mesenteric glands, the lungs, the pancreas, the spleen, the kidneys, and in the Peyer's patches of the intestines.

The history was that of diarrhœa and wasting for two months, followed by slight cough, and then by squinting, convulsion, slight rigidities, and coma. There was no symptom to point to special involvement of stomach.

Remarks.—This is the fourth specimen which I have seen of multiple small ulcers of the stomach in children who were the subjects of tuberculosis. Two specimens were shown to me by Dr. Buxton, and one by Dr. Money, but no miliary tubercle was to be found in the stomach in these specimens. Probably if carefully looked for such ulcers would prove not to be very rare.

On referring to the literature of the subject I find that Steiner and Neureutter have recorded four cases of tubercular ulcers of the stomach in 302 autopsies on tuberculous children, Widerhofer two cases out of 418 autopsies, whilst Rilliet and Barthez have recorded twenty-one out of 141 autopsies.

But on reading carefully Rilliet and Barthez' account it appears to me that they have somewhat hastily concluded that the ulcers found were *necessarily* tubercular. Of the twenty-one cases they speak somewhat naïvely of fourteen in which there was tubercular ulceration without tubercle (!)

This contrasts with Louis' observations on adults. He found small ulcerations in about one twelfth of his cases, but he is careful to state that he never found tubercle or grey semi-transparent granulations in the substance of or beneath the mucous membrane, although he attentively examined 400 cases.

It is quite an open question whether the ulcers present in my specimen have been produced by the breaking down of tuberculous deposit, or whether they have formed independently of tubercle.

I have brought the specimen under the observation of the Society on account of the coexisting but independent simple opaque white body near the pyloric end which appears to me to be a miliary tubercle, and the presence of which seems to suggest, at all events, the possibility of the ulcers having started in similar deposits.

December 21*st*, 1886.

---

9. *Colloid cancer of stomach.* (*Card specimen.*)

By Leopold Hudson.

The stomach of a man aged 64, who was under Dr. Coupland's care in the Middlesex Hospital. It is laid open on its anterior surface by an incision carried midway between the greater and lesser curvatures. At the pyloric end its walls are infiltrated by a colloid carcinomatous growth which has completely encircled the viscus, the thickness in some places exceeding three quarters of an inch. Its extent to the right is limited accurately by the pyloric valve, whilst to the left it extends three inches from the valve, measured along the lesser, and four inches measured along the greater curvature. Its mucous surface presents a honeycombed appearance, and shows several scattered areas of ulceration from which hæmorrhage had taken place, more than three quarters of a pint of altered blood being found in the organ. The pyloric orifice was not obstructed, a forefinger passing through it with ease.

The only secondary deposits were some enlarged glands in the portal fissure, which on section showed an appearance precisely similar to the parent growth.

There was arrested tubercle in both lungs, and the kidneys were cystic. *April 5th*, 1887.

---

10. *Perforation of intestine four days after accident.* (*Card specimen.*)

By J. H. Targett.

A man aged 40, crushed between a rail of a barge and crane. He vomited immediately after the accident.

December 1st.—8 a.m., admitted very collapsed. Considerable tenderness in lower iliac region and hæmatoma in abdominal wall. Vomited frequently. No hæmaturia. Temperature 101°. Pil. opii, gr. j 6tis horis.

2nd.—Vomiting continued, brownish material. No blood. Ab-

domen tender on palpation, but no signs of distress. Not at all under opium.

3rd.—Better. Respiration quiet. Temperature normal. No pain. Less tenderness.

4th.—Much better and cheerful. No sickness for thirty-six hours. Passed flatus freely. Temperature normal. 10 p.m., vomiting came on suddenly. No special pain complained of, but sickness continued through the night.

5th.—Persistent vomiting, brownish material, fæcal (?) odour. Very weak and faint. Cold perspiration. Temperature 98·4°.

6th.—Severe collapse. Pulse imperceptible. Occasional sickness. Vomit bright yellow. Bowels acted. Temperature 97·6°. 8 p.m., death. Temperature 99·4°.

7th.—*Autopsy.*—Acute suppurative peritonitis with a large quantity of bright yellow fæcal material in the abdominal cavity, and gas. Rupture in the small intestine seven and a half feet from cæcum, the bowel being glued to the spine on the left side of fourth lumbar vertebra. Scybala in cæcum and ascending colon. No fracture or injury to other viscera.

December 7th, 1886.

---

11. *Chronic perforating ulcer of duodenum with erosion of pancreatic artery.* (*Card specimen.*)

By W. H. Allchin, M.B.

W. H. D—, male, aged 43, formerly a soldier, lately a club porter. Has been in India and China some years. Drank beer and spirits freely. Two years ago passed a considerable amount of blood *per rectum*, but no hæmatemesis. No record of any burn.

On March 30th, after no particular exertion, suddenly vomited an enormous quantity of blood, and fainted. There was no recurrence of the hæmatemesis, but before admission into the Westminster Hospital, on April 1st, he passed some altered blood by the bowel. On admission he was extremely blanched, and soon became semi-comatose and died thirty-six hours afterwards.

The body was very stout, the pericardium, mesenteries, and omentum being loaded with fat. Viscera extremely pale. Heart weighed 20 oz., and was excessively fatty. Slight emphysema of lungs. Spleen and kidneys and liver quite healthy.

No other ulcer was found in the intestines. No peritonitis. The lesion being strictly limited to the ulcer shown, which has completely perforated the duodenum about one inch beyond the pylorus, the base being formed by the pancreas. In the floor the eroded vessel is distinctly to be seen. *April 5th*, 1887.

---

12. *Congenital occlusion of the jejunum.* (*Card specimen.*)

By F. Charlewood Turner, M.D.

The specimen consists of the entire intestinal tract of a female infant, which died on the fourth day after birth. About the middle of the jejunum is a portion of the canal, about an inch in length, which is shut off from the parts above and below by membranous diaphragms. It contains a small quantity of mucous secretion, which cannot be pushed past either boundary. The bowel above is greatly dilated, that below is contracted.

This specimen was obtained from the body of a small, wasted infant, aged 4 days. The other viscera were normal, and there were no other malformations observable. *April 5th*, 1887.

---

13. *Perforation of large intestine in enteric fever.* (*Card specimen.*)

By W. B. Hadden, M.D.

The specimen is a portion of descending colon and sigmoid flexure, extensively ulcerated. There is a round perforation an eighth of an inch in diameter, situated in the sigmoid flexure. The entire large intestine was ulcerated to an extreme degree, as low down as the anus. The ulcers were clear of slough and deeply

excavated. Only the lower three or four inches of small intestine were affected. There was recent peritonitis.

Taken from a man, aged 19, who died in St. Thomas's Hospital.

February 15*th*, 1887.

---

14. *Cystic tumour of the cæcum.*

By Harrington Sainsbury, M.D.

Emma M—, aged 11, was admitted into the Royal Free Hospital under the care of Dr. Cockle, on March 22nd of this year. She was suffering from typhoid fever. In the course of the case relapse occurred, and the patient passed into a very low state, marked towards the end by lung symptoms.

Death occurred on June 10th.

At the *post-mortem* there was found extensive and deep ulceration of the ileum; also similar ulceration of the large intestine, reaching into, but not beyond, the transverse colon.

In both lungs extensive broncho-pneumonia.

Besides the above the following remarkable tumour was discovered:—A large, soft, fluctuating swelling, about the size of a duck's egg; it occupied the first portion of the ascending colon, distending slightly the gut, so that, viewed from without, the colon appeared slightly constricted at the upper limit of the tumour, where the distension ceased. On opening the colon the tumour was found to arise from the anterior wall of the gut, just above the level of entry of the ileum, the mouth of what appeared to be the ileo-cæcal valve being overlaid by it. On careful examination, however, of the aperture, which was situated below and somewhat behind the base of attachment of the tumour, it was found that it was divided into two by a septum, and that on the one side of this septum a probe passed into the ileum, on the other side into the cæcum. Passing a probe from the ileum it was possible to enter the colon on either side of the septum. The explanation of this was that by ulceration (typhoid) a false passage had been formed from the ileum into the cæcum, and accordingly the probe passed either by the normal route, or it went first into the cæcum and then into the colon.

The tumour itself was ovoid, smooth, elastic (fluctuating). On cutting into it, it proved to be a cyst filled with very dark, ropy (mucoid) fluid. The sac was completely shut. Externally the cyst presented all the naked-eye characters of mucous membrane; internally it was smoother, and resembled a serous membrane. In thickness the cyst wall varied much; thus, towards the base of attachment it measured 4 to 5 mm., but towards its free end it was very thin, and averaged 0·5 to 0·75 mm. The thinner parts appeared to consist of the outer and inner layers only, with a very small amount of loose connective tissue between them.

The microscope showed the outer layer to be mucous membrane similar to that which lines the large intestine throughout. (The ducts of Lieberkühn were quite normal in form, and in parts a well-developed muscularis mucosæ was present.)

The inner layer presented the structure of a serous membrane. In places a distinct muscular coat was present.

As to the interpretation to be put upon the tumour, I know of nothing similar, and those whom I have consulted have been unable to give me any reference to cases of a like nature. When I first saw the tumour I thought it possible we had to deal with some form of entero-cystoma, such as we find described by Roth;[1] but Mr. Sutton, to whom I showed the tumour, declared the inner wall of the sac to be serous membrane (as it subsequently proved to be), and considered the specimen to be one of cystic dilatation of one of the lips of the ileo-cæcal valve. This, indeed, seems to me to be the simplest mode of explaining the structure present, for reference to any anatomical plate giving a section through the ileo-cæcal valve will make it evident how easily an excessive invagination at either lip of the valve might carry with it a small portion of the serous membrane, which small pouch of serous membrane being shut off, would yield the condition of parts here found, viz. a serous sac covered towards the lumen of the gut by mucous membrane. Should secretion take place into its cavity a cyst would form.[2]

[1] "Missbildungen im Bereich des Ductus omphalo-mesentericus," von Prof. M. Roth, 'Virchow's Archiv,' Bd. 86, p. 371.

[2] Another mode of explaining the tumour is that the case is one of mucous retention cyst. The epithelium lining such cyst would be much modified by the distension, though it is perhaps more probable that it has been shed after death,—hence the resemblance of the inner wall to a serous membrane.

With regard to the septum, described as dividing into two the opening common to the cæcum and ileum, this septum is in all probability the lower lip of the ileo-cæcal valve.

Respecting the effect of the tumour, it could only act mechanically and obstruct, though it would seem to offer special facilities for intussusception at the ileo-cæcal valve. There is no history of any alimentary trouble, the child having been said to have enjoyed good health till her present illness. *November 16th*, 1886.

---

15. *Carcinoma of cæcum with extreme narrowing.* (*Card specimen.*)

By W. B. Hadden, M.D.

The walls of the cæcum are infiltrated with white, firm growth, which has undergone extensive colloid change. The diameter of the cæcum at its junction with the ileum is only a quarter of an inch, and at its junction with the ascending colon it is three quarters of an inch. The ascending colon for an inch and a half is also extremely narrowed from infiltration of its coats with new growth; its diameter varies from a quarter to half an inch. The lower two inches of the ileum are similarly affected, and the ileo-cæcal valve will only allow the passage of a No. 12 catheter. The vermiform appendix is also infiltrated, and at its junction with the cæcum there is a small perforation, which gave rise to peritonitis. There were nodules of new growth on the peritoneum, and the abdominal glands were much affected. The growth was found to be carcinoma, the cells of which had undergone colloid degeneration. The small intestines were much distended, the large intestines moderately collapsed.

Taken from the body of a woman aged sixty, whose symptoms had dated for five months before admission. Her main symptoms were abdominal pain and distension and vomiting. The bowels were open three times during the ten days she was under observation, the last time being the day before death.

December 7th, 1886.

16. *Imperforate anus;* (A) *male,* (B) *female.* (*Card specimen.*)

By D'Arcy Power, M.B.

A. The rectum and urino-genital organs of a male infant. The anus is imperforate. The rectum opens by a small aperture, through which a black bristle has been passed into the prostatic portion of the urethra immediately to the left of the verumontanum. The situation of the anus is marked by a small papilla in front of the upper portion of the bristle.

The specimen was obtained from the body of a child aged twenty-three days; lumbar colotomy had been performed three weeks before death.

B. The rectum and urino-genital organs from a newly-born child. The anus is imperforate, and the rectum opens by a large aperture into the posterior wall of the vagina. A glass rod has been passed through this opening. The other organs are natural.

The specimens are preserved in the museum of St. Bartholomew's Hospital, Nos. 3640, *a* and *b*. *November 16th,* 1886.

---

17. *Malarial disease of liver and spleen with tuberculosis.*

By Norman Moore, M.D.

A liver and spleen from a case of malarial disease terminated by tuberculosis.

The spleen weighed 60 oz., and the liver 120 oz.

Naked-eye sections of the spleen showed numerous white specks throughout it, and some larger and caseous masses. None of the masses had any increased vascularity round them.

The liver contained many similar white masses. The whole peritoneum was covered with them, some being caseous. A layer of caseous material a quarter of an inch thick surrounded the upper part of the rectum. In all the lobes of the lungs were scattered masses exactly resembling those of the liver. One abdominal caseous gland had broken down in the middle. Under the

microscope the masses in the liver and spleen were seen to consist, some merely of caseous material, others of collections of small cells; some near blood-vessels, others in the midst of the gland-tissue. Besides the small round cells a few multinucleated cells could be seen in some of the masses, but no true giant-cells. After several examinations no bacilli were found. The liver showed some general connective tissue increase. The spleen showed collections of cells precisely resembling those in the liver, and also many pigmented patches, a large connective tissue increase, and a general infiltration by blood-cells resembling that seen under the microscope in nutmeg liver.

The patient was a man aged 21 years, who came under my care, in St. Bartholomew's Hospital, November 26th, 1885. After some time he left the hospital, was again admitted, and died in one of Dr. Andrew's wards, January 21st, 1887. He had worked on a railway in Cape Colony from 1880 till 1884, and in 1883 was laid up for a year with tertian and quotidian ague. He went to Ceylon and had dysentery on the voyage. From 1884 he had noticed his greatly enlarged spleen. After returning to England he had fever again. He never had syphilis. He suffered from an irregular fever; for two months had a temperature suggesting quotidian ague, then two months of almost normal temperature, then daily fever for a week, then six weeks of normal temperature, then fever again. He improved under very large doses of quinine, thirty-five grains every twenty-four hours, and his spleen was perceptibly reduced in size. The proportion of white blood-corpuscles to red was throughout about one to five; the red corpuscles were normal. The history of malarial infection and the appearance of the liver and spleen make it certain that the chronic inflammation was that form of cirrhosis due to intermittent fever. The large quantity of caseous material in the glands and the distribution of the white masses over the peritoneum are strong evidence that the white masses in the liver and spleen were true tubercles. Gummata they were not. They have of course some resemblance to leukæmic tumours, but their caseous degeneration, as well as their distribution, seemed to negative the hypothesis that they belonged to this class. They were tubercles invading viscera already affected by long-lasting changes due to malaria. *March 3rd*, 1887.

18. *Primary scirrhus of liver of tubular type with secondary growths in liver, lung, vertebra, Douglas's pouch, &c.; prostatic calculi.*

[With Plate IX.]

By G. N. Pitt, M.D.

Alfred W—, aged 48, admitted November 25th, 1886, under Dr. Pavy, with pain in right side and swelling of abdomen.

A horsekeeper, married, has had no children. Family history unimportant. He had occasional nocturnal incontinence of urine when a child. At nineteen he had a sore on his penis; no definite secondaries. Five years ago he began to be subject to irregular attacks of vomiting with griping pain in left hypochondrium, and has never been free from them for any length of time. Bowels constipated. Five weeks ago he noticed his abdomen was enlarging, it is now thirty-one inches in circumference.

For the last two years he has occasionally wetted his bed in the night, and in the daytime he would sometimes have incontinence of urine, as he was unable to hold his water when once he had felt the stimulus from his bladder; but he was free from pain. Lately he has been worse, and has passed his water involuntarily two or three times a week. He is much worse at night-time; often when he got out of bed he could not pass his water, and when he returned to bed it would dribble away from him.

He cannot pass a strong stream, it only flows away gently, and the stream often ceases and recommences again. There is frequent micturition, more water is passed at night-time, and he has never had hæmaturia. For the last six months the urine has been fœtid. Nine weeks ago a very severe pain, with hyperæsthesia, on the right side in the region of seventh to tenth ribs commenced, which was shortly followed by pain on the left side. He has not been able to work since the first week in November on account of the pain.

On admission.—The patient is a well-developed man with normal temperature, and at the time of examination free from pain.

Alimentary system.—Appetite good, digestion bad. He vomits three or four times a week without reference to meals. His motions are usually properly formed, and he has control over them.

Splenic dulness.—Normal.

Liver.—Dulness extends seven and three quarter inches in nipple line from fifth space to within half an inch of the umbilicus. There is much fulness and tenderness in the region of the liver in the right hypochondrium. The surface feels smooth and the edge sharp.

Genito-urinary system.—The patient has incontinence of urine. Urine 1017, ammoniacal and fœtid; turbid, with a thick white deposit; no albumen, blood, or pus. Microscopically there are triple and amorphous phosphates.

Circulatary and respiratory systems.—Normal.

Nervous system.—There is no loss of power in the limbs or ataxia; no anæsthesia. The plantar reflexes are present and the abdominal absent. On the right side the knee tap is almost absent, but is normal on the left side. No ankle clonus. Right pupil larger than left.

The urine was ordered to be drawn off regularly, and the bladder washed out with boracic acid lotion.

December 1st.—During the last few days any exertion has brought on attacks of shooting pains in the legs, starting from the epigastric region.

3rd.—Two days ago he noticed his left leg was numb and felt cold; to-day both legs are numb, and he has considerable difficulty in moving them.

7th.—He cannot move his legs at all. The patient has less power over his bladder, and his urine is continually dribbling away.

9th.—He cannot sit up or turn over. The abdomen is more distended. He is able to move his toes, but cannot draw up his legs except for a slow momentary flexion of the knees through 10°. He is aware when he rotates his thigh, but not when he flexes his toes. The paraplegia is almost complete. There is anæsthesia to touch and pain over the legs, but he can just feel a touch on the soles. Sensation is impaired up to the lower end of the sternum and seventh rib, above which it is normal. Plantar reflex exaggerated on the right side, normal on the left. Epigastric present, abdominal and cremasteric absent. Knee taps absent; no muscle-taps can be elicited in legs; no wasting of muscles; no twitching. Has passed his motions unconsciously into the bed on more than one occasion this week, but usually there is neither rectal nor

urethral anæsthesia. The abdomen is globular and distended. The respiration is chiefly diaphragmatic; his breath is very short, and he has some difficulty in coughing. He complains of some numbness in his hands, and the grasp of the right hand is weaker than that of the left; his arms have wasted, the right more than the left. There is some bronchitis.

11th.—The right plantar reflex is exaggerated, the left is not. He has incontinence of fæces.

14th.—Decided spinal curvature in the dorsal region, chiefly lateral.

15th.—Plantar reflex almost absent in left foot, normal on right side. Sensation on right side better than on left. Slight knee tap on right side, none on left.

January 2nd.—The condition of the plantar reflexes and knee taps on both sides has varied on different days. The patient has had more bronchitis and increasing difficulty of expectoration, and died to-day.

At the inspection of the body, which was well nourished, thirty-five hours after death, there were numerous small subcutaneous hæmorrhages over the back, most numerous between the fifth and tenth dorsal spines, especially on the right side.

There was a sharp angular curvature at the eighth dorsal vertebra, the body of which was entirely replaced by a fawn-coloured growth of less consistency than kidney tissue. The growth was entirely encapsuled, and formed a semi-elliptical swelling an inch wide and half an inch thick on the inner surface of the thorax, extending across from rib to rib, and projecting on to the surfaces of the adjacent vertebræ.

On section it is evident that a vertebra has entirely disappeared, and been replaced by a growth. Two large healthy intervertebral discs enclose the thin lamina of growth, which is biconcave on section, being one twelfth of an inch thick in the middle, three eighths of an inch anteriorly; posteriorly it extends obliquely upwards, rounding off the intervertebral discs, and reaching over the posterior surfaces of the bodies of the adjacent vertebræ, forms a sheath an inch and a quarter long round the anterior part of the spinal canal.

The growth projects between the ribs and round the adjacent nerves, but does not involve them. The corresponding rib is adjacent to the growth, and is not in contact with any vertebra.

The lower intervertebral disc is three eighths of an inch and the upper a quarter of an inch thick, the loss of height by the replacement of the vertebra by growth being half an inch. The adjacent vertebræ and ribs are free from growth. At one point there is on the left side a shell of bone over the raised mass of growth.

The cavity of the spinal column is encroached upon chiefly by the projection of growth, which takes place posteriorly as well as anteriorly.

The spinal cord was slightly compressed and softened for an inch or more.

For an inch and a half above and below the flexion the inner surface of the dura mater was thickened, and was attached to the cord by adhesions. This was a chronic condition, and showed no hyperæmia. The size of the cord was not appreciably diminished by the pressure.

The lungs were œdematous, and there was some pus in the medium-sized and larger tubes. There were irregularly scattered throughout the lungs some twenty nodules of firm white growth one tenth to a quarter of an inch in diameter. None were on the surface, and they followed no particular distribution. There was some old scarring of the left apex, but no caseous or calcareous products.

Heart 11 oz., normal.

There were four pints of clear ascitic fluid free from blood. On the under surface of the diaphragm there were numerous millet-seed growths; there were also some on the peritoneum over the liver. In Douglas's pouch there was an adherent layer of lymph three inches by two in surface, which contained some growth, and round it was an irregular petechial area, and in the neighbourhood disseminated minute nodules of growth. These nodules were very scanty or absent in the rest of the peritoneum, and it appeared as if fragments of growth had gravitated down and then disseminated themselves. Beneath the lymph the growth could be traced invading the connective tissue.

The liver weighed 120 oz., and the right lobe was enormously enlarged, especially the posterior and inferior portions.

The growth did not project as a tumour, but had been deposited interstitially; the upper surface did not extend higher above the diaphragmatic pillars than usual, but the right lobe was much deeper from back to front than normal, and the vertical measurement was increased to eleven inches, the thickness reaching five. The surface

showed numerous nodules of growth, which were markedly capped, and were most abundant in the lower half; they were greyish white in colour, and scarcely raised above the surface at their margins.

On section there was a large mass of infiltrating growth occcupying the inferior part of the right lobe. This showed, amid its white structure, small brown spots, mapping out the distribution of the lobules, clearly showing that the growth was an interstitial one, and that it had not entirely destroyed the liver-cells, which continued to secrete bile, which stained the growth.

Independent of this large mass were innumerable nodules of growth of elastic consistence, some being translucent and others of a chalky whiteness, from a quarter of an inch to an inch in diameter, scattered throughout the liver, most numerous in the lower part of the right lobe, very scanty in the left lobe, and moderately numerous in the upper part of the right lobe.

A mass of growth in the glands of the transverse fissure of the liver lay in contact with the bile-duct, but did not press on it. The hepatic artery and vein, the portal vein, and inferior vena cava were unaffected.

There were extensive growths in the lumbar and portal glands, and also surrounding but not invading the suprarenals. The right suprarenal was a mere flattened atrophied disc adherent to the posterior surface of the kidney.

The gall-bladder contained a little blackish viscid bile. The spleen weighed 11½ oz., was firm in consistence, and contained a nodule of growth a third of an inch across.

The right kidney weighed 4½ oz., was irregularly scarred with depressed patches, due to consecutive nephritis of past date, which had resulted in wasting of the cortex. At one place on the inferior surface there was a ribbon-shaped depression three quarters of an inch broad and one tenth of an inch deep, in which, outside the capsule, lay a mass of growth which had produced atrophy of the superjacent portion of the kidney by pressure. There were numerous patches of white growth surrounded by hyperæmic areas, and in some places there were hyperæmic areas extending through the cortex without obvious growth. The pelvis was injected. The left kidney weighed 7 oz., and was quite healthy, except for one nodule of growth.

The urethra showed slight laceration of the mucous membrane of the membranous portion, due to catheterism. There were two

old pigmented spots, one on the trigone and one on the fundus of the bladder, due to catheterism. There was some hypertrophy of the muscular coat. At the fundus of the bladder was a pouch two inches long, which admitted one finger, the wall of which was more hypertrophied than the rest of the wall. The ureters were dilated slightly, but not hypertrophied. The prostate contained in cavities numerous small black calculi, some of which were just palpable on the surface when the urethra was slit up. There was no inflammation round them; they none of them exceeded one twentieth of an inch in diameter, and some were much smaller; they lay near the urethral surface of the prostate.

There were numerous adhesions between all the viscera in the upper part of the abdomen. On the upper surface of the diaphragm there were numerous small, tortuous, distended veins, which doubtless helped to carry on the circulation through the adhesions between the diaphragm and the liver. There was no lardaceous change in any of the viscera.

The large mass of growth in the liver is chiefly composed of a more or less richly nucleated fibroid tissue, consisting of bundles of fibres, in many parts running in all directions, in others collected into parallel bundles with small round or elongated nuclei.

Among the bundles of fibres arranged parallel to one another are groups of fair sized vascular channels, some lined by a single layer of elongated nuclei, others by several layers with parallel layers of fibres outside.

Some fields of view under a No. 7 Hartnack are occupied chiefly by these vascular channels, others by the nucleated fibroid tissue, the number of nuclei varying greatly in different parts of the section; in others there is a stroma of more or less parallel bundles of fibrous tissue, with but few nuclei containing irregularly-shaped sections of columns and tubes of large spheroidal and of flattened cells. In many the cells form a single layer, lining a large duct from $\frac{1}{100}$ inch to $\frac{1}{50}$ inch or more in diameter. The nuclei are larger and rather more deeply stained than when unmodified, and the amount of protoplasm surrounding the nucleus is very small; some of these cells have been flattened by pressure. (Plate IX.)

Most of the tubes are empty, in some there are loose cells similar to those lining the ducts, while in others there are cells with small nuclei and abundant protoplasm, resembling normal liver-cells.

DESCRIPTION OF PLATE IX.

To illustrate Dr. Pitt's paper on Primary Scirrhus of the Liver. (Page 151.)

From drawings by Mr. T. Fisher.

FIG. 1.—Section under a low power, showing groups of columns and tubes of cells embedded in a richly nucleated fibrous stroma.

FIG. 2.—Section under a high power, showing cells with large nuclei lining the tubes, and also densely packed in columns.

Fig. 1

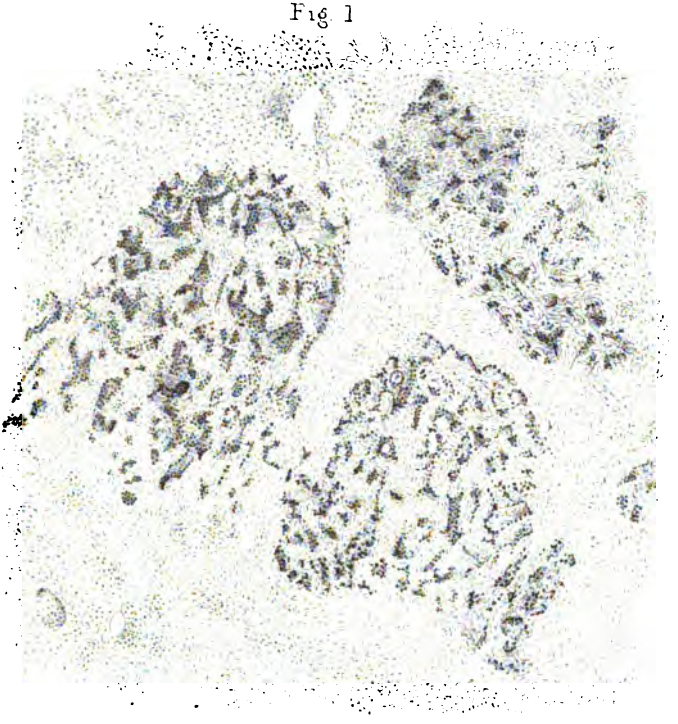

Fig. 2

T. Fisher del.

Minten Bros. sc.

There is a layer of fibrous tissue near the surface of the liver with numerous elongated nuclei, which is probably a thickening of the capsule.

The fibrous tissue, especially round the larger tubes, is denser and contains fewer nuclei than that which is free from the glandular cells. It is difficult to decide to what extent the columns and tubes of glandular cells are new formations, and to what extent they are only modified liver tissue.

In many places it appears as if there were a fibro-nucleated intercellular change, which leads to compression and atrophy of some liver-cells, while the minute spaces between them become dilated into large tubes, which are lined by the modified and compressed liver-cells. In this stage it is evident that many cells still secrete bile, as the white surface of the growth was streaked by bile stain, and the secretion is the cause of the dilatation of the tubes of cells.

Between the nodules of growth the liver tissue is healthy. Adjacent to them the liver-cells are flattened, and there are groups of small cell-infiltrations running between the liver-cells, the nuclei of which are enlarged and often double. There is marked cell-infiltration in the adjacent portal canals.

The secondary nodules consist of alveoli of fibrous tissue densely nucleated with small round cells, which enclose glandular cells, which are compressed, distorted, often fatty, and with large nuclei; in many, however, the cells have fallen out. In the walls of some of the alveoli are small lacunæ which are probably lymphatic.

The nodules of growth in the lung showed a glandular carcinoma. There were sections of tubes lined by large cubical cells with deeply stained large nuclei. These tubes are of varying sizes, and lie in a densely nucleated fibrous stroma; in some parts the stroma consists almost entirely of cells. The arrangement of the tubes is very irregular, and they are often imperfectly formed or consist of a column of cells.

The growth in the vertebra showed a similar structure, but there were very few nuclei in the stroma.

A general review of all the growths points conclusively to the large mass of growth in the liver being the primary one, while the smaller growths in the liver, and those in the vertebra, the lungs, peritoneum, kidneys, spleen, and glands are secondary.

The primary growth shows much more fibrous tissue than in the

secondary ones, but they all present the same characters, and are glandular carcinoma in structure.

The primary growth is a glandular scirrhus consisting chiefly of fibrous tissue, but containing carcinomatous tissue, chiefly of the tubular type. The probability, therefore, is that the growth started in the epithelium of the bile ducts.

While primary scirrhus of the breast is so common, it is curious that scirrhus of the liver is exceedingly rare, and is undescribed in books.

During the last few years important papers on primary carcinoma of the liver have been contributed to this Society's 'Transactions' by Drs. Whipham, Greenfield, Fagge, Mahomed, Coupland, Pye-Smith, and Paul. Dr. Whipham's case in vol. xxii, which he called a "columnar epithelioma," was a growth of nucleated fibrous tissue forming alveoli, lined by columnar epithelium, or packed irregularly with cells. The cells and alveoli resembling those of carcinoma mammæ. The growth was soft, elastic, and of a light liver-brown colour. It was probably of a similar nature to the present one.

Dr. Fagge's three cases (vol. xxviii) of primary scirrhus resembling cirrhosis differ somewhat from my case, as the growths were diffuse and not localised, and there were no secondary growths. The same difficulty existed in determining whether the cells were disarranged liver-tissue or new growth, as the liver-cells seemed to be multiplying and turning into new growth; the growth, however, consisted chiefly of acini and not of tubes.

Dr. Coupland's case (vol. xxxi) was a carcinoma limited to the liver, which was associated with so much connective tissue and spindle-cell growth, that it was uncertain whether there was not also a sarcomatous growth. It would, however, appear to have been very similar to the present one.

Mr. Paul's (vol. xxxvi) fourth case was an associated scirrhus and cirrhosis similar to Dr. Fagge's.

Dr. Mahomed (vol. xxviii), Lanceraux, and others, would look on such cases as malignant tubular adenomata of the liver.

In the cases of malignant adenoma or primary carcinoma hitherto described there have either been no secondary growths or very few, and I have found no other case where there has been such a widespread diffusion as in this, where the liver, lungs, vertebra, glands, peritoneum, kidneys, &c., were involved.

While the growth in the liver is a very rare one, I believe the condition of the vertebra to be unique. The body of the eighth dorsal vertebra is entirely replaced by a secondary growth, and no trace of any bony tissue is left, except a thin shell on the surface. A careful examination shows that a vertebra is missing corresponding to the eighth rib, and there is no evidence of any abnormality of the vertebræ. I have been unable to find a record of a vertebra being symmetrically and completely replaced by growth.

It is curious that the growth should have entirely absorbed the bone, and yet not have eroded through the capsule. It is also clear, from the microscopic appearance, that the growth is secondary to that in the liver.

The growth projecting into the spinal canal had set up a chronic meningitis of the adjacent membranes, and ultimately, as the spine flexed, had caused paraplegia by its pressure. The general protrusion of the growth beyond the surface of the vertebræ was doubtless due to the adjacent vertebræ being approximated to one another half an inch, owing to the growth being less resistant than the bone.

The occasional incontinence of urine for the preceding eighteen months may have been due to the irritation caused by the projecting ends of the prostatic calculi.

The greater portion of the peritoneum was free from growth, but in Douglas's pouch was a layer of growth in the most dependent portion, where there was also a layer of inflammatory lymph. It would appear as if a fragment of growth had become loose in the peritoneal cavity, and had gradually made its way to the lowest point, where it had become adherent, and continued its growth. Extraordinary as such may seem, I recollect hearing the late Dr. Moxon refer to a similar case, where a growth had taken place in Douglas's pouch secondary to a growth remote in abdominal cavity, and where he suggested the same explanation; as also in a case of cancer of the kidney, with a secondary nodule at the vesical orifice of the ureter. *May 3rd*, 1887.

19. *Two cases of gall-stone causing obstruction of the bowels.*

By P. H. Pye-Smith, M.D.

Case 1.—The calculus now shown was passed by Mrs. C—, a lady 78 years old, whom I saw in consultation with Dr. Hammersley, of Catford Bridge, for obstruction of the bowels, on the 30th of November, 1886.

She had always been liable to constipation, but had never suffered from severe colic nor from jaundice. The bowels had been relieved by enemata a fortnight before I saw her, after several days' inaction, but now there had again been no motion for nearly a week. The abdomen was distended and tympanitic, the left flank decidedly fuller than the right. There was no pain or tenderness, only slight vomiting, and no tumour could be felt.

On examination *per rectum* the bowel was found healthy as far as the finger could reach, but through its walls, and, as I believed, through the wall of a higher segment of the gut, could be felt a rounded, smooth, firm tumour, which eluded the pressure of the finger, and appeared to be free and movable.

I regarded this as most probably a cancerous growth, and its seat as being in the transverse colon, and advised strictly liquid food and the use of enemata of olive oil night and morning. Having regard to the age of the patient and the uncertainty of the lesion, I dissuaded from colotomy.

After twelve days' patient treatment in this way, the large calculus now shown was voided, and the patient made a good recovery. Dr Hammersley informs me that she is now (March 15th 1887) in excellent health for her age.

The stone consists chiefly of cholesterine, with a friable coating of dark bile pigment. It measures four inches in circumference, and would be nearly globular but for two flat facets, which give it a more cubical aspect. It weighs, when dry, about 4½ drachms.

Remarks.—Gall-stones are not a frequent cause of intestinal obstruction. In 1152 cases collected by Leichtenstern they made up only 41, *i. e.* less than 4 per cent.; and probably of these cases only about a fourth recovered.

Obstruction from this cause is far more common in women than in men, and in women above fifty than in younger ones. The symptoms

are sometimes acute with incessant vomiting, though without the excessive pain and deep collapse of strangulation; more frequently they are chronic, with ingravescent symptoms. The gall-stone most often lodges at the end of the ileum, sometimes in the jejunum, or even in the duodenum. If it has gone through the valve it probably is always passed safely on to the anus.

So large a stone as this probably entered the duodenum by a fistulous communication with the gall-bladder;[1] but, as in similar cases, this took place without a definite attack of pain or illness.

Mr. Le Gros Clark published in the fifty-fifth volume of the 'Medico-Chirurgical Transactions' (1871) a case of intestinal obstruction from gall-stones in a lady 58 years old, which proved fatal, after eight weeks' sickness, by some small calculi perforating the walls of the ileum. Two large calculi were found just above the valve, each about an inch in length and four inches in circumference. One of them, as figured, much resembles the calculus now shown in shape as well as in size. In Mr. Clark's case there was no evidence of communication having taken place between the gall-bladder and intestine, yet the calculi consisted only of cholesterine and bile-pigment. Is it possible that a calculus, after having passed from the duct into the duodenum, may increase in size by the bile poured over it from time to time?

I have recorded this case partly because of its curiosity, and also because in rare and important diseases it is only by accumulation of cases that we can safely decide on prognosis and treatment.

The 'Transactions' of this Society contain but few cases of obstruction caused by gall-stones. The first was related in our first volume by the late Dr. Peacock; it occurred in a young woman of 27. The second calculus was shown by my father (vol. v), and is now in the museum of Guy's Hospital (No. 1986[55]); the third by Mr. Potts in 1864 (vol. v). My late colleague, Dr. Fagge, brought forward two cases, one in a woman of 56, and the other in a man of 64, both ending in recovery. Dr. Murchison, who collected twenty cases from all sources, showed one to this Society in 1869 (vol. xx, p. 219); it caused fatal obstruction in "an elderly female." Two other cases were shown by Dr. Vanderbyl (vol. viii) and Dr. Baly

[1] Escape through fistulous communication with the hepatic flexure of the colon is much more rare. An old observation of Dr. Abercrombie in his 'Diseases of Stomach and Abdomen,' 1828, shows that a large calculus may gradually dilate the gall-duct to the size of a finger, and thus pass without ulceration into the duodenum

(vol. x). Dr. Ord showed the Society, in 1880, a large gall-stone which caused no obstruction, but diarrhœa (vol. xxxi, p. 140). The remarkable calculus shown last session by Mr. E. H. Fenwick was intestinal in origin, not biliary (vol. xxxvii, p. 261). Frerichs had only seen two cases of obstruction of the bowels from gall-stone. In Mr. Treves's excellent monograph on intestinal obstruction he has collected sixteen.

Probably the calculus, when felt, was in the lower part of the ileum. I am not aware whether a gall-stone has before been felt by the finger in the rectum during life. In this case the sex and age of the patient, together with the presence of a movable tumour felt through the wall of the rectum, ought, perhaps, to have led to a correct diagnosis. I should, I think, if another opportunity offered, recognise the smooth rounded tumour with its curious mobility.

Case 2.—By a curious coincidence I happened, this same day, after writing the above communication, to meet Dr. Burt, of Shepherd's Bush, who put in my hands the second calculus which I show this evening.

It is still larger than the other, but instead of being cubical or globular it forms a long oval, and thus was more readily passed, by its long diameter coinciding with the axis of the gut. As will be seen, it is broken across, and shows the usual structure, a dark, friable, amorphous nucleus, with a well-marked shell of somewhat harder substance, a thick zone of radiating cholesterine crystals, and a more or less complete outer coating of pigment. It is of a yellowish-white colour, with a tint of green in places, smooth, and mammillated on the surface. Its greatest circumference is five inches and three eighths, its long diameter two inches and a quarter, and its short diameter an inch and a tenth. It is somewhat more porous than the first; for whereas that when dry sinks at once in water, this floats until the air has been gradually expelled from its interstices. Both calculi would certainly have remained at the bottom of a vessel when first passed and saturated with moisture. The first, as above stated, weighs 270 grains; this one weighs 323 grains. Both are preserved in the Guy's Hospital museum.

This large calculus was passed by a lady aged 60, whom I had seen with Dr. Burt shortly before. She was then suffering

from abdominal pain, constipation, with occasional diarrhœa, and other obscure symptoms, which I feared indicated malignant ulceration of the colon. After complete obstruction of the bowels for ten days, with but little vomiting and moderate pain, she passed this calculus in two pieces. The symptoms gradually subsided, and she is now in her usual state of health; but within a week after the passage of the gall-stone there was an attack of zona on the left side. She also had never had jaundice. The calculus, though larger than the other, produced less severe symptoms, owing, no doubt, to its long and uniform shape.

March 15*th*, 1887.

20. *Cirrhosis of pancreas in diabetes.* (*Card specimen.*)

By W. B. Hadden, M.D.

The specimen shows a very large amount of fibrous tissue. The acini are very scanty, and the epithelium is proliferating. At the *post-mortem* examination the pancreas appeared very small and firm, and there were islets of pale gland-tissue separated by much connective tissue.

There was advanced tubercular disease of the left lung, and slight disease of the right.

Taken from the body of a man, aged 38, a painter, who had suffered from diabetes for four years. There was no unusually rapid emaciation. *December* 7*th*, 1886.

V. DISEASES, ETC., OF THE GENITO-URINARY ORGANS.

1. *Kidneys, with old ascending nephritis, which has produced numerous large cysts and extensive local destruction and shrinking.* (*Card specimen.*)

By G. N. Pitt, M.D.

The kidneys are irregularly diseased and unequal in size; together they weighed 15 oz. Part of their structure is fairly healthy, the surface being smooth and the cortex not shrunken. Microscopically, the tissue is not much affected, although here and there groups of small cells, causing interstitial changes, are scattered.

In the diseased portions are cysts varying in size from half an inch to one and a half inches, and one large one of three inches diameter forming a hydronephrosis. On the surface of the affected spots, which are irregularly scattered about, the cortex was extremely wasted, the surface of the kidney being depressed and irregularly scarred.

Microscopically, the convoluted tubes were found to be more or less destroyed by an extensive cellular interstitial change, the density of which varied from spot to spot, being much more extreme in some spots than in others.

The glomeruli were crowded together, and there was a thickening outside of concentric scantily nucleated fibrous tissue; but there was no great change inside. The infiltration with small cells extended into the medulla of the kidney between the straight tubes.

The pelves of the kidneys, the ureters, bladder, and urethra were healthy, so that the cause of the ascending nephritis had passed away, and only left its traces in the kidneys. It may have been a cystitis, but no history of such was obtained.

The urine was only examined once before his death, and then was of sp. gr. 1020, and did not contain any albumen.

The interest of the case consists in the advanced condition of local disease which existed in otherwise healthy kidneys.

The patient was aged 65, and died with extensive and numerous patches of cerebral softening due to very atheromatous cerebral arteries. *December 7th,* 1886.

---

2. *Urinary tuberculosis with multiple renal calculi.* (*Card specimen.*)

By E. Hurry Fenwick.

This specimen is shown as a good example of primary urinary tuberculosis, for neither testicle was affected, and also on account of the questionable factor which the renal calculi played in determining the locality of the outbreak. The specimen was removed from the body of a man aged 32, who for five months before death suffered with difficulty in passing water and in retaining the same. The case ran the usual course of urinary tuberculosis.

Lungs free, except the left apex, which is puckered and adherent, and contains a knot of caseous matter the size of a horse bean.

The bladder is small and contracted, holding about 4 oz.; there is no perivesical condensation. The muscle wall is not hypertrophied. The trigone is free, but the mucous membrane of posterior wall is covered with superficial irregular ulcers of a tubercular character. The entire prostate is converted into a dense caseous mass, and the prostatic urethra and neck of bladder are covered with fine miliary tubercle. The right ureter is enlarged. Situated at the junction of the renal pelvis with the ureter proper is a stone which has become so impacted as to completely obstruct the lumen. The right kidney has been transformed into a large multiloculated membranous sac, and only a patch here and there of renal substance remains. It will be observed that these patches are infiltrated with tubercular deposit. On slitting open the sac eight highly polished rounded stones were found loose in the cavity, and on turning the sac inside out, patches of growth varying

in size from a pea to a monkey nut, became visible situated upon the fibrous wall. At first it was supposed that the tubercular growth had arisen from the membranous structure, but on more careful examination it was found that these little projecting masses were small infiltrated clumps of renal substance. They are eight in number. The left kidney has evidently done double work, for it is nine inches long and eleven inches round; its entire substance is infiltrated with tubercle. Its pelvis contained eleven highly polished stones, like small horse chestnuts.

The specimen is shown as an illustration of tubercular infection. In the membranous remains of the right kidney were eight small disconnected patches of renal tissue, and in the course of the urinary tuberculosis these became likewise affected. It is interesting also to note the obvious precedence of the stones to the disease, and the question naturally arises, were the calculi the excitors of the tuberculosis? *May 3rd*, 1887.

---

3. *Encephaloid cancer of right kidney.* (*Card specimen.*)

By E. Hurry Fenwick.

This kidney was removed from the body of a man aged 64, who during life had suffered from profuse hæmaturia of a vesical type.

Ten months before death he noticed some obstruction in passing water, and voided a blood-clot, which was followed by a profuse hæmaturia of a painless character. After twelve hours the bleeding was arrested. For three months he was free, when another attack supervened of three days' duration. Character painless and vesical. He was again free for ten weeks, when painless hæmaturia again ensued. Since this time he has had recurrent attacks every ten days. No stone, no cause assignable for outbreak. Prostate rather large. Urine of sp. gr. 1015, alkaline. Blood almost pure, and of a scarlet colour. Exploration of the bladder was performed by Mr. Coulson, in the hope of finding a villous growth, but the bladder was found to be free. The patient

had a severe attack of suppression of urine, from which he recovered, with a profuse attack of herpes labialis. He died a month after the operation.

The bladder was somewhat hypertrophied but otherwise healthy. The right kidney was eight inches long. Section showed the upper quarter to be renal substance, with innumerable deposits of encephaloid cancer scattered through it, and the lower three quarters was transformed into a disintegrating blood-red mass of the same growth, evidently growth with a large extravasation of blood.

Left kidney was normal, but a branch of the left renal artery contained a *hollowed* plug (a canalised clot).

The entire aorta was extensively atheromatous. The inferior vena cava was similarly but less diseased.

This case is shown as an illustration of that class of hæmaturia in which a renal bleeding simulates one of vesical origin.

There is no doubt the renal bleeding had been sudden and profuse, and the bladder being rapidly distended with a weighty alkaline fluid had as rapidly contracted.

One other point is of importance,—that is the occurrence of the prolonged suppression and the recovery with an outbreak of labial herpes of an extensive character.

Three and a half days after the operation he had a severe rigor due to passing a blood-clot. From this time for forty-eight hours he was blanched, delirious, and only 8 oz. of highly albuminous urine were drawn off. His temperature after the initial rigor sank to 95°, and remained at that. The reaction set in with the voiding of a pint of urine of a sp. gr. 1007 containing albumen, and with the elevation of the temperature to 89·6° F. To account for this attack we have both kidneys affected,—one, the carcinomatous, infiltrated with blood; and the other, with a branch of its main artery blocked, and subsequently canalised.

February 1st, 1887.

4. *Great dilatation of one ureter and pelvis of kidney secondary to urethral stricture.* (*Card specimen.*)

By W. Hale White, M.D.

A man about 40, found leaning against some railings, was brought to the hospital in a cab by a policeman. On admission he was semi-unconscious,—very little information could be got out of him. Bladder not distended. Has a tight urethral stricture; passed a little urine strongly ammoniacal, without pus, albumen, or sugar, sp. gr. 1027, some turbidity, but that cleared on heat, showed triple phosphate crystals. On being put to bed he became more sensible, but he soon began to gradually get worse, and after three days' stay in the hospital he became delirious and sank.

Post-mortem.—There was a very tight stricture at the membranous part of the urethra. The bladder was considerably hypertrophied. The left ureter was dilated right down to the bladder to such a size that it would admit the middle finger. No cause for this dilatation was noticeable in the wall of the bladder. The pelvis of the left kidney was much dilated, and the greater part of the pyramids had disappeared, constituting an early hydronephrosis. There were no inflammatory signs; the right kidney and ureter were healthy. *April 5th*, 1887.

---

5. *Slight unilateral hydronephrosis due to stricture of the ureter.* (*Card specimen.*)

By G. N. Pitt, M.D.

These kidneys were removed from the body of a healthy man, aged 22, who died from cerebral injuries caused by coming in contact with a moving train.

The right kidney is healthy. The left was distended with about 2 oz. of urine. On section the pelvis is seen to be considerably enlarged, but the pyramids are not flattened, and the kidney structure appears normal; there were a few ecchymoses on the mucous membrane.

The ureter, at its junction with the pelvis, is very small, only just admitting a probe the size of a No. 2 catheter. On opening it up the mucous membrane appears smooth and healthy but for a definite line of thickening at the junction, the mucous membrane of the ureter being thicker than that of the pelvis; no cicatrix is visible. The circumference is only three sixteenths of an inch, while that of the opposite ureter is three eighths of an inch.

The rest of the ureter is normal, and an inch beyond the obstruction is the same size as the right. The bladder and lower part of the ureters are normal, except for a few ecchymoses on the bladder.

It is evident from the appearance of the pelvis and its distension with urine that the abnormally small size of the orifice of the ureter had led to well-marked obstruction to the outflow of urine, and though cases of hydronephrosis are not rare, I am unaware of a case of narrowed urethral orifice having been recorded as a cause, although the valve-like opening and total obliteration of the ureter have been.

Whether the narrowing in this case was congenital or not it is difficult to say, but I should have expected more pressure signs on the pyramids had the obstruction existed since birth. On the other hand there was no evidence of there having been any ulceration at a previous time leading to contraction ultimately, and no evidence of a calculus having ever passed. *April 5th*, 1887.

---

6. *Atrophied kidney and dilated ureter from a female child aged 2 years.* (*Card specimen.*)

By W. R. Dakin, M.D., B.S.

The bladder, ureters, and kidneys of a child, who died of anæmia connected with rickets, and had no symptom of disease of the genito-urinary organs.

Left kidney weighed 3 dr., was one and a half inches long. Cortex much atrophied, and pelvis dilated. The corresponding ureter is elongated, tortuous, and dilated to about the size of the little finger, and has very thick walls. It opens into the bladder by a large orifice, admitting when fresh an ordinary-sized pencil. Bladder normal, except for a few faint spots of pigment. Micro-

scopically, an extreme state of cirrhosis, with irregularly dilated tubes, and much atrophied Malpighian tufts and capsules.

Right kidney weighed 2¾ oz., was three inches long. There was no history to throw any light on the cause of this condition, but a calculus which might have passed *per urethram* is a possible cause.

April 19th, 1887.

---

7. *Ectopia vesicæ.*

By Samuel G. Shattock.

The specimen is one of ectopia in a male child, and, from a pathological point of view, presents nothing uncommon. But although the malformation is so well known, no adequate explanation is forthcoming, I do not say of its cause, for of this, as in other cases, there is as yet no knowledge, but of the anatomy it presents; and it is in order to shortly criticise the correct explanation, and to offer a new one, that I exhibit the present specimen.

As the selection of the term ectopia implies, the condition is classed under the same category as ectopia of the heart and ectopia of the abdominal viscera. Both of the latter malformations result from a deficiency in growth of the mesoblastic basis of the body-wall, which is thus wanting to a greater or less extent in the middle line, and they are analogous in this respect to spina bifida.

In ectopia cordis and ectopia of the abdominal viscera the organs themselves are perfectly formed, and it is this which removes ectopia of the bladder from precisely the same pathological category.

In ectopia vesicæ there is not only an incomplete formation of body-wall in the middle line, but the anterior wall of the bladder is itself deficient. Inasmuch as the bladder is morphologically the unobliterated portion of the sac of the allantois within the body of the embryo, and the allantois is formed as a blind, pouch-like protrusion from the anterior wall of the hind-gut, it is obvious that what is usually taken as an explanation is insufficient to account for the appearances in question. Were the case one similar to that of ectopia of the heart the bladder would protrude through a

deficiency in the lower part of the abdominal wall, but the viscus itself would be entire.

The explanation which I submit is the following: that the primitive cloacal invagination of the surface which normally lays open the lower end of the rectum and the lower end of the urogenital sinus, does in these cases, by an undue extension forwards and upwards, lay open the anterior wall of the urogenital sinus and the anterior wall of the bladder.

There would thus result a complete fission of all the parts in the middle line as high as the umbilicus, and the rudimentary penis or clitoris would be on its first appearance completely cleft.

WOODCUT 7.

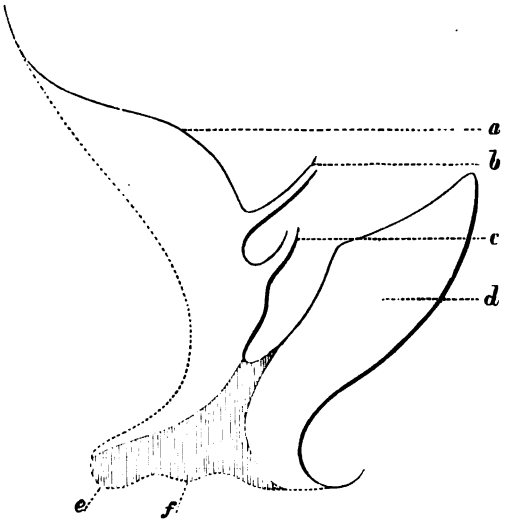

The broken line indicates the outline of the parts to the right of the mid-plane; the continuous line, the condition in the mid-plane, in a case of extroversion. The primitive cloacal cleft is represented as continued to the umbilicus. The shaded portion indicates the area of fusion that subsequently occurs in the mid-plane in the male, the cleft penis uniting from below, whilst a urethral groove remains above. *a*. Posterior wall of the bladder. *b*. Ureter. *c*. Genital cord. *d*. Rectum. *e*. Rudimentary penis or clitoris. *f*. Scrotal fold or labium.

During the subsequent course of development the rectum would, as under normal circumstances, be partitioned off from the uro-

genital sinus and the perinæum be formed. And in ectopia in the female this is all that happens; the bladder and urethra are continuously exposed, the clitoris being completely cleft. In the male the perinæum would be formed in the same way, the fusion of the scrotal folds would occur as usual, and the urethra would be closed below by fusion of the lateral rudiments of the penis, whilst it would remain enclosed above and continuously open with the opened bladder.

It is a significant fact that although epispadias may occur without ectopia of the bladder, ectopia never occurs without epispadias. For, clearly, on the theory submitted, if the unnatural extension of the cloacal fissure involve the bladder it cannot do so, except it involve also the urethra; but should the undue extension occur to a lesser extent it may involve the urethra without involving the bladder. In such a case epispadias would result without ectopia. The cleavage, therefore, in ectopia is, on this supposition, the result, not of the undue persistence of the whole or part of a normal primitive cleft, but of its unnatural extension. The cleft in the situation of the symphysis would also thus receive its explanation.

The large interval, it may be of four inches, at times existing between the pubic portions of the hip-bones does not indicate a corresponding deficiency in the original formation of the bone, but is due in chief part to the transmission of weight from the spine to the acetabula. For it is obvious that if the pelvic girdle is wanting in the middle line anteriorly, the transmission of weight will lead to a forward displacement of the sacrum and posterior parts of the hip-bones, whilst the pubic portions will be correspondingly disparted in front, owing to the absence of the anterior tie of the pelvic brim. *February* 15*th*, 1887.

---

8. *Frozen section of an hypertrophied bladder removed from a case of stricture of the urethra.*

By E. Hurry Fenwick.

In the course of an investigation into the mechanics of the urinary bladder, and more especially into the amount of the stress-resistance which each individual section of that viscus is able to bear, I found it necessary to make frozen sections of the healthy and of the diseased organ.

This procedure obviously affords the only reliable data for estimating the comparative thickness of the different layers, and without some such comparison no accurate grasp can be obtained of the different elasticities, extensibilities, and powers of sustaining sudden or prolonged pressure which are possessed by the different sections of the viscus in question.

I am not aware that work has been done in this direction, and yet I do not wish to lay before the Society more than one fact, for my examinations are as yet not sufficiently numerous to justify dogmatic statements.

This bladder was removed from the body of a man who had died in the prime of life from some intercurrent disease whilst suffering from a tight stricture of the urethra in the bulbo-membranous portion. It was frozen, and cut vertically. Its most striking feature is the difference which exists in the thicknesses of the anterior and posterior walls. The anterior is more than twice as thick as the posterior (Woodcut 8).

The first question which is naturally asked is, Does the anterior wall usually hypertrophy more than the posterior? That question I would answer in the affirmative, for it will be found in museum specimens of hypertrophied bladders that the anterior wall is generally thicker than the posterior. To formulate this I would say, "If an obstruction has existed to the outflow of water, and the bladder has been called upon to exert extra-expulsive power, the extra work will mainly fall upon the anterior wall, and the evidence of that will be found in its greater hypertrophy."

I believe this fact has been overlooked, but I would guard myself by saying that it is new to me, and I can find no notice of it in the literature. The reasons for its presumable non-recognition are: first, that it is rare to get cases of *unrelieved* stricture on the *post-mortem* table, and directly the necessity for the increased work has been done away with by operation, or even partial instrumental interference, the muscle wall wastes. Secondly, it is usually customary in examining the bladder to slit open its anterior surface and turn it inside out, hence no comparison of the thickness of the two walls can be obtained.

The next question to be answered would be, Does this patho-

WOODCUT 8.

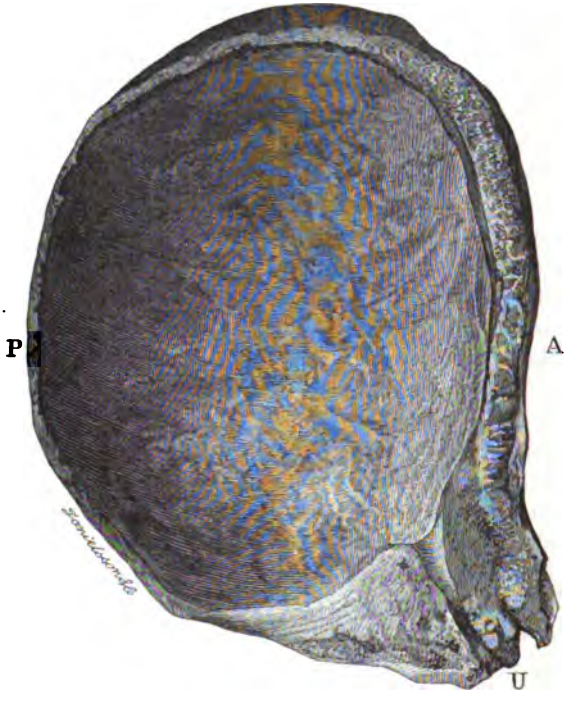

P. Posterior wall. A. Anterior wall. U. Opening of prostatic urethra.

logical condition receive support from a consideration of the anatomical structure of the bladder? I believe so.

In the first place I would submit that it is the anterior wall which possesses the greater capacity or power of hypertrophying. Normally its movements are freer and less restrained than the posterior.

The anterior wall is unfettered in its contraction and expansion; but the posterior is hampered by the inelastic adherent peritoneum. It will be found also that the venous drainage of the anterior wall is superior in its capacity and intricacy to that of the posterior (*vide* Author, 'Journal of Anatomy and Physiology,' vol. xix, pl. xvi, p. 321), and one naturally concludes, therefore, that the blood supply to the anterior wall is freer than that to the posterior. Work and nourishment go hand in hand. Dr. G. N. Pitt has called my attention to the fact that the anterior wall hypertrophies in obedience to the principles of hydrostatics. Dr. Pitt says, "If membranes in the shape of spheres of varying sizes enclose fluid so that the tension is uniformly distributed along each fibre, the thickness of the membrane must, by the principles of hydrostatics, be exactly proportioned to the radius of the corresponding sphere; thus it is that the anterior wall, having a greater curvature than the posterior, must be thicker than the posterior in order that the pressure of urine in the bladder may be balanced by the same tension of each muscular fibre." Now, at the same time that I would acknowledge the partial value and partial truth of this law as applied to the bladder, I would submit that we cannot govern the many vital conditions which obtain in the bladder by a stern mechanical law admitting of no deviation.

To prove the inadequacy of the hydrostatic principle just mentioned to account for the comparatively greater thickness of the anterior wall, let us examine a series of frozen vertical sections or museum specimens of hypertrophied bladders. The composition of the strata does not conform with the law. There are two main muscular strata—the circular and the longitudinal. Which has the greater curvature? The longitudinal. The longitudinal layer then, if the law enunciated be strictly applicable to the case in point, should be the thicker. But this is not so. It is almost invariably the circular stratum which has hypertrophied so greatly, and it is often twice as thick as the longitudinal.

There is a pathological condition which lends some weight to the theory that different thicknesses and strength of the muscular

layers of the anterior and posterior walls usually exist. I refer to the tunicary herniæ of Cruveilhier. These are found chiefly on the posterior wall, and are formed by the pouching of a lax mucous membrane between a trellis-work muscle.

It is well known that rupture of the urinary bladder usually involves the posterior wall and rarely the anterior.

"Thus, out of 100 cases of rupture in which the position of the aperture is clearly noted, forty-four presented the rent on the posterior aspect of the bladder; twenty-two posteriorly and superiorly; twenty-two at the superior fundus; three superiorly and anteriorly; four on the anterior aspect of the superior fundus; four behind and below; and one at the side" (Rivington, 'Rupture of the Urinary Bladder,' fig. 22).

The same author in discussing the reason for this immunity which the anterior wall enjoys, attributes it to the direction of the violence, and to the fact that the posterior wall is weaker. He gives, however, no reason for the latter statement, except a reference to the tunicary herniæ of Cruveilhier. I believe that the facts and specimen I lay before the Society enable one definitely to say that the anterior wall is the stronger and has the greater capacity of resisting the sudden stresses which the bladder is frequently called upon to bear. *January* 18*th*, 1887.

---

9. *Extra-peritoneal wound of bladder without extravasation.* (*Card specimen.*)

By J. H. Targett.

Man, aged 68; wheel passed over left leg and lower part of abdomen. Had passed water half an hour before accident.

On admission.—Fracture of left leg with great tenderness and crepitus about pelvis. About one drachm of urine drawn off, quite clear; no albumen. Eight hours later 5½ oz. drawn off, porter coloured. Hæmaturia persisted till death, but last specimen had less blood. On third morning, became rather

suddenly collapsed. Abdomen distended. Died sixty-two hours after accident.

Autopsy.—No signs of peritonitis. The peritoneum was carefully separated from the hypogastric region, where much blood had collected, and water injected into the bladder before it was disturbed. It was at once seen to ooze out rapidly on the left side, outside the peritoneum, and in relation with the descending ramus of the pubes. The pouch of Douglas was quite healthy. No injury to peritoneum. The pelvic viscera were taken out *en masse;* urethra normal.

On the left wall of the bladder in front were two wounds of the mucous surface, about half an inch apart. A probe passed readily into the tissues outside, in an oblique direction, so that the punctures were somewhat valvular, and their margins were very shreddy. Much hæmorrhage into the tissues outside, but no urine could be detected, nor any signs of suppuration. Kidneys healthy. Multiple fractures of pelvis, so that left pubic bone was quite free, and displaced downwards and backwards.

February 1*st*, 1887.

---

10. *Subperitoneal rupture of bladder.* (*Card specimen.*)

By W. Bruce Clarke, M.B.

Michael van V—, aged 73. Ruptured bladder and urethra. December 9th, 1886.—Was run over the abdomen by a four-wheeled cab, and had some bruising in the perinæum as well. Some difficulty in passing a catheter on his admission, but at last a silver prostatic was introduced, and about a pint of urine drawn off. The next day a soft rubber catheter was introduced without difficulty, but there was a little bleeding on each occasion of the passage of the catheter. He could not pass water of himself.

In the evening of December 10th I saw him, as no instrument would pass and he could not evacuate his urine. There was apparently a false passage in the membranous part of the urethra. Passed down a staff, and opened the urethra *in perinæo*, where I found without difficulty the rupture, and, introducing a full-sized black catheter, tied it in.

11th.—Abdomen more distended and tender to touch; this was partly at least accounted for by the fact that he had pulled out his catheter, consequently the bladder was distended. The wound in the perinæum was reopened, and a lithotomy tube inserted, after which the water passed without any difficulty.

The patient became gradually weaker and died on December 13th.

The abdomen got more distended and painful at the lower part, notwithstanding the fact that the urine did not again accumulate in the bladder.

Post-mortem examination.—When the abdominal cavity was opened, the intestines in the neighbourhood of the bladder were much distended, and the peritoneum was a little injected on the surface of the bladder, but there was no lymph effused, and scarcely any fluid in the peritoneal cavity.

When the bladder had been most carefully removed, it was opened in my presence, and the rupture, which extends only through the mucous and muscular coats, and is about an inch in length, was detected at its apex. The edges of the rupture are clean cut, and there is no extravasation between the coats. The bladder wall was red and injected with both large and small vessels, and contained a few teaspoonfuls of foul urine; there was a little mucus clinging to its walls. The rupture is not in the site of a tunicary hernia, but there are several small herniæ of this nature below it. The bladder is larger than it should be, and the walls are thin and flabby. The prostate is not enlarged. *February 1st*, 1887.

---

11. *Sacculated bladder with calculus fixed behind prostate.* (*Card specimen.*)

By C. Mansell Moullin.

Prostate enlarged. Bladder small, and muscular coat hypertrophied. Two large sacculi and numerous small ones.

The calculus lay behind the left lobe of the prostate, and was so deeply embedded and so firmly grasped by the muscle of the bladder

that though it could be felt with a lithotrite and by the finger in the rectum it could not be dislodged. *May 17th*, 1887.

---

12. *Tumour (papillomatous) removed by supra-pubic cystotomy. (Card specimen.)*

By Sydney Jones.

This tumour, about the size of a walnut, was removed from a man aged 54. He was admitted into St. Thomas's Hospital on March 21st, 1887. He had had symptoms for two years; the symptoms were chiefly hæmorrhage, which recently had been very great. During the last three months he had been losing flesh, was looking anæmic, and getting much weaker.

On March 31st Mr. Sydney Jones did supra-pubic cystotomy; found the tumour about the situation of the right ureter, and removed it flush with the bladder with a wire écraseur. The wound in the bladder was not sutured, but a large drainage-tube was inserted. Since the 1st of May passed all urine by the urethra. On May 10th got up. Wound quite healed, and patient well in every way.

The tumour was examined by Mr. Shattock, and said to be simple papilloma. It is preserved in St. Thomas's museum.

May 17th, 1887.

---

13. *A case of villous tumour of the bladder. (Card specimen.)*

By Frank Hewkley and E. Hurry Fenwick.

This bladder was removed from the body of a man aged 60, who began passing bloody urine in May, 1885, though for two years (?) previously he had been troubled with frequency of micturition. Up to the date of onset of the frequency he had been in good health. Family history good.

The frequency gradually increased after the appearance of the blood until October, 1886, when the call was repeated every ten to fifteen minutes. At this date he came under Mr. Hewkley's care, and the following note was made:

"Every act of micturition is associated with extreme distress, the bladder being thrown into a state of spasm; the straining culminates in a widespread agony. Towards the close of the act rectal prolapse occurs with escape of glairy mucus or fæces. Sometimes at the conclusion the patient would vomit or faint. His stream of urine is full, unbroken, and forcible. Night and day are the same."

The character of urine varied as regards blood, but always contained albumen. It was generally acid, 1002 sp. gr. The colour ranged from "pure blood" to a porter colour; sometimes it had even a smoky aspect. It never contained pus, nor did it ever become offensive. For weeks together the blood used to disappear, the longest interval of freedom being seven weeks. No microscopical evidence of growth obtainable.

A feeling of a soft something was communicated to the sound when the instrument explored the right side of the bladder. A growth was diagnosed at an early period, but patient refused absolutely any form of operative interference, and he died exhausted twenty-one months after the appearance of hæmaturia.

Notes of the autopsy by Mr. E. Hurry Fenwick.—The bladder and kidneys only were examined, a more extensive autopsy being prohibited. The bladder wall is thin, its muscular wall fasciculated, and the mucous membrane is pouched here and there between the muscle bundles ranged on the back of the bladder. One pouch, the size of marble, is found by the side of the displaced orifice of the left ureter, which opens into it posteriorly. A large villous mass is seen on the right side of the viscus. In shape the mass is oval, four inches in length, and three quarters of an inch in breadth. It is placed obliquely at the opening of the right ureter, which it has dragged from its position; the muscular wall subjacent to and adjoining the growth is hypertrophied. The right kidney is in an extreme state of chronic interstitial nephritis from pressure. The left kidney appears healthy. The growth is benign as regards structure, and could have been removed by supra-pubic incision.

April 10th, 1887.

14. *Double epithelioma of the bladder.*

By W. Bruce Clarke, M.B.

E. R—, aged 60.

The symptoms in this case dated back about three and a half years. There had been two attacks of bleeding, the second following the first, at an interval of two years; shortly after this a third and a fourth, which continued till his death with scarcely any intermission. Death occurred from peritonitis, owing to the bladder wall being perforated by the ulcerating growth.

There are two distinct growths to be seen in the bladder: one round the urethral orifice, which has been cut in two in opening the bladder, and is villous in appearance; and the other, situated almost in the apex of the bladder, displayed no villi, but assumed the characters of an ulcer, and finally made its way into the peritoneum.

Unfortunately no *post-mortem* examination could be obtained till nearly forty-eight hours after death, and the specimen was too far advanced in decomposition to yield any satisfactory microscopic specimens. The sections were cut and prepared by various methods, but the only one which displayed any distinctive characters was the slide which is exhibited. It has been stained with picrocarmine, and shows the villous outgrowths on the surface of the tumour and the downgrowths of epithelial processes, so that there can be no doubt that the specimen in question is a true epithelioma. Though it is very rare to find two separate tumours in the bladder, this specimen is by no means absolutely unique in this respect, a somewhat similar specimen in a bladder having been shown by Dr. Samuel West on a previous occasion at this Society. There does not appear to be any malignant continuity between the two growths. No attempt was made to verify this statement by a microscopic examination of the intermediate bladder wall, owing to the advanced stage of decomposition. *December* 21*st*, 1886.

15. *Encephaloid disease of apex of bladder.* (*Card specimen.*)

By E. Hurry Fenwick.

This specimen is shown as a good example of the rarest position for bladder growth—the summit. Statistics of one hundred cases show this part to be affected in three cases, this specimen being included in the list. It is also shown as an illustration of the duration of a primary vesical growth. Symptoms were here observed for ten years before death.

The gentleman from whom this specimen was removed had been troubled with frequency of micturition for ten years, and had been obliged from time to time to wear a urinal; this trouble was evidently vesical, for his prostate was small for his age. Six months before death the calls for micturition became unbearably frequent. Every ten minutes he would strain violently to relieve himself of a few drops of foul urine, and great pain in the perinæum was experienced during the act. The bowels acted coincidently with urination. Latterly his penis, scrotum, and thighs were in a state of acute eczema from the soakage of putrid urine passed involuntarily, and his health rapidly failed. There was but little loss of weight.

Bimanual examination revealed the bladder to be full of growth, and the capacity, as determined by injection, to be 1 oz. He came under observation a week before death. On *post-mortem* examination the bladder was seen to be somewhat distended, and it felt so full, thick, and elastic as to suggest the feeling of a sarcomatous tumour, or a bladder tensely filled with blood-clot. The prostate was soft and small; the perivesical fat was large in quantity; the basal connective tissue, and its prolongations along the ureter, felt thick, firm, and condensed. Turning the bladder on to its face there was noticed, on the posterior superior surface, the projection of a walnut-sized mass of carcinoma, the growth having evidently penetrated the coats of the viscus at this spot. On opening the bladder on its anterior surface no cavity could at first be discovered. The entire cavity was filled to distension with brain-like matter, the dead white colour of which was relieved by the bright red of large and recent hæmorrhages. Towards the base of

the bladder were found collections of coagulated pus and clumps of necrotic tissue.

With careful washing the growth was reduced in size, and it was then seen to have sprung from the summit and the surrounding area, and to have hung from thence pendent and progressive. The middle and the lower zone of the bladder was found to be quite free from growth, but inflamed and encrusted here and there with phosphatic deposit.

The right ureter was enlarged to the size of the little finger; its mucous membrane was pigmented. The left ureter was not enlarged. The right kidney was replaced by a large multilocular sac containing five polished stones, the largest of which was the size of a thumbnail. The left kidney was large and apparently healthy. The aorta and other vessels were very atheromatous. No secondary deposits were discovered, nor were the glands found enlarged.

May 17th, 1887.

---

16. *Chondrifying sarcoma removed, together with multiple papillomata, from the male urinary bladder.* (*Card specimen.*)

By Samuel G. Shattock.

The tumours were removed by Sir Henry Thompson, by means of supra-pubic cystotomy, from a male patient (W—) aged 55, on August 18th, 1886.

The clinical details of the case are fully reported in the 'Transactions of the Clinical Society' (1887) by Sir Henry Thompson, to whom I am indebted for the exhibition of the specimen.

The presence of a tumour, largely composed of cartilage, within the urinary bladder is surprising enough to suggest the possibility of some error. Sir Henry Thompson, however, is quite sure that on his part no error has arisen; and I am equally sure on mine that the specimens exhibited are each and all those sent to me by Sir Henry Thompson.

Excluding minute fragments, there are altogether six portions; the largest measures about an inch in its chief diameter, the

smallest about half an inch. They have, with one remarkable exception, the usual macroscopic structure of vesical papillomata.

The external character varies slightly in the different tumours, as it often does; in some, the processes of the growths are finely branched, like long compound papillæ; in others the surface is raised in wavy intercommunicating ridges, the free edges of which are but slightly or not at all cleft.

The exception referred to is a solid spheroidal growth five eighths of an inch in its chief diameter. Its more central part, as exposed in section, is composed of firm translucent cartilage.

The mucous membrane over the growth is inseparable from it; the surface of the membrane, save about the base, is devoid of fimbriation; the general exterior of the growth is slightly lobulated.

Histology.—This tumour consists in part of perfectly formed cartilage, and in part of sarcoma tissue. The latter is of the spindle-celled and mixed kinds, and the process of its chondrification is readily traceable; the cells become surrounded by matrix, and by their subsequent multiplication and secondary capsular formation there is produced the characteristic structure of ordinary cartilage.

The surface of the mucous membrane is for the chief part smooth and rugose, but in spots it bears branching papillary processes; these are of the ordinary character, *i.e.* formed by a delicate centre of connective tissue with epithelium, but some (much coarser than these) are composed of spindle-celled sarcoma tissue continuous with that of the tumour.

Sections of one of the papillomata, studied in the light of the preceding evidence, show no unequivocal characters of malignancy. There is somewhat more tissue in the processes than usual, but this has the characters of unstriped muscle, or is formed of tissue with oval corpuscles like that seen under various conditions of connective-tissue formation, and, though suspicious looking, it hardly has the structure of typical spindle-celled sarcoma. The tumour corresponds, indeed, with those classed by Sir Henry Thompson[1] as fibro-papilloma, of which Dr. Gibbes writes, "Here there is a distinct outgrowth from the wall of the bladder, of trabeculæ composed for the most part of non-striped muscle tissue; from these arise secondary trabeculæ, into which the non-striped muscle tissue is continued in varying amount according to

[1] 'Tumours of the Bladder,' 1884.

their size; the growth is covered with layers of columnar epithelial cells exactly similar to those of the normal bladder."

Remarks.—This specimen is almost, if not quite, unique by position, for the mere formation of a chondrifying sarcoma in such a situation is in itself nothing highly remarkable, since the possible distribution of such tumours is conterminate with all the forms of connective tissue.

Ordonez is cited by Cornil and Ranvier ('Pathological Histology') as having recorded a case of chondroma of the walls of the bladder in the 'Gazette Médicale,' 1856. The original description of this tumour does not render its nature so clear as might be desired. The vesical wall was thickened generally to about a centimetre, semi-transparent, greyish white in section, presenting granulations like half-cooked grains of tapioca.

The bladder was filled with a brownish-yellow, transparent substance, like gelatine, strewn with small white flakes. There was tubercular disease of the prostate, which was enlarged on the right side, and contained small tuberculous foci of the size of peas. The microscope showed well-formed cartilage, the basis of which in places presented a fibroid aspect, the fibres, in general isolated, forming large meshes, in which were one or many cartilage cells.

The gelatinous substance filling the bladder contained an enormous number of cartilage cells, the white flakes floating in this being meshworks of fibrous tissue holding cartilage cells.

The growth, it is clear, was malignant, and cannot therefore be rightly termed a chondroma. Possibly it was an infiltrating myxoma mingled with cartilage, or it may have been a chondrifying sarcoma, in which mucoid softening had occurred.

On October 1st, 1886, I received a note from Sir Henry Thompson, in which he says, "The patient bled more than usual after the operation. He stayed here a month exactly, and we have heard since his return once. He has still some bleeding occasionally, goes about his garden, and is not the worse for it."

On May 17th, 1887, nine months after the operation, Sir Henry Thompson sent me the entire bladder, the patient having shortly before died. Owing to the difficulties under which the parts were obtained the prostate was left behind, so that the condition of the latter is not determinable.

The bladder is the seat of very extensive disease. There is a large, soft growth, about two inches in diameter, encroach-

ing upon the cavity from the base; the right ureter passes through the middle of this growth, and is dilated to about twice its normal size behind it; the left ureter is similarly dilated, but its orifice is free of this, the main part of the disease.

The interior of the bladder over this tumour is for a considerable extent raised in delicate intersecting ridges; in places this condition culminates into distinct papillomatous outgrowth. In other spots there project more compact polypoid processes, some of them nearly an inch in length.

From the main tumour the walls of the bladder, chiefly the muscular and subperitoneal, are very extensively infiltrated, the peritoneum being adherent and raised in low elevations on the back of the viscus.[1]

Microscopic sections taken from the infiltrated wall show the growth to be a round-celled sarcoma. There was no cartilage in the sections, and none was detectable with the naked eye in any part of the tumour.

Perhaps no better comment on the clinical aspect of the case can be made than by quoting Sir Henry Thompson's own caution (loc. cit., p. 60): "It may be remarked here that the mere presence of papillæ on a tumour, whether met with in the simple form, which has just been referred to, or when assuming the long fimbriated form previously described, does not serve in any way to identify or characterise a growth, since such papillæ may be met with springing from the surface of heteroplastic growths, as epithelioma and cancer."

In the present case the papillomatous outgrowths removed by operation were probably growths over a more deeply-seated and serious neoplasm, the existence of which was disclosed only by the portion of chondrifying sarcoma removed together with them.

November 16*th*, 1886.

[1] The different specimens referred to are in the museum of St. Thomas's Hospital.

17. *Acute tubercular exfoliating cystitis (perforation).* (*Card specimen.*)

By E. Hurry Fenwick.

This specimen was removed from the body of a seaman aged 25, who was admitted into the London Hospital under the care of Mr. McCarthy, in the last stage of tuberculosis of the bladder. A putrid pig's bladder, half full of foul and decomposing urine, was found tied round his penis, in lieu of a urinal. The man himself was in a low muttering delirium, but the mate of the vessel to which he belonged gave the following account of him:—Three months ago, on leaving the China station, the patient began to lose flesh, and seemed ailing. He was not driven to his work, for he looked wretchedly thin and ill.

Two and a half weeks previous to his admission he began to have trouble with his water; soon losing control and suffering greatly from supra-pubic pain. The bladder symptoms therefore ran their course in *three* weeks, for he died soon after being warded, a period extremely short when the extent and gravity of the lesions found at the autopsy are considered.

Post-mortem examination revealed the presence of acute purulent peritonitis, evidently induced by a perforation of the bladder in the upper left lateral segment. On opening the bladder the mucous membrane was found to have been completely removed by tubercular inflammation. The muscular coat was also superficially fretted, and formed a surface not unlike a Turkish towel. The surface was deeply injected and covered in every part by a sprinkled deposit of yellowish caseous matter, the index of the rapidity of the inflammation.

The trigone was especially interesting. The interureteral bar had been cleanly dissected out, and, bulging forwards, left behind it a well-marked, deepish, post-trigonal pouch. The lateral borders of the trigone had been likewise cleaned. The left ureteral opening was smooth and healthy, but the right could not be found, and on turning to the back of the bladder the corresponding ureter was found transformed into a fibrous cord, feeling as thick as a No. 12 French catheter. On section a minute pigmented canal only

existed. The perforation before mentioned had a smooth edge, and equalled in size a No. 9 catheter (French gauge).

The prostatic urethra had disappeared, and the *entire* prostate had been converted into an abscess sac, the wall of the abscess being formed by the capsule of the gland. No pus or caseous deposit was found in it, and the difficulty experienced during life in passing a catheter was thus explained. The left kidney was large, and had disseminated miliary tubercle throughout its substance. The right kidney was small, and only one eighth of an inch of the secreting structure was left, the remainder of the gland tissue had been transformed into a multiloculated cyst, the cavities of which were lined with a thin layer of caseous deposit. There was no pelvis to the ureter. Both testes were small. The left epididymis contained a caseous focus. Both vasa deferentia were dissected out; the left contained two small caseous foci near the entrance of the canal into the prostate. The lung was infiltrated with miliary tubercle, and there was a similar deposit at the base of the brain. This specimen is an illustration of two separate specimens shown during the session 1885-86, "Congenital Atresia of Ureteral Orifice and Tubercular Exfoliating Cystitis," pp. 300 and 310.

May 17th, 1887.

---

18. *Purpura hæmorrhagica of the bladder.* (*Card specimen.*)

By E. Hurry Fenwick.

This bladder was removed from the body of a child aged 9, who was suddenly seized with a succession of fits two months before death. For six months previously she had been observed to get up at night to pass water, and her urine passed in the daytime was excessive. Three weeks before the fits she became anæmic, her face got puffy, her body emaciated, and she complained of loss of sight. Her urine presented all the features of acute nephritis. Three weeks before death the child became gradually blind, and both retinæ, on ophthalmoscopic examination, were found to be detached by effusion, which gravitated with the position of the body. Hæmaturia of a vesical type, melæna, petechiæ on legs, and

uræmia ushered in death. At the autopsy the heart was found hypertrophied (5½ oz.). The right kidney was seen to be undeveloped; its weight was ¾ oz., its pelvis was dilated, its surface was lobulated like a fœtal kidney, and what remained of its secreting structure was besprinkled with urates, chiefly ranged along the uriniferous tubes. The right ureter was somewhat large, but quite free from inflammation. The left kidney showed signs of chronic interstitial nephritis with the grafting of an acute attack upon it. The left ureter was dilated, pigmented, and acutely congested.

The bladder felt thick, its walls were hypertrophied, and the mucous membrane presented an unusual appearance. The mucous membrane was extremely œdematous, and was raised up from the subjacent tissue in patches, reminding one forcibly of gelatinous polypi. This condition was more marked on the posterior surface.

There were no large submucous hæmorrhages, but covering the entire surface were innumerable hæmorrhagic points, the source, evidently, of the vesical hæmaturia. The central part of the trigone was free; its edges, however, were œdematous, and resembled in aspect the appearance of the detached retinæ. The cervix of the uterus was extremely congested, and with this exception the generative organs were normal.

A similar specimen, presented by Dr. Murchison, is in the Museum of the Royal College of Surgeons (No. 3601).

May 17th, 1887.

---

19. *Bladder, kidney, and dura mater from a case of purpura.* (*Card specimen.*)

By F. Charlewood Turner, M.D.

In the bladder there are massive elevations of the mucous membrane, produced by hæmorrhagic extravasations into the submucous tissue, covering the trigone, and extending upwards over the posterior wall. They are as much as one third of an inch in elevation. There is no ulceration of the mucous membrane.

The kidney is divided longitudinally, and shows extensive hæmorrhage under the mucous membrane of the pelvis and calyces.

In the pelvis of the kidney is a loose coagulum of extravasated blood. There is no hæmorrhage in the renal tissue.

The dura mater shows numerous hæmorrhages beneath its inner lining membrane, mostly in the parietal regions, and more abundant on the right side, where the inner surface of the dura mater is roughened over the most elevated hæmorrhagic areas.

From a girl, aged 7, admitted into the London Hospital under the care of Dr. Sutton on March 28th, 1887, with general purpuric eruption and great debility. She was a delicate child, and had been out of health for six months, getting weak and thin. She had lost her appetite, and had taken no green vegetables and but little potatoes during this period. There were petechiæ over the mouth and bleeding from the gums, but no ulceration or loosening of teeth. There were no pains or swellings about the joints. She was intelligent but apathetic.

There was nothing abnormal discoverable in the thoracic or abdominal viscera. There was some enlargement of the lymphatic glands. The temperature was 102° on admission, and had risen to 103° the following morning. After falling to 101° that evening it rose progressively to 104° shortly before her death in the night of April 1st—2nd. On the morning of April 1st she passed some claret-coloured urine. That passed on the previous day was amber coloured, with a thick deposit of urates containing some blood-corpuscles, and slightly albuminous. On admission, the urine had sp. gr. 1005, with no albumen and no deposit.

At the autopsy there were a few petechiæ on the surface of the lungs, many upon the surface of the ventricles of the heart, which were contracted. The peritoneum in the pelvis was discoloured by abundant extravasations under it, which extended up the psoas muscles, and the omentum was studded with minute petechiæ. In the stomach and ileum were a few extravasations, in the latter into solitary follicles. The colon was studded with pigmented spots. The spleen was enlarged with conspicuous Malpighian bodies; the brain pallid. *May 17th*, 1887.

20. *Urinary organs from a case of Bilharzia hæmatobia. (Card specimen.)*

By Reginald Harrison.

From a man who came under the care of Dr. Mackie, of Alexandria, suffering from continued pain and the passing of urine mixed with blood, and quantities of débris containing ova of bilharzia. Perinæal urethrotomy was performed with some advantage. The patient died a fortnight afterwards of uræmia.

At a *post-mortem* examination the walls of the bladder were found full of small tumours filled with ova. The kidneys, ureters, and rectum were also similarly affected. *December 7th*, 1886.

---

21. *Spontaneous disintegration of vesical calculus.*

By W. M. Ord, M.D.

The fragments of a vesical calculus now shown have been passed within the last six months by a gentleman aged 75. The patient has been under my observation during the last six years. During that period his urine has always contained sugar in varying quantity, very often albumen, and very often crystals of uric acid in large quantity. About ten months ago obstruction of his left femoral artery, followed by superficial sloughing of the skin of the leg, occurred. From that time till now he has kept his bed. About three months after the beginning of his illness he began to pass the fragments. They were passed with no great amount of suffering, and with slight hæmaturia. He had been subject to no shock or violence, and no catheter had been passed. Neither in the bladder nor in their transit have they, till quite recently, produced any urinary obstruction; although, looking at their size, such obstruction might have been expected. Retention of urine occurred a month ago, due possibly in part to the impaction of a fragment in the vesical surface of the urethra, due also to enlarge-

ment of the prostate. Under the able treatment of Mr. Buckston Browne the obstruction has been relieved, and the patient can partially empty his bladder by voluntary effort.

The fragments appear to have become detached from the surface of a calculus of some size—not less than an inch in diameter. Some must have been recently broken off. Others, having rounded edges of fracture and fresh material uniformly deposited, must have remained in the bladder for some little time after separation from the main calculus.

I have already had the honour of showing to this Society five specimens illustrating the occurrence of the spontaneous disintegration of vesical calculus. In this instance it appears to me that the disintegrative influence has been from without. The fragments consist of uric acid, with a small addition of urate of ammonia. They are not very compact in their structure as seen under the microscope, and their appearance suggests that they have been peeled off, so to speak, from the surface of a loosely laminated calculus. During the time in which the patient has been under care the urine has varied considerably as regards the quantity of albumen and sugar present.

It appears to me probable that the variations in the proportion of sugar have been the chief cause of the breaking up. They have been large enough to exert effects upon the surface of the calculus; effects such as might be produced by alternations of drying and moistening—drying by urine of high specific gravity containing much sugar, moistening by urine of low specific gravity containing little sugar or none.

In our collections we often see calculi breaking up and falling to pieces in the simple process of drying. But in addition it is possible that the process of "molecular disintegration" due to variations in the constituents of the surrounding medium, and independent of any kind of chemical action, may have taken a part in the disruptive process. *January* 18*th*, 1887.

22. *Calculus formed round an india-rubber umbrella ring.* (*Card specimen.*)

By E. Hurry Fenwick.

These fragments of stone, weighing 140 gr., were removed by lithotrity at St. Peter's Hospital; but the india-rubber ring, upon which the calculous material had formed, was found after death in the bladder of the patient. The history of the case is as follows:—A deaf mute, aged 22, with infantile paralysis of the right side, was brought by his father for relief. Symptoms of stone had been noticed three months. The boy had been in the habit of masturbating.

A stone was detected and crushed by Mr. Heycock, under whose care the case came, and to whom I am indebted for permission to publish these details. It was noticed, however, that the fragments evacuated did not correspond to the size of the stone which had been gauged by the lithotrite at the commencement of the operation, and the most careful sounding did not reveal where the deficit lay. The boy developed symptoms of peritonitis and died.

On *post-mortem*, slate-coloured pus was found in the sheath of the right rectus, which proved to be an extension upwards of severe extra-peritoneal cellulitis, which I found had started and had spread from the posterior surface of the bladder. The loops of small intestine which occupied the rectovesical pouch were glued together and to the back of the bladder by soft lymph. The bladder and prostate were therefore removed *en masse*, and the former was opened in front. The vesical wall was thick, its cavity contracted, being only as large as a duck's egg. An india-rubber ring was found behind the trigone; one side of its circumference rested on the interureteral bar, and the other dipped into an ulcer of the posterior wall. On removing the ring and examining the ulcer more carefully it was seen to have perforated all the coats of the bladder with the exception of the peritoneal, and it was evident that the urine had percolated through this opening, and had set up primarily cellulitis and secondarily peritonitis. There is no doubt that this ulcer must have finally given way under the distending force of the water used in the evacuation of the fragments, for

the traces of the rush of water were visible under the peritoneal covering up to the top of the bladder in the form of fine calculous débris.

The mucous membrane of the bladder was inflamed, the ureters healthy, and the condition of the other viscera apparently normal. It is presumable that the split umbrella ring had been pressed down the canal to produce erotic sensations. Although the list of foreign bodies found in bladders is a long and a curious one, and seems to comprise all that human ingenuity or the subtle vagaries of idiocy could suggest and employ, yet it does not embrace an umbrella ring. The case has, however, an important clinical aspect. It will be at once conceded that the operator may be justly exonerated for having left so soft, so elastic, so resilient a body as india rubber in the bladder after litholopaxy. Doubtless, when his instrument engaged the ring he would suppose that a fold of atonic bladder had been grasped, and would wisely desist from crushing the same, while it is obvious that so sound-deadening a material would give no just or reliable evidence of its presence when struck with the beak of a solid steel sound. *November 2nd*, 1886.

---

23. *Large vesical calculus with hair-pin as nucleus.* (*Card specimen.*)

By Sydney Jones.

This specimen was shown by Mr. Sydney Jones for Dr. Sparke, of Mansfield. It was removed by him on the 18th of March, 1885, by the supra-pubic operation. It was a large calculus, four and a half inches in its long diameter, two and a half inches in the short (transverse) diameter; a hair-pin ran obliquely through it, the bend of the pin being backwards, the points forwards. The history from Dr. Sparke was as follows:—Lucy M—, aged 20, domestic servant, unmarried, came to him complaining of complete incontinence of urine. She was very weak and fragile, having continued to do her work when quite unable to do so. On examination a stone of large size was at once detected. She admitted that about five years previously she was scratching herself with a hair-pin when she lost it, and thought no more of the matter.

A supra-pubic operation was done by Dr. Sparke under the

spray. There was no complication or difficulty; except on extraction, on account of the large size of the calculus. She died six days after the operation from exhaustion. Bladder not sutured. There was no peritonitis; no infiltration of urine. The wound, which was not sutured, was healing. The stone, recently removed, weighed 7¾ oz. *December 7th*, 1886.

---

24. *A case of carcinoma of the right lobe of the prostate.*

By E. Hurry Fenwick.

The patient from whom this specimen was removed was 53 years of age, and the following is a brief outline of his case:—Six weeks before his death he consulted my friend Dr. Astley Cooper for a sudden difficulty in defæcation. This was at the end of February, 1886. He had always enjoyed good health, but had suffered from a stricture of the urethra for fifteen or sixteen years, for which he was in the habit of occasionally using a bougie. There was no history of syphilis, but certain suspicious scars of an ulceration thirty years ago were found upon his legs. He was not suffering any pain.

On examination *per rectum* Dr. Cooper discovered a tumour of the prostate, the size of a large Tangerine orange, projecting backwards into the bowel. The tumour grew rapidly, and I was asked to see the patient in consultation on March 15th.

The following note was made:—"G. L—, somewhat emaciated; suffers no pain; is losing no blood, either from the urethra or rectum; there is no difficulty in micturition. The rectum is occupied by a large tumour, which is springing from the prostate. The surface of the mass is smooth and covered by normal rectal mucous membrane. It is not softened in parts, but elastic throughout. It is apparently fixed, more to the right than the left side. It is impossible to say whether the base of the bladder is invaded or not. The index-finger can just reach the upper limit of the mass."

I saw him again at the end of March, and found the tumour considerably increased in size. The bowel was now almost occluded; the finger was insinuated with difficulty into the rectum and passed over the tumour.

The surface was ulcerated and the examining finger slipped into a deepish cavity formed by the breaking down and fungating out of the growth. The bladder and urethra were displaced upwards, and the bladder had to be relieved by a Coudée catheter, a pint of residual urine being withdrawn each time. The patient was suffering extreme pain from the obstruction and from the driblets of liquid motions which passed over the open sore.

Recurrent hæmorrhages of a profuse character were slowly exhausting him. I therefore proposed and performed left lumbar colotomy, with the kind assistance of Dr. Astley Cooper and Mr. Thomas.

The patient was greatly relieved, but sank on the 8th April, just six weeks after the first onset of the symptoms.

Autopsy.—The bladder is somewhat hypertrophied, but free from any trace of invasion of the growth; the right lobe of the prostate is transformed into a small cocoa-nut sized mass of encephaloid carcinoma, which has fungated at its most projecting part. The left lobe is small for the patient's age, and quite free from any deposit; there was no deposit elsewhere in the body.

There are some points of great interest in this case. In the first place, there is the extreme rapidity of the growth of the tumour—an increase which could be realised week by week; secondly, there is the absence of all pain until the growth ulcerated; and, lastly, we have the unusual limitation of the disease to one lobe, and the fact that it grew towards and implicated the rectum, rather than, as is generally the case, the bladder and urethra.

October 19th, 1886.

---

25. *A case of metastatic carcinoma of the prostate.*

By E. Hurry Fenwick.

I do not hesitate to bring this specimen of carcinoma before the Society for inspection and criticism, for it is an extremely rare one.

Carcinoma of the prostate is rarely observed in the living subject, and is still more rarely published, whilst secondary carcinoma of that gland, or "metastatic carcinoma," as it is termed by our

French *confrères*, has been observed only four times.[1] In three of these cases the primary growth was in the stomach, and in the fourth the seat was in the dura mater. With the exception of Mercier's case all are named carcinoma (presumably of the hard type); in Mercier's case there was a large encephaloid tumour found.

The history of the case from which this bladder was removed is as follows:—J. M—, aged 26, on the 1st May, 1884, was seized with pains in his back of a sharp shooting character; they were most severe on stooping down. He believed he had caught cold by sitting, at his trade of bootmaker, in a draughty shop. He gradually lost flesh, strength, and colour, got very sleepless, and applied for relief five weeks after onset of symptoms.

He was carefully examined, and the case was looked upon as one of lumbago, and this diagnosis was somewhat confirmed by the ease he obtained when at rest in the horizontal position. He had been a total abstainer. His urine was 1028 sp. gr., not albuminous, but phosphatic, faintly acid. Both parents were rheumatic.

He was treated with various anti-rheumatic drugs and anodynes, but with little effect. He became emaciated, and the pain increased considerably. There was tenderness when pressure was made over both loins.

In July he complained of numbness of the knee-joints. He was admitted into the London Hospital under the care of Dr. Gilbart Smith, to whom I am indebted for the case.

On July 16th his urine was tested and found normal, with the exception of increased phosphates.

On July 17th he was seized with an attack of retention, which was relieved by catheter, and which subsequently merged into a state of complete incontinence. This was one month before death. There were no lung symptoms. Simultaneously with the urinary trouble there commenced a gradual loss of sensation and motion in lower half of the body, which culminated a little before his death in complete paraplegia. Still no organic mischief could be detected. He got gradually weaker, cystitis supervened, diarrhœa set in, and

[1] Langstaff, 'Catalogue of Prepar. in London Museum,' 1842, p. 352; Mercier, 'Recherch. Anat. Patholog.,' Paris, 1841, p. 160; Guyot, 'Bullet. de la Societ. Anat. de Paris,' 1856, p. 457; Lebert, 'Traité d'Anat. Pathol.,' vol. i, p. 323.

he died exhausted, two months and a half from the onset of the pain in the back.

Autopsy revealed a large fist-sized primary scirrhoid growth in the left lung, and scattered small patches of secondary deposit were found in the liver, spleen, and kidneys. Embracing the tenth intercostal nerve near its exit was another deposit, which could be traced to the cord. On slitting open the bladder there were the usual evidences of cystitis. I did not expect to find those grave changes which occur in a sudden loss of vesical power, such as is seen in fracture of the spine, but I was surprised to find the bladder so free from ulceration, after so long a period of enervation.

The bladder was obovate, was smaller and thicker than normal. Muscular tissue was increased. Internally, the mucous membrane was not ulcerated, with the exception of the ureteral mouths and mouth of the bladder. At these places there was a localised shreddy ulceration covered with phosphatic crust. There were the ordinary patches of congestion, and the folds of mucous membrane covering the columnæ carneæ were injected. I therefore removed the bladder for future dissection, and in a week or two's time returned to its consideration. I was at once struck with the size and appearance of the section of the prostate, and thought I had labelled a gland of fifty-five years with commencing hypertrophy by mistake. I then noticed that the surface was cupped like a scirrhus of the breast appears on section. My notes were as follows:

Prostate uniformly hard, large for twenty-six, cutting like leather, surface yellowish white, speckled, and cupped. The hardness extends backwards into that part which is called the third lobe, and to the adjacent bases of the vesiculæ seminales. The latter are harder and firmer than usual.

On cutting microscopical sections of the prostate in various directions I was surprised to find that the gland had become the seat of innumerable deposits, and the case resolved itself into a secondary carcinoma of the gland. These sections are submitted to the Society, and are so stained that the growth deposits show up clearly against the lightly stained prostatic tissue.

March 15*th*, 1887.

26. *A case of carcinoma of the left vesicula seminalis and adjoining lobe of prostate.*

By E. Hurry Fenwick.

I removed this specimen from the body of a man aged 59, who had been admitted into the London Hospital suffering from overflow from an engorged bladder. I am indebted to Mr. Tay, under whose care the patient came, for permission to publish the case.

Nine months before his death the patient noticed a diminution in the size and force of his stream. This symptom was rapidly followed by the passage of "small pellets of coagulated blood." He then began to suffer from great frequency of micturition, and finally, two and a half months before death, the urine, which was now occasionally tinged with blood, began to flow away involuntarily. A month before death he was admitted into the hospital, and it was noticed that the left lobe of his prostate and the corresponding vesicula seminalis were harder and larger than the corresponding parts of the other side. His bladder contained about fifteen ounces of alkaline residual urine, of a pale colour and sp. gr. 1010. His family history was a good one. He himself had never suffered from syphilis or any urinary complaint. An attempt to evacuate the residual urine was followed by a profuse vesical hæmorrhage and a rapid rise of temperature. The residual urine was removed little by little, and he was able, after a fortnight of vesical irrigation, to retain his water four or five hours at a time.

Repeated and exhausting hæmorrhages from the bladder now took place, and he died nine months after the first onset of the symptoms. The clots of blood and the urine were frequently examined for small pieces of growth but without success.

Autopsy.—On cutting into the bladder I found the anterior wall to be unusually dense and thick, for the muscle was infiltrated. The cavity was small, and the mucous membrane, with the exception of the part next to be described, was healthy. The left half or two thirds of the trigone, and the parts surrounding the left ureteral orifice, had been transformed into a flat patch of carcinomatous growth. This patch was so suggestive of invasion that

the back of the bladder was immediately examined. The left vesicula seminalis and the adjoining posterior part of the left prostatic lobe were found hard and transformed into a carcinomatous growth. The left ureter was surrounded, and its lumen plugged, with the same growth. The right ureter was enlarged, and both kidneys showed signs of chronic interstitial nephritis. No secondary growths were found, and the viscera, with the exception of anæmia, showed no marked change.

November 16th, 1886.

---

27. *Thickened capsule of testicle.* (*Card specimen.*)

By G. N. Pitt, M.D.

The right testicle is enclosed in a dense white fibroid capsule an eighth of an inch thick. The mediastinum testis, and the epididymis are also densely fibroid. The vas deferens is not thickened.

The tunica vaginalis is adherent to the tunica albuginea. There are two small cysts half an inch in diameter at the upper end, containing yellow clear hydrocele fluid. The testicle is healthy in appearance; it is increased in size, being wider than the left one by a quarter of an inch.

It is unusual to find such a dense capsule. Possibly it may be due to an obliterated hydrocele cavity. There was a slight hydrocele on the left side. The capsule showed no caseous or gummatous change.

The specimen is from a man aged 55, who died of chronic Bright's disease, of whom nothing is known.

March 3rd, 1887.

---

28. *Cystic tumours of the testicle.*

[With Plate X, and Table of Cases.]

By Frederic S. Eve.

My excuse for entering on the consideration of these peculiar tumours is the uncertainty still existing regarding some points in their morbid anatomy, and especially of their pathogenesis. Further, I am not aware of any considerable recent monograph dealing fully with the subject; nor do I think it probable that any observer has had the opportunity of examining so many specimens of the disease as I have been able to select from the museums of the Royal College of Surgeons and St. Bartholomew's Hospital.

The descriptions are based on a microscopic examination of twelve specimens, and to these have been added a table of twenty-eight recorded cases, in which a careful microscopical examination had been made.

These tumours may be divided into two well-marked groups—the innocent and malignant, or cystic fibromata or sarcomata. To these a third may conveniently be added, having characters often intermediate between them, and may be termed cystic myxomata or myxo-fibromata.

The common cystic fibroma or adeno-fibroma of the testicle is illustrated by many beautiful specimens in the College museum, of which No. 4220[1] may be taken as a good example. The characteristic features of this disease are only apparent on section, when the testicle is seen to be occupied by a tumour composed largely of cysts of tolerably uniform size, and usually not exceeding a quarter to half an inch in diameter. The cysts are largest and most numerous at the upper and posterior part of the tumour in a position corresponding to the mediastinum testis; they have a definite wall of fibrous tissue, and many of the cyst-like cavities are really of a tubular form; this is obvious on microscopic examination, and that they intercommunicate more or less widely is shown by the fact that fluid injected into one tubule issues from others at a considerable distance from it.

[1] Particulars of all the cases referred to under a number or the name of the author may be found by reference to the Table of Cases.

The contents of the cysts are various, the smaller often containing a ropy mucus, and the larger a clear or brown serous fluid. In very many tumours there are cysts filled with a solid, curdy material, having sometimes a pearly lustre. From this circumstance the name of pearly bodies or cholesteatoma[1] was given to them, from the supposed presence of crystals of cholesterine.[2]

The stroma in typical cases is dense and fibrous, and in nearly all the fibro-cystic tumours tortuous rods or nodules of cartilage are embedded within it. The rods have occasionally, as in simple enchondroma of the testicle, a narrow central channel, which is shown by microscopic examination to be produced simply by degeneration and softening, The amount of cartilage present is very variable and may be so insignificant as to escape observation, except with the microscope, or it may constitute the chief bulk of the tumour. It is said to be usually most abundant at the posterior part of the growth.

A thicker or thinner layer of the substance of the testicle, atrophied and compressed, may be distinguished in most specimens. It usually forms a thin covering to the upper and anterior, and more rarely to the lower part of the tumour.

Microscopical appearances.—Sections show large cyst spaces and tubules embedded in a variable amount of fibrous tissue. Their walls are formed of concentric layers of fibrous tissue, and some are lined with epithelium; but in many of the larger cysts this has disappeared, either by degeneration or in the process of cutting the sections.

In some instances the lining consists of several layers of epithelium; the outermost or deeper layer of cells are elongated or columnar; then follow several layers of spheroidal cells, which towards the free surface become longer, flat, and pavement-like. Caird and Richon observed (see Table), in their cases, that the middle or intermediate layer of cells were dentated or "prickle-cells," like those of epidermis.

In many specimens there are cysts filled with laminæ of coherent, large, flattened epithelium forming the masses described

[1] Müller, cholesteatoma; Billroth, atheroma perlé; Cornil and Ranvier, epitheliome perlé.

[2] According to Kocher (op. cit., p. 335) in one variety of cystic disease the contents are fluid, ropy, and mucous, and in another they are fatty like those of atheromata of the skin. But this distinction does not, I think, exist as cysts are formed often within the same tumour, the contents of which present these differences.

above as cholesteatoma. They are evidently formed by the accumulation of epithelial cells in cysts, and their flattening by pressure. But in nearly all examples of cystic fibroma there are some cysts or tubules, especially the smaller ones, lined with longer or shorter columnar epithelium. In two typical examples from adults I found ciliated columnar epithelium (see figs. 1 and 2). In Athole Johnson's case of fibro-cystic tumour in an infant all the cysts were lined with ciliated epithelium; and Hertzberg has recorded a remarkable case of congenital tumour, in which were cysts forming chains, and lined with ciliated columnar epithelium. There was no adenomatous formation. The tumour was of walnut size, and involved the testicle only.

Changes are evidently brought about in the character of the epithelium by pressure. This is shown in fig. 2, in which at one part of the wall of a cyst lined with ciliated columnar epithelium the cells are quite flattened. Similar changes are observed in the epithelial lining of ovarian cysts. In explanation of the occurrence of several layers of flattened epithelium[1] in some of the cysts and tubules, it may be thrown out as a suggestion that the superficial cells are flattened from pressure; and this is the more probable as the flattened cells occur in the larger cysts and tubules. The columnar epithelium too may be caliciform or "goblet-shaped" from the formation of mucus within the protoplasm.

It is scarcely necessary to say that the cysts are evidently formed as the result of dilatation and cutting off of portions of tubules by valvular folds or otherwise. Microscopic appearances are observed which may be taken to indicate a new formation of epithelium and a continuous formation of tubules and cysts. In sections of a typical specimen of innocent cystic fibroma (No. 2789 St. Bartholomew's Hospital Museum) I noted solid rounded outgrowths or buds which projected into the surrounding stroma from cysts lined with ciliated epithelium (see fig. 1). The buds were composed of small round and apparently "embryonic" or young cells. Near them small columns or tubules filled with similar cells were cut across. Other appearances which may be similarly interpreted were observed in other specimens. There were also rounded groups and elongated strips of spheroidal cells,

[1] Two other hypotheses appear tenable on this point: one is, that the evolution of embryonal epidermic cells to cylindrical cells is not complete; the other, that there is an attempt to form dermoid structures.

to be subsequently alluded to. The new formation of tubular spaces and cysts lined with small spheroidal epithelium was especially obvious in Mr. Hutchinson's case of cystic sarcoma (see Table). But I am entirely in doubt as to the probable mode of origin of this tumour, as it contained no columnar epithelium, and there was no trace of the body of the testicle, whereas the epididymis was well developed. This specimen I had the opportunity of examining when fresh.

Virchow speaks of sprouts of epithelium springing from the tubules in a case of cystic fibroma, and considers them evidence of epithelial new formation.

Occasionally, fibrous intracystic growths exist. And I have seen microscopic papillary ingrowths of epithelium.

The minute structure of the stroma of the cystic fibromata has some peculiarities of interest. The stroma of the denser forms is composed chiefly of interlacing fasciculi of coarse fibrous tissue; in parts it may be softer, looser, wavy, and reticulated, or studded occasionally with patches of myxomatous tissue. In many specimens are fasciculi of spindle-cells, which in some instances may be in process of development to fibrous tissue. But in others in which these cells persist, form well-marked bundles, and do not show any tendency to develop into fibrous tissue, there are good grounds for believing that the tissue is plain muscle-fibre.

In the Hunterian specimen No. 4220, in which the fibrous stroma was exceedingly dense and well developed, I noticed such bundles. It may here be mentioned that Malassez notes the presence of unstriped muscle in a specimen of cystic myxoma, and Lagrange in a mixed tumour in part cancerous.

Mr. R. W. Parker's case of congenital cystic myxoma is remarkable for the existence of bundles of unstriped muscle around the tubules.

The occurrence of striped muscle in tumours of the testicle will be adverted to in speaking of the cystic sarcomata.

The minute structure of the cartilage presents some points of interest. In many instances it has characters intermediate between those of hyaline and fibro-cartilage. The matrix is less transparent and more homogeneous than in ordinary hyaline cartilage, and forms thin bands enclosing nucleated cells with clear but scanty cell-substance. The cells are round, oval, compressed, rarely branched, and of relatively small size. The growth of the nodule takes place at its periphery, where there is a thin layer of

myxomatous-looking tissue; and the manner of transformation of this tissue into cartilage reminds the observer of the mode of formation of fœtal cartilage from embryonic cells as, for example, in the protovertebræ.

The tumours of the second group or cystic myxomata are sufficiently distinctive to merit a separate description, the more so as they have attracted but little attention.

In illustration of them I shall take specimen No. 4228 in the College museum; it was removed by Mr. Liston from a man, aged 33. The disease had long existed, and was believed to have originated in a blow; its growth, slow at first, was at last rapid. There was no return of the disease after operation. A section of the tumour presents a soft glistening texture intersected by fibrous bands; scattered sparingly throughout it are cysts for the most part one eighth of an inch, but reaching half an inch in diameter. Many of them (especially the larger) are nearly filled with finely lobulated growths of soft connective tissue. No cartilage could be found either with the naked eye or with the microscope.

This tumour, in its microscopic characters, will bear comparison with some cystic myxomata or soft connective-tissue tumours of the breast. Its stroma consists of loose fibrillar connective tissue containing round, branched, and a few stellate connective-tissue cells, with fasciculi of fibrous tissue interspersed throughout it. But the chief peculiarity of the tumour lies in the existence of narrow slit-like tubules or solid rods of gland tissue. Some are nearly straight, and run for considerable distances across the section; many are curved and some branched. The tubules are lined with a single or double layer of small columnar epithelium, while that of the solid rods varies from small nuclei to columnar epithelium. Many of the tubules are dilated into irregular elongated or oval spaces or cysts with tubules and rods passing out from their walls. The gland tissue was everywhere surrounded by a thick zone of mucous connective tissue more transparent than that of the rest of the tumour, a peculiarity which exists in the myxosarcomata of the breast. Malassez has described a tumour similar to the preceding. The patient was twenty-one years of age, and had noticed an enlargement of the testicle for seven months. The tumour was composed largely of cysts, and was surrounded by the expanded substance of the testicle. The cysts were lined with flattened or with cylindrical epithelium, the latter

being in places ciliated, and in others goblet-shaped from the presence of mucus. The stroma was composed of soft connective tissue interspersed with bundles of spindle-cells, believed to be fasciculi of plain muscular fibres. The tubuli seminiferi in the expanded substance of the testicle were in various stages of compression and atrophy, but in no instance were they dilated. Malassez gives the name of 'myxoid cystom' or 'épithéliome myxoides' to this tumour.

The case described by Mr. R. W. Parker and also that of Richon may perhaps belong to this group, which, however, is connected by such gradual transitions to the cystic fibromata on the one hand and the cystic sarcomata on the other, that sufficient data are not always present to allow of exact distinction.

The cysts are not usually so large and abundant as in the cystic fibromata, and are usually lined with columnar or columnar ciliated epithelium, although in Malassez' case, in some cysts, the epithelium was pavement-like. The proper substance of the testicle was expanded over the surface of the tumour in Malassez' case, but was not observed in the others mentioned.

The third group, or cystic sarcomata, as they may roughly be termed, form a large proportion of cystic tumours of the testicle. The cysts are usually less abundant, smaller, and less uniformly distributed throughout the tumour than in the cystic fibromata. Cartilage is less constantly present, and often forms a mass at some part of the growth.

A layer of the expanded substance of the testicle proper is found in a considerable proportion of cases. The epithelial lining of the cysts, as far as I have been able to observe, does not differ essentially from that of the fibromata. It is often mixed, but columnar epithelium preponderates over the laminated form, while the reverse is the case in the fibromata. This may be due to the fact that the growth of the tumour is more rapid, and therefore there is less time for the expansion of tubules by an accumulation of fluid and consequent flattening and lamination of epithelium. Yet in the sarcomata, cysts are found filled with laminated epithelium, fig. 3 having been taken from one.

The characters of the stroma of these tumours are so various that it would lead me much beyond the space which this paper should occupy were I to describe them fully. Let me briefly state that it may be composed of round or round and spindle-celled

DESCRIPTION OF PLATE X.

To illustrate Mr. Eve's paper on Cystic Disease of the Testicle. (Page 201.)

FIG. 1.—Cystic fibroma of testicle. The drawing represents a cyst lined with columnar ciliated epithelium. From its walls buds composed of small, round, epithelial cells project into the stroma. Some of these buds are seen in transverse section to the left. (No. 4 Hartnack, oc. No. 2.) From specimen No. 2789 St. Bartholomew's Hospital Museum.

FIG. 2.—From a cystic fibroma of the testicle, showing tubules lined with ciliated epithelium; at one part flattened from pressure. (× 230 diam.)

FIG. 3.—Cyst filled with laminated epithelium. Above a small tubule lined with columnar epithelium. From a cystic sarcoma of the testicle. (× 11 diam.)

FIG. 4.—Gland-tubule from a cystic myxo-fibroma of the testicle. The tubule is at one part dilated, at another obliterated from pressure; it is lined with small columnar epithelium.

Fig. 1 is from a drawing by T. Godart; Figs. 2 to 4 from drawings by Mr. Eve.

Fig. 1



Fig. 4

Fig. 3

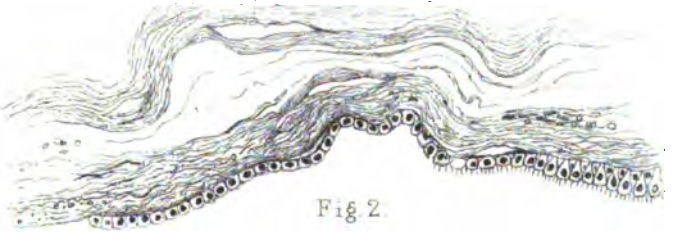

Fig. 2

West Newman & Co lith

tissue, of fasciculi of spindle-cells alone, or intermingled with fibrillar connective and myxomatous tissue, or again, of fibro-sarcomatous tissue. Myxo-sarcomatous tissue is commonly present, either forming a considerable portion of the tumour or distributed in scattered patches. Billroth, Senftleben, and Ehrendörfer have recorded a case of malignant cystic disease of the testicle containing striped muscle. In Ehrendörfer's case the muscle was found in the centre and at the margin of the tumour. The fibres were long, narrow, and frayed out or "dendritic" in arrangement. This specimen of highly cystic tumour is described as cancer. But the diagnosis is open to doubt as the stroma was myxomatous besides containing muscle, and some of the cysts were lined with cylindrical epithelium. Moreover, the metastatic growths were not examined. It must also be remembered, in regard to cases described as "cancer" in the accompanying table, that most of them were examined before the line between sarcoma and cancer was drawn as sharply as at present, and when the tendency of sarcoma of the testicle to take an alveolar form was not recognised. I am therefore of opinion that most of these cases were sarcomata.

Cystic cancer undoubtedly occurs; and a good example exists in the College museum, No. 4235, the tumour involving the testicle of an Italian greyhound. There were also appearances indicative of cancer in some parts of specimen No. 4223 in the College Museum.

Having described the chief naked-eye and microscopic characters of the cystic tumours of the testicle, two questions remain for consideration:—First, what is the relation of the different forms of cystic tumours among themselves? And that having been discussed, there then comes the next questions,—How do they originate, and what are their homologies?

In regard to the first question, the chief point to endeavour to decide is, whether the innocent and malignant cystic tumours of the testicle are practically different, that is, originate in different structures, and have different relations to surrounding structures, or whether they are merely varieties of the same form of tumour. This question may, I think, be decided by examining the relation of the cystic fibromata and sarcomata respectively to the remains of the testicle, and by comparing each tumour to see if certain structures are common to both.

In the accompanying table, it is noted that in six cases of presumably malignant tumours a layer of testicle substance was

spread out over the whole or some portion of the surface of the tumour, a condition well known to be observable in most cases of cystic fibroma.

Again, the tubules and cysts in the cystic sarcomata, like the fibromata, are lined both with the columnar and flattened epithelium. Certain structures, as striped and unstriped muscle, ciliated epithelium, and cartilage constituting characteristic features of the cystic fibromata, are present in the malignant varieties. In three cases described as "cancerous," in two of which the diagnosis was confirmed by subsequent metastasis, striped muscle-fibre was found; and in one of these ciliated epithelium also existed. Unstriped muscle was said to be present in Malassez' case of myxoma, in Mr. Parker's of congenital sarcoma, and in Lagrange's mixed malignant tumour. The mean age at which adult patients came under observation with each form of tumour differs but slightly.

Finally, in my opinion, it may with truth be said that certain tumours show conditions intermediate between the innocent and malignant growths. Such, I take it, are those with a stroma composed of a mixture of fibrous and mucous connective tissue (cystic myxomata). And several apparently well-marked examples of cystic fibroma (as, for example, No. 2789 in St. Bartholomew's Hospital Museum) show microscopically many suspicious nodules of round-celled tissue.

All these facts incline me strongly to believe that there is no genetic difference between the cystic fibromata and sarcomata; that their origin is similar, although the character of the stroma differs. The development of cysts is much more marked in the cystic fibromata, but this may be explained by the rapid growth of the sarcoma tissue compressing the epithelial tubules in the malignant, and the slower growth allowing more time for their dilatation in the innocent tumours.

These two forms of tumour, therefore, probably originate in the same manner. But, before passing on to consider this second question, it may be convenient to state the views with regard to it expressed by previous writers.

Sir Astley Cooper believed that the cysts arose by dilatation of the tubuli seminiferi, and hence entitled his monograph on this subject the "Tubular Disease."

Curling first showed that the disease originated in the mediastinum testis, and held that the cysts were produced by dilatation

of the normal tubuli of the rete testis. Virchow and Billroth assented to this view, but both commented on the fact that a new growth of epithelium was observable in their cases. Nepveu, Klebs, and others considered that the cyst formation was due to compression of the tubuli by a primary growth of cartilage or connective tissue. In late years examples of cystic disease have been described as cystic adenoma by Kocher, Malassez and Ehrendörfer. Kocher's able article is not free from some confusion, as he hesitates to place some specimens of common fibro-cystic disease among the cystic fibro-adenomata.

Mr. Shattock[1] and, after him, Mr. J. Bland Sutton,[2] have contended that cysts in cystic disease of the kidneys originated from Wolffian remains included in the permanent kidney,[3] and the latter author has drawn a parallel between this disease and cystic disease of the testicle.

Mr. Sutton says (op. cit.), in the innocent variety of cystic disease of the testicle, "the cystic spaces are lined with tesselated epithelium, and arise from dilatation of the collection of mesonephritic remains familiar as the organ of Giraldés, situated between the testis and epididymis." But he has not supported this view as regards the testicle by any original histological observations. In passing, it may again be mentioned that the cysts in the innocent or fibro-cystic disease of the testicle are not exclusively lined with tesselated epithelium, as first stated by Mr. Curling.

Some time previously (Erasmus Wilson Lecture on "Cystic Disease of the Breast and Testicle," 1883) I suggested the possibility of the origin of the cystic disease of the testicle from fœtal remnants, and stated the case as follows:—"The mixed character of their [cystic tumours] constituents, as in the presence of cartilage and sometimes of striped and unstriped muscle, lends some support to the view that they are of the nature of teratomata, and perhaps originate in connection with the anterior or sexual portion of the Wolffian body normally present in the mediastinum testis." It was for this lecture that the greater part of the work involved in this paper was done. It is my intention, in the succeeding portion of it, to consider the question of the actual mode of origin of the tumours under discussion.

[1] 'Trans. Path. Soc.,' vol. xxxvii, 1886, p. 287.

[2] Erasmus Wilson Lectures, 1887, 'Lancet,' Feb. 5th, 1887, p. 256.

[3] Mr. Lockwood has combated this view, see 'Brit. Med. Journal,' March 5th, 1887, p. 501, as I think with good reason.

Curling's view, that cystic disease begins in the mediastinum testis, is generally accepted. It is supported by the following considerations:—the position of the tumour, the existence of a layer of the parenchyma of the testicle expanded over it; the presence, in nearly all specimens, of tubules lined with columnar and, in some, of columnar ciliated epithelium, which could only have been derived from the structures of the hilum and epididymis. On the other hand, careful examination of the peripheral layer of expanded parenchyma of the testicle (among other observers by Malassez and Ehrendörfer) has shown simply atrophy of the tubuli seminiferi without any trace of cystic dilatation. Ehrendörfer observed colloid masses in the atrophied tubules, but these changes never went on to cyst formation. Further, any observations showing that the disease is due to dilatation of the tubuli seminiferi are wanting. In the accompanying table of forty cases of innocent and malignant cystic tumours, in twenty-one there was a more or less distinct layer of testicle parenchyma at some portion of the surface of the tumour.

But it is necessary to go further, and inquire if the cysts are simply due, as Curling apparently believed, to a dilatation of the normal tubules of the rete testis? Or again, if we are to accept, with Kocher and others, the view that there is a new formation of epithelium, or an adenoma springing from the normal ducts in this region? Or lastly, if the cysts and tubuli originate solely from an adenoma-like growth of certain structures enclosed within the hilum, and derived from the remains of the Wolffian body?

Apart from arguments which might be adduced on general grounds, there is microscopic evidence in favour of the view that an actual new formation of epithelium takes place.

I have already adverted to the fact that in innocent tumours I observed evidence of new formation in the form of buds of small, apparently embryonic, cells springing from fully-formed tubules (see fig. 1).

Billroth and Senftleben noted solid dendritic sprouts of epithethelium in the malignant tumours described by them, and Ehrendörfer has figured appearances indicating a new formation of epithelium (op. cit., Taf. v, figs. 21, 21). These three cases all contained striped muscle, and although described as cancers they clearly belong to the malignant form of cystic tumour.

Granted, then, that there is a new formation of epithelium, it

would be difficult to disprove an assumption that this new growth proceeded from the normal tubules of the hilum. I must rather adopt the alternative and bring forward reasons in support of the view that it originates from fœtal remains.

In the first place there can be no doubt that the epididymis and vasa efferentia are formed from the anterior or sexual segment of the Wolffian body or mesonephros. The exact mode in which the junction of the Wolffian tubules with the tubuli seminiferi takes place is still uncertain. Mr. Lockwood in his recent lectures has advanced the view that there is a distinct growth from the Wolffian body into the hilum; and this may be in some measure borne out by the circumstance that, embedded in the hilum of the normal testis, are numerous groups of peculiar cells, which Klein believes to be derived from the epithelial columns of the Wolffian body, and analogous to similar remains in the hilum of the ovary. The cells are polyhedral, and are "arranged in plate-like, cylindrical or irregularly shaped, anastomosing masses" lying between the laminæ of intertubular connective tissue. In some animals these structures are very abundant, and in the boar they form a predominant portion of the whole testicle (Klein).

Roth also observed, in the rete testis, vasa aberrantia lined with ciliated columnar epithelium, which ran for a considerable distance along the epididymis, and terminated in cæcal extremities.

If Klein's view of these structures be correct, there are therefore in the hilum of the testicle abundant fœtal rudiments. Considering their origin from the Wolffian body, they might be anticipated, in the event of their taking on active growth, to form tubules lined with columnar or columnar ciliated epithelium, in fact structures resembling the epididymis and its prolongations into the testicle. And, as the rudiments in question are composed of polygonal epithelium, a complete transformation of these to columnar cells in some tubules might not take place. Another explanation is thus offered of the ununiformity of the epithelium in certain cystic tumours. I also observed in more than one example of cystic fibroma appearances favouring this view, and an imperfect attempt has been made to show them (fig. shown). There are rounded groups and strip-like masses of spheroidal cells lying near and even continuous with tubules.

Again, let me remind you that the tubules of the epididymis, coni vasculosi, and vasa efferentia only are lined with *ciliated*

columnar epithelium, while the vasa recta forming the rete testis are lined with short columnar cells. Now, the presence of columnar ciliated epithelium in many tumours in adults has been noted; and in a case of large cystic tumour in an infant recorded by Mr. Athole Johnson, all the cysts were lined with columnar ciliated epithelium. Supposing that these growths were adenomata originating from normal tubuli they must have been derived from the vasa efferentia or epididymis and not from the rete testis lying in the hilum; but, owing to the peripheral position of the first named ducts, the tumours would in that case be expected to project backwards and involve the epididymis. On the contrary, however, they project forwards into the testicle, and I cannot therefore think that they can be derived directly from the vasa efferentia. But the fœtal rudiments or interstitial cells of Klein not only occupy the hilum but the interstices between the tubuli seminiferi. Therefore the acceptation of the hypothesis that the cystic adenomata originate from these rudiments is the only way I see out of the dilemma in which one is otherwise placed in explaining the presence of ciliated epithelium in these tumours.

The hilum cysts of the ovary (described in 1881 by Coblentz in his almost classical monograph on cysts originating in fœtal rudiments in the female ('Virchow's Arch.,' Bd. 84, S. 26) offer a nearly, but not quite analogous example of cysts formed by dilatation of remains of the Wolffian body, and in Hertzberg's case (see Table) of congenital cystic disease of the testicle the resemblance seems to me extremely close. But the analogy does not entirely hold good, for although the ovarian hilum cysts may be filled with papillary growths, it has not been shown that there is any adenoma-like growth of epithelium, and the stroma is insignificant in amount.

It might further be argued that the mixed character of the stroma of the cystic tumours of the testicle allied them to the teratomata, and pointed to their origin from fœtal rudiments. Too much stress must not, however, be placed on this, as cartilage commonly occurs in the sarcomata apparently arising in the body of the organ. The frequent occurrence of cartilage in tumours of the testicle may probably be explained by the circumstance that the stroma of the testicle is derived from embryonic cells lying in close relation to the protovertebræ. The presence of striped muscle may be similarly explained, as Cohnheim pointed out in the

case of the myo-sarcomata of the kidney. Again, regarding the striped muscle found in cystic tumours of the testicle it cannot be maintained that it is derived from the gubernaculum Hunteri, for in the only two instances of this mode of origin recorded respectively by Neumann[1] and Rokitansky, the tumours were situated at the inferior pole of the testicle near the point of attachment of the gubernaculum. They were solid, composed for the most part of striped muscle, and were distinct from the testicle.

The presence of smooth or unstriped muscle may, however, be taken as a further indication that the tubules of the cystic tumours have a common origin with those of the epididymis and coni vasculosi, the tubules of which are surrounded by a layer of unstriped muscle. This is especially so, when, as in Mr. R. W. Parker's case of congenital tumour, the tubules are surrounded by a layer of muscle.

The chief conclusions to which this inquiry has led me may be briefly stated as follows:

1st. There is no genetic difference between the innocent and malignant cystic tumours of the testicle; they are merely varieties of the same form of tumour.

2ndly. The tumours originate in the hilum of the testis.

3rdly. There is evidence of a new formation in these tumours of highly organised epithelial tissue, and it is therefore convenient, for anatomical classification, to describe them as adeno-fibroma, myxoma, or sarcoma, as the case may be.

4th. That the prototype of the epithelial formations is found in the tubules of the vasa efferentia and rete testis.

5th. There are grounds for believing that the tubules and cysts originate in certain elementary outgrowths from or rudiments of the Wolffian body existing throughout life in the hilum testis.

6th. But it is incorrect to say that they are derived from the organ of Giraldés, for these tubular remnants of the Wolffian body are situated between the testicle and epididymis, and altogether outside of the testicle. Besides, the cystic disease is produced, not merely by a dilatation of pre-existing tubules, but by a new formation of epithelium.

A brief analysis of the table of cases may be of some value, and is of interest as showing a much closer parallel than might have been anticipated between the innocent and malignant groups. It

[1] See 'Cent. f. Chirurgie,' No. 52, 1886, S. 912.

Table of Cases of Cystic

Reference.	Nature of Tumour.	Of Stroma.	Age of Patient.	Duration.
Hunterian, R. C. S. Mus., No. 4220	Cystic fibroma	Fibrous	...	...
R. C. S. Mus., No. 4222, Mr. Cock	Ditto	Fibrous; masses of small spindle-cells	...	...
R. C. S. Mus., No. 248, Sir A. P. Cooper	Ditto	Fibrous	...	...
St. Bart.'s Hosp. Mus., No. 2789	Ditto	Fibrous, but many nodules of round-cells	40	Slowly growing
St. Bart.'s Hosp. Mus., No. 2793, Sir J. Paget	Ditto	Fibrous	58	20 yrs.
F. M. Caird, 'Edinburgh Med. Journ.,' Nov., 1885	Ditto	Ditto	24	16 mos., followed a blow
Athole Johnson, 'Trans. Path. Soc.,' vol. vii, 1855, p. 241	Ditto	Ditto	2 yrs. 9 mos.	2 yrs. 6 mos.
Hertzberg, 'Virchow's Jahrbericht,' 1885, Bd ii, p. 247	?	Ditto	2 yrs.	Congenital
Wurzberg Mus., Kocher	Cystic fibroma	...	...	...
Ditto	Ditto	...	...	...
Kocher, Case 1, 'Billroth and Pitha's Handbook'	Ditto	Some nodules of round-cells	...	...
Kocher, Case 2, idem.	Ditto	...	...	...
Virchow, Case 1, 'Archiv,' Bd. viii, S. 404	...	...	...	...

Disease of the Testicle.

Cartilage Present.	Muscle Present.	A Layer of Testicle Substance expanded over Tumour.	Results.	Nature of Epithelium of Tubules and Cysts, and other Particulars.
Yes	Probably unstriped muscle	Not observable	...	Chiefly spheroidal and flattened; smaller tubules with cylindrical. Solid columns of small spheroidal cells. "Cholesteatomata" cysts abundant and of moderate size.
Yes	?	Yes	...	Columnar and ciliated epithelium chiefly; some flattened. Stripes and rods of spheroidal cells.
No	...	Not observable	...	Spheroidal and flattened epithelium; a few small tubules with columnar.
Yes	...	Yes	Patient in good health 4 years after operation	Ciliated columnar, sub-columnar or cubical. Solid buds of epithelium springing from tubules.
Yes	...	Not observable	Ditto 12 mos. after operation	Tube-like spaces filled with small spheroidal epithelium, which for most part had disappeared.
Yes	No	Yes	...	Chiefly tesselated; a few with cylindrical. "Cholesteatomata."
No, but osseous mass	...	Yes	...	Ciliated columnar. Many cysts.
No	No	Tumour lay in testis	...	Tumour of walnut size involving testicle. Composed of cysts forming chains lined with ciliated columnar epithelium.
Not mentioned	...	Yes	...	...
Yes	...	Yes	...	Cysts filled with flattened epithelium.
No	...	Not noted	...	Tubules lined with, also columns of columnar epithelium, with "buds" springing from them.
Much	...	Yes	...	In part ciliated columnar epithelium.
Yes	...	Yes	...	Pavement-like epithelium.

Table of Cases of Cystic

Reference.	Nature of Tumour.	Of Stroma.	Age of Patient.	Duration.
Virchow, Case 2, idem.	Cystic fibroma	...	...	...
Jabez Hogg, 'Trans. Path. Soc.,' vol. iv, p. 180	...	...	30	1 yr.
Curling, Case 1, 'Med.-Chir. Trans.,' vol. xxxvi, p. 240.	Cystic fibroma	...	37	7 mos.
Nepveu, Case 1, 'Soc. Anatom.,' 1870, p. 66	Ditto	Fibrous, some islets of mucous tissue	28	11 mos.
Nepveu, Case 2, idem.	Ditto	...	25	...
Ehrendörfer, 'Langenbeck's Archives,' Bd. xxvii	Ditto	Fibro-myxomatous	...	...
R. C. S. Mus., No. 4228, Liston	Cystic myxofibroma	Ditto	33	Long duration
Malassez, 'Arch. de Physiologie,' vol. vii, p. 122	Ditto	Chiefly myxomatous	21	7 mos.
Richon, 'Bull. Mém. de la Soc. de Chirurgie,' p. 132, 1883	Cystic myxosarcoma	Myxomatous	22	½ yr., appeared after blow
R. W. Parker, 'Trans. Path. Soc.,' vol. xxxvi, 1885, p. 299	Ditto	Patches of myxomatous tissue	3 mos.	Congenital
S. Q. Silcock, idem., p. 301	Sarcoma	Spindle-celled and myxosarcoma	8 mos.	Congenital
R. C. S. Mus., No. 4231, Mr. Hutchinson	Cystic myxosarcoma	Myxomatous	5 mos.	...
R. C. S. Mus., No. 4233, Mr. Cock	Sarcoma, a few cysts	Round-celled	55	10 mos.
Ditto, No. 4237, Hunterian.	Sarcoma, minute cysts interspersed	Ditto	...	...
Ditto, No. 4223, Mr. Hancock	Chondrosarcoma, cysts small and few	Spindle-celled and fibrillar	...	...
R. C. S. Mus., No. 4224	Chondrosarcoma	In part fibrillar	...	...

Disease of the Testicle—continued.

Cartilage Present.	Muscle Present.	A Layer of Testicle Substance expended over Tumour.	Results.	Nature of Epithelium of Tubules and Cysts, and other Particulars.
Yes	...	Yes	...	Sprouts of epithelium from dilated tubules.
Chiefly	...	Yes	Recovered and remained well	...
...	...	Yes	...	Flattened epithelium. "Tumour developed in rete testis."
Yes	Fasciculi of spindle-cells	Yes	In good health 2 yrs. after operation	Cysts lined with pavement epithelium.
Yes	Ditto	...	. .	Buds of epithelium projecting from dilated tubes.
...	...	...	...	Cylindrical epithelium.
No	No	Not visible	No return	Branching tubules of columnar epithelium, surrounded by myxomatous tissue.
No	Unstriped muscle	Yes	...	Cylindrical, ciliated, calyciform, and some flattened epithelium.
Yes	...	No	...	One layer of columnar, or several layers of epithelium of which inner were flattened, middle "prickle" cells and outer cylindrical.
No	Unstriped muscle around tubules	No	...	Cylindrical epithelium. Growth studded with minute cysts.
...	...	...	...	Tubules scattered in sarcomatous stroma.
Yes	...	No	...	Embryonic gland-tissue composed of small spheroidal epithelium. Origin doubtful.
Yes	Probably unstriped	...	...	Flattened and columnar epithelium.
No	...	...	Metastasis	Small spheroidal epithelium, filling some tubules.
Yes	...	...	...	Masses and rods of sub-columnar and spheroidal epithelium.
Yes	...	...	...	Spheroidal and columnar.

Table of Cases of Cystic

Reference.	Nature of Tumour.	Of Stroma.	Age of Patient.	Duration.
R. C. S. M., No. 4225, Sir. W. Fergusson	Cystic myxo-sarcoma	Spindle-cells and myxo-sarcomatous	...	...
Mr. V. Horsley, 'Trans Path. Soc.,' 1883	Cystic-sarcoma	Round-celled sacoma in nodules?	Adult	18 mos.
Mr. F. S. Edwards	Sarcoma, cysts not numer-ous	Fibro-sarcomatous	30	18 mos.
Billroth, 'Virchow's Arch.,' Bd. viii, S. 433	? "Cancer"	...	25	3 mos.
Senftleben, 'Virchow's Arch.,' Bd. xviii	Ditto	...	35	1½ yrs.
Ehrendörfer, 'Langen-beck's Arch.,' Bd. xxvii, S. 354	Ditto	Myxomatous tissue	22	1½ yrs.
Sir H. Thompson, 'Trans. Path. Soc.,' vol. vi, p. 240	Ditto	...	25	6 mos.
Curling, op. cit., Case 2	Ditto	...	32	18 mos.
Mr. W. Haward	Ditto	...	30	2 yrs.
Billroth, 'Virchow's Arch.,' Bd. viii, S. 270	Ditto	...	31	1 yr.
Lagrange, 'Progrès Méd.,' No. 19, 1882, p. 367.	Mixed, "in part cancer"	...	23	3 mos., imme-diately fol-lowed a blow

Disease of the Testicle—continued.

Cartilage Present.	Muscle Present.	A Layer of Testicle Substance expended over Tumour.	Results.	Nature of Epithelium of Tubules and Cysts, and other Particulars.
Yes	...	Yes	...	...
...	...	Not noted	Secondary growths in lungs, liver, and bladder	Cylindrical and flattened epithelium.
Yes	...	No	...	Several layers of spheroidal or one of short columnar.
Yes	Striped muscle	...	Metastasis in lumbar glands	Sprouts of epithelium from dilated tubules.
...	Ditto	Yes	Died soon after operation with typhoid symptoms	Cysts lined with flattened and ciliated epithelium.
Yes	Ditto	Yes, nearly all	Metastasis	Flattened and cylindrical epithelium.
Yes	...	Yes, in part	Died of cancer	...
...	...	...	Metastasis in lumbar glands	...
Yes	...	Yes	Ditto and in lungs	Collections of large epithelial cells in meshes of fibrous tissue.
...	...	Yes	Metastasis in lumbar glands	Sprouts springing from tubules and columns of epithelium.
No	Unstriped muscle	Yes	...	Macroscopic cysts lined with columnar or flattened epithelium. Peripheral portion of tumour "pure cancer."

has been found convenient to include those tumours containing a large proportion of myxomatous tissue among the sarcomata. The two groups will be spoken of respectively as cystic fibromata and sarcomata, the former being nineteen the latter twenty-one in number.

Age.—Of nine cases of fibromata, in which the age was stated, two occurred in infants, and in one of these the disease was congenital. The mean age of six adults was 30 years. Of sixteen cases of sarcomata there were three in infants, two being congenital; and of the thirteen adults the mean age was 29½ years.

The age taken is that when the patient came under observation; therefore the occurrence of the sarcomata at a younger mean age than the fibromata may in some measure be accounted for by the more rapid course of the disease. The case (see Table) in which cystic fibroma had existed for twenty years is omitted.

Duration.—Excluding again the same case, the mean duration of five cases of fibromata, in which this particular point was stated, was fifteen months.

Of thirteen cases of sarcomata, twelve months. Metastasis occurred in eight cases of sarcoma; in no case of fibroma.

A layer of testicular parenchyma was spread out over the surface of the tumour in thirteen cases of fibroma; it could not be observed in three, and no note was made in three.

In the sarcoma it existed in eight, was unrecognisable in five, and no note was made in eight.

Cartilage was present in twelve cases of fibroma, absent in four, and not noted in three. Among the sarcomata it was present in eleven, absent in five, and not noted in five.

Tissue resembling plain muscle-fibres was observed in three cases of fibromata and four of sarcomata; but, owing to the difficulty of distinguishing it from growing or embryonic connective tissue, these statements must be taken with reserve.

Striped muscle existed in three malignant tumours, but was not found in any case of fibroma.

Several of the sarcomata appeared immediately after a blow, and in some the growth was exceedingly rapid.

Only cases in which a careful microscopic examination was made have been included in the table; and I do not pretend that it is a complete collection of these. Possibly, too, one or more tumours may have been included among the cystic sarcomata in which the

cysts were hardly a sufficiently conspicuous feature to warrant it. In conclusion, I may express the hope that the facts herein collected may be of value, whether the hypothesis of which the case is stated be generally accepted or not. *March 15th*, 1887.

---

29. *Cases of small round-celled sarcoma of testicle and spermatic cord.*

By F. Swinford Edwards.

The first of the three cases of disease of the testicle and cord which I bring before you this evening is that of a man (Thomas L—), aged 50, who came under my care at the West London Hospital on December 11th, 1885. There was no history of cancer in the family. He was married, and had healthy children.

The note on admission runs as follows:—Has always had good health. Eighteen months ago had gonorrhœa. Six months ago was in St. George's Hospital, under Dr. Ewart, with rheumatic fever. He left the hospital a cripple, and went to Bath, where he took the waters, returning to London cured.

Six weeks ago noticed a swelling about the size of a pea, which was painful, and was situated just above the left testicle. It has since increased in size, and the pain is now so great as to prevent any sleep at night.

There is now a globular swelling of stony hardness, the size of a walnut, in the position of the globus major. Another smaller swelling is felt lower down towards the globus minor. The cord is thickened. Both tumours are tender to the touch, as is also the testicle.

On December 18th, the patient having been placed under ether, the tumour was exposed, and a small piece excised for microscopical purposes, as at a previous consultation much difference of opinion was expressed. The wound healed by first intention in four days.

Mr. Eve, to whom the piece of excised tissue had been submitted, reported it to be a round-celled sarcoma; so, acting on this,

I removed the tumour and testicle, ligaturing the different vessels of the cord separately. The patient rapidly convalesced.

The specimen shows a new growth, of the size of a marble, attached to the posterior surface of the epididymis at the site of the globus major. It is hard, and presents a fibrous appearance. A section has been made through it. The vas deferens, at its junction with the epididymis, is infiltrated by a like growth.

The section under the microscope shows infiltration of small round-cells in the substance of cord, extending chiefly along the course of the vessels. In parts the cells appear to be undergoing organization, and this fact raises a doubt as to the malignant nature of the disease; but the clinical symptoms, combined with the histological characters, are, on the whole, we think, in favour of its being a malignant growth.

Case 2.—Mr. C—, a gentleman of robust appearance, between 45 and 50, had, twenty years previous to my seeing him, undergone Ricord's operation for the cure of varicocele on the left side. After a time the induration disappeared, and he had no further trouble in that region until the summer of last year, when he noticed for the first time a small lump in the scrotum about the site of the old operation, and for which he consulted my colleague Mr. Coulson. As Mr. Coulson was leaving town for a holiday, soon after the patient's second or third visit to him, he asked me to take charge of the case.

On examination one felt a very hard swelling attached to and apparently involving the cord just above the epididymis on the left side. It was painful, well defined, and increasing in size. No history of syphilis. Judging it to be probably sarcomatous in character, I advised castration, and with this view took the patient to Sir James Paget, who agreed that the sooner the organ was removed the better. This was accordingly done on September 18th, 1885. The wound healed in its entire length by first intention, the vessels having been tied separately with catgut.

The specimen, which Mr. Eve has been good enough to send up from the Museum of the College of Surgeons, shows a testicle with a rounded swelling an inch in diameter, situated in the spermatic cord immediately above the epididymis. The swelling is firm, and its section is obscurely fibrous, or in parts smooth like fibrous tubercle. The vas deferens courses along the posterior surface.

Sections show under the microscope larger and smaller rounded

masses, composed of central giant-cells, surrounded by a layer of lymphoid cells, these lying in the meshes of a fibrous reticulum.

This specimen, No. 4292A in the catalogue of the College museum, is described as tumour of spermatic cord, probably tuberculous.

Mr. Eve, on first examining the growth, wrote to me that it was sarcomatous; subsequently, I believe, he came across some bacilli, and in conjunction with Dr. Klein pronounced it to be probably tuberculous.

I should like to ask the members of this Society, if they agree as to its tuberculous nature, how one is to account for its purely local existence, for the patient showed no signs of tuberculosis? Is it possible that inoculation took place twenty years previously?

CASE 3 is one of round-celled sarcoma of testis, which I removed from a young man 30 years of age last September. There is nothing of particular interest about the case, and I merely bring it forward as a supplement to the other cases.

E. B— was admitted into St. Peter's Hospital with the left testicle of about the size of a large ostrich's egg. It was heavy, non-translucent; semi-fluctuant in parts; surface even; veins of scrotum dilated; cord not thickened.

The testicle began to swell two and a quarter years ago (four months after marriage); it then became stationary for a period of about a year; swelling then recommenced, and has continued up to present date. Tapping two months ago. Small quantity of blood-stained fluid came away. Lumbar pain for last three weeks. Gonorrhœa eight years ago.

Castration was performed two days after admission. The cord was tied with silk, which separated on the fifteenth day. He left the hospital a week afterwards.

I prefer tying the vessels of the cord separately, but in this case the cord slipped, on division, being retracted within the inguinal canal, which I was obliged to slit up to secure it.

The tumour is composed of a brain-like substance, soft, and easily broken down.

The section, which I am sorry is not a better one, though it is no fault of my friend Mr. Eve, to whom I am also indebted for this, shows that the tumour is made up of round-cells intermingled with a few spindle-cells, and these are supported by some fibrils of connective tissue. *December* 21st, 1886.

30. *A dermoid cyst of the right testis.*

By D'Arcy Power, M.B.

In presenting for your inspection to-night this dermoid cyst of the testicle I must apologise to you for its small size. If it had been allowed to grow, however, I have no doubt but that it would in a short time have rendered itself more worthy of your notice. It is of interest, however, for two reasons: in the first place because it is an example of this rare congenital tumour, and secondly, because, so far as I have been able to discover, it is the first specimen of its kind which has been shown before this Society of which any record is preserved.

Dermoid cysts of the testicle are of much greater rarity than the references to them in text-books of pathology and surgery would warrant us in supposing. Verneuil,[1] after careful search through the literature of a period of more than two centuries, could only bring forward ten instances of such tumours, and they do not seem to have become more numerous since the year 1855, when he published his collection of cases. This scarcity is due in great measure to the fact that many specimens are allowed to pass unrecorded, for during the last few years more than one case has, I believe, been observed at the Hospital for Sick Children in Great Ormond Street.

For the present specimen, as well as for the clinical details which accompany it, I am indebted to Dr. Stanley Wood, of Pontypool, and to his assistant Mr. C. C. Harris. The testicle was removed from a healthy child, aged 4 years, in whom the swelling had been observed for three years. During the early part of this period the tumour only slowly increased in size, but during the eighteen months preceding castration its growth was more rapid. Before removal the testis was freely movable in a normal scrotal sac which was without scar. The enlarged gland felt smooth, it was ovoid in shape, regular in outline and heavy. There was some sense of fluctuation in parts, but there was nowhere any translucency. No nodules could be felt on palpation, but the fluctuating parts were less resistant than the rest of the gland. The testicular substance could not be felt and the epididymis was imperceptible;

[1] 'Arch. Gén. de Méd.,' 5th series, vol. v, p. 644, 1855.

it was therefore apparent that the body of the gland was implicated, and castration was deemed advisable. The spermatic cord was slightly thickened. The parents, so far as could be ascertained, were without malformation.

A closer examination after removal revealed the following characteristics. The right testis is affected, and this is of interest since in the ten cases collected by Verneuil the right organ was affected in six cases.[1] The testicle measures two and a quarter inches in length by one and three quarter inches in thickness. The spermatic cord was at first indistinguishably blended with a mass of muscular tissue and blood-clot, but by a little dissection its component parts have been unravelled, a bristle being passed into the cut extremity of the healthy vas deferens. The epididymis is present as a flattened band lying, as the testis has been divided, between the spermatic cord and the tumour. The tumour itself occupies the whole of the body of the testis, and is enclosed by the smooth and somewhat thickened tunica vaginalis, which is not, however, adherent to it. After the testis had been preserved for some months in spirit the tumour measured two and a quarter inches in length by one and a quarter inches in thickness. On section it is seen to consist of a number of cysts filled with a substance of gelatinous consistency. The cysts vary in size from a small pin's head to one which occupies the whole of the posterior border of the organ. In the recent state this large cyst contained a number of long and delicate hairs which sprang from the deeper layers of its lining membrane. The rest of the tumour is formed by the thick septa between the cysts; they consist of dense fibrous tissue with fat, and in some parts eyots of calcified cartilage.

Microscopical examination shows that the gland tissue has entirely disappeared from the body of the testis. The wall of the largest cyst consists of an epidermis and corium. The free edge of the epidermis is turned towards the interior of the cyst, and it appears as if the proliferation of the cells from this edge had formed the gelatinous contents of the cyst, the cells themselves having undergone some colloid change. The epidermis consists of a thick layer of stratified epithelium lying upon a well-marked rete Malpighii. In some places the epithelium appears to have been tilted forwards, so that the constituent layers form an angle with the surface instead of lying parallel with it. The corium

[1] Op. cit., vol. vi, p. 29.

consists of dense connective tissue containing in its deeper part a considerable quantity of fat and a large number of hair-follicles. Each follicle has well-developed sebaceous glands in connection with it, and each contains a non-medullated hair. The connective tissue is dense and has many of the characters of embryonic fibrous tissue. The minute structure of the tumour is therefore of the same type as the one examined by Professor Goodsir for Dr. Duncan, of Edinburgh.

The specimen is preserved in the museum of St. Bartholomew's Hospital, Series xxxvi, No. 2810 (*a*) and Series lv, No. 122 (*b*).

October 19*th*, 1886.

---

31. *Tuberculosis of the uterus.* (*Card specimen.*)

By R. G. Hebb, M.D.

H. B—, aged 40, was admitted to the Westminster Hospital under the care of Dr. Donkin on June 1st, 1886. Family history immaterial. The condition of her right foot and leg was the result of a burn in 1880. Her present illness began twelve months before admission with vomiting and pain after food; these ingravesced so that for four months previous to admission she had been unable to retain solids. In April, 1886, her legs began to swell. On admission, legs œdematous, abdomen distended and tender. Frequent vomiting; urine acid, 1020, albumen. Died June 7th, 1886.

Post-mortem examination.—Body much emaciated. Right lower extremity, from which the toes are absent, is stiff, contracted, and deeply scarred. The foot is covered with a mass of yellow crusts under which are ulcerating sores. Thoracic viscera normal. Liver, spleen, and kidneys amyloid. Gastro-intestinal tract *nil.* Uterus soft, flabby, and flexed to the right Fallopian tubes, much thickened. On opening the uterus the fundus and tubes are found to be filled with a soft yellow caseous mass, on removing which the wall of the uterine canal is seen to be hollowed out by numerous small irregular cavities, wormeaten as it were. Within

the uterine wall, especially near the cervix, are yellow spherules the size of a large pin's head; ovaries shrivelled.

Microscopical examination of the uterus gave the characteristic appearance of tubercles. *December 7th*, 1886.

---

32. *A specimen of early pregnancy in the fimbriated extremity of a Fallopian tube, with retro-uterine intra-peritoneal hæmatocele, and a decidual cast of the uterine cavity.*

By W. S. A. Griffith, M.B.

This specimen was removed from the body of a woman who died in St. Bartholomew's Hospital, under the care of Dr. Matthews Duncan. The patient was 32 years of age, and though married eleven years had had no previous pregnancy. The catamenia ceased four months before admission, and lately she had suffered from morning sickness, severe right iliac pain and metrostaxis. On examination the cervix was found to be softened, and behind it to the right, in Douglas's pouch, was a rounded, soft, movable, not very tender swelling. A few days after admission she had a severe attack of abdominal pain, and on the following day, with much bleeding, she passed a complete decidual cast of the uterus, without fœtus or ovuline strictures, identical in appearance with the one exhibited. On the third day after this she was seized with a severe attack of pain followed by extreme collapse and anæmia. She died five days later.

At the *post-mortem* examination a large hæmatocele was found filling the pelvis, displacing the uterus forwards, and shut off from the general peritoneal cavity by adhesion of the omentum and intestines to each other and to the uterus and broad ligaments, the adhesions being quite recent and easily broken down with the finger. On cleaning out the blood, which was chiefly coagulated, the conditions shown in the specimen were seen.

The uterus is seen displaced forwards, compressing the bladder against the pubes, and the utero-sacral pouch is distended to its fullest extent.

The gestation tumour is situated immediately within the abdo-

minal orifice of the right Fallopian tube, and forms a mass the size of a hen's egg, situated on the right side of the utero-sacral pouch, above and to the outer and posterior surface of the ovary which it conceals. The extremities of the fimbriæ can be seen on the inner extremity of the tumour into which they are retracted.

On section a minute fœtus is seen lying in a collapsed amnion, and embedded in a mass of chorion and extravasated blood.

The left as well as the right tube have undergone similar changes, which were undoubtedly the cause of the arrest of the ovum in the tube.

The outer third of the left tube and the corresponding portion of the right tube internal to the gestation tumour, are considerably dilated, and have been laid open; the dilated portion ends abruptly in what appears to the unaided eye as healthy tube. The dilated portion is somewhat convoluted and is smooth internally, having lost its longitudinal folds of mucous membrane and its columnar ciliated epithelium.

A microscopical examination of the apparently healthy uterine end of the tube shows the same changes there. The lumen of the tube is larger than usual (though not dilated) from the destruction of the mucous membrane. It is nearly circular, and is lined by a layer of the deeper part of the mucous membrane; it is smooth and slightly undulating, and is quite denuded of columnar epithelium. Its muscular wall appears to be thickened, and the individual muscle-cells of the right tube are undoubtedly enlarged.

It would be natural to call this condition "chronic salpingitis," but our knowledge of diseases of the tubes is too elementary to allow us to do so.

The conditions present appear to indicate a comparative recovery from a destructive inflammation of the mucous membrane.

It is extremely unusual to find in extra-uterine gestation any obvious naked-eye changes in the tubes which can be considered a cause of the condition; in future it will be advisable to examine the tubes microscopically, and we shall not have to resort to such feeble hypotheses as mental emotion and spasmodic stricture as causes of this condition.

The decidual cast exhibited is probably diagnostic of extra-uterine pregnancy, it differs obviously from the menstrual decidual cast shed in so-called membranous dysmenorrhœa, in its much larger size and the greater thickness of its walls. The menstrual

cast rarely exceeds an inch and a quarter in length, is translucent and scarcely a line in thickness, and is rarely passed entire, whilst the pregnancy cast is much larger, and each wall varies in thickness from one eighth to a quarter of an inch.

These casts are triangular bags, with their anterior and posterior walls in contact; the base of the triangle (the shortest side) corresponds to the fundus uteri, the apex with the internal os. At each angle there is an opening; the two base angles are the uterine orifices of the Fallopian tubes, the apex angle the internal orifice of the cervix.

The inner surface of the bag is smooth, and presents everywhere the dilated orifices of the uterine glands visible to the naked eye, The outer surfaces are rough and shaggy, where they are torn off the subjacent tissue.

This specimen also illustrates the anatomy of pelvic hæmatoceles. Effusions of blood into the pelves of women may be either intra- or sub-peritoneal, that is to say perimetric or parametric, and in spite of what has been said to the contrary, it may be safely asserted that any considerable effusion of blood comparable in size with that in this specimen is, with one class of exceptions, usually intra-peritoneal. This class of exceptions is undoubtedly a new condition, produced, and therefore observed chiefly by abdominal operators, who having left a vessel in the broad ligament unsecured, find a large and perhaps a fatal effusion of blood to have taken place in the broad ligament and cellular tissue of the side wall of the pelvis.

With these exceptions hæmorrhages into the cellular tissue of the pelvis are for the most part small in size, and occur in connection with difficult labours.

The term hæmatoma, suggested by Dr. Duncan, should be applied to effusions of blood into the cellular tissue, and hæmatocele retained for intra-peritoneal effusions.

The question of the pre-existence or subsequent formation of the adhesions between the viscera which enclose, and if the patient survives long enough, usually limit the effusion, is difficult to decide for want of sufficient anatomical evidence. In this case there can be no doubt, and I believe it is so in the large majority of instances, that the adhesion of the viscera followed the effusion of blood.

February 1st, 1887.

33. *Note on the pathology of tubal pregnancy.*

By Lawson Tait.

The large amount of attention now being given to all questions of pelvic surgery, and to the pathology of the conditions requiring surgical interference in the abdomen, would be quite enough to justify me in once more drawing attention to the views I have already published on this subject. I have one additional reason for bringing the subject before the Pathological Society in the fact that these views have never yet been criticised, though they have been made the subject of much misrepresentation. They were first given to the Obstetrical Society in 1873, and were immediately characterised by Dr. John Parry, in his classical work on extra-uterine pregnancy, as having at least the merit of simplicity.

Since then my views have received most remarkable confirmation by the results of *post-mortem* examination, by thirty-four operations which I have performed in cases of extra-uterine pregnancy, and by the remarkable observations of Arthur Johnstone and Bland Sutton on the inner surface of the uterus and tube as affected by menstruation. Both of these investigators assert, and, as I believe, prove, that there is no destruction of the endometrium during menstruation beyond the shedding of the epithelium. On the other hand, the endometrium, according to Johnstone, is a glandular structure, having gland functions, the object of which is to prepare a site for villous connections (and probably to assist in preplacental nutrition). The periodic desquamation and turgescence of the endometrium are, in my opinion, essential for the retention of a fertilised ovum, and therefore it comes that we have to reckon pregnancies from menstrual dates. This has involved the larger assumption that menstruation and ovulation are concurrent. That there is no such concurrence—that ovulation does not stand in any relation as the cause of menstruation—was proved by Ritchie in 1842, and this proof has since been amply confirmed by Beigel, De Sinéty and Malassez, Balfour, myself, and others.

A vast mass of clinical material, to which I cannot refer here, has induced me to offer the suggestion that the starting-point (not the cause) of menstruation lies in the Fallopian tubes, structures

which do not exist outside the order of primates, for what elsewhere looks like a Fallopian tube is true uterus, the Fallopian organ existing only as a fimbriated aperture. This suggestion has been distorted into what has been erroneously called Tait's theory of menstruation—the tubal theory. I am not aware of anything I have said or written which justifies this misrepresentation, and in favour of what I have really said are two indisputable facts. The first is that in cases where one or both tubes are occluded and distended by fluid one of the most characteristic symptoms is intense, often agonising, pain during one or more days immediately preceding the appearance of the menstrual flow. For the explanation of this pain I have offered a double suggestion, that the first menstrual flow is in the tube, and that a rhythmical contraction of the tube, to aid its function in propelling onwards an ovum, is the initial fact of each menstrual cycle. Such contraction must inevitably be painful in a tube that is occluded. The first part of this suggestion is proved by a fact I have often observed, that occluded tubes are larger at and just after the menstrual period than they are at the middle and latter part of the intermenstrual period.

The second fact is that the removal of the tubes without the ovaries will, in the majority of cases, completely arrest menstruation.

I have therefore come to the conclusion that the tubes have far more to do with menstruation than the ovaries have, but more than this I have not said, and I have advocated no tubal theory of this curious feature of human sexual physiology.

When we remove a Fallopian tube in a woman we amputate an integral part of the uterus, even though it is altered in function, and largely, in anatomical features. When a Fallopian tube is deprived of its epithelium it is again reduced to its original uterine condition; only its altered anatomical structure and relationship deprives it of an important uterine power, that of almost indefinite expansion. The importance of this change will be seen immediately.

The epithelial lining of the tubes is ciliated, the movement of the cilia being constantly toward the uterus. The function of this ciliary movement has been limited by every writer, so far as I know, previous to my own writing on the subject, to the pushing of the ovum down towards the uterus. I have suggested that addi-

tional functions may exist in the prevention of the passage of spermatozoa into the tubes, and the prevention of the fastening of impregnated ova upon their walls. Numberless experiments on animals with bifid uteri have established the fact that spermatozoa in such animals permeate to the furthest extremity of the uterine tube, quite up to the fimbriated aperture. But as the uterine tubes in these animals do not possess ciliated linings these experiments have only led us astray in their application to human organs, and I have not met with any record of spermatozoa having been found in the normal human Fallopian tube. The conclusion which has been widely, I may say uniformly, adopted, that impregnation may take place in the Fallopian tube in women under normal circumstances is a mere assumption.

I have said that destruction of the tubal epithelium reduces the tubes to their original uterine condition, so far as their inner surface is concerned, and they are then, as I believe, ready to permit the passage upwards of spermatozoa and the attachment of an impregnated ovum to their bared walls. Like epithelium elsewhere of the columnar or single-layered kind, the lining surface of the tubes, when once destroyed, does not seem capable of being reproduced, and the whole sexual mechanism of the woman is thrown out of gear. This is indicated by the history of almost every case of tubal pregnancy where I have been able to get at the facts, and is peculiarly well shown in the case, the last on which I have operated, which forms the basis of this note.

The patient was 43 years of age. She was married for the first time at twenty-two, and had one child. As she graphically expressed it, she was confined on Wednesday and was downstairs on Sunday, and has never been well since. Her child died, and she never was pregnant again. Her menstruation was regular, always profuse and accompanied by great pain. She had a severe illness eight years ago, which was characterised by great pelvic and abdominal pain—it was called inflammation of the bowels, and it kept her in bed three months, and since then she has hardly been out of the hands of the gynæcologist. Another serious attack began last October. She took to her bed on November 6th, and has not left it till convalescent from the operation I performed on her. It is not difficult to believe that this woman's procreative machinery was put out of gear by an attack of pelvic inflammation after her labour, and I suggest that one feature of that was

desquamative salpingitis. Some such history, I have already pointed out, pertains to the vast majority of cases of tubal pregnancy. Another feature, common to all of them in my experience, is that the tube distended by the growing ovum ruptures about the end of the third month. This is proved alike by the history and by the appearance of the ovum. In the present case the history does not help us to the date, but I suspect that the rupture occurred in the early part of November. No fœtus was found at the operation, but the remains of the placenta would justify my putting the usual date as the time of rupture in this case.

For the further elucidation of the views of the pathology of this interesting displacement which I have suggested, it is necessary for me to recall to your minds the primitive facts of the anatomy of the Fallopian tube. It is held loosely in its place by a folded piece of peritoneum passing round its circumference and uniting itself very near its starting-point. The two external surfaces of the peritoneum (that is, external in relation to the cavity of the sac) touch each other, and are loosely united by some cellular tissue as in the broad ligament. There is a narrow line of tube running in its axial direction, at the point where the two external surfaces of the peritoneum meet, which is not touched by the serous coat; and it is not difficult to imagine that as the tube gets distended by the growing ovum these layers tend to get separated, and this uncovered line of tube will therefore increase in width. It is made certain by the preparations I have examined at the time of rupture that the mesosalpinx is practically obliterated by the separation of its layers, just as the broad ligament is obliterated by the growth of a broad ligament cyst, or the occurrence of a broad ligament hæmatocele.

The tube inevitably ruptures, and the site of the rupture is the leading feature, not only of the future pathological changes but of the clinical progress and treatment of the case. The site of rupture is determined by the seat of the placenta, and that seems, as in uterine pregnancy, to be largely a matter of accident. In every case in which I have been able to determine the point of rupture and the seat of the placenta the rent has occurred at the margin of the placenta and in its structure, a fact which at once accounts for the appalling mortality which results from rupture of tubal pregnancies.

The site of the rupture may be at any point of the circumference

of the tubal section, and for the pathology as well as the surgery of the lesion this circumference must be divided into two parts, that which is covered by peritoneum and that which is not. In linear measurement these have a relation of probably ten to one, therefore tubal rupture into the peritoneal cavity is far more common than tubal rupture into the broad ligament. Tubal rupture into the peritoneal sac means death to the mother with almost perfect certainty unless a prompt surgical remedy is employed; indeed Jessop's celebrated case is the only exception about which there can be no doubt. In that case in all probability no serious vascular rupture occurred, the fœtus escaped from the tube; as the placenta grew its villi penetrated whatever it came across, and the child lived to be born by abdominal section—a rarity as great as the Siamese twins.

On the contrary, tubal rupture into the cavity of the broad ligament means, in a great many instances, that the ovum does not die, and I know nothing to make me believe that the mother ever dies of the rupture, for the hæmorrhage is controlled by the fact that it occurs into a mass of cellular tissue, this alone being a powerful hæmostatic, especially for venous hæmorrhage, and into a cavity which resists rapid extension, though capable of indefinite extension at a slow rate. In fact tubal rupture into the broad ligament must rank as an extra-peritoneal hæmatocele for the time being—a matter of little importance. It is the broad ligament pregnancy, formerly known as the "grossesse sous-peritoneo-pelvienne" of Dezeimeris.

The ovum in a great many cases must die, and is absorbed without one knowing anything about it, and without the patient suffering anything more than temporary inconvenience. But in some cases it lives and grows. I have brought seven children into the world near the full time from between the folds of the broad ligament. In one case, at the time of false labour, I operated by the vagina and lost both mother and child. In six I operated by abdominal section and saved five mothers and two children, both of these children being now grown up. Surgical literature is full of cases where the fœtus in the broad ligament has died before the full time, and has been found after death as a lithopedion, or when the ovum cavity has suppurated and been discharged exactly in the positions where a broad ligament abscess ought to discharge itself into the rectum, bladder, and roof of the vagina.

The pathology of extra-uterine pregnancy is thus made extremely simple, and the surgical rules arising from pathological facts are easily deduced.

In a broad ligament pregnancy the death of the fœtus may be secured by the galvanic current, or the case may be carefully watched and a live child delivered by abdominal section. I do not like the idea of killing a child even when it is in the broad ligament, and as it is infinitely likely to be the only child the woman will ever have she may vote for its preservation. But the chief interest, alike pathological and clinical, lies in the tubal pregnancy which ruptures into the peritoneum. Of this kind was the case of the woman, the preparation from whose pelvis I now submit. She was placed under my care by Dr. Annie E. Clark on January 20th after having been in bed since November 6th. She was in great pain, wasted and anæmic. The whole pelvis was occupied by a mass which was ill defined over the pubis; the abdomen was swollen and very tender. Neither history nor physical signs helped us to a diagnosis, but something had to be done to save the woman's life. The only guess that I hazarded—and in pelvic surgery it is only the young and inexperienced who can make a diagnosis with absolute certainty—was that the mass was a strangulated ovarian tumour. I opened the abdominal cavity and found it full of blood-clots and bloody serum, and in a condition of subacute peritonitis. The clots I traced to a rent in the back of a cyst, close to the rectum, and then I felt quite sure that I had to deal with a rotated and strangulated ovarian tumour. It was densely adherent to intestine, uterus, and bladder, and I had to exercise much care in separating it. At last I came to the pedicle and pulled it out. Then I recognised my familiar friend, a distended Fallopian tube, and in it Dr. Clark subsequently found a mass of placenta. No fœtus was ever seen; I drained the pelvic cavity, and the patient made an easy and rapid recovery.

There are many of the surgical features of this case on which I might enlarge if this were the proper place, but I desire only to say that nothing could persuade me to any other belief than that operation was necessary to save that woman's life, and that it did save it. I am also convinced that scores of such cases are lost every year for want of surgical pluck.

What I must speak of is the pathology of the case. The rupture of a tubal pregnancy into the abdominal cavity is the most

terrible accident to which suffering woman is liable. In my experience of intra-peritoneal hæmatocele, ruptured tubal pregnancy forms the sole cause of that formidable condition, and that it is so uniformly fatal is easily explained when we recognise the thin structureless nature of the walls of the bleeding vessels and remember that the hæmorrhage takes place into a cavity capable of holding an indefinite quantity, and therefore possessing no restraining influence against the hæmorrhage. Not only so, but the fluid normally present in the peritoneum seems to have somewhat of a preventive influence against the formation of coagula—a fact we recognise in the value of the drainage-tube as a hæmostatic. *March 3rd*, 1887.

---

34. *Additional note on the pathology of extra-uterine pregnancy.*

By Lawson Tait.

The theory of extra-uterine pregnancy which I advanced in 1873, and further advocated before this Society on March 3rd, 1887, has meet with only one objection so far. When my last paper was read one of the members of the Society urged that my theory, being based on the belief that the rupture of the tube was caused by the placenta, could not be accepted because the placenta was not differentiated till after the third month, whereas these ruptures generally occurred between the tenth and twelfth week.

I could not at the moment quote authorities on embryological development to controvert a statement which, upon clinical grounds, I knew to be absolutely incorrect, but a research amongst authorities entirely confirms the statement of Carpenter that "the formation of the placenta commences in the latter part of the second month, and during the third the organ acquires its proper character." In fact, according to Goodsir, by far the most painstaking, minute, and incontrovertibly accurate observer of such facts, the changes upon which depend, in my belief, the ultimate rupture of the tube begin before the end of the first month. I mean the immersion of

the fœtal tufts in the maternal tissue and the formation of new vessels, and the great increment in size of those in previous existence. The ultimate localisation of this immersion for the subsequent differentiation of the placenta is evident long before the completion of the eighth week.

All the facts are completely proved by two preparations of the Pathological Series of the College of Surgeons Museum (4691 and 4691*a*). The former displays a ruptured tubal pregnancy of the variety known in text-books as interstitial, that is where an adhesion of the fertilised ovum has occurred to the tubal walls on that part embraced by uterine tissue. "The tube enters the ovum cavity," according to the Catalogue, "by a funnel-shaped opening close to the rent on its walls," but this would be more accurately described by saying that the tube had been greatly dilated by the ovum, and that the present funnel-shaped appearance of it is due to contraction after the escape of its contents; for only those who have watched a distended Fallopian tube contract on being emptied and subsequently placed in spirit can see how much this tube must have been originally distended. Nothing but a microscopic investigation of the walls of the ovum cavity can decide in this particular instance that the placental growth was the cause of the rupture, but it has been so in every instance where I have made the research. In a case in which I made a *post-mortem* examination in 1874, and succeeded in perfectly injecting the uterus, ovaries, and tubes, the enlarged maternal vessels at the edge of the placental site were clearly the reason of rupture and the source of the fatal hæmorrhage. The difference in the uterus and the Fallopian tube in the matter of a contained fertilised ovum is that the uterus has the power of indefinitely increasing the thickness of its walls, whereas the tube has no such power, or has it to a very limited extent. The site of the placenta, as a seat of active nutrition, wherever it may be, becomes extremely vascular as is proved by preparations now exhibited. If the tissue in which this change is effected is also infiltrated by soft villi, is naturally of a kind easily torn, and if it does not increase proportionately in strength, it must offer a feeble resistance to the pressure of the rapid growth of the ovum.

Preparation 4691*a* is of remarkable value as illustrating this point. It consists of the entire ovum which escaped from the ruptured tubal pregnancy just described (Preparation 4691), found

on *post-mortem* examination; for, as usual, the patient died with six pounds of clot and five pints of bloody fluid in the abdomen. The fœtus is about one and a half inches long, and is stated in the history to be in the second month. I should say about the sixth week. The villi are concentrated on one small spot, and though not so agglutinated by decidual growth as to form a separable cake, they are practically a placenta, and are sufficiently formidable to account readily for the fatal rupture.

Preparation 4692 shows "a large dilatation of the right Fallopian tube containing a fœtus of about the third month connected by a well-formed umbilical cord to a placenta lining the walls of the dilatation." I am here using the words of the Catalogue as an answer to Dr. Griffiths' remarkable criticism. "The left tube is also dilated to more than half an inch in diameter, and its fimbriæ are effaced, ovary and tube being united," as is characteristic of hydrosalpinx. This is a condition remarkably suggestive of my initial theory that tubal pregnancy is probably the result of desquamative salpingitis, for in this preparation we have one side of the patient absolutely sterilised by old inflammatory trouble, and it needs no great stretch of imagination to believe that the side which became the seat of the tubal pregnancy was damaged too much to carry on its functions fully, and that therefore the displacement occurred as suggested in my first paper.

Examination of this specimen shows clearly that the rupture took place in the second and more limited zone of the tube which is related to the cavity of the broad ligament, and that the ovum did not die at the time of rupture, but went on developing as a broad ligament pregnancy. The clinical history of this case as given in the Catalogue of the Pathological Series is of the greatest possible value in elucidating its pathology, but a discussion of this is, unfortunately, debarred by the rigid customs of this Society.

Preparation 4697 gives another example of the broad ligament pregnancy in which it is clear that the pregnancy was originally tubal and was one of the minority not causing death at time of rupture by reason of the rupture being directed into the cavity of the broad ligament; and being further one of a minority of the minority in that the ovum did not die either at the time of rupture, but went on developing towards the full time. Here the cyst is eight inches long and contains a fœtus of the eighth month. The Catalogue tells us that the right Fallopian is lost on its

surface, precisely as it was in the cases which I diagramatised in my first paper.

There are many other preparations in the College museum and elsewhere, illustrating and confirming these points, notably one at the College contributed to it by Dr. Heywood Smith, who originally exhibited it at a meeting of the British Gynæcological Society. It was removed from the living abdomen as a pedunculated tumour, and the conditions were such that it seemed to me that at last a case had been found that unhinged completely my theory of extra-uterine pregnancy. Fortunately for me, I proposed that the preparation be submitted to a Committee for report, and after careful examination they recorded a unanimous opinion as follows:—"The specimen consists of a fœtus and placenta corresponding to the fifth month of gestation. Also the Fallopian tubes with the ovaries. The sac containing the fœtus and placenta is made up of involuntary muscle-fibre and resembles in structure the Fallopian tube, portions of which from the same case were cut and prepared for the microscope and compared with the sac-wall. Sections were also taken from an undoubted case of tubal pregnancy which had advanced to the fourth month of gestation. The sections from the two cases were identical. The outer wall of the sac presents pieces of omentum, showing that fairly strong adhesions had arisen between the dilated tubes and the omentum. It is also important to note that the Fallopian tube corresponding to the sac, &c., was scarcely represented except by fimbriæ. The corresponding ovary contains a large corpus luteum. Lastly, there is no evidence of rupture of the tube; and there can be no doubt that the specimen is one of tubal gestation.

"(Signed) LAWSON TAIT, President.
GEO. GRANVILLE BANTOCK.
HEYWOOD SMITH.
JOHN W. TAYLOR.
J. BLAND SUTTON."

What then is wanted now for the modification or destruction of my theory is a preparation of extra-uterine pregnancy which is inconsistent with a tubal origin, or a case of tubal pregnancy which has not ruptured either into the peritoneum or into the broad ligament at or before the twelfth week of ovum life.

By the kindness of Dr. Berry Hart I am enabled to exhibit actual drawings of a find as fortunate as it is almost unexampled

in pathological research. Equally unparalleled is also the stroke of good fortune which sent it into the hands of so diligent a worker and so minute and accurate an observer as all who know Dr. Berry Hart must recognise him to be.

It was nothing less than a cadaver the subject of extra-uterine pregnancy, which he subjected to the process of freezing and longitudinal slicing. It was a case of tubal pregnancy ruptured into the broad ligament, and developed there until at least the eighth month, perhaps longer. Unfortunately nothing is known of the history, but the fortunate sections cut by Dr. Berry Hart absolutely prove beyond all criticism what I had convinced myself of by the facts observed by me in operating upon these cases, that they are originally tubal, that they develop in the broad ligament, pushing its layers and those of the peritoneum upwards and backwards and towards the centre. I shall not anticipate in any way, I certainly could not do so to a full and exhaustive extent, the paper which will embody Dr. Berry Hart's observations on this remarkable specimen. But one point I wish to speak of because it was a point on which I was puzzled and on which I had sought in vain for an explanation.

In operating on these cases sometimes I opened the peritoneum and sometimes I did not. The reason is made plain by Dr. Berry Hart's sections, where the uterus is central. The growth of the pregnancy has stripped off the tubal and peritoneal layers and carried them upwards, but a moment's consideration will make us conclude that the peritoneum could be stripped off the posterior wall of the uterus only,—it could not be shifted from the anterior wall of the uterus and bladder, though these were pulled well up. But immediately on each side of the uterus the peritoneum has been shifted off the transversalis fascia as far up as the umbilicus, leaving a long conical tube of the peritoneal cavity reaching down over the median line of the fœtal mass down as far as, and corresponding in diameter to the uterus. In my operation cases sometimes the uterus was central, but in the majority it was not. The moment, therefore, I saw Dr. Berry Hart's drawings I knew why it was that sometimes I had opened the peritoneum and sometimes I had not. When this peritoneal tube was central I opened it; when it was not I missed it. So that these operations are sometimes to be ranked as abdominal sections and sometimes not.

I submit also sections of the tube in early tubal pregnancy

showing the immersion of the fœtal villi into the tissue of the Fallopian tube, and the consequent enlargement of the tubal vessels. In connection with this latter point I would also point out the enormous increase of size of the vessels of the abdominal wall in Dr. Berry Hart's drawings, vessels which would be ordinarily invisible in such a section, and it is clear from the appearance of the fœtus that the function of these vessels had been suspended for some time, probably for some months, by the death of the fœtus. *May 3rd*, 1887.

---

35. *A pair of chronic inflamed uterine appendages, illustrating the development of tubo-ovarian cysts.*

By Alban Doran.

This pair of uterine appendages explains how a tubo-ovarian cyst may be formed as a result of chronic disease of the Fallopian tube and ovary. They were removed in February, 1887, by Dr. Bantock, from a woman, aged 23, who had been subject for several years to constant pain in the pelvic region, and other severe local symptoms.

The right appendages form a single cystic body with very thin walls (Woodcut 9, R.). The outer part of the tube can only be distinguished from the ovary by the presence of a slight fold, which was strongly marked when the specimen was fresh. The uterine end of the tube remains quite distinct. I assisted at the operation, and noted that this cyst formed the whole of the appendages on the right side of the uterus.

The opposite appendages (Woodcut 9, L) show an early form of the same condition. The tube is held firmly to the ovary by adhesions. It is obstructed and its fimbriæ have disappeared, the extremity being already dilated. The ovary has undergone cystic dilatation at the part furthest from the tube. It is highly probable that if the appendages had not been removed, the cyst would have involved the entire ovary, and its cavity would possibly have coalesced with the interior of the dilated tube.

No. 4475,[1] which I exhibit this evening, displays a yet earlier stage. The tube is dilated, but there is no cyst in the ovary. On the other hand, in No. 4478, the process of conversion of a diseased tube and ovary into a tubo-ovarian cyst has advanced a stage further than in the left appendages of the pair which are the subject of this memoir. In the uppermost appendages in 4478 the dilated tube and ovary are becoming fused. In the lower

WOODCUT 9.

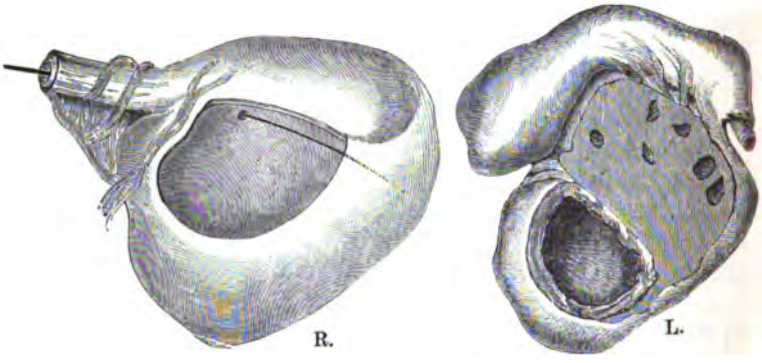

R. Right ovary and Fallopian tube converted into a single cyst. The outline of the external part of the tube is faintly indicated. A portion of the cyst wall has been excised to show that the bristle passed through the tube enters the common cavity of the cyst. Flocculent bands cover a portion of the cyst and tube.

L. Left ovary and Fallopian tube. The tube is obstructed, dilated, and bound to the ovary by flocculent adhesions. The cut surface of the ovary exposes a cyst cavity which lies at some distance from the line of adhesion to the tube.

appendages, using the term "lower" in reference to the manner in which they are mounted, the fusion is less advanced.

I will now turn to some specimens where the tubo-ovarian cyst is yet more developed than on the right side, in the case of the first pair exhibited this evening. In 4574 both Fallopian tubes are greatly dilated, especially the right, which has become fused to a cyst of the corresponding ovary, or rather to the ovary converted into a single cyst. The cavities of the tube and cyst communicate by a large opening, though not so freely as in my own specimen. The

[1] These numbers refer to specimens in the Museum of the Royal College of Surgeons, Pathological Series.

flocculent adhesions on the surface of the uterus, and other appearances, all indicate that chronic pelvic peritonitis, in the more local form commonly called "perimetritis," and "disease of the uterine appendages," had existed for long before death. The cyst of the right ovary has none of the characters of the common ovarian cystic tumour; it is evidently a simple cystic degeneration of a chronic inflamed ovary.

No. 4573 is almost a *fac simile*,[1] on a large scale, of the right appendages in my own specimen. Unfortunately there is no history attached to it.

Here I must note that in every specimen above described excepting the last, there was a history of inflammatory disease of the appendages, in the common acceptation of the term, and even in No. 4573 there is little reason to doubt that the condition was brought about by the same affection, and not by the development of a non-inflammatory disease, the common ovarian cyst.

In 4574 *a* we see a large cyst with an obstructed and slightly dilated tube adherent to its upper surface, but not in communication with the cyst cavity. A portion of the ovary is seen below, and it communicates with the cavity of the cyst. The opposite ovary formed a large multilocular cystic tumour. I believe that the cyst, in this specimen, either originated in the hilum of the ovary or in the broad ligament.

I show this specimen because it is the only example in my own experience where in true cystic disease of the ovary or broad ligament there has been any approach to the formation of a tubo-ovarian cyst; and I have had the opportunity of examining a very large series of ovarian cysts. On the other hand, after careful inspection of half a dozen pairs of appendages affected with chronic inflammation, I find, in several cases, more than a distinct approach to the development of a tubo-ovarian cyst. Hence my experience leads me to believe that tubo-ovarian cysts are a result, essentially, of inflammatory changes in the tube and ovary, leading to cystic dilatation of both and fusion of the cystic cavities. When a tubo-ovarian cyst forms in the course of ovarian cystoma, I suspect that it is developed by pure coincidence, the tube happening to become inflamed, obstructed and dilated, and ultimately fusing into one cavity with the ovarian cyst. This condition must be rare,

[1] Though described in the catalogue as "a Fallopian tube, dried," I have not the slightest doubt that it includes the ovary as well, as in my specimen.

for in ovariotomy the tube is generally found to be healthy, with its fimbriæ remarkably distinct and its ostium patulous.

Foreign writers lay great stress on the changes which the fimbriæ undergo after obstruction. I believe that they simply become matted together, forming at first a kind of bud, as in this specimen (No. 4567), but becoming rapidly effaced altogether. All trace of them is certainly lost at a very early stage of dropsy of the tube, whilst they remain conspicuous after years of stretching, or of other non-inflammatory but morbid conditions. When these delicate structures become infiltrated with inflammatory products and covered with exudation, their nutrition must soon be interfered with, and they atrophy as they coalesce. The distension of the obstructed tube will aid in completing their atrophy.

The tubo-ovarian cyst itself is evidently formed by the same process of degeneration due to inflammatory changes in the tube, ovary, and pelvic peritoneum. The tube and ovary becoming matted together by adhesions, their vascular supply must soon be obstructed. At the same time, degenerative changes progress within the parenchyma of the ovary, which becomes cystic. The precise nature of this cystic change is not very clear; it appears to me to be simple dilatation of more or less ripe follicles. It is certainly different from the cystic changes which produce the common ovarian tumour, where evidence of inflammatory changes in the tube and broad ligament is almost invariably absent.[1] At length, in intractable cases, the cyst in the ovary becomes approximated to the dilated tube, and the septum between them yielding, as such septa do yield in all kinds of cystic formations, a tubo-ovarian cyst is formed.

The patient from whom these appendages were removed had menstruated regularly until the date of the operation, although both tubes must have been obstructed for a prolonged period. The appendages were strongly adherent to surrounding structures, especially to the omentum. *April 5th*, 1887.

[1] Even when these structures appear morbid, in the course of an ovariotomy, the appearance is generally due to œdema, of the kind still more frequent and more marked when myoma of the uterus exists. Directly the parts are cut away, the serum drains from the broad ligament, and that fold as well as the tube assumes a normal appearance. This never occurs when inflamed appendages are removed.

36. *Two cases of hydrosalpinx.* (*Card specimen.*)

By G. N. Pitt, M.D.

1. From a woman, aged 39, who had had an eight months' still-born child nine years previously, and no children since.

There are numerous loose fibrous adhesions round the uterus, especially on the posterior aspect. The Fallopian tubes are dilated and their ends occluded.

The right tube is normal for the first three quarters of an inch, the remainder being dilated into a semi-transparent thin-walled cyst three inches long, and half to one inch diameter, the end being folded on itself.

The left tube is less dilated, but forms an elongated cyst two and a half inches long by one third to three quarters of an inch diameter. Neither cyst is tense.

2. From a woman, aged 28, who had never borne any children. The ends of the Fallopian tubes are occluded by inflammatory adhesions. The left is dilated into an elongated cyst in its peripheral part, which is one and a half inches diameter by two inches.

The left tube is also dilated at its periphery, and its proximal part is much thickened, so that the lumen is occluded and the thickness of the tube is a quarter of an inch.

February 15th, 1887.

---

37. *Fibro-myoma of the ovarian ligament.*

By Alban Doran.

This specimen consists of the left ovary, the left ovarian ligament, and the adjacent part of the left side of the uterus. In the midst of the substance of the ovarian ligament is a small spherical tumour, about half an inch in diameter. The parts were removed, in February, 1887, from a young patient, by Mr. Knowsley Thornton. The patient suffered pain from a small fibro-myoma of the uterus. The removal of the appendages alone was intended, but, as frequently occurs under the circumstances, it was found necessary to amputate the uterus above the vagina. From the surface

of the right ovary bulged a small lobe, what has been termed a "supernumerary ovary."

The spherical tumour in the ovarian ligament is composed of plain muscular fibres, mingled with white fibrous tissue, as may be seen from inspection of a section which Mr. Eve kindly prepared for me at the Royal College of Surgeons. It is, in fact, simply a uterine "fibroid" situated in that part of the uterus known as the ovarian ligament. In this case, the body of the uterus was converted into a "fibroid" mass of the familiar type. The universally enlarged walls contained numerous circumscribed spherical nodules like this specimen.

The ovarian ligament is a band of uterine tissue running from the uterus to the parenchyma[1] of the ovary, and not to the tissue of the hilum.[2] Over this band the peritoneum forms a fold. Systematic anatomists often speak as though the fold were the essential part of the ligament.

Being uterine tissue, it is not surprising that the ovarian ligament should enlarge when fibro-myoma develops in that portion of the uterus adjacent to it. In cystic ovarian disease the ligament simply becomes stretched; its peritoneal fold, however, increases in proportion. On the other hand, I find that the ligament enlarges distinctly in cases of fibroma of the ovary, especially in that form where the ovarian tumour contains numerous plain muscular fibres, so as to be a true fibro-myoma.

Thus the ovarian ligament is a band of muscular fibres, coming from an organ where muscular fibres greatly predominate over other tissues, and proceeding to an organ which contains several other tissues of importance in almost even proportions. Hence, as I have already noted, that ligament is subject to the kind of tumour which specially and frequently affects the uterus, the organ whence it is derived; whilst it takes no active pathological part in the development of new growths in the ovary, the organ to which it proceeds, excepting when the new growth happens to consist of that tissue which forms the ovarian ligament itself and the greater part of the organ whence it originates.

[1] "The oophoron" of J. Bland Sutton; see 'An Introduction to General Pathology.' Its relation to ovarian pathology is explained in my memoir on "Papillary Cysts of the Ovary" in the Society's 'Transactions,' vol. xxxiii, p. 207.

[2] The "paroophoron" of Sutton. Its relation to ovarian pathology is explained in the paper noted in the preceding footnote.

The morbid anatomy, clinical history, and microscopical appearances of this specimen conclusively prove its nature. At the same time it must strike the observer how very much the bands of plain muscular fibre in the microscopic specimen resemble the tissue of a spindle-celled sarcoma. Had there been, by coincidence, a tumour of this kind in the ovary, as well as the uterine fibro-myoma, there can be no doubt that the nature of the ovarian ligament tumour might have been disputed by some of the most experienced members of the Society.

The tumour is clearly no "supernumerary ovary," but during the operation, which I witnessed, I thought when it first came in sight that it might be a true example of that abnormality which, strange to say, was discovered a few minutes later on the opposite side. My experience in this case leads me to believe that others may have mistaken a fibro-myoma of the ovarian ligament for a supernumerary ovary. *March* 15*th*, 1887.

---

38. *Uterus extirpated on account of large fibroid in pelvis interfering with the functions of the rectum and bladder.* (*Card specimen.*)

By Sydney Jones.

This specimen consisted of the whole uterus removed just above the os together with the appendages, from H. P—, aged 36, single, who was admitted into St. Thomas's Hospital under the care of Mr. Sydney Jones on March 1st, 1887. She began to menstruate at twelve, and has been regular up to the present time; losing somewhat in excess during the last nine months, and the period being accompanied by pain. Seven years ago she first had pain on the right side of the abdomen on moving about, and then found a lump about the size of a hen's egg between the pubes and umbilicus on the right side. She often had nausea and vomiting, and there was always very great difficulty with the bowels. Three years after the first appearance of the tumour she lost more or less the use of the right leg, but recovered this in four or five months.

Three years ago began to have frequency of micturition giving place to dysuria, which has continued till the time of her admission.

On examination of the anterior wall of the abdomen in the right iliac and hypogastric regions, a hard rounded swelling, clearly defined, could be felt, extending laterally from the crest of the ilium to within an inch or so of the median line of the abdomen, dipping down into the pelvis below and reaching as high as the umbilicus.

In the vagina the tumour could be felt close to the external orifice, and pressed together the anterior and posterior walls, so as to impede the introduction of the finger In the rectum the tumour could be felt as a large hard rounded ball, and evidently interfered by pressure with the function of the rectum. There had been no very excessive menorrhagia, but there had been much pain, and there was serious interference with the action of the bowels and with micturition.

After consultation with Dr. Gervis, it was decided to attempt removal of the entire uterus above the os. On April 19th, the patient being under ether, and antiseptic precautions being used, an incision was made from above the umbilicus to two inches above the pubes. The bladder was found drawn up several inches; although supposed to have been emptied by the catheter before the operation, it was found to contain several ounces of urine which were drawn off with some difficulty.

Connected with the upper part of the tumour, that part which had been felt through the anterior abdominal wall, there were numerous omental adhesions; these were divided after the use of double ligatures. Then, by insinuating the hand into the pelvis behind the tumour, the latter was very easily turned out. It was an irregular dumb-belled mass and included both ovaries with the uterus. The pedicle was formed by an elongated cervix. Koeberle's serre-nœud was used, and division of the cervix above was made by scissors. Perchloride of iron was dabbed over the stump; above and below the stump a harelip pin was used; and intermediate sutures of silk and catgut brought the edges of the wound together, and dry dressings of iodoform gauze and salicylic wool were applied. There was no shock. She was slightly sick during the operation, but not once afterwards. All sutures were removed after nine days. On May 2nd, fourteen days after the operation, the écraseur wire and pins were removed. There was very little disturbance throughout the whole progress of the case; the temperature on one or two occasions reaching to 101° or 102°, but for

the most part normal. She went out quite well, about one month after the operation. The specimen showed a large globular tumour in the body of the uterus, which had been lodged in the pelvis; from the right cornu an outgrowth extended into the right side of the abdomen. The whole weighed about 3½ lbs.

May 17*th*, 1887.

---

39. *Large uterine fibroid and the uterus with a smaller submucous fibroid.* (*Card specimen.*)

By Peter Horrocks, M.D.

The uterus was lifted up out of the pelvis, so that the fundus reached nearly to the left hypochondrium. The cervix was elongated over the front and left side of the fibroid. It was removed by abdominal section, and had to be shelled out of the broad ligament. The main tumour was intimately united with the back of the lower part of the fundus and the upper part of the cervix uteri. *May* 17*th*, 1887.

---

40. *Ulcer of vagina.* (*Card specimen.*)

By G. N. Pitt, M.D.

There is a single irregular ulcer ⅛th inch across, with loss of the mucous membrane, $\frac{1}{40}$th inch deep, situated ¾ inch from the os uteri on the anterior wall of the vagina. The floor is irregular, the margin at one spot is undermined. When fresh the margins were extremely congested and swollen, but there was no infiltration and no signs of adjacent tubercles. The ulcer was fairly recent and not healing.

Ulcers in the upper part of the vagina, excluding malignant and traumatic, are very uncommon. None are recorded in the 'Transactions' of this Society.

The patient in whom this ulcer was found had been in the hospital in bed for four months previous to her death, suffering from phthisis. *Post mortem*, numerous tubercular ulcers were found in the intestine and larynx. *February* 15*th*, 1887.

VI. DISEASES, ETC., OF THE OSSEOUS SYSTEM.

1. *A neglected point in the pathology of Colles' fracture.*

By D'Arcy Power, M.B.

The point to which I am desirous of calling your attention this evening, Mr. President, is one that may appear to be well known to those members of the Society who have made a special study of the pathology of Colles' fracture. It is not yet sufficiently known, however, if I may judge by the answers which I have received from a large number of pathologists to whom I have at various times shown these specimens. They have for the most part replied that the preparations were not such as agreed with the ideas which they had formed as to the pathological appearances presented by this variety of fracture. I am aware that cases occur in groups, and that even special and rare forms of injury may present themselves repeatedly to any individual observer, but I do not believe that unless this kind of fracture were much more common than it is usually supposed to be, so many examples of it could have come under my notice in such a comparatively short space of time.

The point, then, which I wish to bring under your notice is that in a large number of Colles' fractures the lower fragment of the radius is split by one or more fissures which extend into the joint. The fracture, therefore, is very frequently not simple, with or without impaction, as is usually supposed to be the case, but is in reality a comminuted fracture involving the carpal articulation. I further hold that such comminuted fractures cannot be distinguished from the simple fractures without the most careful examination, and that sometimes it is impossible to distinguish the two varieties without actual dissection since the deformity may be identical. From an examination of the specimens preserved in the various museums attached to the metropolitan hospitals I have

ascertained that, from a pathological standpoint, the comminuted fracture is slightly more common than the simple form. Fifty-nine[1] specimens are preserved in London, and of these thirty-one have the lower fragment comminuted, the fracture implicating the carpal articulation. In several of these cases the fractures occurred many years before death, but good smooth union has resulted, and a useful joint has in nearly all cases been obtained.

My attention was first called to this subject when I was acting as house surgeon at St. Bartholomew's Hospital. A man aged 39, whilst cleaning a window after breakfast, fell a distance of about eight feet, first on to some spiked area-railings and then on to the pavement. He walked from a cab into the surgery, a distance of about twenty yards, without assistance, and as my dresser happened to be away I examined him myself, diagnosed an ordinary Colles' fracture, and proceeded to place his arm in splints in the ordinary manner before I admitted him into a ward, on account of other and more serious injuries which he had received. The patient subsequently died, and I had an opportunity of dissecting the lower end of his radius, which I here exhibit to the Society. The further details will be found in the list of cases which I have placed as an appendix to this paper.[2]

The occurrence which I have just narrated happened at the end of my yearly tenure of office, and therefore at a time when I might be supposed to be familiar with the appearances presented by Colles' fracture, for I apprehend that few practitioners are so thoroughly conversant with the diagnosis and treatment of the various forms of fracture as the house surgeons at a large general hospital, and of fractures coming under their notice Colles' is, perhaps, the most common. In this instance, however, I have no hesitation in saying that there was absolutely nothing which suggested to my mind that in this particular case the injury differed in any respect from other cases of simple Colles' fracture which I had been accustomed to treat with tolerably good results. Yet here is a bone in which the lower fragment has undergone very complete crushing, and in which, if at all, one would have expected to make out the comminution. It presented, however, the typical deformity of a Colles' fracture, and the ordinary amount of difficulty was experienced in getting the parts into good position.

[1] Appendix II.

[2] Appendix I, Case 1.

After meeting with this case I took care to make as accurate an examination as was possible of all the examples of Colles' fracture which occurred in the hospital, and owing to the kindness of Mr. Bowlby, our surgical registrar, I have been able to examine several recent cases both before and after the removal of the bones from the body. Such opportunities are rare, but during the years 1884 and 1885 we appear to have had an unusual proportion of cases in which patients died who had sustained this injury. During the last eighteen months, however, no similar instance has presented itself. In each case before an incision was made into the arm the fracture presented the usual deformity, and there was nothing to indicate that the lower fragment was splintered; and yet in each when the parts were dissected the fracture was found to extend into the joint. In other patients who survived, and in whom I have no doubt that a similar injury has occurred, recovery took place almost as well as when the radius had merely undergone a simple fracture. As instances of this may be quoted the cases related in Appendix I, Nos. 4 and 6, and the specimens which may be found here and there in the various pathological museums, in which even after severe comminution a good and useful joint has resulted. Although in the greater number of cases it appears impossible to distinguish between the simple and the comminuted fractures of the lower end of the radius, yet in some there is no doubt that crepitus can be obtained between the separated fragments. Since, as I have already stated, nearly all the cases appear to recover with fairly useful wrists, the prognosis of such a fracture is not necessarily more unfavorable than in the simple form. In enumerating the causes of stiff wrist after Colles' fracture, however, such implication of the joint should be placed high upon the list, but it is a cause which cannot be guarded against, and which certainly cannot be treated.

So far then as my observations have proceeded they agree with the statement made by Mr. Clement Lucas that "pathological specimens show a very large proportion of comminuted fractures,"[1] but they hardly bear out the further remark that only "the worst cases, such as are caused by falls from a great height, as a rule yield to *post-mortem* observations." There are, as I have already shown, several specimens in London in which comminuted fractures of the lower end of the radius occurring long before death have

[1] 'Guy's Hospital Reports,' vol. xlii, p. 388.

been repaired, and many more cases might easily be collected in which comminuted fractures have not been followed by any fatal results. I think then that it is fair to assume that comminuted fractures involving the carpal joint are much more common than is usually supposed, and that their diagnosis during life is extremely difficult.

In looking through some of the extensive literature on the subject of Colles' fracture I find that Mr. Callender[1] and more lately Mr. Hutchinson and Professor Bennett,[2] have recognised the comparative frequency of comminution of the lower fragment; but I do not find that any observer, with the exception of Mr. Hutchinson, has pointed out the close similarity which this variety bears to the simple form of Colles' fracture. Mr. Callender indeed laid it down as a general rule that "the less the deformity and the less the impaction the worse the prognosis, because of the splintering of the lower fragment," though this appears only to hold good for those rarer cases in which the comminution can be felt during life.

I have annexed two appendices, one giving short abstracts of some of the cases upon which I have based my observations this evening, and the other containing in a tabular form the various specimens of Colles' fracture which are preserved in the pathological collections attached to the hospitals in London.

Appendix No. I.

The following are short accounts of the cases upon which I have founded my conclusions in reference to Colles' fracture.

1.—A man aged 39 fell from a distance of about eight feet on to some spikes and thence to the pavement, and was admitted with slight bleeding from the right ear, a Colles' fracture of the right arm, and a punctured wound over the crest of the ilium. He was pale but not unconscious; he vomited once and died seven hours later without rallying from his state of collapse.

[1] 'St. Bartholomew's Hospital Reports,' vol. i, p. 293.

[2] Remarks on Colles' fracture read in the Section of Surgery at the annual meeting of the British Medical Association in 1879: quoted in Dr. McDonell's edition of Colles' works published by the New Sydenham Society, 1881, pp. 420–424.

At the autopsy there was an extensive rent dividing the right end of the right lobe of the liver; extensive fracture of the ilium, and a complicated fracture of the vault of the skull, the fracture extending through the middle fossa.

The right arm presented to all appearance a typical Colles' fracture an inch above the lower end of the radius. On removing the lower half of the radius, however, the upper end was found to be slightly impacted into the lower fragment, which was greatly comminuted. The fracture extended horizontally across the centre of the carpal articular surface, the dorsal anterior half being again divided transversely near its ulnar margin. The ulnar facet was also divided but not in its whole extent. The main line of fracture was irregular and several pieces of bone were completely detached.

The specimen is preserved in the museum of St. Bartholomew's Hospital, Series iii, No. 925 (*a*).

2.—A man aged 43 fell from a first-floor window, and was brought into the hospital in an unconscious state. He had a comminuted fracture of the left malar bone and a Colles' fracture of the left arm. He never recovered complete consciousness and died on the sixth day.

At the *post-mortem* examination it was found that he had sustained a fracture of the anterior fossa of the skull without much splintering. The left forearm was the seat of a Colles' fracture, in which the upper fragment was well impacted into the lower. As a result of the impaction the lower fragment was cleanly divided by a horizontal and two longitudinal fractures into four pieces which were only held together by ligament. The articular surface, which corresponded with the semilunar bone, had disappeared; but there were only slight signs of inflammation in the wrist-joint. The styloid process of the ulna was torn off. This specimen is an extremely interesting one as it can be compared with a specimen preserved in the museum of St. George's Hospital, No. 3423 (*b*), in which after an almost exactly similar injury the patient lived for eleven weeks. In the latter specimen good bony union has taken place, and there is little or no evidence of joint disease, though in some parts the bone has undergone rarefaction.

The specimen is preserved in the museum of St. Bartholomew's Hospital, Series iii, No. 925 (*b*).

3.—A man aged 56 fell from a second floor window upon some iron spikes and from thence to the pavement. On admission he was found to have a fracture of the sternum, and what appeared to be a fracture of the radius and ulna immediately above the thigh. He died on the eighth day after the accident, his death being accelerated by long-standing disease of the heart.

At the *post-mortem* examination his heart weighed 17 oz., the aorta was atheromatous, and the liver was fatty and had on it a small subperitoneal extravasation. The ulna was intact, but the radius was fractured three quarters of an inch above the thigh. The lower fragment was divided into four pieces, which were slightly displaced, but could not be reduced until after division of the long and short carpal extensor, of the extensors of the thumb, and of the supinator longus.

The specimen is now in the New Museums, Cambridge.

In my opinion the preparation may not only be compared with the preceding cases, but also with the next specimen, in which I believe that had the patient died a very similar condition of affairs would have been found; he did not do so, however, and finally obtained a very fairly movable joint.

4.—A man fell from a warehouse platform three stories high. On admission he had a comminuted fracture of the left tibia and fibula. He also had a fracture of the left radius about an inch above its lower end. On admission there was a depression over the fragments, which were freely movable. The ulna was dislocated from the carpus for about a quarter of an inch. The forearm was in a condition of pronation. It was treated by a pistol splint, and was subsequently encased in plaster of Paris. Two months after the injury the wrist was a little swollen and red, and the fingers were rather stiff. Supposing the previous patient had lived I have little doubt that at the end of the same time a similar note would have been made of his condition.

5.—In another case, a man aged 34 fell a distance of thirty feet, and sustained a fracture of the lower extremity of the left radius, which was at first mistaken for a dislocated carpus. At the same time a small hæmorrhage appeared to have occurred into the spinal cord, for he subsequently had anæsthesia of the lower limbs with paralysis of the bladder. He eventually recovered, and

ten weeks after the injury the note states that his wrist was swollen, but that he had fair movement in his fingers.

The following is another example of what would, I am sure, have been found to be a comminuted fracture of the lower fragment if the radius could have been examined.

6.—A woman aged 70 fell down a flight of thirty stone steps, sustaining a slight concussion of the brain. She fractured the fifth left metacarpal bone, and was admitted with an injury which was supposed to be an ordinary Colles' fracture of the right arm. The fracture of the radius extended obliquely upwards and outwards, and there was comparatively little displacement. A month later, when the splint was removed from the right arm, it was found that although passive movement had been practised from an early period, the fingers could not be moved without much pain.

Appendix No. 2.

In investigating this feature of Colles' fracture I have taken the trouble to look at the specimens preserved in the various pathological museums in London.

In the Hunterian collection there are five specimens of Colles' fracture, of which the lower fragment is comminuted in three cases; in one the fracture is simple, and in one the union is too complete to decide whether it was or was not comminuted.

In the museum of St. Bartholomew's Hospital we have fourteen preparations illustrative of this form of fracture, and one example of an incomplete separation of the lower epiphysis. Five of these are simple, but in the remaining nine the fracture extends into the joint.

At Guy's Hospital there are seven examples of which, curiously enough, only two present the splintering of the lower extremity of the radius, and these two were obtained from the same patient. On the other hand, in St. Thomas's Hospital, there are only two fractures of this nature, and in both the lower fragment has undergone comminution. In St. George's Hospital, as at St. Thomas's, there are but two preparations, of which one is simple and the other is the comminuted fracture to which allusion has already been made. In the museum of King's College Hospital, on the other hand, there are six examples, of which two are simple and

four are comminuted. The London Hospital possesses three cases of simple fracture and five cases of comminuted fracture; whilst University College has no examples of comminuted fracture, but it has five of simple fracture which are in all cases of long standing. At St. Mary's Hospital there are three examples of simple fracture and three of comminuted. Two of these cases are of extreme interest, for they, too, occurred long antecedent to death, and the union which has resulted is quite as good as in simple fractures. The museum of the Middlesex Hospital contains three examples of Colles' fracture, all of which are comminuted, but as two of them are the result of direct violence due to the passage of a wheel over the arm, only one should be reckoned. Charing Cross and Westminster each contains a single example of a comminuted Colles' fracture.

The Hunterian Museum.

No.	Nature of Injury.	Remarks.
954	...	Fracture of long standing.
955	Comminuted	Fracture extends into joint. A portion of the dorsal surface near the ulnar facet has been broken off. There is good and smooth union.
955 (*a*)	Comminuted	Fracture extends into joint: the resulting union is good.
956	Simple	...

The Museum of St. Bartholomew's Hospital.

923	Simple	...
927	Simple	...
928	Simple	...
929	Simple	...
930	Simple	...
930 (*a*)	...	Colles' of long standing.
924	Comminuted	Much crushing of lower fragment, scaphoid broken across.
925	Comminuted	Appeared to be a simple Colles' during life.
925 (*a*)	Comminuted	Much crushing of the lower fragment.
925 (*b*)	Comminuted	Very similar to the specimens preserved in Guy's Hospital, No. 1118[20]; and in St. George's Hospital, No. 3423*b*; details in Appendix I, Case 2.
925 (*c*)	Comminuted	...
925 (*d*)	Comminuted	By direct violence, a heavy van passed over arm.
926	Comminuted	The lower fragment has been split, but has repaired itself in such a way that the fissure into the joint is a mere line.

The Museum of Guy's Hospital.

No.	Nature of Injury.	Remarks.
1117^{41}	Simple	Colles' fracture of long standing.
1117^{43}	Simple	...
1117^{44}	Simple	...
1117^{45}	Simple	...
1119^{10}	Comminuted	See 'Guy's Hospital Reports,' S. iii, vol. 7, p. 267.
1118^{20}	Comminuted	Typical splintering of both radii resulting from a fall from a height.

The Museum of St. Thomas's Hospital.

B_{16}	Comminuted	The fracture extends obliquely into the joint.
B_{17}	Comminuted	The lower fragment is much crushed.

The Museum of the London Hospital.

Gbi_2 (228)	Simple	...
Gbi_5	Simple	...
Gbi_{19}	Simple	...
Gbi_2 (227)	Comminuted	Fracture extends into the joint: the lower fragment is divided into two portions.
Gbi_6	Comminuted	Much comminution of lower fragment; ulna fractured.
Gbi_8	Comminuted	An oblique comminuted fracture of the radius; a longitudinal fracture passes into the joint. The patient fell from a window straight on to his feet, and afterwards fell forwards. The left wrist showed all the signs of a Colles' fracture, the hand being displaced backwards.
Gbi_9	Comminuted	The fracture extends into the joint. The accident was not diagnosed during life; the patient died of pyæmia after an injury to the head.
Gbi_{11}	Comminuted	After smashed hand.

The Museum of University College.

211	Simple	Old Colles' fracture.
212	Simple	Old Colles' fracture.
213	Simple (?)	Old Colles'; a small piece of the articular surface is separated, but I think accidentally, after death.
214	Simple	Old Colles'.
217	Simple	Old Colles'; the ulna is also fractured at same level as radius.

The Museum of King's College Hospital.

No.	Nature of Injury.	Remarks.
645	Simple	...
646	Simple	...
639	Comminuted	Bony union; cast of St. Mary's specimen.
640	Comminuted	Vertical fissures run downwards, but do not extend into the joint. There is bony union, with very slight deformity. Cast of St. Mary's specimen.
643	Comminuted	Fracture extends into the joint. The styloid process of the radius is broken off. The interarticular fibro-cartilage is ruptured.
647	Comminuted	Fracture extends into the joint, and although the patient lived six weeks there does not appear to be any evidence of joint disease. From a woman aged 63.

The Museum of St. George's Hospital.

3423 (*a*)	Simple	...
3423 (*b*)	Comminuted	Typical splintering of both radii, eleven weeks after a fall upon both hands from a height of twenty feet. There is good bony union, with little or no evidence of joint disease. The bone between the fractured portions is rarefied.

In the Museum of St. Mary's Hospital.

A *a* 54	Simple	...
A *a* 96	Simple	...
A *a* 163	Simple	...
A *a* 77	Comminuted	The fracture is doubtfully into the joint. There has been complete union. The preparation is a cast.
A *a* 78	Comminuted	The fracture extends into the joint. The injury occurred in a man aged 80, two years before his death. Good smooth union has taken place with only slight deformity.
136	Comminuted	The comminution of the lower fragment is very slight, and it hardly extends into the joint, a thin shell of bone intervening.
136	Comminuted	The fracture involves the joint. There has been good smooth union. From the same patient as the preceding, but of much older date. The clinical details are wanting.

In the Museum of the Middlesex Hospital.

No.	Nature of injury.	Remarks.
23 16	Comminuted	There is an extreme amount of comminution of both the radius and ulna.
234	Comminuted	Both bones have been comminuted by direct violence.
235	Comminuted	The fracture involves the joint to a small extent upon the posterior portion of the ulnar side of the radius.

In the Museum of Charing Cross Hospital.

351	Simple	...
353	Simple	...
352	Comminuted	The joint is greatly involved.

The Museum of the Westminster Hospital.

51	Comminuted	...

February 1*st*, 1887.

---

2. *Colles' fracture repaired with forward displacement of the lower fragment.* (*Card specimen.*)

By Samuel G. Shattock.

The unusual feature in regard to this specimen is the angular displacement *forwards* of the lower fragment, such as is stated to result from falls on the back of the hand. Firm osseous union has taken place. The specimen is one that has long been in the museum of St. Thomas's Hospital. *March* 3*rd*, 1887.

---

3. *Osteomyelitis of scapula; separation of its coracoid epiphysis; pyæmia.* (*Card specimen.*)

By JOHN POLAND.

GEORGE L—, aged 12 years, was admitted into Guy's Hospital on October 11th, 1886, under the care of Mr. Durham. Nine days previously he was said to have been thrown down by a dog, and to have fallen on his right shoulder; his right thumb was also bitten. Three days afterwards his illness commenced with vomiting, feverishness, and great pain in shoulder.

On admission he was delirious and his legs drawn up. Temperature 103·6°, pulse 124. Redness and puffiness over back of right hand. Two incisions were made into swelling over dorsum of scapula. Death, however, took place early next morning.

Post-mortem.—Body was well nourished and developed; both lungs contained numerous pyæmic abscesses, more so in the right lung than the left, and were especially marked over the lower lobes.

The pleuræ acutely inflamed and coated with purulent lymph. Pericardium was also acutely inflamed and held 2 oz. of blood-stained pus.

Heart 5 oz. Muscles soft and flabby. In the posterior wall of left ventricle there was an abscess half an inch in diameter which opened into the pericardium.

Brain soft; numerous minute purulent deposits in the cortex, a few in the white matter and in the corpora striata. Lining of ventricles presented numerous hæmorrhagic points; the ventricles themselves contained a little blood-stained fluid.

On opening the peritoneum a little blood-stained fluid was seen. Liver: Numerous small abscesses scattered through the organ, but more especially on the upper surface beneath the peritoneum.

Kidneys thickly studded with small deposits of pus, very numerous and running together in the cortex.

Spleen contained several small pyæmic abscesses; those towards the surface had their peritoneal covering coated with lymph.

Intestines: Several small follicular abscesses with some surrounding swelling and inflammation were found in the mucous membrane of the lower part of the ileum.

RIGHT SCAPULA was almost entirely denuded of its periosteum, the subscapular, supra- and infra-spinous fossæ being bare with the exception of the upper and lower angles, and full of bloody pus. The abscess cavity on the dorsal surface communicated freely with that in front by means of the shoulder-joint, and also over the neck of the bone. The joint was acutely inflamed and full of pus. The capsule partly destroyed and the cartilages commencing to be so. The scapula itself was of a greenish-yellow colour, and on section infiltrated with pus. The coracoid epiphysis was completely detached; a small flake only of the cartilaginous epiphysial line remained. The muscles were still attached to its apex; around this process were the remains of what had apparently been a cavity full of blood suggesting that this was the original seat of the disease, viz. that this process had been detached by the injury at its epiphysial line of cartilage, and that this injured tissue had formed a congenial soil for micro-organisms to flourish, acute osteomyelitis of the scapula in a similar manner to the shaft of a long bone taking place, and with it other signs of general infection. That the pyæmic process in this case had a predisposition for the epiphysial line of cartilage was shown by the commencing suppurative periostitis of the shaft of the fourth metacarpal bone and partial detachment of its head. But the line of cartilage was still intact, although its proximal surface in part formed one end of the abscess cavity. The case appeared to be analogous to pyæmic arthritis in infants, and might be appropriately termed *epiphysial pyæmia.* There was no pus in any of the other joints. Sections of the numerous foci of suppuration in the brain and liver, kidney, intestines, &c., were carefully stained by Mr. H. J. Campbell, and found to be crowded with micrococci. *May 17th*, 1887.

---

4. *A case of osteitis deformans associated with a sarcomatous tumour of cerebellum.*

By A. H. ROBINSON, M.D.

THE calvarium and clavicle I show to-night were removed from the body of a man the subject of osteitis deformans. Along with them I show the cerebellum from the same case, having con-

nected with it a large sarcomatous tumour, which had encroached upon and displaced the middle lobe of that organ. The man was under observation for a considerable time on account of the affection of his bones, but no symptoms occurred up to the day of his death in any way suggestive of cerebellar disease. As an example of osteitis deformans the case is of interest from its association with the presence of sarcoma, and also on account of the family history of the patient, it being, I believe, the first recorded instance in which a plurality of cases has occurred in the same family.

The patient was a clerk, fifty-two years of age at the time of his death. He had lived in tolerably comfortable circumstances until thrown out of employment by his illness. Had never been intemperate; indeed, for upwards of twenty years had been a total abstainer. Had never had syphilis or rheumatism. There was no history of cancer in his family. His occupation at the docks exposed him a good deal to climatic influences, and he was frequently "wet through." He was always well nourished; latterly he was stout. Was of fair complexion, and lost the bulk of his hair by thirty years of age.

Family history.—The man was one of twins, his twin brother being imbecile, and died in early life in an asylum. He married at twenty-six, and his wife bore him ten children. Two of these children died, between seven and eight years of age, of dropsy following scarlet fever. At the time of their death there was considerable enlargement of the skull in each case. The remaining children are grown up, but are not of vigorous intellect. Another interesting and more reliable point in the family history is that an elder brother of the patient died a few years ago at fifty-two years of age, who was a cripple for some years owing to the deformity of his lower limbs. The course of his illness resembled that of the subject of this paper, and by the friends the condition was looked upon as the same.

Clinical history.—Prior to 1876 patient enjoyed fairly good health, but some time during that year, when boarding a ship in the course of his employment, he felt a sudden pain in the lower part of his back. From this time onward he complained of weakness in the loins and back generally, which increased gradually to such a degree that he was unable to reach his office; indeed, he could hardly walk at all without the aid of sticks. His attention was then

drawn to his left shin, and the tibia was found thickened and bowed. The increase in size of head was first noticed in 1880, when difficulty was found in supplying him with hats large enough to fit him, and about the same time his wife noticed considerable increase in circumference of his hips, which was in great measure due to the bowing outwards of the femur. In the summer of 1882 he was an in-patient at the London Hospital, suffering from lumbago and pneumonia. Later in the same year he was readmitted under the care of Dr. Stephen Mackenzie with some similar symptoms, and the condition of his osseous system was noticed.

He came under my care some twelve months before his death. At first he was able to walk about with assistance, but latterly he was confined to bed owing to weakness and sheer inability to walk. He appeared to be a man of some intelligence, but was irritable and easily excited by any opposition to his wishes, and on inquiry this irritability was found to have been noticed during the whole course of his illness. The head was very manifestly enlarged generally, the circumference measuring twenty-four and a half inches. At the situation of the posterior fontanelle was a pulsating area, which pulsation was synchronous with the pulse. There was no apparent alteration in vision, patient spending a good deal of his time in drawing. There was no paralysis of ocular muscles, and no change in fundus oculi; in fact, no symptoms referable to nervous system. Respiratory system was normal. Heart's apex-beat was displaced downwards and outwards, and there was a soft systolic murmur audible over it. Urine was examined from time to time, and was usually pale and clear, faintly acid, did not contain albumen, and occasionally deposited phosphates. His appetite and digestion were good, and, besides weakness, he made no complaint of illness except headache of a dull character, which was frequently present.

Besides the calvarium and clavicle, other bones were markedly affected, and produced considerable deformity. The left tibia was thickened to almost double its normal thickness, and was much curved, with its convexity forwards. Over its lower third was some old discolouration of skin. The right tibia was affected in a less degree than the left, and both bones were somewhat roughened. The right femur was enormously thickened in its entire length, and the bowing outwards and forwards was very

exaggerated. The left femur was similarly thickened, but less bowed. Both humeri were thickened, the right the more so. The bones of the hands and feet were unaffected. There was marked kyphosis in the upper dorsal region, causing some degree of stooping.

In April, 1886, the patient died quite suddenly, sitting up in bed. An examination of his body was made fifty-three hours after death. There was much lividity of dependent parts; much fat, subcutaneous and omental.

The lungs were emphysematous. There was no fluid in pleura.

The heart was enlarged, weighing 14 oz., and its cavities were empty. Wall of left ventricle was an inch in thickness, and of firm consistence. The wall of right ventricle was attenuated, and the auriculo-ventricular orifice was dilated to an extent which admitted all the fingers and thumb with ease. The pulmonary and aortic valves were normal.

The liver was enlarged and fatty. Spleen weighed 10½ oz., of firm consistence.

Kidneys weighed 5¼oz. each, and to the naked eye appeared normal.

In removing the calvarium (in doing which the saw passed very readily through the bone), a good deal of clear fluid escaped from cranial cavity. The membranes were normal, with the exception of some fulness of veins. After removing brain a large tumour was found connected with the right hemisphere of the cerebellum on its under surface, encroaching upon the middle lobe, and pushing the medulla oblongata to the opposite side. This growth, which was the size of a Tangerine orange, was found on microscopical examination to be a round-celled sarcoma.

The section of the skull showed an amount of thickening of bone of an almost unilateral disposition, it being most marked in the occipital and right parietal regions. The changes characteristic of the condition could, however, be traced round the entire section. Save at its thickest portions there is no trace of diploë left, and in the prepared bone the substance to the naked eye closely resembles plaster of Paris. Over the greater portion of its outer surface the calvarium is riddled with minute foramina. The internal surface is deeply grooved by the meningeal vessels. At the vertex externally the outer table has been removed, and the osseous structure beneath is seen to be in a condition of rarefaction. Only

slightly in the temporal region is there any trace of suture remaining; everywhere else the obliteration is complete.

The clavicle shown is enlarged almost entirely at its inner and middle thirds, the acromial end being but little altered. The companion bone was normal.

Of the remaining bones the ribs only appeared affected, and were so soft as to be readily cut with the knife. The bodies of the vertebræ, the innominate bones, and the sternum, all appeared normal. *April 19th*, 1887.

---

5. *Case of disease of the humerus.*

By John R. Lunn.

J. T—, male, aged 86, was admitted into the St. Marylebone Infirmary September 10th, 1881, with bronchitis and old age. Patient stated that he had always enjoyed good health, and that his family had lived to a great age. No disease was noticed on admission,—he was merely suffering from the effects of old age. He was bedridden till his death January 20th, 1887. He used always to rest on his right arm until three months before he died, when it was noticed that the right arm was curving outwards and painful to touch, after which he was kept on his back and left side; but still the right humerus continued to bend, and was most distinctly visible a month before he died.

There did not appear to be much thickening, except at the angle, where it was bent, which felt dense and hard. All the other bones of the body appeared free from any thickening.

There was no history of syphilis, gout, or rheumatism, or blow, or a fall. At the autopsy, no disease was found, except in the shaft of the right humerus, which was bent outwards at an obtuse angle.

Description of specimen.—The right humerus is obtusely curved outwards, about the middle of its shaft, which is here remarkably thicker than natural. The thickening gradually tapers off above and below the curvature, the bone regaining its normal dimensions towards the ends.

On sawing the bone longitudinally (during which its unnatural softness was made evident) the medullary canal opposite the curvature is found to be diminished in size, the osseous substance being here toughest, of a somewhat closely cancellated structure. The wall of the shaft above is distinctly rarefied, and the cancellated tissue within the tuberosity and neck deficient.

The medullary canal, thus unduly large, is filled with pale yellow, soft adipose tissue.

Mr. Shattock's account of the histology.—Horizontal sections through the middle of the enlarged shaft opposite the curvature, show (after decalcification in picric acid) a trabecular framework of well-formed bone of medium density. The substance within its spaces is vascular connective tissue, the cells of which are mostly elongated or delicately branched.

In a few places large osteoclasts lie against the trabeculæ, and abundant evidence of previous absorption appears in the abrupt differences in direction of the bone-corpuscles and striæ in the same trabeculæ.

In most of the spaces ossification is in active progress, the most noteworthy feature being the brushes of stiff-looking osteogenic fibres spreading out from the sides of the trabeculæ; these are traceable in places as "perforating fibres" in the new bone.

New bone formation is proceeding also in the deeper part of the periosteum; the connective-tissue bases are here denser and more fibrous in character.

There are a few brownish-red pigment granules scattered in the connective tissue of the spaces; some of these are contained within cellular elements, others are not. The forms of red blood-corpuscles are distinctly recognisable in some cases, and these have doubtless given origin to the pigment in question.

Longitudinal parings of the rarefied shaft above the seat of callus, examined without artificial decalcification and after staining in picro-carmine, show a bright red transparent edge to the trabeculæ; the central part of the trabeculæ is unstained, and has the ordinary microscopical characters of bone that has not been decalcified.

Remarks by Mr. J. R. Lunn.—The reason why I have brought this case before this Society, is chiefly to have the opinion of others, as it seems to be one of obscurity and extreme interest.

On first examining the case, it seemed to be one of senile atrophy with curving, probably a green-stick fracture.

If the case is one of osteitis deformans, the peculiarity of the disease is that it only affected one bone, and at the onset was more or less acute; it differs clinically from my other case which I reported to the Clinical Society last year; though the microscopical appearance appears something like the section of one of my cases in the 'St. Thomas's Hospital Reports' of 1885.

From the description given by Mr. Shattock of the microscopical appearance, it appears to be a case of osteomalacia occurring in a single bone of an old man.

I am greatly indebted to my friend Mr. Shattock for so kindly assisting me by making microscopical sections of the case.

April 19th, 1887.

---

6. *Case of acute necrosis of the fourth cervical vertebra in a man of forty-eight.*

By Samuel West, M.D.

Henry C—, aged 48, was admitted into the Royal Free Hospital for pains in the shoulders and loss of power in the left hand.

Ten weeks ago the pains began in the right shoulder without any obvious cause. The patient had had no injury or strain. The pain then extended to the left shoulder, and gradually round to the front, after which it became intense in the back of the neck. After three weeks the patient went to a dispensary, and, getting no better, he became an out-patient at the hospital, and a fortnight night later he was admitted, *i. e.* ten weeks after the commencement of his illness.

When seen in the out-patient room he held his neck and shoulders stiff, and the head thrust forward with the chin protruded. To move the head or arms, or to straighten the neck, gave pain, which was felt chiefly in the shoulders and arms.

May 29th.—The patient sits up in bed with the head bent forward so that the chin almost rests upon the sternum, and any movement from this position gives pain. He complains of pain in

the arms from the shoulders to the elbows, but he has no pain in the neck or back. The left arm is flexed across the chest, and he is unable to move it. Pulse 102, respiration 24, temperature 101°. There is tenderness on pressure over the middle cervical vertebræ. The temperature, pulse, and respiration did not vary much for some days.

By June 4th there was less pain in the arms, and the left could be moved a little, but this was only a temporary improvement.

On the 9th a seton was put in the back of the neck.

On the 10th the left arm was almost powerless, remaining flexed, but not rigid on the chest. Some stiffness was complained of in the right arm, and a feeling of pins and needles in all the fingers. There was no impairment of sensation on either side. The patient suffered a good deal from time to time from profuse sweats.

On the 14th this note was taken:—The patient lies half upright on the back as at first with the head bend forward, profusely sweating, especially on the head, but equally on both sides; both legs are completely paralysed, but sensation is retained. Ankle-clonus is considerable, knee-jerks somewhat increased, but reflexes all equal on the two sides. There has been retention of urine for two days, and yesterday a bedsore began to form. In the left arm the paralysis is complete, the sensation is normal, and there is no rigidity. In the right there is great loss of power, but the sensation is normal. There is much wasting of the muscles of both arms, especially of the hand-muscles. The pupils are unequal, the left being a little larger. There is no difficulty in swallowing, and the appetite is good. These leg symptoms have developed rather suddenly in the course of the last thirty-six hours.

15th.—The condition was unaltered, but towards the end of the day the temperature began to rise.

16th.—The patient slept very well until half-past four. At five the nurse found that he had some difficulty in his speech. Some brandy was given, but he could hardly swallow. He sank rapidly and died at seven, the temperature running up to 108° just before death.

Post-mortem examination.—The body appeared healthy. Nothing was to be felt in the neck externally, nor was anything found on dissection until the side of the vertebræ was reached, then on the right side in the sheath of the longus colli muscle an oval fluc-

tuating swelling was felt. On incising this a small quantity of curdy pus escaped, and the bodies and sides of the vertebræ, fourth and fifth, were found bathed in the pus. On further dissection the whole body of the fourth vertebræ was necrosed and bare of periosteum, the joints above and below, together with the intervertebral discs, being almost completely destroyed. The corresponding nerves were soft and yellow. The spinal cord throughout the whole cervical enlargement was swollen, soft, and pale in colour. No change at the base of the brain or over the medulla was present. No cause for the necrosis could be found. All the other organs were healthy.

Acute necrosis of one of the cervical vertebræ in an adult of 48 must be a very rare affection. It is interesting to note the order of development of the different symptoms. The case was clearly regarded for some time as one of shoulder rheumatism, beginning as it did with pains in the shoulders. The next important symptom, beyond the position of the head, was the paralysis in the arms with wasting, but without loss of ordinary sensation. The subsequent rapid termination of the case must have been due to pressure upon the cord, as evidenced by the softening, although no displacement of the vertebræ was evident on the *post-mortem*.

The spinal cord and nerves have been put aside for examination, and if they disclose any changes of interest will be reported subsequently.

There appears to be no case of this kind recorded in our 'Transactions.' *November 2nd*, 1886.

---

7. *Two specimens of osteomalacia, showing metaplasia of the osseous substance into fibrous tissue.*

By Samuel G. Shattock.

Setting aside all speculations on the relation of osteomalacia to other diseases of bone, notably its relation to rickets and to osteitis deformans, its pathological anatomy is sufficiently interesting, and at the same time sufficiently obscure, to justify perhaps the exhibition of microscopic preparations of indubitable cases of the disease.

The sections which I am able to exhibit are taken from two well-known examples of osteomalacia, viz. that of Howship's, the specimens of which are in the Museum of the Royal College of Surgeons, and that of Solly's, most of the specimens of which are in the museum of St. Thomas's.

Neither of these cases has been before examined by the histological methods now in ordinary use, and although microscopic descriptions of these specimens are extant, to say the least, they are not very satisfactory.

The microscopic sections shown have in each case been made from one of the femora where the disease is exceedingly well marked. Howship's specimen (for portions of which I am indebted to Mr. Eve) is thus described in the last edition of the College Catalogue:—

No. 739. "Longitudinal sections (made with a knife) of a left femur affected with mollities ossium. The whole of the osseous substance has been removed from the shaft. In the place of the walls of this part there is nothing but the periosteum, increased to nearly a line in thickness, and of a deep pink and brownish-crimson colour. The space which it encloses is about as large as the shaft of an ordinary female femur, and is filled with a soft, reddish, probably fatty substance, varying in consistency at different parts." Nos. 740, 741, 742, are portions of other of the bones from the same patient, a lady, aged 35, who died five and a half years after the first appearance of the disease.

Solly's specimen (c 13, museum of St. Thomas's) is a vertical section of the upper part of a left femur. The shaft is reduced to a thin shell of rarefied bone filled with a brownish-red, soft-looking substance.

The cancellated tissue of the head, neck, and trochanter is largely wanting; the contents of the resulting spaces (which are mostly well defined and have a fibrous-looking wall) have mostly fallen away. The intervening osseous substance is closer in texture than natural.

There are portions of several bones from the same patient in the museum. The calvaria is also preserved as a dry specimen; it is rarefied, but of natural thickness; its inner surface is smooth and compact, and traces of the outer table are visible externally. The calvaria was so soft as to admit of being easily cut with a knife;

its cancellated spaces were filled with a transparent, gelatinous material.

A similar condition of the contents of the cancellated spaces is noticed also in the sternum, which, moreover, contains numerous cysts; the latter were filled with a material varying in consistence from that of weak jelly to the white of hard-boiled egg, and when recent of a blood-red colour; other of the cysts, now empty, contained bloody fluid. There is a section of the lower end of the femur from the same case in the Museum of the Royal College of Surgeons.

The whole of these specimens were from a woman aged 39 (Sarah N—), in whom the disease commenced four years before death. One of the kidneys contained in its pelvis a large calculus of phosphate of lime, and the urine shortly before death contained a large excess of that salt.

The patient died from the disease in St. Thomas's Hospital, death being immediately due to asphyxia, resulting from the softness of the thoracic wall.

The case is fully reported by Mr. Solly in the 'Medico-Chirurgical Transactions,' vol. xxvii, p. 467.

Remarks.—In both of these cases there is distinct clinical evidence that the disease was progressing at the date of death. The disease, in fact, in each case, was the cause of death. The changes presented, therefore, are those of progressing osteomalacia, and not its after-results.

Rarefaction is the most obvious change shown by these specimens. In Howship's case the only representative of the shaft of the femur is a shell one millimetre in thickness; in Solly's it is scarcely more; and in both this relic of the shaft is itself rarefied. Within the shell the contents of the enlarged medullary space consist of adipose tissue and extravasated blood, and added to these are variously-sized collections of granular blood-pigment. In the parts somewhat removed from the surface (in Howship's case) the blood extravasated between the groups of fat-cells contains round-cells far in excess of those found in ordinary recent coagulation. The hæmorrhage in itself can be held as of only little significance, for the long bones at such a stage are practically flexible tubes, the mere bending or compression of which would entail the rupture of some of the numerous and but delicately supported capillaries of the altered tissue.

But perhaps the most interesting fact disclosed by these specimens—and it is really this that leads me to show them—is the direct conversion of the osseous substance into fibrous tissue.

Bone, as Mr. Savory justly says, is after all only calcified fibrous tissue.

And in osteomalacia (as it is illustrated in these specimens) the bone is unmade, and reconverted after decalcification into connective tissue.

In Solly's case the decalcification and fibrous transformation of the bone proceed so closely that no zone of simply decalcified osseous tissue is recognisable in sections made without artificial softening. But in Howship's there is a distinct interval between the two processes. Many of the trabeculæ resulting from the rarefaction are quite devoid of earthy salts; in others, the central portion still remains more or less opaque from their presence.[1] The decalcified parts retain at first all the characters of bone, except that in some the lacunæ enlarge and ultimately coalesce, as Mr. Durham has described and figured in his paper in the 'Guy's Hospital Reports,' 1864; but as the transformation of the decalcified substance into connective tissue proceeds, the corpuscles of the bone, retaining their position, come to lie in the new tissue, of which they constitute the cell-elements, whilst the decalcified matrix by its fibrillation furnishes the rest.

On the deep aspect especially (in Howship's case) there are spots in which no doubt can arise as to the accuracy of this interpretation; the decalcified trabeculæ pass directly into long wavy bundles of fibrous tissue which partially bound the general adipose medulla.

In Solly's case the fibrous tissue maintains to a large extent the trabecular construction of bone until altered by further metamorphosis. For the connective tissue again is replaced by fat, which doubtless results from the fatty infiltration of its corpuscles.

In Solly's case the soft reddish substance in the tissue of the cranial bones is described by Mr. Birkett as containing round-cells, and very rarely a few caudate-cells.

[1] Mr. Eve, from whom I obtained the material in this case, tells me that he had not submitted it to any artificial decalcification. The sections, whether stained with picro-carmine, hæmatoxylin, or osmic acid, show corresponding appearances.

Mr. Birkett states also that the substance from the cavities in the bodies of the vertebræ was composed of cells like those of pus, or those found in malignant disease, in great numbers. I have examined the coagulated contents of some of the cysts in the sternum and find the same to hold true.

Rindfleisch's view of the cyst formation from mucoid degeneration of the decalcified substance of the bone may thus need modification.

In the remarkable way described adipose tissue is formed directly out of bone; and by Sir James Paget osteomalacia has been viewed as fatty degeneration of bone.

And if it be agreed that the term degeneration shall include this process of tissue-transformation generally, fatty degeneration would be the expression that would best indicate the process.

But the term degeneration has come rather to convey the idea that the tissue resulting from degeneration is, for physiological purposes, destroyed.

To distinguish, therefore, such cases as the present, in which a distinct physiological tissue results from the transformation of another of an allied kind, some new term is needed; and no better term could be offered than that furnished by Virchow—metaplasia.

Lastly, I may be allowed to draw attention to a possible source of fallacy in connection with the study of diseases of bone from museum preparations that have been preserved in spirit. In old museum preparations the spirit has often a decidedly acid reaction.

Dr. Bernays has been kind enough to carefully analyse some spirit of this kind taken from a jar containing a fœtus with spina bifida. There are traces of acetic, of sulphuric, and of phosphoric acids, but the main substance is an acid giving none of the ordinary reactions, and which, as told by its crystallization, is sarco-lactic.

Percentage of acids in 100 *parts of spirit.*

Acetic	·0005
Sulphuric . . .	·0006
Phosphoric . . .	·0037
Sarco-lactic . . .	·028

The sarco-lactic acid is doubtless derived from the muscular tissue, and the presence of such tissue in bulk might lead there-

fore to some degree of decalcification, and under certain circumstances be a conceivable source of histological fallacy.

April 19th, 1887.

---

8. *Case of infantile scurvy. (Card specimen.)*

By T. Colcott Fox, M.B.

Leo L. T—, aged 11 months, an illegitimate male child, born at full term, was admitted into the Victoria Hospital for Children, under the care of Dr. Julian Evans, on April 15th, 1887. The mother was fairly healthy, but not robust. No clue to syphilis could be obtained. The child had never suffered from any special illness. According to the mother's account he was quite strong and healthy until five months old, and then would kick about and dance when supported. After that age he began to get pale, fail in strength and general health, the ankles fell in, and marked head sweats were noticed. The child became constantly sick, throwing up curdled milk, and the bowels were habitually constipated. When the napkins were left off red sand was seen several times at the bottom of the chamber, and the mother was struck by the surprising quantity of urine passed. Two months before admission the roof of the mouth became red and the gums spongy and livid. The nose used to bleed profusely, and one week ago it spurted out freely. For two months the mother also noticed that the child cried when the feet were touched, as if they were specially painful; and five weeks ago the ankles, feet, legs, shoulders, wrists, and hands were swollen, and the eyelids became very puffy and discoloured. The mother stated that on three occasions the face became greatly swollen and the eyelids suffused with blood, but that all traces disappeared in a few days.

For the month previous to admission the child was so constipated that an enema was necessary to produce a motion. The motions were hard and lumpy and dark, but the passage of blood was never observed. The urine was often very thick. For the last week the subcutaneous veins of the hypogastrium had been swollen, and the inguinal glands enlarged. Two days before admission a red patch,

the size of half-a-crown, formed on the dorsum of the left foot and vesicated, the contents of the bleb being bloody. It was suggested to the mother that this might have been caused by the proximity of the cradle to the fire. The mother stated that the swelling of the face and arms, already described, subsided in a fortnight, but that of the legs and ankles continued rather to increase. Since the fifth month of age the child had been gradually ailing and wasting, constantly vomiting food, lying helpless, and of late screaming when handled, and even when approached. A troublesome cough had existed for some time.

Feeding.—Careful inquiry elicited the following facts:—The child took the breast only till three months old, and then the mother, from weak health, had to discontinue it. Cow's milk with water was then given for a month or six weeks, and then for two months Mellin's food made with good cow's milk and water; then Ridge's food used similarly for three months; then Mellin's food was tried again; and finally Ridge's until admission, together with a new-laid egg beaten up in the food and beef-tea for the last few days. No potatoes, arrowroot, or other starchy food of the kind was given. The child was never left unwatched, and seems to have been well attended to by the mother under medical supervision. As for the amount of food given, it was administered "whenever the child wanted it, as he was so ravenous." The mother stated that half a pint of milk a day and half a pint at night were given throughout, except for a few days before admission, when the child would only take half the quantity. The greater part of the milk, however, seems to have been constantly thrown up in curdled lumps, notwithstanding the addition of lime-water.

State on admission.—Extreme general pallor of the skin and mucous membranes, dirty tongue, no fœtor of breath, gums around the teeth spongy and livid, heart beating feebly, and lungs natural. Urine, sp. gr. 1010, acid, with a cloud of albumen; no casts, no blood. The ribs distinctly beaded. Abdomen somewhat distended, with some fulness of superficial veins in hypogastrium, where also resonance noticed to be impaired shortly after child passed urine. No visceral enlargement detected. Arms emaciated. The lower ends of forearm bones slightly enlarged, and the head of the right humerus very distinctly so, and manipulation appeared very painful. The head of the left humerus was thought to be slightly larger than natural. No œdema of arms or hands. The thighs emaciated

but œdematous. Legs and feet very œdematous, helpless, and feeling broken up, as if they had been run over; and on the dorsum of the left foot a round surface, size of a penny, of congested skin with a bullous periphery, as if about to slough.

The child screamed when the legs were touched, and it was impossible to examine them very carefully. The mother said that the legs for some time had felt as if they were broken. She was also positive that the œdema had been at times very great, but had varied. It had been mostly about the loins, face, neck, and eyes.

On the 16th the child passed two motions without medicine or injection; the motions yellowish and rather constipated.

The temperature was 98° F. on the day of admission, but rose through that night and the early morning of the 16th to 101° F. at 8 a.m. With a slight remission in the day it rose again to 101·8° at 8 a.m. on the 17th; then, with another slight remission during that day, it rose to 104·2° early in the morning of the 18th, when the child died.

Post-mortem examination ten hours after death.—No purpura of skin; some œdema of ankles. Considerable layer of fat on the body.

Head: Cranial bones very thin, but firm, and without craniotabes or bosses. No hæmorrhages within or without.

Chest: Heart pale, but otherwise healthy. Lungs: Slight congestion of lower lobes. Ribs markedly beaded, especially on inside, brittle, and easily broken on trying to bend them. No hæmorrhages under periosteum of ribs, or anywhere in thorax.

Abdomen: No hæmorrhages. Liver very pale, but of natural size. Spleen not enlarged. Kidneys very large and pale, capsule not adherent. Intestines healthy.

Bones: Right humerus fractured through the middle third; upper epiphysis widely separated by blood-clot. The periosteum completely stripped from the shaft in its whole length by hæmorrhage. Left humerus unaffected. The forearm bones showed distinct rickety changes, at the wrists especially, but were otherwise natural. Scapulæ unaffected. Pelvis: Both ilia unduly soft and yielding, right more than left, the cancellous tissue in its centre being blood-stained, and the periosteum separated by hæmorrhage. The rim of the left ilium loosened, as if partially separated from the body of the bone. Over the back of the sacrum a small hæmorrhage, perhaps from pressure.

Right femur: Periosteum entirely stripped from the bone, which is bare, a distinct layer of blood intervening between the bone and periosteum. The quantity of extravasated blood plainly shows through the unopened periosteum in this and the other bones. There is an irregular, rather oblique fracture of the lower end of the shaft about the epiphysial line, and a similar state of things at the upper epiphysial line. The ragged ends of the fragments are widely separated by blood-clot. The knee-joint healthy.

Right tibia: Both epiphyses completely separated, and some irregular splintering of the bone immediately adjacent to the epiphysial line. Periosteum completely separated from bone by hæmorrhage. Comminuted fracture in centre of shaft.

Right fibula: Comminuted fracture through the middle of the shaft, and complete separation of the epiphyses by blood-clot. The periosteum entirely stripped off the shaft.

Ankle-joint healthy, but there is a good deal of fluid effused beneath the periosteum of several of the tarsal bones.

Bones of the left lower extremity: The lesions are precisely the same as on the right side, and there is a remarkable symmetry about them.

Muscles: There was not any hæmorrhage into or between the muscles of the body; but Dr. Harper, the house physician, to whom I am much indebted, called my attention to the remarkably greasy state of all the muscles.

Remarks.—The fractures through the shafts of the tibiæ and fibulæ and right humerus seem to have been spontaneous, or at any rate not brought about by rough handling or ill-treatment. Careful inquiries were made, and the impression left was that the mother had very tenderly nursed her child throughout.

The rickety element in the case was distinct, but moderate.

April 19th, 1887.

9. *Extensive disease of the bones from a case of congenital syphilis associated with rickets.*

By WILLIAM HY. BATTLE.

THE patient from whom the specimens which I show to-night were taken was a boy, aged 3 years and 10 months, who came under the care of the late Mr. Francis Mason in St. Thomas's Hospital on the 13th of January, and died on the 30th of May, 1885.

He was illegitimate and the only child of his mother, a general servant, who had put him out to nurse.

No history of syphilis could be obtained, the mother denying symptoms of the disease, seldom coming to see the patient, and knowing little about the child, who had apparently been neglected. She could tell nothing about the father.

The boy was said to have been delicate, especially during the last two years. About a year before admission the left arm was said to have been broken, after which the left elbow began to swell; this was soon followed by swelling of the right elbow, and about nine months ago by swelling of the right knee. During the month before he came into hospital there had been progressive emaciation, sleeplessness, and great tenderness all over when touched. He attended the out-patient department for some time under the care of Mr. Bernard Pitts, who treated him with mercury; he found, however, that the child did not respond to treatment, being probably improperly fed and nursed, and therefore sent him into the hospital.

On admission the boy was very anæmic and waxy in appearance, much emaciated, with loose wrinkled skin. The face was old-looking and thin, the angles of the mouth wrinkled and drawn in, the forehead high and broad, there being well-marked bosses in the frontal and parietal regions on each side. The fontanelles were closed. The eyes were normal, and there was no evident disease of the teeth or nails. Examination of the left upper extremity proved thickening of the lower end of the humerus, with free mobility between the epiphysis and shaft; the joint was fixed.

A small sinus existed over the olecranon which did not lead to bone. The head of the humerus was also greatly enlarged, and free movement was permitted between the shaft and the epiphysis; there was also thickening along the shaft. The right elbow was fixed, but the epiphyses, which were enlarged, were not movable on the diaphysis.

The right lower extremity was greatly deformed, the shaft of the femur being bent forwards, and the lower extremity of the bone turned outwards. The whole bone was greatly enlarged and the lower (enlarged) epiphysis movable. Mobility also without crepitus was obtainable about an inch and a half above the right ankle, also below the left knee where the bones were thickened and tender. The rickety rosary was well marked. Several bruises of recent origin were visible over the front of the right thigh, the sacrum, and the legs. There was no evidence of visceral disease. The temperature at night was 103°, the next morning 98°. He refused to take solid food, and was thirsty. The bowels were regular. Pulse 128.

January 20th.—There is more swelling above the left ankle with œdema of both feet.

28th.—The boy is losing flesh, has a very bad appetite, and sleeps little. No vomiting or diarrhœa, but motions are dark (probably from the iron which he is taking) and offensive. A slight sore which was found over the sacrum on admission is spreading. He keeps the right thigh flexed on the abdomen; it is now about four times the size of the left, the skin is very tense, fluctuation being evident as low as the tibia, with much tenderness; the superficial veins of the thigh are dilated. The left tibia is now deformed, the diaphysis being displaced outwards and backwards, the epiphysis projecting prominently on the inner side, whilst the line of junction of the two is so yielding that free movement can be obtained, but not without pain to the patient who occasionally cries with the pain of the leg, only ceasing when it has been propped up with pillows. On the upper gum in the situation of the incisor teeth, displacing the right lateral incisor outwards, is a purplish projection half an inch broad, resembling a vascular epulis; this has only been noticed for two days.

30th.—A puncture was made into the outer side of the right thigh, but no fluid was found.

February 2nd.—Bedsore spreading. The child is more feeble,

taking very little food. Pulse 136. The epulis is enlarging and causes projection of the upper lip.

13th.—Bedsore spreading deeply and superficially, also sores on the elbows. Body more emaciated and skin wrinkled. There appears to be more marked fluctuation in the right thigh with œdema of the upper part.

20th.—The epulis has disappeared. The sores are closing and healing well. Child thinner, but improved.

March 3rd.—On February 28th a weight of two pounds was applied to each leg, and the limbs are now much straighter. The right thigh has diminished to half its former size, and it is now comparatively firm; the upper part of the swelling being hard as if from commencing ossification.

May 29th.—There is increased emaciation, and the child has a more waxy, anæmic appearance; the mouth is dry and the aspect very anxious. It was not possible to retain the extension apparatus on the legs because of the swelling. There was profuse sweating yesterday and the day before, but no diarrhœa. He now lies partly turned on his right hip, with both hips and thighs flexed, the deformity of the limbs appearing exaggerated. Both legs and feet are swollen with shiny white skin, and over the lower one third of the right tibia there is well-marked fluctuation, whilst the thickening of the right femur, which appeared to be undergoing organisation, now seems to have retrograded, for there is much fluid in the thigh.

He died on the following morning at 9 o'clock.

For the first month the evening temperature was usually higher by one or two degrees than the morning, not, however, exceeding 101·2°. During the remainder of the time it occasionally presented the same character for a night or two, not exceeding 101·8°, but was more frequently subnormal, sometimes below 96°, and often only 97°.

Treatment.—January 14th.—Vin. Ferri et Ol. Morrhuæ, āā ʒj, b.d.

15th.—Syr. Ferri Iod., ʒss; Ol. Morrh., ʒj, b. d.; Hyd. c. Cretâ, gr. ij, nocte maneque. Ol. Morrhuæ to be rubbed into the chest at night.

29th.—Lotio nigra to bedsores.

February 25th.—Hyd. c. Cretâ, gr. iij, night and morning.

March 9th.—Vaseline and iodoform to the sores.

30th.—Succus Limonis, ʒj; Aq. et syrup., ad ℥j, t. d.

At the *post-mortem* examination (Dr. Hadden) "all the internal organs were healthy excepting the lungs, which showed much broncho-pneumonia and collapse posteriorly, and in the lower lobes. The disease was most marked in the right lung."

The other long bones presented a condition somewhat similar to that seen in the specimens which I show to-night and were not preserved. A thin, semi-purulent fluid escaped from under the periosteum when incised. The joints were healthy.

The skull-cap, which is markedly natiform, presents four bosses, two frontal and two parietal. The anterior fontanelle, which appeared firm during life, has never been completely closed, the small irregular interval between the bones being filled up by membrane. The surface of the skull is quite smooth excepting over the right parietal node, where it is porous, somewhat granular, and marked by numberless irregular lines, elevations, and openings for the passage of small vessels; this appearance extends over an area of about two and a half inches diameter. Section of the right anterior node, which is three eighths of an inch in thickness, shows much spongy bone between two layers of compact tissue, the superficial layer being extremely thin, a mere shell; the lower consisting of several dense layers, which are plainly visible to the naked eye, the intervals between becoming rapidly more marked until they are lost in the somewhat spongy portion. Along the sutures the bones are thinned, but nowhere completely absorbed.

The second specimen shows the sternum with the sternal ends of the clavicles, the costal cartilages, and attached portions of ribs. The ends of the bones are markedly enlarged, and the spongy tissue much rarified; the compact tissue is very thin. In some of them there is an area of great vascularity about the centre of the spongy portion where attached to cartilage. The section of the sternum also shows the centres of ossification.

The left lower extremity.—There is a solution of continuity at the junction of the lower end of the diaphysis with the epiphysis of the femur, the periosteum being separated from the former for nearly the lower half, completely below, more irregularly above. The periosteum is much thickened and vascular; but the only evidence of repair is the presence of a small patch of new bone adherent to the shaft, about one and a quarter inch from the extremity on the posterior surface. The end of the diaphysis, exposed by removal of a portion of the periosteum, is whitish in colour, and somewhat

worm-eaten on the surface. The medullary tissue having been absorbed, leaves a mere shell of compact tissue. The epiphysis is hollowed out, probably by the movement during life of the necrosed end of the diaphysis; there being considerable loss of substance from its interior. The neck of the femur appears shortened.

Tibia.—A similar necrosis with separation has taken place at the lower end of the shaft of the tibia; but here the changes are less extensive, the separation of periosteum extending only for a short distance up the diaphysis, whilst the loss of substance from the epiphysis is less extensive. The upper epiphysis is displaced inwards but firmly united.

Fibula.—The lower epiphysis of this bone is movable on the shaft, but on section is found not to be separated, the movement being permitted by a zone of soft material at the junction of the two portions.

Left upper extremity.—The upper epiphysis of the head of the humerus is separated and hollowed out into a kind of socket for the end of the necrosed shaft. The necrosis in this instance extends downwards to the lower end of the shaft, the periosteum being thickened and separated throughout. The whole diaphysis appears necrosed, and there is a small portion separated from the diaphysis at the lower end, which is still adherent to the epiphysis.

The epiphyses of the ulna and radius appear to be firmly attached, but are enlarged, the enlargement being due to an increase in the proliferating cartilage, above which the bone is softened, and sections carried through the bone show the medullary cavity filled with gelatinous material, the compact tissue forming a mere shell.

I do not think that there is much doubt but that this was a case of congenital syphilis. Omitting the clinical record the evidence afforded by the appearance of the skull is such that it can hardly be contradicted. The appearance of the right parietal node being especially characteristic of that disease. The extensive and widely spread mischief of the bones which is here shown, commenced in the neighbourhood of the epiphyses and spread thence to the diaphyses, in one instance to the whole of the diaphysis of the humerus, which was found lying loose and dead in the thickened periosteum, which held it in position.

It is not uncommon to meet with well-marked cases of congenital syphilis in which a similar process to that found in the case which

I bring forward has progressed near a joint, where suppuration has followed, and the bone bared and necrosed has presented on the incision of the abscess, in a state shown by the lower end of femur in that specimen. Neither is it uncommon to find more than one epiphysis affected, but it is extremely rare to find such a multitude of centres of disease as in this instance. It seems probable that this was an example of that form of the disease in which there is a tendency to the deposit of new bone tissue; of this we have evidence in the condition of the skull, in an attempt at ossification of the effused fluid around the right femur at one period of the boy's residence in the hospital, when his health had temporarily improved, also in the deposit of new bone which is seen on the posterior surface of the femur. And one explanation of the condition ultimately found is that the organisation of the new material failed, because of the extremely poor nourishment of the tissues, the result of bad feeding, bad nursing, and of the unfavorable conditions to which he was exposed before he came into the hospital, and from the effects of which he was unable to rally. The rickety condition of the skeleton may also be ascribed to the same causes. I would also draw attention to the different behaviour of the bones developed from membrane and those developed from cartilage; the deposit in the former instance showing no sign of absorption. Other points to which I would draw attention are, the absence of joint affection, and the attachment of the periosteum to the margin of the epiphyses.

A remarkable clinical feature is the almost entire absence of hectic, or even of pyrexia, which was observed during the progress of the case, although suppuration was present at so many different points. *May 17th*, 1887.

---

10. *Tubercle of the skull leading to perforation.*

By Bilton Pollard.

The subject of this communication was an example of a rather rare disease of the skull—tuberculosis, leading to perforation of the bone.

The patient was a female child, aged 10 months when she first came under observation at the North-Eastern Hospital for Children. At that time there were four chronic abscesses on the skull, for which no cause could be assigned. The child was well nourished, and presented no other signs of disease.

There was no family history of either syphilis or tubercle, and the child had not presented any of the usual signs of congenital syphilis. The abscesses were opened, and found to be situated immediately over the bone. Each was scraped out, and a quantity of caseous material and tubercular granulation tissue was removed. They were dressed with iodoform and antiseptic wool. In the course of a few weeks the smallest abscess healed, but sinuses surrounded by fungous granulation tissue remained at the site of the others, and a fifth abscess developed over the occipital protuberance. It was treated like the others, and ran a similar course. The sinuses were scraped out on two subsequent occasions, but they failed to heal.

Four months after the patient first came under observation the sinuses were opened up, and a sequestrum was found at the bottom of each. The sequestra were removed, and a quantity of tubercular granulation tissue was scraped away. Three of the abscesses healed soundly, but that over the occipital protuberance never quite healed. After the removal of the sequestra the child rapidly lost flesh, and two months afterwards she died.

At the *post-mortem* examination the bronchial glands were found enlarged and caseous, and there were a few patches of caseous tubercle in the lungs. The mesenteric glands were enlarged, but no caseous foci were detected in them. There were no signs of syphilis or rickets. There were four perforations in the vault of the skull. The skin covering three of these was soundly healed, and the borders of the same three perforations were smooth and healthy. The lower margin of the perforation in the occipital bone was smooth, but the upper margin was irregular and "worm-eaten," owing to the persistence of the disease at that spot up to the time of the child's death. At the situation of the smallest abscess, which healed after scraping alone, there was a pit in the bone, but no perforation. The dura mater was quite healthy, and there was no disease of the other membranes of the brain. The granulation tissue, which was scraped away, presented the microscopical structure of tubercle, but no bacilli were detected in it.

The pieces of bone which were removed have been referred to under the name of sequestra, but they were not really necrotic; they had in parts a reddish tint, and one of them, which was examined microscopically, was infiltrated with granulation tissue, in which there were numerous giant-cells. The bone corpuscles were apparently degenerated, for they failed to take any stain. Tubercle bacilli were not detected in the giant-cells, but the naked-eye and microscopical structure was sufficient to prove the tubercular nature of the bone disease.

Volkmann ('Centralblatt f. Chirurgie,' 1880, p. 3) has drawn attention to perforation of the bones of the skull occurring as the result of tubercle, and has given short abstracts of the last seven cases of a total of eleven, which had come under his observation. In some of his cases necrosis and in others caries of the skull resulted. In some, after perforation of the skull had occurred, pulsation was communicated from the brain to the superjacent abscesses. Volkmann's experience of tubercular disease of the skull appears to have been peculiarly large, for but few references to it can be found in English literature.

Dr. Edmunds ('Brain,' April, 1885) has recorded a case in which tubercular disease led to the separation of a piece of bone involving the whole thickness of the skull, and measuring seven eighths by five eighths of an inch.

Dr. Barlow tells me that he has met with extensive tubercular disease about the temporal bone, and I have but little doubt that many cases of chronic suppurative disease of the ear are of a tubercular nature.

When the disease is situated in the vault of the skull it is easily accessible to treatment, and both clinical and pathological observations point to the desirability of applying radical measures early. The tubercular disease tends to spread in the bone, and between the bone and the dura mater. The mere opening of the superficial abscess and the removal of caseous débris is rarely followed by healing. The diseased bone should be freely exposed and completely removed as early as its condition is detected.

February 1st, 1887.

11. *A new growth, apparently springing from the periosteum of the right clavicle, and extending into the triangles of the neck, &c.* (*Card specimen.*)

By J. R. Lunn.

J. C—, aged 64, clerk, admitted into St. Marylebone Infirmary November 18th, 1886, with a large growth apparently springing from the right clavicle, which he had only suffered with two weeks before admission. The growth gradually extended in all directions, and pushed the trachea towards the left. Tracheotomy was performed to relieve the patient, but he died December 24th, 1886. No secondary changes were found, except some suspicious scattered nodules over the superficial surface of the liver.

(A specimen of the growth was shown under a microscope.)

January 4th, 1887.

---

12. *Sarcoma of clavicle.* (*Card specimen.*)

By William Bull, for Mr. Rouse.

A large spindle-celled, and in some places myeloid-celled, sarcoma, originating after an injury, in a man aged 29. Existed seven weeks before it was removed. The growth is from the periosteum, and had involved the subclavian vein, which was partly embedded in the tumour, and was wounded in two places. The vein was tied at the points of puncture.

The man died on tenth day from septicæmia. The wounds in the vein were found healed. *May 17th*, 1887.

---

13. *The sequel of a case of central sarcoma of the femur.* (*Card specimen.*)

By D'Arcy Power, M.B.

A section through the head and upper third of the shaft of a femur. The medullary cavity of the shaft and of the neck of the bone, nearly as high as the epiphysis, is invaded by a new growth. At the lower part of the shaft the growth has extended beyond the bony wall, invading the surrounding muscle and connective tissue. Microscopically, the growth is a round-celled sarcoma.

The details of the case, with drawings of the primary tumour, were published in the 'Transactions' of the Society, vol. xxxvii, p. 377, and Plate XIV, figs. 2, 3, and 4.

The patient, a gentleman aged 28, had suffered pain in his right thigh for four months. On examination a tumour was found in the long axis of the femur. Shortly afterwards, whilst turning in bed, the femur broke. Amputation was performed, and the patient made a good recovery.

Microscopical examination showed that the growth consisted of a round-celled sarcoma, which in its lower part was mixed with a large quantity of fibrous tissue, and was undergoing calcification.

In consequence of a recurrence of the growth, during which the patient twice experienced a sharp attack of pain, Mr. Langton disarticulated the stump of the femur, exactly seventeen months after the amputation had been performed.

The specimen is preserved in the Museum of St. Bartholomew's Hospital, Series I, No. 475 (*b*). *April 5th*, 1887.

---

14. *Sarcoma (?) of the lower end of the femur.*

By Jonathan Hutchinson, F.R.S. and J. Hutchinson, junr.

Difficulties in the diagnosis between syphilitic gummata and new growths are not of infrequent occurrence, but I have never met with a case in which it was more nearly impossible to

remove doubt than in the present instance. Not only was there difficulty before the operation, but it remained after exploration by the knife, and even after microscopic examination of sections had been made.

The patient was a gentleman in the army, of splendid general development. He had, it was believed, suffered from syphilis several years ago, and he had lost his mother and two cousins from tumours of a malignant nature. One cousin had died after amputation through the thigh for a tumour of bone. With this double history Mr. F— came under my care with a soft swelling nearly as large as a fist over the inner condyle of the left femur. The swelling was sessile and apparently sprang from the bone. It was soft and might have been supposed to fluctuate. The parts over it were quite sound. There was a moderate amount of effusion into the knee-joint, but Mr. F— could still walk about without much pain. The evidence as to the former attack of syphilis was by no means conclusive. At first I certainly thought that the swelling was a soft periosteal node, and this belief was strengthened by his statement that it had on one occasion for a time considerably diminished. The surgeon who sent him to me from India had already prescribed specifics, but hitherto without definite result. I treated Mr. F— with large doses of iodides for six weeks, and then finding no diminution I gave mercury to full ptyalism. As the swelling got larger rather than otherwise, I now began to change my opinion and to suspect that we had to do with a new growth, and that it was unwise to defer an operation any longer. A consultation with the President of our Society, Sir James Paget, confirmed this suspicion, and it was determined at once to make an exploratory incision into the tumour with permission to amputate if it should seem desirable.

This was done, and the circulation being well controlled by an Esmarch's strap, I had an excellent opportunity for inspecting the state of things. After division of the overlying vastus muscle I came upon a smooth glistening capsule, on incising which an almost opaque whitish material bulged freely. Its appearance was exactly like that of a soft sarcoma of encephaloid structure, and for a moment I felt quite confident as to the diagnosis. On going deeper, however, a considerable quantity of a glairy chocolate-coloured fluid escaped, not unlike the contents of a bursa, and when this was emptied, an extensive surface of roughened bone was

exposed. In an examination which was continued some little time the greater part of the very soft solid structure was squeezed out and lost. There remained only an empty capsule and a patch of bare bone roughened by outgrowths. The bone was not softened, and there was no evidence of growth into it or from it. The case had now again assumed to a considerable extent the features of a node. As the diseased bone was close to the knee-joint, and as the latter was indeed involved, the finger passing readily into it, I resolved to amputate, feeling sure that whether the disease was a gumma or a growth there was but little chance of recovery with a useful limb. The amputation was accordingly proceeded with, and the patient subsequently recovered without ever having had a single drop of pus or a degree of increase of temperature.

It has been noted that the tumour was seated in front on the inner aspect of the internal condyle and adjacent part of the shaft of the femur, projecting beneath the synovial membrane into the joint. As regards the rest of the joint, along the cartilaginous margin of the condyles there was slight formation of lymph and considerable congestion of the synovial fringes; there was perhaps an excessive development of fat under the quadriceps, &c. There were no enlarged glands in the popliteal space.

The growth was almost circular in outline, nearly three inches in diameter, and for the whole of this extent the subjacent bone was superficially eroded and slightly softened. At the same time there seemed to be at the margin new formation of bone and cartilage in small irregular spicules. At the upper part of the tumour there was a well-defined margin of fibrous tissue, and the overlying vastus internus was not in the least invaded. The central part, consisting of thick fluid suggesting synovia had escaped, the more peripheral part was composed of whitish, irregular projections, and about the nature of this there was some uncertainty.

It may be said that it chiefly consisted of fibrous tissue with a considerable mixture of round and stellate cells, of a great number of microscopic vessels, round some of which were closely packed masses of round-cells. Here and there the tissue stained badly, and had evidently degenerated, but it must be noted that to naked-eye examination there were no typical gummatous deposits. The vessels, which were evidently to a large extent of new formation,

being as a rule destitute of any elastic lamina, and often of any trace of a muscular wall, were often arranged in rows. One of the most prominent features of the growth was the extreme thickness of the vessel walls; many of them had their lumen practically obliterated, in others the intima was infiltrated with round-cells, much thickened, and sometimes apparently detached. This condition seemed to me so unlike that met with in true tumours, and was so suggestive of syphilitic growth, that I believe the latter diagnosis to be correct.

Mr. Eve, however, who kindly examined the sections, was inclined to regard it as a peculiar form of angio-fibro-sarcoma. It has already been said that the margin was sharply defined, and had, indeed, a sort of fibrous capsule at one part, but since the bone was involved sections were examined of this to see if there was any invasion of sarcoma elements. On the contrary, the fibrous tissue here predominated; there were neither round- nor spindle-cell accumulations. Irregular patches of hyaline and fibro-cartilage existed, which must have been of new formation, and spicules of bone. This fact, together with the extensive erosion of bone, seemed to point to an irritative lesion, such as a syphilitic growth, rather than a sarcoma. It should be mentioned that no giant-cells were found, and there was not the slightest evidence in favour of a strumous node. The same curiously thick vessels, with very small or obliterated lumen, were found amongst the spicules of bone. The question whether this endarteritis obliterans is, apart from arterio-capillary fibrosis, good evidence of a syphilitic origin, is an extremely interesting one, and was particularly raised by Dr. Greenfield in his paper on "Visceral Syphilis," in our 'Transactions' for 1877, and several other observers discussed it in the same volume. Dr. Greenfield writes: "My belief is that the change in the vessels is the effective agent in the process of decay, and is at the root of the peculiar characters presented by gummata. Whether it is peculiar to them or is common to chronic inflammation, and only more extensive and common in the former, my own observations do not permit me to say."

If a sarcoma, this tumour was one in which fibrous tissue formed a large part, and was evidently of slow growth. The tendency of periosteal sarcomata in this region to infiltrate widely and to rapidly destroy life is well known, and it is a question whether fibro-sarcomata are met with in connection with the lower end of the femur.

Mr. Rickman Godlee records, in vol. xxxii of our 'Transactions,' a case in which a small fibro-cellular tumour was attached to the outer condyle by a broad pedicle, and which was removed by an incision into the joint. Mr. Godlee suggests that it arose from inflammatory thickening of one of the synovial fringes; but in this case the tumour was firm and white on section, and there was no lesion of the bone. This is the only record of a similar tumour in this position, and the resemblance is by no means close. The failure of specific treatment is, of course, not conclusive against a syphilitic origin. It may be said that the marked vascularity of the growth is somewhat against it, but syphilitic deposits in their early stages are certainly often very vascular. Thus Dr. Greenfield believes that "a special tendency to profuse hæmoptysis with slight lung disease in cases of syphilis is dependent partly on the high vascularity of the connective-tissue growth in its early stages," and the same free development of new vessels is seen in the deposits of lymph in specific iritis. Unfortunately, records and drawings of syphilitic joint disease are rare, but in one figured in H. Marsh's 'Diseases of Joints' (a periosteal gumma of the lower end of the femur) there are some marked features of resemblance to the present case. As regards the central softening, it may be noted that Ziegler states of syphilitic nodes, "Varieties which are poor in cells, such as are found at times in bone, are soft and gummy in texture. On section they have a gelatinous look, the liquid constituents exceeding the cellular in quantity. The older surrounding tissues undergo a mucoid change." *May 3rd*, 1887.

Report of the Morbid Growths Committee on Mr. Hutchinson's specimen of sarcoma (?) of the lower end of the femur.—The preparation, when received, showed an area of softened, porous bone, surrounded by the remains of the covering of the original swelling.

To further display the characters a section was made, when the following appearances were found:—beneath the irregular surface above referred to was seen a patch of softened bone, reaching below nearly to the articular cartilage, and upwards from this point for nearly two inches, while it extended almost half way across the lower end of the femur.

This area showed much pale gelatinous tissue at its periphery, more particularly where this reached the surface. In this small

spicules of loose bone, some of them of a yellow colour, were found. In the central part the colour was reddish, and the material diffluent, like degenerating medulla. Nowhere was the bone absent, but it was extensively absorbed, and the trabeculæ, reduced in size, and in places loose, were embedded in the granulation tissue.

The deep limit was marked by a border of condensed bone. The compact layer of bone on the surface was much thickened and blended with the periosteal new bone, which gave rise to considerable thickening of the lower end, around the periphery of the original swelling. These appearances point to an inflammatory origin rather than to a new growth. In confirmation of this view the absence of the dense infiltrating material usually seen with periosteal sarcomata may be noted, as well as the absence of any uniformity in the structure and arrangement of the morbid material.

The microscopical appearances have been well described and illustrated by Mr. J. Hutchinson, jun., but the Committee thinks that they point more in the direction of an inflammatory formation than of a new growth. The vessels are very numerous; many are developing, and are embedded in a delicate connective tissue, which shows a state of development not found in sarcomata. The thickened vessels, again, resemble those seen in chronic inflammatory processes, notably in those of syphilis and tubercle. The absence of any signs of caseation in these sections is a noticeable feature; but here it must be remarked that the sections were taken from the surface of the swelling, a situation where the growth would be progressing. Whether the cause of this disease be syphilis or not is, perhaps, more difficult to decide; but looking to the size of the external swelling; to the amount of new periosteal bone around the diseased area; to the thickening of the compact layer of the bone; to the vascular condition of the tissues, as shown by the microscopical sections; and to the arrangements of the elements composing this tissue, the Committee is inclined to attribute the disease to syphilis rather than to any other cause. Tubercle, the only other affection which would be at all likely to be confused with this, appears excluded, both by the naked eye and microscopical appearances.

It may be added that Mr. Hutchinson's description of the nature of the material removed at the time of the operation, taken with the

appearances seen on section of the bone, appear to support the conclusion that the case was syphilitic.

J. F. PAYNE,
SIDNEY COUPLAND,
ANTHONY A. BOWLBY,
CHARTERS J. SYMONDS

Appendix.—A microscopical section taken from the softer area above described showed the spicules of bone surrounded by many large osteoblasts, and separated by a tissue in part fibrous and hard, and in part having a loose texture like that seen in mucoid tissue. Numerous areas of proliferating hyaline cartilage were also visible. Taken as a whole, the appearances were those of a chronic ostitis, and while not tubercular, there was nothing to indicate a syphilitic nature, though this appears to be the only other cause that could give rise to such changes.

---

15. *Cystic enlargement of metatarsal bone; sarcoma.* (*Card specimen.*)

By JOHN H. MORGAN.

THE specimen was removed by operation from a girl aged 12 with healthy family history.

Enlargement of the metatarsal bone had been observed for nine months, and had gradually increased. At the time of operation there was a firm oval swelling, moderately hard, not painful on pressure. No redness of skin, no dilatation of veins, no enlargement of glands.

The great toe was amputated at the tarso-metatarsal joint. Both epiphyses of the bone were found to be perfectly healthy, the middle or shaft only being altered. This consisted of a very thin dilated shell of bone, the interior of which was lined with a thick membrane showing septa and dividing it into irregular cavities. These contained a thick brown fluid.

Microscopical examination and report by Dr. Mott.—The sections show in parts a dense fibroid growth, consisting for the most part

of nucleated spindle-cells. Irregularly scattered in this are small islets of calcareous matter surrounded in some instances by osteoblasts. Other parts of the section show a much less dense structure consisting of a fibro-nucleated blastema and branched cells. In this softer part of the growth are very numerous multinucleated cells contained either singly or in small groups in irregular spaces. There are numerous vascular spaces seen throughout the growth, the walls of which cannot be differentiated from the surrounding structures. *May 17th*, 1887.

---

16. *Congenital dislocation of the hip.*

By Anthony A. Bowlby.

This specimen was removed from a girl aged 13, who died in St. Bartholomew's Hospital on April 7th, 1884, of a malignant growth of the stomach, which was exhibited at a meeting of this Society by Dr. Norman Moore on November 18th, 1885.

The lameness from which she suffered was noticed on her admission, and in answer to inquiries made of her father after her death, when the condition of the hip-joint had been ascertained, the following facts were elicited. She was the first child of the family. The labour was easy and natural, no interference being required. Nothing was noticed amiss with the leg before the child commenced to walk, and lameness was not very noticeable before the age of three. She had met with no accident, and had never suffered from symptoms pointing to any disease of the hip. No other member of the family had been similarly affected.

An examination of the specimen when recent showed that the head of the femur was not in its normal position, and after dissection the following conditions were found.

The whole of the right innominate bone has, unfortunately, not been removed, the section passing through the obturator foramen at a point corresponding with the lower part of the acetabulum. In the position of the normal acetabular cavity is a triangular depression, which although it evidently represents the acetabulum, is far too small to have accommodated the head of the femur at

any time. The floor of the depression is covered in its upper part by cartilage, which in the lower half gradually thins away so as to leave the bone uncovered. The edges of the depression are scarcely raised above the level of the surrounding bone. The upper portion of the normal acetabulum, which, from being formed by the ilium may be called the iliac segment, and which extends normally from a point below the anterior inferior spinous process of the ilium obliquely backwards to the ischium, appears to have been suppressed, so that the ill-developed acetabulum, represented by the above-mentioned triangular depression, is formed merely by the coalescence of the pubic and ischiatic segments. In consequence of this malformation the antero-posterior diameter of the bone from the spine of ischium to the anterior inferior iliac spine is shortened, and the sciatic spine being thus rendered less prominent the shape of the great sciatic notch is altered, so that its lower margin, instead of presenting a concavity upwards, presents an almost plane surface directed backwards (see Plate XV).

Upon the dorsum ilii, immediately above the apex of the triangular depression representing the acetabulum, is a slightly depressed surface of bone covered by dense fibrous tissue, which in the recent state was continuous with a fibrous capsule placed around the head of the femur, the latter resting on the dorsum ilii at this place. No attempt has been made at the formation of a fresh socket, either by absorption of the ilium or by development of new bone. The ilium itself is abnormally smooth, all the ridges for attachments of muscles being extremely slight.

The head of the femur is but little smaller than natural. Its shape, however, is altered, for it is ovoid and somewhat flattened, although covered in all parts by normal articular cartilage. The ligamentum teres is absent, and there is nothing which would lead to the supposition that it has ever existed. In place of the slight depression on the head of the femur for the insertion of this ligament there is a slight projection which, though quite smooth and rounded, is evidently partly composed of fibrous tissue.

I have brought this specimen before the Society because it illustrates a cause of congenital displacement which is but too little recognised. Other instances of imperfect development of the acetabulum have been recorded, and three specimens from the museums of Charing Cross and St. Thomas's Hospital, almost exactly resembling the one now exhibited, have been kindly brought

here this evening. I am myself disposed to think that deficiency in the acetabulum is perhaps a more frequent cause of congenital dislocation than any other, and this view is borne out by the conditions that obtain in other joints which are more rarely the seat of similar displacements. Thus, in the shoulder, the glenoid cavity has been found undeveloped in cases where the humeral head was natural; in dislocations of the head of the radius there is usually a deficiency of the corresponding articular surface on the humerus, and in those of the patella an imperfect development of the external condyle of the femur. It is of course tolerably certain that other causes besides abnormality of the acetabulum produce congenital dislocations of the hip, although amongst them I am myself not disposed to include breech presentations, or other abnormal labour, or the use of instruments during parturition.

My reasons for dissenting from such views, although they are generally accepted, are, that in the large majority of cases, and in the one here recorded, there is no evidence whatever of abnormal labour or the use of instruments; that it is extremely difficult to dislocate one or both femurs when the thighs are flexed on the abdomen by any force applied from behind and below, or, when the thighs are extended by direct traction; that no specimen has ever been dissected in which tearing of the muscles and ligaments has been demonstrated; that in almost all of the cases examined after death some abnormality of one or other of the articulating surfaces has been found, whilst the capsule has been intact, enclosing the head of the femur; and lastly, that it is very unlikely that both femora would be mechanically displaced, as is often the case in these patients.

Another theory explains these congenital displacements by hip disease in the fœtus. The following facts seem to me to be opposed to such a view. 1st. The patients in whom the deformity occurs are commonly healthy, and show no evidence of tubercle or struma. 2nd. Suppuration is never seen in these cases. 3rd. Ulceration of cartilage, caries, and necrosis have never been described. 4th. The limb develops in a normal manner after birth, the displaced femur in cases of unilateral displacement equalling its fellow in length, conditions which are commonly reversed when hip disease occurs in infants. 5th. Disease of the joint does not explain the abnormal development of the acetabulum to which I have alluded.

Into the other causes to which congenital dislocation of the hip has been attributed I do not propose to enter, for most of them are purely theoretical and difficult to prove or disprove by specimens. I am rather desirous of directing attention particularly to two points. 1st. The condition of the acetabulum. 2nd. The effects of violence during parturition; for I think that the experience of members of this Society is capable of throwing much light on a subject which is yet obscure. *April 19th*, 1887.

---

17. *Congenital dislocation of hip.* (*Card specimen.*)

By JOHN H. MORGAN.

THE specimen is one which was exhibited by the late Mr. Canton to the Westminster Medical Society in March, 1848. The patient from whom it was removed was a female, aged 32, and was affected in both hips. She died fourteen days after giving birth to a living child at full term. Examination of one hip only was permitted. The body and upper limbs were well formed, whilst the lower extremities were somewhat atrophied. The head and neck of the femur were found on the dorsum ilii, the former having passed beneath the small external rotators, whilst a large bursa existed between the capsular ligament, which immediately covered the former like a hood. This ligament preserved its natural connections, but was considerably elongated, thickened, and strongly fortified with supplemental bands at its upper part. The head of the bone was coated by a bluish film of cartilage, which was continued over a superficial depression, marking the site of the pit for the ligamentum teres, which was not present. The portion of the dorsum ilii played upon by the femur was smoother than natural. The acetabulum was triangular in form, the base directed outwards. The height was one inch, the breadth half an inch. The cavity was nearly filled with fat (see Plate XIV).

April 19th, 1887.

---

18. *Congenital (?) displacement of the hip.* (*Card specimen.*)

By D'Arcy Power, M.B.

The pelvis and femur of an adult female. The head of each femur is dislocated upon the dorsum of the ilium. Portions of the capsules of the hip-joints remain, but there is no vestige of either ligamentum teres. There has been absorption of the surface of the head of each femur, diminishing its size and giving it an irregular conical form. On the dorsum of each ilium there is an oblong, roughened patch, produced by friction of the heads of the thigh-bones in walking. The acetabula are represented by small triangular cavities. There is considerable lordosis of the spine.

The dislocations were probably congenital, but the history of the case is unknown.

The specimen is No. 1050 in the museum of St. Bartholomew's Hospital. It was added by the late Mr. Stanley, surgeon to the hospital (see Plate XI). *April 19th*, 1887.

---

19. *Bilateral dislocation of the hip-joints, probably congenital.* (*Card specimen.*)

By Samuel G. Shattock.

D 42 (museum of St. Thomas's Hospital).—The left hip-joint of a girl aged 16. The head of the femur is displaced almost directly upwards on to the dorsum ilii. The capsule of the joint is entire and correspondingly elongated. The articular cavity is nowhere obliterated, and extends downwards to the cotyloid notch. The acetabulum is diminished in depth, and has a somewhat triangular outline.

All the elements of the capsule are strongly marked; the ischio-femoral ligament is especially noticeable. The head of the femur is in considerable part smoothly covered with cartilage.

D 43.—The opposite hip-joint of the same patient, macerated. There is a slightly concave facet, about three quarters of an inch

in diameter above and slightly behind the acetabulum, on which the head of the femur has moved.

The acetabulum is shallow, and its margin triangular; there is a broad cotyloid notch, or rather no proper lower border, whilst the anterior and posterior sides converge superiorly to an angle of 45°. The ischial rami are strongly everted, the distance between the tuberosities being considerably increased.

The head of the femur is flattened, with slight concavity, from its centre downwards and backwards.

The specimens were obtained from the body of a girl aged 16, who died of tubercular disease of the lungs and mesenteric glands. Both the thighs were flexed, and the muscles appeared to have been permanently contracted during life. There was no further history recorded (see Plates XII and XIII). *April 19th*, 1887.

---

20. *Remarks on congenital displacement or so-called dislocation of hip-joint.*

By Wm. Adams.

[With Plates XI to XVIa.]

The recent specimen showing congenital displacement of the right hip-joint from the museum of St. Bartholomew's Hospital, exhibited by Mr. Bowlby and represented in Plate XV, is more especially interesting as having a reliable history connected with it. In a specimen of such rarity it was obviously of importance that the appearances which it presented should be compared with the other specimens in the museums of London, either known, or supposed to be examples of the same affection; and now through the kindness of Mr. Morgan and Mr. Shattock the members of the Society have the opportunity of comparing these appearances with specimens which they have brought from the Charing Cross and St. Thomas's Hospitals (see Plates XII, XIII, and XIV). The appearances may also be compared with another specimen of displacement of both hip-joints, believed, but not known to be of congenital origin, which Mr. Bowlby has brought from the museum of St. Bartholomew's Hospital (see Plate XI).

Through the kindness of Professor Stewart, I have also the opportunity of exhibiting two dried specimens from the museum of the Royal College of Surgeons (see Plates XVI and XVIA; specimens which Professor Stewart agrees with me in the opinion that they belong to the class of congenital displacement now under consideration, so that we have before us six specimens represented in Plates XI to XVIA inclusive. Of these three are examples of double displacement, one single, and two in which it was unknown whether one or both hips were affected, and these I believe are the only specimens in London, with the exception of one doubtful one, and without any history, in the Middlesex Hospital.

Of this series it is remarkable that there is only one other specimen, in addition to Mr. Bowlby's, with any reliable history connected with it, viz. that exhibited by Mr. Morgan from the Charing Cross Hospital (represented in Plate XIV). This specimen was exhibited at the Westminster Medical Society as long since as March, 1848, by the late Mr. Edwin Canton, who removed it from "a case of congenital dislocation of both hip-joints" which he related to the Society.[1] All the other specimens have been placed in the museums as examples of dislocation from disease, but in the recent catalogue of St. Bartholomew's museum, the specimen represented in Plate XI is described as probably of congenital origin.

Individually, these specimens each present some special features, and show the head of the femur to be displaced in different directions on the *dorsum ilii*, *e. g.* directly upwards, or upwards and a little forwards, as in Mr. Bowlby's recent specimen, which Mr. D'Arcy Power took great pains in dissecting (see Plate XV); and upwards and backwards towards the sciatic notch, as in the other specimen of double displacement which Mr. Bowlby has brought from St. Bartholomew's Hospital museum (see Plate XI); and also in the specimen brought by Mr. Shattock from the museum of St. Thomas's Hospital (see Plates XII and XIII); whilst in one of the specimens from the College of Surgeons the head of the femur rested as nearly as possible in the central point of the *dorsum ilii* (see Plate XVI).

Taken collectively, all the specimens now exhibited agree in showing a deficiency of the acetabulum, together with certain alterations in shape of the lower portion of the innominate bone,

[1] This case is published in the 'London Medical Gazette,' New Series, vol. vi, 1848, p. 559; also in the 'Lancet,' vol. i, 1848, p. 341.

such as could only be of congenital origin. There is no trace either of strumous or rheumatic disease having existed in any of the specimens. The three bones entering into the acetabulum are all firmly united, so that the floor of the acetabulum may be said to exist, but there is no trace of a deep circular cup-like depression having existed, and the acetabulum is represented only by a flattened triangular depression, the base of which is formed by the border of the *obturator foramen*, and the apex corresponding to a point a little above that which should represent the centre of the acetabulum, if this cavity were present. The upper half of the prominent border of the acetabulum, which should naturally be formed by the ilium, is entirely absent, so that there is nothing to prevent the head of the femur passing upwards on to the dorsum of the ilium, when the weight of the body is thrown on the limb; also nothing to prevent it descending again under light extension.

With regard to the alterations in shape of the innominate bone, all the specimens exhibited agree in showing that this is narrowed and elongated in its lower portion, especially in the region which should naturally be occupied by the acetabulum. The tuberosity of the ischium is generally everted, and its ramus somewhat twisted.

The head of the femur, in all the specimens, is seen to be smaller than natural, and altered in shape; being generally flattened in its posterior and inferior aspects, but always covered with a thin layer of healthy articular cartilage, as seen in the wet preparations represented in Plates XII, fig. 2, XIII and XV. There is no trace of the round ligament in either of the two wet preparations exhibited, but it does sometimes exist and become greatly elongated. The head of the femur always remains within the capsular ligament, which becomes elongated and increased in thickness and density. In the valuable specimen exhibited by Mr. Shattock from St. Thomas's museum (see Plate XIII), the capsular ligament has been laid open anteriorly, and the head of the femur is exhibited *in situ*.

In the very interesting specimen, exhibited by my colleague Mr. Lockwood, of displacement of the hip-joint in a fœtus, this condition is associated with several other articular displacements and malformations. I have no doubt Mr. Lockwood will show by dissection how closely it resembles, or in what respects it differs from, the specimens now exhibited.

The specimens exhibited this evening will contribute to a more

DESCRIPTION OF PLATE XI.

This Plate and the following (to XVIA) illustrate Mr. W. Adams's paper on Congenital Displacement of Hip. (Page 300.)

Drawing of an adult female pelvis with portions of femora attached, in St. Bartholomew's Hospital Museum, No. 1050, believed to be an example of congenital displacement of both hip-joints, but without history. The specimen has been dried with the ligaments preserved.

a a.—Head of femur on either side, in its displaced position on the dorsum ilii, but still within the capsular ligament *b b*, which has been laid open at the upper and back part. No trace of ligamentum teres. Head of femur on either side, much diminished in size and altered in shape, the left to a much greater extent than the right.

c c.—A slightly roughened and depressed surface of ilium, a little above the upper border of the sciatic notch, where the head rested on either side. Surface of ilium generally smooth, and ridges denoting the attachment of muscles absent.

The acetabula, not shown in drawing, are represented by triangular depressions, with flattened margins; the upper portions of these cavities naturally formed by the projecting lip of the iliac segment of the acetabulum being entirely absent.

The lower portion of the innominate bone on either side, including the region which should naturally be occupied by the acetabulum, is narrowed and elongated, and the sciatic notch is therefore much altered in shape. The tuberosities of the ischia are everted and somewhat twisted.

d.—The sacrum shown to have assumed almost a horizontal position by the tilting of the pelvis and consecutive lordosis.

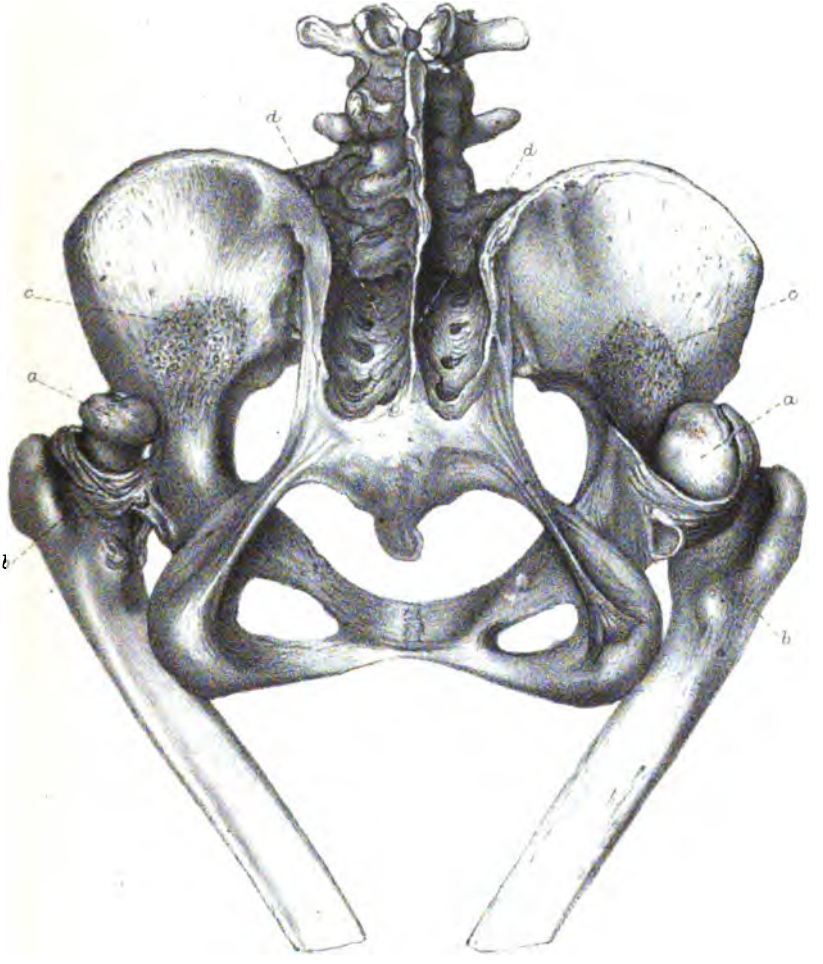

Horace Knight lith ad nat

West, Newman & Co imp

DESCRIPTION OF PLATE XII.

Drawings of two specimens in St. Thomas's Hospital Museum, Nos. 42 and 43, Section D, each consisting of the innominate bone, with upper portion of femur, from the same subject, a girl aged 16. One has been completely macerated, all ligaments removed, and put up dry—Fig. 1. The other partly macerated, with the capsular ligament dissected and remaining intact, put up as a wet preparation—Fig. 2. These specimens are described in the catalogue as examples of "dislocation of the femur from hip disease," but they present all the appearances described as characteristic of congenital displacement, and there is no evidence of disease having existed. The body was brought to the dissecting room, but there is no history of the case.

FIG. 1, No. 42 in catalogue.—The left innominate bone and upper part of femur.

a. Head of femur, very much reduced in size and misshapen, being flattened in its lower and posterior aspect; its surface presents a thin layer of smooth compact osseous tissue; the neck of the femur is shortened and a little twisted.

b. A flattened, circular, medallion-like surface, slightly raised on the dorsum ilii near to the margin of the sciatic notch, at its upper part, upon which the head of the femur had chiefly rested. In this case it is mentioned that both thighs were flexed and contracted at the hip-joint, so that movement had become restricted.

c. An elongated triangular depression, with flattened margins representing the acetabulum. The naturally projecting lip of the iliac segment of the acetabulum is entirely absent, nor is there any projecting margin on either side of the triangular depression.

The lower portion of the innominate bone, including the region which should naturally be occupied by the acetabulum, is narrowed and elongated; consequently the shape of the sciatic notch is much altered. The tuberosity and ascending ramus of the ischium are both everted and twisted. The surface of the ilium is very smooth, and the ridges or curved lines denoting the attachment of muscles absent.

FIG. 2, No. 43 in catalogue.—The right innominate bone and upper part of femur.

a. The head of the femur, displaced on to the dorsum ilii towards the upper margin of the sciatic notch, and closely invested by the capsular ligament *b*, in an extremely thickened and dense condition. The tuberosity of the ischium is everted and twisted. The surface of the ilium very smooth.

The capsular ligament is also shown to be greatly elongated, extending from the upper border of the obturator foramen below, to cover the head of the femur above, in its displaced position on the dorsum ilii.

Fig. 1

Fig. 2

S. G. Shattock del. ad nat.

West, Newman, & Co. Lith.

DESCRIPTION OF PLATE XIII.

Drawing of the same specimen as represented in Plate XII, fig. 2, with the capsular ligament laid open in front, in its entire length. This Mr. Shattock was kind enough to do at my suggestion.

a.—Head of femur in its displaced position on the dorsum ilii, still retained within the capsular ligament *b b*, in a thickened and dense condition. The capsular ligament is also seen to be greatly elongated, extending from the upper border of the obturator foramen below, to cover the head of the femur above, in its displaced position on the dorsum ilii.

The head of the femur is diminished in size and altered in shape, being flattened in its inferior and posterior aspects, but not to the same extent as in the corresponding head of the femur shown in fig. 1, Plate XII. It is everywhere covered with a thin layer of healthy articular cartilage, and there is no trace of the ligamentum teres.

The imperfect cavity of the hip-joint within the capsular ligament, is shown by the edges of the latter being kept open by bristles; its deep surface is irregular, and in its lower half the capsular ligament was depressed, or flattened, so as to diminish the cavity, which probably would not have been capable of receiving the head of the femur had any attempt been made by extension, to have drawn it towards its natural position.

c.—The anterior superior *spinous* process of ilium seen to be below the level of the head of the femur, in consequence of the ascent of the latter.

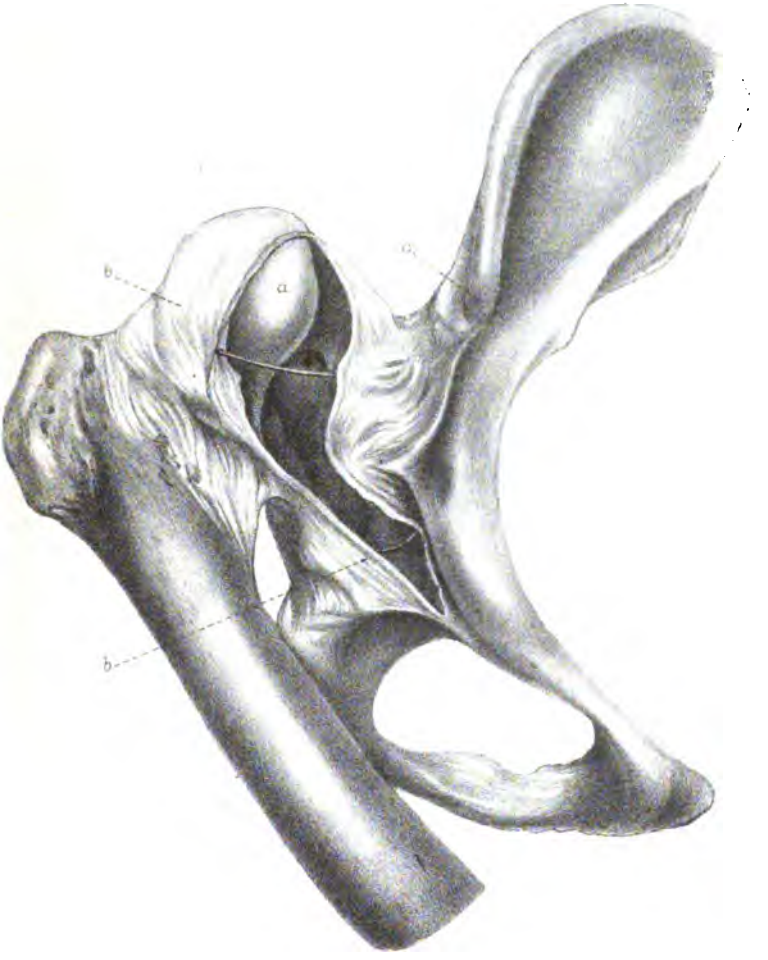

S G Shattock del ad nat.

West, Newman & Co lith.

DESCRIPTION OF PLATE XIV.

Drawings of a portion of the right innominate bone, and upper part of corresponding femur, in the Museum of Charing Cross Hospital, from a case described and published by the late Mr. Edwin Canton, Surgeon to the Hospital as long since as the year 1848, as one of congenital dislocation of both hip-joints. From a female aged 32. Drawn natural size.

Fig. 1.—Upper portion of femur.

a. Head of femur diminished in size, and altered in shape, being somewhat flattened on its inferior and posterior aspects (not seen in drawing), but to a less extent than in some of the other cases. The surface is everywhere smooth, and presents a layer of compact osseous tissue. In the recent state Mr. Canton observes, "The head of the femur was coated by a bluish film of cartilage, which was continued over a superficial impression, marking the site of the absent pit for the ligamentum teres. This latter part was absent."

Fig. 2.—Portion of the innominate bone, especially exhibiting the triangular depression representing the acetabulum. The floor of this depression is very irregular. The base of the triangle is formed by the upper border of the obturator foramen *e*, which has been preserved in this specimen. The naturally projecting lip of the iliac segment of the acetabulum is entirely absent, nor is there any projecting margin on either side of the triangular depression.

a. Portion of ilium sawn through horizontally, about on a level with the anterior inferior spinous process.

b. Portion of the ischium sawn through.

c. Spine of the ischium.

d. Section made through the ramus of pubes into the obturator foramen.

The description of the case from which this specimen was removed is published in the 'Lancet,' vol. i, 1848, p. 341; and is also rather more fully reported in the 'London Medical Gazette,' vol. i, 1848, p. 559; in the 'Report of the Proceedings of the Westminster Medical Society,' March 18th, 1848, when Mr. Canton exhibited the specimen.

Fig. 1

Fig. 2

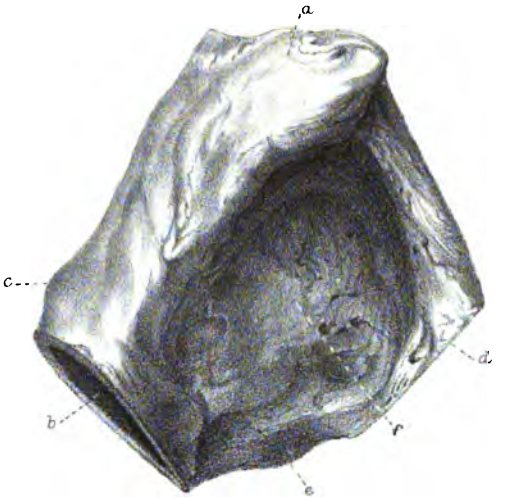

Horace Knight lith. ad nat.

West, Newman & Co. imp.

DESCRIPTION OF PLATE XV.

Drawings of the right innominate bone and upper portion of corresponding femur, in St. Bartholomew's Hospital Museum, No. 1050 A. A recent specimen, with reliable history of congenital displacement of hip-joint, removed from the body of a girl, Catherine Gibbs, aged thirteen, who died in St. Bartholomew's Hospital 7th April, 1884. She was very lame. The limping appeared after the walking period, and gradually increased without pain or suspicion of disease. She was the first child, but the labour was easy and natural.

FIG. 1.—Right innominate bone, imperfect in its lower portion, as during removal the saw was passed through the base of the triangular space representing the acetabulum, and close to the upper margin of the obturator foramen. The absent portion is indicated by the dotted line. The specimen put up as a wet preparation.

a. Smooth circular depression on the dorsum ilii, covered with adherent periosteum, in which head of femur, covered by the capsular ligament, rested during life. The centre of this depression corresponds to a line drawn horizontally from a little above the anterior inferior spinous process, which its margin touches; and the upper border of the depression extends as high as a line drawn horizontally from the anterior superior spinous process of the ilium, so that the head of the femur was displaced in a direction upwards and forwards. This circular depression is immediately above and a little in front of the triangular depression with flattened edges, which represents the acetabulum *B*, and only separated from it by a slight ridge of bone. The iliac segment of the acetabulum, or rather its naturally projecting lip, which extends from a point below the anterior inferior spinous process of the ilium, obliquely backwards to the ischium, is entirely absent, so that there is nothing to prevent the ascent of the head of the femur. The margins of the lower part of the triangular depression are also flattened. The lower portion of this triangular depression *c*, including the margin of the obturator foramen, as well as portions of the ischium and pubic bones, also marked *c*, were not preserved.

The lower portion of the innominate bone, including the region which should naturally be occupied by the acetabulum, is narrowed and elongated; and the shape of the sciatic notch is consequently

much altered. The surface of the ilium is generally smooth, and free from any lines or ridges denoting muscular attachments. No new bone had been thrown out anywhere, nor were there any traces of disease.

FIG. 2.—Upper part of femur from same case—anterior view. Head of femur diminished in size and altered in shape; flattened in lower half. It is everywhere covered with a layer of healthy articular cartilage. The ligamentum teres is completely absent, a little nipple-like elevation existing at its normal seat of attachment, with a pin-hole depression in its centre.

FIG. 3.—Posterior view of head and neck of femur, showing more distinctly the flattening of the head in its posterior and lower aspects, and the nipple-like elevation at the normal seat of attachment of the ligamentum teres, and the small depression in its centre. The neck of the bone is shortened, and slightly twisted backwards upon its axis.

Fig. 3

Fig. 2.

Fig. 1.

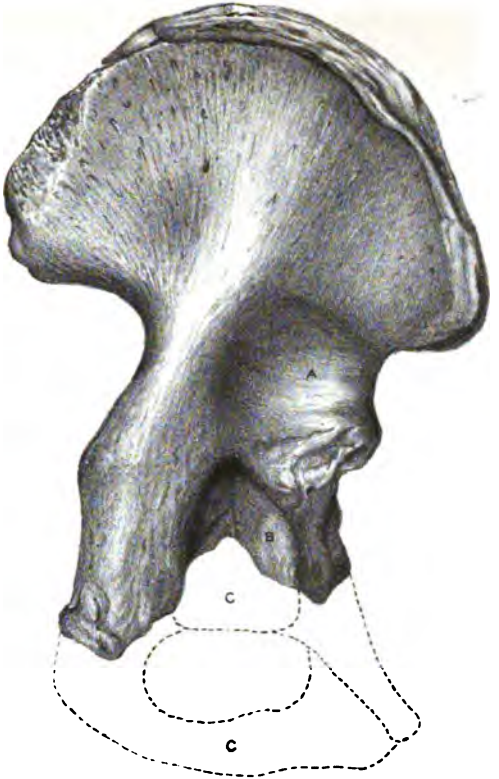

T. Godart del. ad nat.

West, Newman & Co. lith.

DESCRIPTION OF PLATE XVI.

Drawings of left innominate bone, from an adult female, and upper portion of corresponding femur, in Museum of the Royal College of Surgeons, No. 1887, a very old dried specimen, without any history; but it presents all the appearances described as characteristic of congenital displacement of hip-joint, and there is no evidence of disease having existed. The following description is copied from the 'Pathological Catalogue,' vol. ii, part 2, No. 1887, "An os innominatum and a femur. The head of the femur, much reduced in size and altered in its form, was dislocated upon the dorsum of the ilium, on which its flattened inferior and internal surface rested on a shallow concave surface, about an inch above and behind the acetabulum. The two surfaces of bone are simply adapted to each other, neither of them is changed in texture by friction, nor is any new bone formed around them. The axis of the shaft of the femur was directed almost horizontally forwards and inwards; and the lesser trochanter rested on a small, hard, and slightly elevated surface of bone at the posterior border of the acetabulum. The acetabulum is reduced to a small shallow, triangular cavity, the reduction of size being the consequence chiefly of the thickening of its posterior wall. All the bones are thin and light, but they are hard, and there is no appearance of the disease having been in progress at the time of death."[1]

FIG. 1.—*a*. The shallow, concave, circular depression on the dorsum ilii, above described, in which the head of the femur appears to have rested—no doubt still within the elongated capsular ligament. This depression is situated about the centre of the dorsum ilii above the sciatic notch, so that the displacement of the femur in this case was directly upwards and a little backwards.

b. A smooth polished oval surface, on which the small trochanter, also having a smooth polished surface, seems to have played.

c. "The shallow triangular cavity," above described, as representing the acetabulum. The naturally projecting lip of the iliac segment of the acetabulum is entirely absent, nor is there any projecting margin on either side of the triangular depression.

d. The anterior inferior spinous process of the ilium remarkably twisted,

[1] From the museum of Joshua Brookes, Esq.

with a deep smooth depression or groove below it, possibly made by the prolonged action of the displaced psoas and iliacus muscles.

The lower portion of the innominate bone, including the region which should naturally be occupied by the acetabulum, is much narrowed and elongated; consequently the sciatic notch is much altered in shape. The tuberosity and ascending ramus of the ischium are both everted and twisted.

FIG. 2.—Upper portion of corresponding femur.

a. Head of femur, very much reduced in size and altered in form; it is flattened, almost button-shaped, with a smooth undulating surface, covered with a thin layer of compact bone. The upper portion of the head indicated by the dotted line *b* has been broken off by accidents in the course of time. The exposed cancellous tissue is everywhere healthy, though in an atrophied condition. The neck of the bone is shortened and atrophied.

c. The small trochanter, on which is an oval, flattened, and somewhat eburnated surface, which no doubt moved in contact with the polished surface shown in Fig. 1, *b*.

2

1

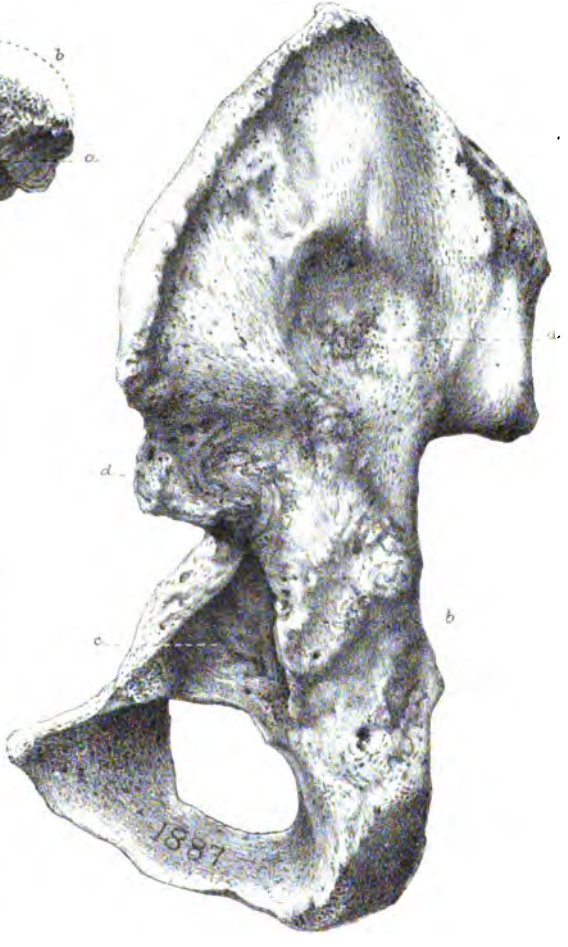

J. Knight ad nat. lith.

West, Newman & Co. imp.

DESCRIPTION OF PLATE XVI A.

Drawing of right innominate bone, from an adult female, and upper portion of the corresponding femur, in the Museum of the Royal College of Surgeons, No. 1888, without any history. It presents all the appearances described as characteristic of congenital displacement of the hip-joint, and there is no evidence of disease having existed, unless the changes in the head and neck of the femur, which are greater than seen in any other specimen, may be so regarded. The only description given in the 'Pathological Catalogue,' vol. ii, part 2, is as follows:—"No. 1888. A similar specimen, with the head of the femur more reduced in size. Presented by Gilbert W. Macmurdo, Esq., 1867."

FIG. 1.—The innominate bone very closely resembles the specimen No. 1887, as to the seat of the depression from the head of the femur on the central portion of the dorsum ilii *a*, above the sciatic notch; the character of the triangular depression *b*, representing the acetabulum, with the complete absence of the projecting lip of the iliac segment of the acetabulum, and also the absence of any projecting margin on either side of the triangular depression; also in the fact of the lower portion of the innominate bone, including the region which should naturally be occupied by the acetabulum, being much narrowed and elongated, producing a great alteration in the shape of the sciatic notch. The anterior inferior spinous process of the ilium is also remarkably twisted, and below it is a deep smooth depression, similar to that seen in the other specimen, No. 1887. The tuberosity and ascending ramus of the ischium are also both everted and twisted.

FIG. 2.—Upper third of femur, said to belong to this specimen, but its characters are so entirely different from all the other specimens of the same class, that a suspicion of its not belonging to the same case naturally arises. In this specimen the head and neck of the femur have both disappeared, and are only represented by a small, flattened, and expanded portion of dense ivory-like bone with overhanging lips—somewhat of a mushroom shape, *a*, at the base of what should be the neck of femur, *i.e.* a little above the small trochanter. These appearances very much resemble those occasionally met with in cases of chronic rheumatic arthritis, in which the atrophic changes predominate; and, so far as I know, they have not been met with or described in cases of congenital displacement of the hip-joint.

1 2

J. Knight ad nat lith.

West, Newman & Co. imp.

accurate knowledge of the pathology of this affection, and dispel several existing errors. It will be seen that it is essentially a consecutive displacement of the femur resulting from a congenital deficiency of the acetabulum, rather than a true dislocation.

Two practical results are the outcome of these views:—1st. That the accoucheur will be freed from all possible blame in producing the displacement or so-called dislocation; and 2ndly. That the practice of dividing the tendons of the glutæi and rotator muscles, with a view to the reduction of a dislocation, must be condemned as an irrational and useless procedure.

April 19*th*, 1887.

---

21. *Two specimens of fœtus, illustrating absence of the margin of the acetabulum, with and without displacement of the head of the femur.*

By C. B. Lockwood.

Mr. Lockwood showed two fœtuses to illustrate absence of the margin of the acetabulum, with and without displacement of the head of the femur, and he also showed a series of histological specimens of the various stages of the development of the human hip-joint. It is proposed, first of all, to describe briefly the fœtuses, and afterwards comment upon that which they demonstrate.

Case 1.—*Absence of margin of acetabulum without displacement.*—Microcephalic fœtus, of male sex, probably born at full time (*vide* Woodcut 10). It was the sixth child, and all the previous ones are alive and healthy. The father and mother are healthy. There is no reason to suspect hereditary disease, such as syphilis. The fœtus was, the midwife says, born "a double-breech presentation," and after birth assumes and keeps a position in which the thighs are flexed upon the abdomen, and legs extended upon the thighs (*vide* Woodcut 10). Attention was drawn to the hips by the great width of the pelvis in the region of the great trochanters. There is very marked talipes varus of both feet, with some degree of pes

cavus. The arms lie by the side with the elbows a little flexed, and the wrist-joints are also flexed, with clubbing of the hands. The right hand is most clubbed, with great distortion of the index and second fingers, the former being hooked over the dorsum of the

WOODCUT 10.

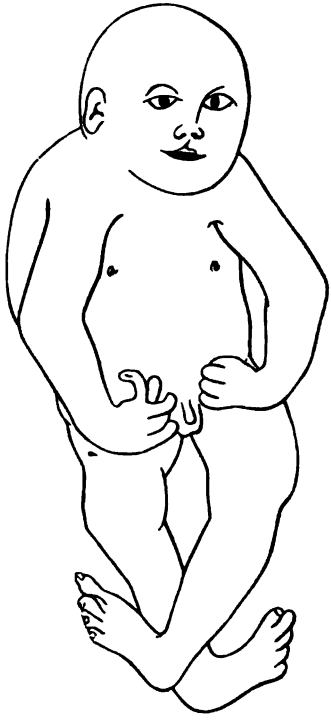

Fœtus (?) microcephalic.—Clubbed hands; clubbed feet; stiff knees; congenital absence of margin of acetabulum; (?) dislocation (slight of hip); harelip.

latter. The neck is short and the head microcephalic; the right cornea is quite opaque, so that the iris is invisible; but the cornea of the left eye permits the iris to be seen, and also the crystalline lens. Upon dissection it was found that the skull was exceedingly thick and bony, and that it contained a small vascular membranous sac, which fills about a third of the cranium. This represents the cerebral hemispheres, and is continuous with a medulla oblongata and spinal cord, but both of these structures are smaller

than in other fœtuses of the same size. The spinal column is perfect as regards its development, but has a lateral flexure, the convexity of which is towards the right, and greatest in the mid-dorsal region. All the thoracic and abdominal viscera seem well developed and healthy. The pelvis is quite well formed, with the exception of the acetabulum (*vide* Woodcut 11). The cartilaginous rim of

WOODCUT 11.

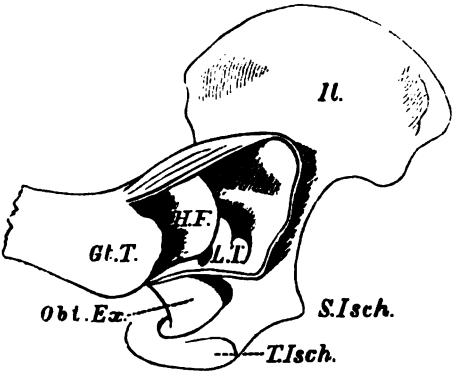

Il. Ilium. *H. F.* Head of femur. *Gt. T.* Great trochanter. *L. T.* Ligamentum teres. *S. Isch.* Spine of ischium. *T. Isch.* Tuberosity of ischium. *Obt. Ex.* Obturator externus muscle.

that socket is entirely absent, but all the other constituents of the joint are present. The capsule is capacious, and the ligamentum teres longer than usual; it is inserted into the lower part of the cotyloid depression and notch, neither of which are in any way peculiar. The head of the femur is normal, and merely lies upon a flat surface, and is not displaced. The intervening articular surfaces of the femur and of the ilium are united by some delicate fibrous bands. The knee-joint is apparently normal, but flexion is prevented by the fibres of the quadriceps extensor, especially of the crureus, which seem too short to permit of flexion of the leg upon the thigh.

CASE 2.—*Absence of margin of acetabulum, with displacement of the head of the femur upon the dorsum of the ilium beneath the anterior superior spine.*—Male fœtus, born probably at full time. The parents were healthy country people, and this was certainly not the first child. Mr. Allen, who delivered the fœtus, says that it was a breech presentation. After birth the legs assumed and kept the following position, viz. the thighs flexed upon the abdo-

men, and the legs over-extended upon the thighs (*vide* Woodcut 12). The feet were not deformed. The arms lay by the side with the

WOODCUT 12.

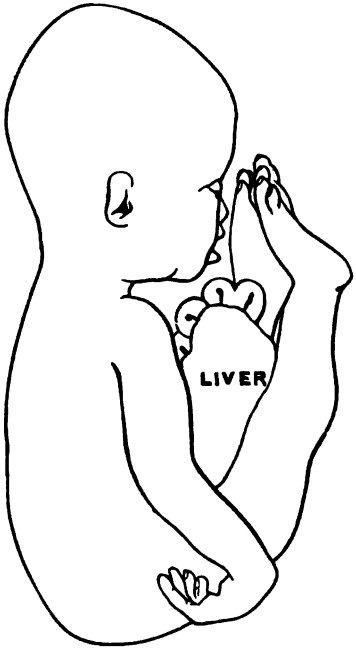

Fœtus.—Ectopium abdominis; clubbed hands; thighs flexed upon abdomen and knees over-extended; dislocation of both hip-joints.

elbows very slightly flexed. The hands were flexed at the wrist-joints, and the right hand had only four fingers; the left hand had also four fingers, and a rudimentary thumb attached by a narrow neck to the index finger. The head was of full size and natural, but the spine has a slight lateral flexion, the bend being greatest in the dorsal region and towards the right. There is an ectopium of the abdomen, with considerable protrusion of viscera, including half the liver, the stomach, great omentum, spleen, small and large intestines, and vermiform appendix. Dissection showed that the brain and spinal cord seemed natural, as did also the thoracic viscera. The shoulder-joint was normal, except that the head of the humerus was rather more anterior and higher up towards the coracoid than seemed natural. The head of the radius was displaced

on to the front surface of the ulna and the carpus towards the flexor aspect of the radius and ulna. These remarks apply to both arms. In the legs the tibiæ were displaced on to the extensor surface of the femur, and their flexion was prevented by the quadriceps extensor. In either hip there was a marked displacement of the head of the femur upon the dorsum of the ilium, and accompanying that condition were changes in all the structures (*vide* Woodcut 13) entering into the formation of the joint. The head of the femur was small and irregular in shape, and lay upon the dorsum of the ilium beneath the anterior

WOODCUT 13.

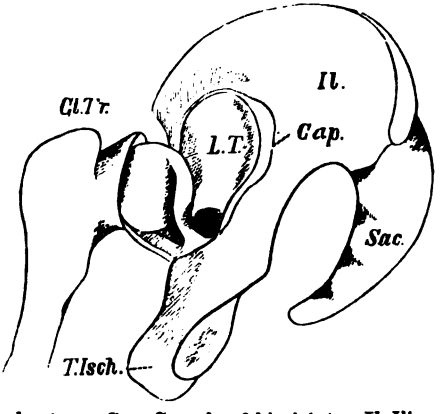

Gl. Tr. Great trochanter. *Cap.* Capsule of hip-joint. *Il.* Ilium. *Sac.* Sacrum. *T. Isch.* Tuberosity of ischium. *L. T.* is placed within the shallow cup within which the head of the femur rested and above the ligamentum teres, which was stretched.

superior spine of the ilium. The cartilaginous margin of the acetabulum was absent, although the cotyloid depression seemed exceedingly deep, but not triangular. The ligamentum teres is exceedingly long, but had the ordinary attachments. The capsular ligament was capacious and attached at the place where the margin of the acetabulum ought to have been; a portion of it pushed upwards, and separated the head of the femur from the dorsum ilii. The muscles which surround the joint participated in the disturbance of position, and the obturator externus and the quadratus femoris were especially dragged upwards by the ascent of the femur. The ilio-psoas lay in a deep groove, which was situated just below and internal to the anterior inferior spine of

the ilium, and the tendon of the psoas wound backwards in an exaggerated way to reach the lesser trochanter.

The fœtuses which have just been described throw light upon the so-called "congenital dislocation of the hip." In the first place they both clearly prove that fœtuses may be born which do not possess a proper margin to the acetabulum; and one of them shows that this condition may be accompanied by an actual displacement of the head of the femur. Two leading features, therefore, call for remark—the absence of the margin of the acetabulum and the displacement. With reference to the first of these it seems hardly necessary to point out that it is not caused in any way by the head of the bone being in a wrong position. In the microcephalic fœtus (Woodcut 10, p. 304) there was no displacement of the head of the femur, nor was it possible that development could have been arrested by any sort of mechanical pressure. The causation lies in another direction, and is only likely to be ascertained by studying the normal development of the human hip-joint. In his excellent article upon "Congenital Dislocations," ('Dictionary of Practical Surgery," Heath, 1886), Mr. Cowell summarises nine causes to which these lesions have been attributed. Without enumerating these it seems right to inquire whether any of them could have been present in the cases under discusssion. One or two of the various propositions may be at once dismissed as not being applicable to the present case. Stromeyer's view that congenital dislocation of the hip may be due "to a distension of the capsular ligament, and a consequent disproportion between the head of the bone and its socket," is not borne out because there was no distension of the capsule of the hip-joint in either case. Morbus coxæ *in utero*, which has also been assigned as a cause, is rendered plausible by the appearance found in the microcephalic fœtus, because, it may be remembered, that in it the head of the femur was attached to the acetabular part of the pelvis by some delicate fibrous bands. But there is reason to believe that this appearance is merely part of a general arrest of development, and may be explained by reference to that process. The development of the joints has been described by Kölliker[1] and many others.[2] However, there are

[1] Kölliker, 'Entwicklungsgeschichte der Menschen und der Höheren Thiere,' p. 493.

[2] *E.g.*, Miss Johnson, 'Quart. Journ. Micros. Sci.,' 1883, p. 399, who gives a

many differences of opinion, so that it is desirable to ascertain what the process is in human embryos. At the beginning, about the twenty-second or twenty-third day, the hind limb of the human embryo is merely a bud of mesoblast; and later, in the midst of this tissue, groups of cells chondrify and form the rudiments of the femur and tibia, and afterwards of the pelvis. In the situations where the joints are formed chondrification of the mesoblast does not occur, but a line of deeply staining mesoblast remains. The hip-joint originates in this manner, and is not at first a pelvic socket in which the head of the femur lies, but the acetabulum is formed by a growth of the pelvic cartilage round the head of the femur. By the third month of intra-uterine life this process is far advanced, and the acetabulum is a deep cup. Whilst this has been taking place the mesoblast around the joint has become converted into capsule and ligaments, and that which has persisted between the head of the femur and the acetabulum forms the ligamentum teres and Haversian gland, and some of it separates into two layers, which invest the contiguous cartilaginous surfaces. This change is synchronous with the development of the various limb muscles. We are now in a position to apply these facts to the abnormal cases which have not been described, and it is clear that in both of them the pelvic cartilage has failed to grow round the head of the femur. And, moreover, I would attribute the fibrous adhesions which were found in the cases of the microcephalic fœtus not to inflammation, but to an incomplete differentiation of the intra-articular mesoblast. Whether this tissue was strong enough to prevent a displacement of the head of the femur, such as there was in the second fœtus, is hard to say, but the possibility ought to be borne in mind. Continuing Mr. Cowell's list we find that congenital dislocation of the hip has been attributed to violence exercised by the accoucheur, but this factor need not to be entertained to explain the displacement in the second of the cases (the fœtus with ectopium of the abdomen), for Mr. Allen says the birth was easy, and that no violence was used to deliver the child. Mr. Wm. Adams has shown that to assume violence is always a very doubtful explanation. Mr. Howard Marsh[1] has, so

number of references; also Schulin, 'Archiv für Anat. und Phys.,' 1879, p. 240; and Schuster, 'Mittheilungen aus dem Embryologischen Institute der k. k. Universität in Wien,' 1880, p. 199.

[1] Howard Marsh, 'Diseases of Joints,' 1886, p. 252.

far as I can ascertain, published the best evidence in proof of this contention; but even his case is open to doubt, for the accoucheur, whilst attributing a dislocation of the hip to violence—indeed, he said he felt the head of the bone leave its socket—does not say that the head of the bone was found to be dislocated immediately after birth. To the cause of congenital dislocation which has just been mentioned, namely, violence, Cruveilhier adds another, and believes that the position of the fœtus *in utero* has something to do with the lesion. Now it is a very significant fact that both of these fœtus were born in a particular way—breech presentations. More than this the peculiar positions of their legs seems to have been intra-uterine. Messrs. Matthews Duncan and Hurry in their learned paper[1] agree with Lefour upon this point, and they have collected examples of the malposition which have been described by Cruveilhier, Lefour, and Shattock. In these cases the thighs had a notable disposition to flex again upon the abdomen after they had been straightened out, and it was difficult, or impossible, to flex the over-extended legs upon the thighs. Mr. Shattock, in his case, attributed this inability to abnormal shortness of certain ligaments, but, as I have already said, the quadriceps extensor seemed to be in fault in the case of the microcephalic fœtus. Assuming, therefore, that both of these fœtuses whilst in the uterus had the thighs flexed upon the abdomen and the legs over-extended upon the thighs, we have to consider what could be the cause of that malposition, and whether the same cause could also produce dislocation of the hip. Without further preface the positions of the fœtal legs may be assigned to an insufficient capacity of the uterus. Whether this was owing to an actual smallness of the organ itself, or whether an inadequate quantity of liquor amnii allowed the uterine walls to squeeze the contents, would, with our present data, be difficult to determine. But, assuming that this line of argument is correct, it remains to be asked if the pressure of the uterine walls could displace the head of the femur. Now, in the case of the microcephalic fœtus, although the margin of the acetabulum was absent, yet the head of the femur rested against the cotyloid depression. So that, assuming that there had been uterine pressure, although the conditions were favorable, no displacement had occurred. But in the second fœtus, that with ectopium, it is possible that intra-uterine

[1] 'Obstetrical Transactions,' vol. xxvi, p. 208.

pressure may have caused the displacement of the head of the femur. That there may have been great pressure in this case is rendered likely by the extrusion of the abdominal contents, and by the subluxations of the shoulder, elbow, and wrists. Although it would not be impossible to show how pressure could produce these various lesions in the arm, yet it is harder to see how the head of the femur could be forced beneath the anterior superior spine of the ilium. Moreover, the absence of the margin of the acetabulum is a factor which requires to be taken into account. It seems more rational to suppose that the absence of the margin of the acetabulum was the essential factor, and that it predisposed to the displacement of the head of the femur; and, further, that the latter abnormality was due either to intra-uterine pressure, or, perhaps, to muscular contraction. Since it seems safe to take for granted that neither of these fœtuses had ever had a proper margin to the acetabulum, a reason for that deficiency has yet to be discovered. I think it may plausibly be argued that a certain degree of motion is essential for the proper formation of a joint. A great many reasons might be adduced to support this contention, and those which arise from a study of the formation of false joints are not the least weighty. Evidently, in the cases under consideration, owing to the position of the legs, a proper degree of movement could not have been possible during intra-uterine life.

The impression left upon the mind by an examination of these specimens tends, therefore, to the conclusion that, in these cases of congenital displacement of the head of the femur, an absence of the margin of the acetabulum is a prime feature, and that it predisposes to displacement of the head of the femur either before or after birth.

Whatever may be the cause of the arrest of development, whether lack of proper movement or ill-development due to central nerve lesions, as may have been the case in the microcephalic fœtus, there is evidence to show that the abnormality is hereditary, and, although, perhaps, commonest in females, affects also the other sex.

April 19th, 1887.

22. *Destructive inflammation of knee-joint without suppuration.*

By Jonathan Hutchinson, F.R.S.

The peculiar feature in this case is the very extensive destruction of the joint and erosion of bone without suppuration and without any history of an acute attack. The patient, a married lady of fair complexion and rather delicate aspect, was engaged in the active superintendence of a large school until within two months of the amputation of her limb. She had been lame in her left knee for some years, but had never been confined to bed, and had never had any acute attack of inflammation. When I first saw her she had been confined to bed for about six weeks, and had recently suffered much pain. The tibia was dislocated backwards, and there being little or no swelling, the condyles of the femur projected strongly forwards under the tense skin. There was considerable œdema of the deep parts in almost the whole of the thigh, so that I suspected chronic periostitis of the femur, but the knee itself and the leg were not swollen. As it was evident from the dislocation that the limb could never again be useful, and from the recent pain and failure of health, that the patient would probably never again leave her bed, I advised immediate amputation. I was not without some misgivings as what might be found to be the state of the femur. These fears proved to be groundless. The shaft of the femur was healthy, and the stump healed entirely by the first intention. On examining the joint after removal, it was found to contain no pus or other secretion, nor anything which looked liked the remains of pus. What remained of the synovial membrane was not thickened, but the cartilages and ligaments were everywhere most extensively destroyed. The tibia was dislocated backwards with the usual rotation outwards, and the inner part of the inner condyle showed great absorption from the pressure upon the tibia. In the inner part of the head of the tibia was an angular erosion nearly an inch in depth into which the condyle fitted. The patella was fixed between the condyles by firm fibrous anchylosis. Although the cartilages were everywhere removed, there was no material erosion of bone excepting at the parts named, and not the slightest trace anywhere of the outgrowths

which characterise rheumatic arthritis. The patient had no rheumatic disease of the joints, nor was she the subject of ataxy.

Perhaps the affection may be considered as a form of rarefying ostitis of the joint ends, and it is particularly to be noted that both femur and tibia, when they touch, are extensively eroded. This marked destruction of bone and cartilage, without the formation of the smallest sequestrum or the occurrence of suppuration, is especially noteworthy, for the reason that "the knee is the joint most frequently attacked with the suppurative form of arthritis deformans." (Holmes' 'System of Surgery,' 1883, vol. ii, p. 386.) Our 'Transactions' do not afford records of similar cases, so far as I have been able to find, but in Mr. C. Hawkins's 'Contributions to Pathology and Surgery,' vol. ii, p. 422, some cases of "a rare form of disease of the knee joint" are described, which seem to be of the same nature. In these there was destruction of cartilage and bone without suppuration in the joint and without other signs of chronic rheumatic arthritis, in fact, the course of the disease was decidedly acute. The patients were under thirty years of age; there was some evidence of rheumatism in other joints in two out of the four cases. *May 3rd*, 1887.

---

23. *Senile arthritis.*

By Thomas Smith.

A patient, aged 67, a widow, who had lived some years in India but enjoyed good health, in the early part of last November complained of some pain in both knees and both ankles; in ten days' time this had passed away, and with the exception of some slight discomfort about the right knee she considered herself well. In the second week in November she was seized with sudden and severe pain in the right knee, followed by great swelling and tenderness, and accompanied by considerable constitutional disturbance. In a few days' time ecchymosis appeared in the neighbourhood of the joint just below the patella and spread over the knee and downwards towards the ankle. Under treatment the effusion diminished to some extent but the joint remained much enlarged, very painful,

and very tender to touch, while the temperature ranged from 100° to 103°, and the pulse from 120 to 150.

This patient would not submit to the restraint of a splint or any appliance to secure rest to the joint. She also during her whole illness rose from her bed every day for urination and defecation, and, as a rule, she sat up in an easy-chair with her foot on a leg-rest for one or two hours a day. The pain was very severe but not constant, and she frequently requested that her limb should be removed.

The joint mischief made rapid progress, and early in March the ligaments began to give way, so that when turning in bed one could hear the bones grating over one another. At this time I had the advantage of having Erichsen's opinion, who agreed on the advisability of amputation, and on March the 13th the limb was removed in the middle third of the thigh. The patient made a good recovery; but it is worth recording, that from the day of the operation she continued her habit of getting out of bed every time she passed water and whenever her bowels acted.

Examination of the knee-joint.—The joint cavity was largely distended with blood-stained fluid. The synovial membrane was very vascular, much thickened, and the fringes were greatly hypertrophied, so that there were leaf-like processes and villous projections growing from the membrane. The cartilage had been completely removed by absorption wherever subject to pressure, and the bone was exposed at these parts; elsewhere the cartilage was reduced to a very thin translucent layer. There was no ulceration or roughening of either cartilage or bone, nor was there any suppuration. The crucial ligaments were softened, frayed out, and lengthened, but they had not completely given way.

Mr. D'Arcy Power was good enough to examine the synovial membrane microscopically, and he reports that it contained abundance of miliary tubercles, but that he failed to find any tubercle bacilli.

In this connection it may be worth recording that the patient's mother died of pulmonary consumption at the age of 70; her father died of bronchitis aged 59, her two brothers of consumption between the ages of 28 and 30, and that a maternal uncle died of phthisis, and it may be noted that once in her convalescence the present patient suffered from slight hæmoptysis.

John S—, aged 70, was admitted into St. Bartholomew's

Hospital, February 28th, under my care. He was a railway plate-layer, and in addition to many minor accidents, about fifteen months since, he was knocked down and for some hours was unconscious, was in bed for one week, and, so far as he knew, did not injure his wrist. A month after this his wrist began to give him trouble, and it steadily got worse up to the time of his admission.

At this time the whole hand and wrist were enormously swollen; the hand was fixed in a position of extreme flexion. The skin was tense and red. There were several open sinuses about the joint, there was an open wound through which the necrosed end of the ulna projected. Dead bone was to be felt through all the openings.

There was a profuse discharge of pus; the pain was not so severe as might have been expected. The urine contained one fourth of albumen, and its specific gravity was 1011; temperature normal. After a few days' rest in bed the forearm was amputated in the lower third. The wound did well, and he suffered no constitutional disturbance, but was greatly relieved by the operation. He died suddenly three weeks after the operation apparently of heart disease, of which there had been auscultatory evidence during his lifetime. No *post-mortem* examination was permitted.

The synovial membrane of the wrist and of the carpal joints was in a condition of pulpy degeneration, the ligaments had given way, and the carpal bones and the joint ends of the radius and ulna were found to be necrosed and separated from their ligamentous attachments.

I have ventured to bring these two cases before the Society as examples of a form of joint affection which is occasionally met with in old people, so far as my experience guides me. Its most frequent seat is in the wrist and neighbouring carpal joints; commencing in the synovial membrane, it quickly leads to complete destruction of the joint by softening of the ligaments and disconnection of the bones. I have never seen the affection in any but the poorer classes until I met with the case I have detailed above, where the knee-joint was attacked.

So far as I am aware, the disease has not hitherto been regarded as a tuberculous affection, but on Mr. Power's authority we may conclude that, at all events in the cases brought forward to-night, the disease was of that nature.

Though one could multiply the instances of the disease from our hospital records, yet I am afraid they would furnish no evidence on this point, as it is only in comparatively recent times that methodical microscopic examination has been made of the synovial membrane in cases of joint disease. *May 3rd*, 1887.

---

24. *Microscopic sections from six cases of tubercular arthritis. (Card specimen.)*

By Samuel G. Shattock.

Case 1.—Lily K—, aged 7, admitted under Mr. Croft, August 17th, discharged December 24th, 1886. Disease of the right hip-joint; incision and drainage on September 11th; excision on October 12th.

The patient fell from a chair twelve months previously, the accident being followed by limping.

There was a history of enlarged glands and abscesses in the neck until seven months ago. An uncle, aunt, and grandmother died of phthisis. The mother is "delicate."

The thickened synovial membrane excised contains numerous tubercles; in some of these, which are in other respects typical, the centre is formed, not by a giant-cell, recognisable as such, but by a close, somewhat ill-defined mass of small round-cells.

A few giant-cells occur apart from any definite tubercular formation; some lie immediately beyond the periphery of well-defined tubercles.

The articular cartilage of the head of the femur is wanting; the bone shows osteitis, but no tubercles are present in it; they exist in the thickened synovial membrane which overlaps its side.

Case 2.—Middleton E—, aged 13. Caries of calcaneum. Admitted into St. Thomas's Home under the care of Mr. Sydney Jones. Amputation was performed on November 1st, 1886; discharged December 2nd, 1886. Two years previously the foot had been struck with a cricket ball; the patient had also fallen from a tree. How far these accidents led to the disease is uncertain.

Excision of the ankle had been performed by Mr. Jones on August 6th, 1886, but was not followed by cure,

Dr. Edmunds writes: "Father, mother, brothers, and sisters alive and well, but I think there was some phthisis in the father's family."

There are typical tubercles in the medulla of the bone; in some of these there are three or even four giant-cells; the arrangement of the nuclei in some of the cells is highly irregular, in formless clusters and strings.

CASE 3.—L—, aged 12. Disease of hip. Admitted under Mr. Croft, November 24th, 1886; excision of joint January 20th, 1887. Four months before admission the boy began to limp, and the usual signs of acute hip disease became evident; no history of injury. One uncle died of phthisis; one brother suffered from "lumps" in the neck; one brother limps, reason not known; other brothers and sisters are well, as are also the father and mother.

There are large close-set and highly typical tubercles in the greatly thickened synovial membrane overlapping the end of the femur.

The articular cartilage has been destroyed; there are no tubercles in the bone, though there are the signs of osteitis.

CASE 4.—C—, aged 17. Caries of tarsus. Admitted into St. Thomas's Home under the care of Dr. Edmunds. The foot had been diseased for two years before; doubtful history of injury; no open wound, but examination of the parts disclosed the presence of abscess. Amputation on January 20th, 1887. The patient's father died of consumption.

There are tubercles in the granulation tissue which has replaced the surface of the carious bone; as also in the cancellous spaces of the bone beneath the carious surface.

CASE 5.—George S—, aged 33. Admitted under Mr. Croft; discharged "well." The right knee was amputated for disease on January 29th, 1887. The disease began seven months before admission, with severe pain in the joint; no injury was remembered.

Two years ago the patient spat up blood, and had a similar attack five months ago. Mother died of congestion of the lungs; father was killed; nothing known of uncles or of aunts. The

patient presented the physical signs of phthisis, these being especially marked in the right lung.

There are tubercles in the thickened synovial membrane. The giant-cells within the tubercles show little or no branching.

CASE 6.—Evelyn Y—, aged 10. Caries of the tarsus. Syme's amputation was performed by Mr. Croft on February 7th, 1887; patient discharged March 3rd.

In February, 1884, the posterior part of the calcaneum had been removed for caries. Two brothers and two sisters were subject to "abscesses about the face." The mother, and all the uncles and aunts died young; the mother when thirty-five years of age.

There are tubercles in the thickened synovial membrane, as well as in the granulation-tissue which has replaced the surface of the carious bone; they are present also in the inflamed bone subjacent to the granulating surface.

Some of the tubercles in the synovial membrane have characters like those mentioned in the first case.

I have ventured to exhibit the foregoing specimens, since although it is now six years ago that the subject of tubercular arthritis was brought under the notice of the Society by Mr. Croft, no specimens have since then been shown at any of the Society's meetings.

Mr. Croft exhibited specimens from six cases, five of which were tubercular; and in an addendum he states that the parts from twelve other cases of excision of the hip-joint had been examined and found to be tubercular in the same degree.

The six specimens shown by myself were from consecutive cases of operation performed at St. Thomas's Hospital during the past six months.

Mr. Makins tells me that he has during the last few years examined over a hundred cases of tubercular arthritis, and found a similar lesion in all; Mr. Bowlby has examined over twenty, whilst Mr. Macnamara has long insisted on the frequency of articular tubercle as a result of his own histological investigations.

These facts are sufficient to give a final answer to Mr. Croft's questions, "Are English surgeons wrong, and German surgeons right?" "Is tubercular disease of the joints more common than we have supposed?" The difficulty of demonstrating bacilli in

tubercular arthritis is admitted on all hands. A careful but ineffectual search was made by Zeill's method in three of the six cases under notice.

This, however, does not affect the classification of the disease; for much the same difficulty obtains in demonstrating bacilli in tubercular disease of the lung on other organs.

The pathological anatomy of the synovial membrane or bone is, as Mr. Croft puts it, "identical with that seen in tuberculosis in whatever organ it may be examined." Whatever term is applied in one case must be extended also to the other.

May 3rd, 1887.

---

25. *Drawings of multiple joint affection in a case of locomotor ataxy.*

By A. H. Robinson, M.D.

[With Plate XVII.]

The patient from whom these drawings were taken is an inmate of the Mile End Infirmary. He is 48 years of age, and was by occupation a seaman. He states that he had acute rheumatism at Malta in 1856, which passed away without leaving any apparent damage. Two years later he had three venereal sores under the prepuce, from which he suffered for nine months, but no secondary manifestations followed so far as he knows. From that time up to 1877 he appears to have enjoyed good health, being almost constantly at sea. In that year (1877), however, his left leg began suddenly to swell between the instep and the knee, the joint being unaffected. He attended Guy's Hospital and the swelling of the leg subsided, but a similar condition then began in the left arm. He says these swellings were painless, yet he lost the use of his limbs through them. Two months later he entered the London Hospital, and at that time the joints appear to have been swollen, and they were freely blistered. With this treatment the swelling again subsided, but some deformity was noticed; indeed he was unable to follow his employment from this time. With regard to other symptoms, he has had what he calls "bilious attacks" from

time to time for some four or five years. For five or six years he has been unable to tell the position of his feet without looking at them, and he has been ataxic in his forearms for some three years.

Present condition.—Patient is unable to rise in bed without assistance. There is ptosis of left upper eyelid with left external strabismus. The pupils are of medium size, and do not react either to light or accommodation.

Upper limbs: There is marked impairment of sensation and considerable loss of power of coordination. The right shoulder is enlarged, and the head of the humerus can be dislocated at will. There is also an osteophytic outgrowth apparently connected with the acromion. There is grating on movement of the humerus. The lower end of the humerus presents two large osteophytes occupying about the position of the condyles of that bone. The olecranon lies between these and projects somewhat backwards. The elbow-joint is freely movable, in fact so much so as to produce a flail-like condition of the limb. Over the back of the carpus are other osseous outgrowths from the carpal bones, and there is marked grating in the wrist-joint.

Lower limbs: There is absence of sensation in the legs when touched lightly, but the prick of a pin or the application of heat is felt after some delay. Incoordination is very marked in the lower limbs, but there is considerable power remaining. The knee-jerks are quite gone. There is no ankle-clonus and the plantar reflex cannot be obtained. The left knee especially is enlarged, due entirely to increase in the dimensions of the bones, more particularly of the head of the tibia, which is "lipped" very distinctly. Here, again, there is preternatural mobility and grating on movement of the joint; but no pain is occasioned by such movement. There is no alteration in the feet, but the knuckle-joints and finger-joints are much enlarged.

Patient is habitually constipated, bowels acting only after aperients. He has "gastric crises" about every three months as a rule. He has some difficulty in micturition.

It is noticed that when a penholder is drawn quickly over the skin of the trunk red lines quickly appear, which later develop into distinct wheals. *March* 15*th*, 1887.

DESCRIPTION OF PLATE XVII.

To illustrate Dr. A. H. Robinson's case of Locomotor Ataxia, with Affection of Joints. (Page 319.)

FIG. 1.—Shows deformity of elbow, produced by osteophytes attached to end of humerus, the bones of forearm being displaced backwards. It also shows deformity of wrist-joint, produced by similar outgrowths on back of carpus.

FIG. 2.—Shows luxation of head of humerus upon dorsum of scapula, and further deformity produced by an osteophyte attached to acromion.

FIG. 3.—Shows distortion of finger-joints, several of terminal phalanges admitting of dislocation easily.

Fig. 2.

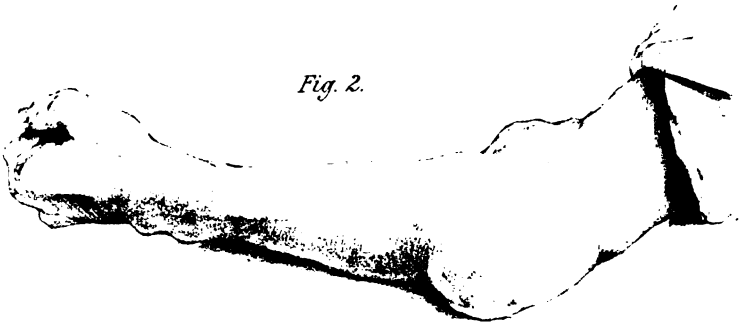

Fig. 1.

Fig. 3.

F Huth, Lith^r Edin^r

VII. DISEASES, ETC., OF ORGANS OF SPECIAL SENSE.

1. *A rhinolith.* (*Card specimen.*)

By D'Arcy Power, M.B.

An irregularly square rhinolith measuring nearly an inch across. It appears to have been formed round a piece of rag which has served as a nucleus. It weighs 33 gr., and chemical examination shows that it consists of a mixture of calcium, carbonate and phosphate. The concretion was removed from the inferior nasal meatus of a woman aged 24, who gave an indistinct history of having had a foreign body in her nose for upwards of twenty years.

The specimen is preserved in the St. Bartholomew's Hospital Museum, Series lii, No. 254 (*a*). *March 3rd*, 1887.

---

2. *Microphthalmos on the left side in a newborn child.* (*Card specimen.*)

By Samuel G. Shattock.

[With Plate XXV, fig. 1.]

There is a very small palpebral fissure on the affected side, but the lids and lashes are carefully represented in miniature, and there is a conjunctival membrane reflected on to the surface of a diminutive globe. The ocular muscles are recognisable in the fat of the orbit, the cavity of which is considerably smaller than that of the opposite side. The globe is represented only by a

tough sclerotic, at least none of the normal structures were seen within the sclerotic at the time the section was made.

In the thirty-fourth volume of the Society's 'Transactions,' Mr. Godlee reported a living case of what he termed one-sided anophthalmos; but it must be confessed that the present specimen shows the uncertainty of such a diagnosis. He writes, "The palpebral fissure leads into a deep slit lined by rather red conjunctiva, and showing at the bottom a little whiteness, which it has been suggested may correspond to some sclerotic tissue; there is no projection as of a dwarfed globe, however." Such a description would apply equally well in the present case.

The condition is rare, and the opportunities of its examination are still more so. In the present instance it is most probable that the arrest of growth has resulted from intra-uterine disease of the globe.

In addition to this "malformation," there is a single harelip, on the right side, and the left nostril is almost closed by a diaphragm; the posterior nares are normal. *December 7th*, 1886.

VIII. MORBID GROWTHS AND TUMOURS.

1. *Multiple, painful, fatty tumours of arms.* (*Card specimen.*)

By Frederic S. Eve.

Seven rounded or oval lipomata varying from three eighths to one inch in their long diameters.

They were removed from a woman, aged about thirty, under my care in the London Hospital. She had noticed them for about two years. Five of the tumours were on the right upper extremity, two being situated on the forearm and three on the upper arm. The two on the left upper extremity were respectively on the fore- and upper arms. All the tumours were on the dorsal surfaces, except two which were on the inner side of the right arm above the internal condyle.

She stated that the pain in this arm was so great as to prevent her from working, and complained of tenderness on pressure over the tumours with pain extending down the arms to the hands. The pain could not be localised to any particular nerves; but there were no hysterical symptoms.

The tumours were removed at one sitting. No nerves were noticed in connection with them.

The existence of neuralgic symptoms with subcutaneous lipomata, although not unknown, is, I believe, rare.

During the past year I have seen two other cases of multiple lipomata of the arms, both in middle-aged women.

January 4th, 1887.

2. *Subpleural lipoma of diaphragm.*

By Francis W. Clark.

The specimen was obtained from a woman aged 65, who was admitted into the Croydon Infirmary under my care in October of last year, and who succumbed to the effects of an intracapsular fracture of the neck of the femur.

At the autopsy, a rounded lobulated tumour, somewhat larger than a plover's egg, was found projecting into the right pleural cavity, resembling at first sight a diaphragmatic omental hernia. There were no adhesions of the lung to the parietes or to the tumour, which was freely mobile. On section the tumour proved to be a lipoma, the base of which was spread out between the muscle-fibres of the diaphragm, like the mycelium of a mushroom.

With reference to this specimen I would venture to draw your attention to the fact that there is normally an outgrowth of fat from the diaphragm, situate on the right side anteriorly, close to the reflection of the pericardial pleura on to the diaphragm. This may, in cases of general obesity, become occasionally so increased in amount as almost to assume the appearance of a fatty tumour, but does not of course constitute a true tumour, since it is but part of a general physiological process. *May 17th*, 1887.

---

3. *Soft fibroma of palm of hand.*

By Sydney Jones.

C. G—, aged 25, female, was admitted into St. Thomas's Hospital under Mr. Sydney Jones, on February 11th, 1886. Her family and previous personal history was good.

Eleven years before admission she first noticed swelling on the palmar aspect of the head of the metacarpal bone of the index finger, supposed to be due to sprain fourteen days before. Four months later was treated at Guy's Hospital with iodine. Four

years later a seton was used at King's College Hospital, and treatment continued for two months. It is said that the swelling disappeared and she was well for six months. Then swelling again appeared and increased gradually—specially so during the last three years. On admission there was a large irregular swelling with sensation of fluctuation in the palm. The swelling extended from above the anterior annular ligament to the base of the second phalanx of the index finger; on the inner side extended to one fourth of an inch at the inner border of the palm, and outwards as far as the base of the first phalanx and the middle of the metacarpal bone of the thumb. The superficial veins were much distended. The index finger could be moved, but was bent backwards at the metacarpo-phalangeal joint.

Operation on February 17th. Esmarch's bandage and antiseptic spray used. An incision was made in the whole length of the tumour and the annular ligament was divided. The dissection was easy, parts were very vascular, and there was considerable oozing afterwards.

After well washing out with iced carbolic lotion, a drainage-tube was inserted and the edges were brought together by silk and catgut sutures. The wound was redressed in the morning on account of oozing. The temperature on the 18th, at night, was 102·6°; on the 19th, 102°; for the next night or two, 100·6°. It soon dropped to normal. The patient went out on the 20th of March. She has been seen several times since leaving the hospital; the movements of the fingers are perfect. The sensation of the thumb and finger is normal; there is some numbness of the middle finger.

The following account is given by Mr. Shattock of the naked-eye and microscopical appearances:

"The parts removed consist of an irregularly lobulated mass eight inches and a half in length. The growth is composed of several spheroidal tumours of various sizes held loosely together by connective tissue. The highest portion is a cylindrical process about two inches long and half an inch in diameter; succeeding this is a globular mass, the largest part of the growth somewhat more than two inches in diameter, and connected with it is a series of smaller tumours looking much like a chain of enlarged lymphatic glands.

"The fasciculi of a large nerve are spread around the upper pro-

cess of the growth, and are traceable over the next succeeding mass, where some have been divided in disengaging it from the surrounding parts; other fasciculi are traceable over the lower processes of the growth, where they have in like manner suffered division. On section, the largest mass presents several foci of softening.

"Histologically there is not anything to say except that it is a soft fibroma.

"The growth was distinctly encapsuled, enclosed within the dilated tendon sheath, and attached to the tendons by loose connective tissue, very elastic while enclosed in capsule, gaping considerably on section, the capsule receding from margin."

A woodcut is shown of the hand before removal of the tumour. The tumour is preserved in St. Thomas's Hospital Museum.

WOODCUT 14.

Mr. Makins has kindly given me references to descriptions of more or less similar tumours in 'Société de Chirurgie Bulletins et Mémoires,' t. iii, 1877, p. 664 and p. 704; also in 'Thèse pour le Doctorat en Médecine par O. De Pezzer,' 1880, No. 325.

November 2nd, 1886.

---

4. *Multiple angiomata of leg with multiple enchondromata and a sarcoma.*

By FREDERIC S. EVE.

I HAVE described the specimen as follows in the Appendix to the Pathological Catalogue of the Royal College of Surgeons' Museum, No. 410A:

"A leg and foot deformed and affected with multiple cavernous angiomata and other tumours. The bones of the leg are bent

backwards in an even curve, extending throughout their whole length. The upper end of the tibia is enlarged, and two osseous outgrowths project from its inner surface. A similar small exostosis is situated on the inner surface of its lower end. Occupying the outer and posterior surfaces of the ankle is a large rounded swelling, which in the recent state was semi-fluctuating. This on section was found to be a white, soft, in parts diffluent sarcoma, of cartilaginous aspect; it had destroyed the ankle-joint and infiltrated the bones entering into its formation. The foot is inclined inwards. The second, third, and fourth toes are deformed by the growth of osseous tumours around their phalanges; that around the first phalanx of the second toe being the largest. These tumours are smooth, of bony hardness, and are probably calcified enchondromata. The cancellous tissue of the extremities of the femur and tibia, exposed by a section through the knee-joint, is very light, with delicate osseous trabeculæ, and contains much fat. Scattered in some parts of it are small brownish granular masses, apparently of the same nature as the vascular growths to be presently described. The shaft of the femur is nearly traversed by an irregular band of cartilage extending inwards from the anterior surface; it, perhaps, occupies the site of an old fracture. But two other small islands of cartilage may be observed higher up the shaft, and there is one in the head of the tibia. Distributed over the limb, but chiefly along some parts of the origin and course of the saphena veins, are numerous rounded nævoid growths of various sizes and of a reddish-brown hue. Most of them are subcutaneous. There is a large group of them surrounding the internal saphena vein, just below the knee; and a few others project beneath the skin of the calf in the course of the external saphena vein. Several are scattered along the outer margin of the foot, where they lie in connection with the small veins entering into the formation of the external saphena. Many others are distributed on the inner side of the foot, great toe, and in the concavity of the sole. They project beneath the skin as rounded, softish swellings, having much the appearance of the common subcutaneous fibrous tumour. A few nævoid growths are situated beneath the deep fascia on the dorsum of the foot, and a large one is adherent to the vessels in the popliteal space. Some of the growths are adherent to a large venous trunk or to one of its branches, and into many others a small vein was traced. An injection thrown into the venous trunks

passed readily into the growths and filled the spongy or cavernous tissue composing them. This may be seen at the upper and inner part of the leg, where the injected tumours are laid open. Some of the growths contain smooth, spherical, very hard and partly or completely calcified phleboliths, which separate readily from the surrounding tissue.'

A macerated vertical section of the adjoining extremities of the femur and tibiæ presented the following appearances :—"The outer surfaces of the bones are irregular, and upon that of the femur, at its lower part, are several spaces which were filled with a soft cartilaginous substance. Near the junction of the middle and lower thirds of the femur is the line of an oblique fracture which has been united. The cancellous tissue of the bones is delicate with wide meshes; the compact layer has almost disappeared; near the line of fracture in the femur are several irregular spaces which also contained cartilage."

"Under the microscope sections of the nævoid growths showed a vascular tissue made up, for the most part, of cavernous spaces separated by thin bands of fibrous tissue; in other parts the fibrous tissue was much more abundant. The spaces possessed no proper wall, but were lined with a layer of endothelial cells having large oval nuclei. The stroma was for the most part dense and fibrous, but in places the presence of numerous round and elongated or oat-shaped nuclei indicated an active growth. In some sections arteries of considerable size were seen penetrating the capsule of the tumours. The round bodies already mentioned, when cut across, were seen to consist of a tissue having no discernible structure but arranged in wide concentric laminæ. In some, calcification had commenced at the centre, while others were completely calcified. Their situation, lamination, and structure clearly show that they are phleboliths. The osseous tissue of the lower extremity of the femur was very imperfect in its microscopic structure. The tumour of the lower end of the tibia consisted microscopically of small round nucleated cells (small round-celled sarcoma) without visible intercellular substance."

A section of a portion of the anterior wall of the femur shows, under the microscope, a thin layer of imperfect osseous tissue beneath the periosteum and a few trabeculæ of badly formed bone on the side of the medullary cavity. The intermediate portion is composed of a tissue containing very large spheroidal or

elongated cells like cartilage cells lying in a homogeneous matrix, the whole tissue being in fact imperfectly formed cartilage.

A section of one of the cartilaginous islands referred to was composed of small, round, irregular, or, in some instances, spherical-shaped cells, giving off anastomosing fibrils. The ground substance was homogeneous, and either chondroid or mucinoid.

"The limb was dwarfed from infancy. The tumours of the toes with similar 'cartilaginous' tumours on the digits of the hand on the same side had existed almost from birth. The femur had been fractured four times; the tibia once. The limb was amputated."

The angiomata were evidently developed in connection with the larger veins, but they had supplying arteries. *Multiple* cavernous angiomata of the subcutaneous tissues must, I think, be exceedingly rare. I find no mention of them in the standard works on Pathological Anatomy, with the exception of Billroth's 'Surgical Pathology.' There the fact of their occurrence in the neighbourhood of the large venous trunks is spoken of. No case is recorded in the 'Transactions' of this Society, nor have I been able to find a reference to any published cases in this region of the body of multiple angiomata; but my search has not been exhaustive.

It is scarcely necessary to add that they are not uncommon in the liver and kidney; and Thierfelder[1] has described two cases in which there were multiple cavernous nævi in the mucosa of the small intestines.

The numerous fractures were doubtless due to the defective structure of the bones.

Remarks.—Apart from its rarity, this specimen is of much interest as an illustration of the dependence of certain tumours of early life on congenital malformation of the tissues. The fact is the more striking since the dwarfing and bending of the limb are apparent to the unaided eye. With the microscope, a defect in the structure of the osseous tissues is apparent, and there are islands of cartilage from which it may be safely inferred that the tumours have originated. Although the largest island in the femur may occupy one line of a fracture, yet that fact alone is evidence of defective power of repair. Virchow long ago showed that islands of unossified cartilage may be found near the extremities of the diaphyses of long bones; and Cohnheim made use of this fact in support of his well-known theory of tumour forma-

[1] 'Arch. f. Heilkunde,' Lief. 3, 1873, vol. xiv, p. 38.

tions. But these islands have chiefly been found in rickety bones. The best illustrations of enchondromata originating from fœtal remnants are the multiple enchondromata of the digits of early life, of which the specimen under consideration is an example.

In this other specimen on the table from the Royal College of Surgeons' Museum (No. 333) we have the digits of a hand affected with enchondromata varying from half an inch to an inch and a half in diameter. And in the medullary cavity of the first phalanx of the little finger is a mass of fœtal cartilage which has not been absorbed and has become a nascent enchondroma. The bone tumours in the specimen just described probably have a similar origin. Many of the islands of cartilage have remained quiescent, while one in the lower end of the tibia probably did not begin to grow until later in life, when the nutrient energy of osseous tissue is lessened; and as a result a more lowly organised tumour has formed which more nearly resembles a round-celled sarcoma.

The specimen was presented to the museum of the College by Mr. Jonathan Hutchinson, to whose kindness I am indebted for permission to publish the case. *January 4th*, 1887.

---

5. *Sarcoma of the back with fibrous nodules over it.* (*Card specimen.*)

By J. H. Targett.

History of case.—Walter P—, aged 61, admitted with tumour in right loin, which had existed there sixteen years. It began as a "knob that grew outwards." Growth very slow till within the last two years. It was freely removed by Mr. Bryant.

Description of specimen.—The tumour is nearly spherical in outline, four inches in diameter, and projecting two and a half inches above the surface. There are several hard nodules in the skin over the tumour; the largest of these is about the size of a walnut, and is situated on the apex of the swelling. Where the skin is most distended it has a blue nævoid appearance, but around the base it is quite normal. On section the greater portion of the tumour consisted of soft growth having a distinct fibrous

capsule which could be easily separated from the skin. The nodules over the tumour were white on section, hard, like fibro-cartilage, and situated in or immediately beneath the skin.

Microscopic examination showed that the main portion of the tumour consisted of a small spindle-celled sarcoma, which was degenerating in places. The hard nodule on the apex of the tumour was composed of dense wavy bands of fibrous tissue, the skin being tightly stretched over it, and thinned, but not invaded.

The smaller younger cutaneous nodules were richly nucleated, and thus closely resembled the main portion of the growth. The probable explanation is that some of these superficial fibromata have undergone sarcomatous degeneration, and *not* that they are local secondary deposits, as was first suggested.

November 2nd, 1886.

---

6. *Sarcoma of pelvic fascia.*

By Leopold Hudson.

The patient from whom this growth was removed was a single man, who had been under the care of Dr. E. A. Hall, of Surbiton, to whose kindness I am indebted for the following notes of his history:

He was 28 years of age, and had been weakly from his birth, both bodily and mentally, and had a decidedly strumous diathesis. There was no history of tumour in any member of his family.

On March 2nd, 1886, he had an attack of mumps, which took the usual course without metastasis. On the 15th of the same month he first complained of pain and difficulty in defæcation. On examination the rectum was found almost blocked up with a bilobed tumour, feeling like an enormously enlarged prostate. A finger, passed with difficulty beyond this enlargement, encountered what was thought to be a bunch of enlarged glands on the posterior rectal wall.

On the 21st April, Mr. Allingham, who saw the patient in consultation, found that the tumour had considerably increased in

size, and upon the limbs small nodules, from the size of a pea to a large bean, were found in the course of the lymphatic trunks.

In June dulness in the hypogastric and right iliac regions was first noticed, due to the rising of the growth above the pelvic brim. During the next two months the tumour grew rapidly until it occupied almost the whole abdomen, causing lancinating gastric pains, and latterly severe vomiting. The patient was seen by Mr. Nunn on the 6th August, who agreed with the diagnosis of malignant growth of the prostate. He gradually emaciated and died on the 16th October. Throughout the case there had been constipation which yielded to purgatives, but never complete obstruction of the bowels, the urine contained no albumen, and there were no symptoms of sciatica or neuralgia of the lower extremities indicating nerve pressure.

At the request of Mr. Nunn I made a *post-mortem* examination forty-eight hours after death, and found the tumour completely filling the true pelvis and bulging upwards into the abdominal cavity. It weighed 7½ lbs.; its greatest circumference was twenty-one and a half inches; below in the true pelvis thirteen and a half inches; its vertical diameter seven and a half inches. It was bounded by a distinct fibrous capsule, separable into several layers. It consisted of a lower main mass with two large lobes attached to it above, one anterior, the other posterior.

On section the lower part of the growth was hard and flesh-like, whilst anteriorly was an area of softer feel and whiter tint. Of the two upper lobes, both of which were more vascular than the lower, and showed no very distinct line of demarcation from it, the posterior contained three cysts filled with gelatinous material, whilst quite behind was a space where the capsule had become separated from the growth, the interval being filled with blood.

The rectum coursed along the posterior wall of the growth to the right of the middle line. It bore no obvious mark of compression, and its mucous membrane showed no sign of ulceration.

The bladder and prostate with vesiculæ seminales were of normal size, but had been displaced upwards somewhat by the tumour, from which they were easily separable by dissection. The vasa deferentia and ureters coursed along the anterior and lateral aspects of the growth. The cutaneous nodules which have been noticed underwent marked retrogression during the last days of his

illness; several of them indeed were scarcely perceptible at the autopsy. There were no other secondary growths.

Microscopically, the growth is found to be a small spindle- and round-celled sarcoma, containing areas which have undergone development into a myxomatous tissue, and others of hyaline necrosis accompanied by liquefaction. Sections of the tumour and of one of the cutaneous nodules are shown.

It appears to me, from the history and from the dissection, that this growth originated from the pelvic fascia, probably from that prolongation of the recto-vesical division of it which, investing the vesiculæ seminales, passes across to form the floor of the space between the bladder and the rectum.

The case was diagnosed as one of malignant prostatic growth. How could this error have been avoided? The question is an important one practically, for it is possible that could the true relations of this tumour have been ascertained early it might have been enucleated through a perinæal incision.

In the 'Edinburgh Medical and Surgical Journal' (vol. i, p. 23) Dr. Drew, of Fermoy, County Cork, relates the case of a lady, who died from retention of urine, occasioned by the pressure of a large fibrous tumour occupying the entire pelvic cavity, and having one of the sacro-sciatic ligaments for its origin. At the autopsy, the growth was found attached by only a slender pedicle, which on division permitted the tumour "to come away like an almond blanched from its skin."

The same practitioner met with a second case in a pregnant woman. The tumour was pedunculated and encapsuled, and grew "from the right side of the pelvis." It measured fourteen inches in circumference, and weighed 2 lbs. 8 oz. It was removed before labour by a perinæal incision, and both mother and child did well.

But a search into the literature of pelvic tumours has failed to discover a case in a male at all parallel with the present one, and this fact, coupled with the surgical interest that is attached to all tumours in this region, has induced me to bring it under the notice of the Society. *May 17th*, 1887.

7. *Sarcoma of pelvis simulating pelvic hæmatocele during life.* (*Card specimen.*)

By Wm. Collier, M.D.

History of case.—Florence A—, aged 15, was admitted into the Radcliffe Infirmary, Oxford, March 30th, 1887, with the following history:—Two months previously, being at the time in good health, she fell down a flight of stairs, striking the lower part of her back. A month later began to complain of tenderness in left iliac region and pain on walking; the symptoms increased in severity up to the time of admission.

On admission.—Temperature 102⅓°. A semi-fluctuating swelling was found in left iliac fossa extending upwards into left lumbar region; there was also distinct tenderness over one of the lower lumbar vertebræ. The swelling was thought to be due to an iliac abscess secondary to the fall. Two days later, the temperature continuing above 102° F., an opening was made immediately above the outer third of Poupart's ligament. The incision was followed by the escape of a large quantity of blood-stained serum, and on introduction of the fingers what resembled decolourised blood-clot was removed, and it seemed as though the fingers were in a mass of broken-down blood-clot; it was then regarded as a pelvic hæmatocele. Patient rapidly lost strength and died a fortnight later.

Autopsy.—The left iliac fossa was found occupied by a large mass of new growth, which extended upwards to a level with the third lumbar vertebra. A distinct circular erosion of the body of this vertebra existed, which appeared to be due to the pressure of the tumour, and not to growth originating from it. The whole mass was behind the peritoneum. Many of the lumbar glands were enlarged. No deposit found in any of the other organs. Microscopical examination showed the growth to be a round-celled sarcoma. *May 17th*, 1887.

8. *Sarcoma of dorsal vertebræ; intraspinal hæmorrhage; (?) secondary.* (*Card specimen.*)

By Herbert W. Page, for Thomas F. Raven (Broadstairs).

A sailor, aged 40, had suffered for some months from dysenteric diarrhœa and vague pains, with increasing cachexia. Malignant disease was suspected, but no certain diagnosis was made until suddenly he became paraplegic. The immediate cause of death was cystitis and peritonitis.

Necropsy.—A tumour, measuring some three inches in the vertical direction, was found involving parts of the fifth, sixth, and seventh dorsal vertebræ, disorganising the adjacent ribs, projecting posteriorly on each side of the spinous processes, and forwards into the spinal canal, where the cord itself was invaded and broken down. A little lower there was hæmorrhage within the meninges.

Microscopical examination shows the growth to be a round-celled sarcoma. *May 17th*, 1887.

---

9. *A case of alveolar sarcoma.*

By G. R. Turner.

The tumour of which microscopical specimens are on view (the drawings exhibited have been made by Dr. Delépine) occurred in the person of a young man, aged 20, and proved fatal in about seven months after he first noticed it in the left lumbar region. It here presented during life as an elastic fluctuating swelling, very like a lumbar abscess; indeed exploratory puncture was necessary to complete the diagnosis. Its connections to the deeper parts were found to be such as to render its removal impossible. The patient died, worn out by pain and exhaustion, about four months after first coming under notice. The chief symptoms during life were pain in parts receiving their nervous supply from the left lumbar plexus, and considerable swelling and

œdema of the left lower extremity, great emaciation, slight cough and pain in breathing some fortnight before death.

Post-mortem examination made forty-one hours after death.—There was a large fungating mass in the left lumbar region. On exposing this fully it was seen to spring from the bone of the twelfth rib, from the outer lip of the crest of the ilium, and from the transverse processes of all the lumbar vertebræ, being connected with their periosteum. It extended on to the diaphragm above and over the bodies of the vertebræ to the upper part of sacrum and left iliac fossa below. Although it covered these parts it did not actually implicate either the bodies of the vertebræ or the ilium. The abdominal aorta was found surrounded by masses of new growth and enlarged diseased lumbar glands. The vessel was much thickened and smaller than normal, and the left common iliac artery was embedded in the substance of the tumour. The inferior vena cava was stretched along the side of the growth, and was not so surrounded as the aorta; the left common iliac vein, however, ran through its substance in company with the artery.

The psoas magnus and parvus stretched tightly over the growth, from which they could not be separated. They were full of broken-down purulent-looking débris. The neighbourhood of the pelvis of the left kidney was occupied by the same material, evidently softened broken-down neoplasm. The kidneys themselves were unimplicated; the left ureter was stretched tightly over the tumour. The pancreas was nodular, firm, and almost an entire mass of the growth. On the right side of the diaphragm were two nodules, each about the size of a shilling. The spleen was a little pale, the liver enlarged and slightly lardaceous. The great omentum was injected and studded with small nodules of the growth. The mesentery and meso-colon were in the same condition.

The spleen and diaphragm were pushed upwards, the intestines and stomach lay somewhat to the right, and the left kidney displaced forwards by the growth behind.

Nothing out of the common was wrong with the heart or pericardium. There were some recent adhesions in connection with the right pleura. Some old ones on the left side.

The lungs were slightly œdematous and studded all over with secondary growths, chiefly superficial, and at the bases. On section these nodules were found to be firm and fibrous, very few

ough

th.—
gion.
: the
from
ected
bove
rum
did
the
s of
ssel
mon
The
and
ein,

rth,
of
the
ial,
m-
ver
an
rm
en
s.
es
ne

s
f

DESCRIPTION OF PLATE XXI.

Illustrating Dr. Walter Edmunds's specimen of Papilloma of Hand. (Page 352.)

From photographs.

FIG. 1.—Inner part of dorsum of hand; the great thickness of growth on the back of the index finger. The hand is deformed by contraction after burn.

FIG. 2.—Outer and palmar aspect of hand. The growth extends along back of thumb, and down index finger; in places it has sloughed away.

Fig. 1

Fig. 2

West Newman & Co lith.

reaching more than a quarter of an inch into the substance of the organ. The deepest penetrated about an inch.

The tumour was somewhat brain-like in appearance, but rather firmer, and was not encapsuled, even in its primary lumbar seat. It had evidently spread by a process of infiltration to the neighbouring parts. The lumbar glands, as mentioned above, were thus secondarily affected; there was no lymphatic enlargement elsewhere.

1. *Description of the tumour.*—The portion of the primary tumour taken for examination was removed from the lumbar region, and included a part of the peritoneal and aponeurotic coverings of the growth on its inner or abdominal side.

The external fibrous capsule of the tumour (composed of the superficial portions of peritoneum) varies in thickness, being almost absent at some places, whilst at other points it forms irregular masses of dense fibrous tissue penetrating for about an eighth of an inch into the substance of the tumour. Where this fibrous coat is thick there is a marked depression in the surface of the tumour. From this thickening a number of tapering processes diverge, penetrating into the body of the tumour where they are apparently continuous with the stroma. The deeper parts of the tumour are composed of small cells enclosed within the meshes of a distinct stroma. The proportion of cells to the interstitial tissue varies in various parts of the tumour. The cells are very abundant immediately under the superficial fibrous layer, where they form an almost continuous layer. In the deeper portions of the neoplasm the stroma is arranged so as to form very distinct alveoli. In some places the stroma is very abundant and the cell spaces very small, containing only a few cells, sometimes only one; in other places, on the contrary, the alveoli are large and contain a great number of cells.

In order to understand fully the arrangement of these various parts it is necessary to magnify them 200 or 300 times, and it is advantageous to use higher powers still.. Taking first a typical portion of the new growth, *i. e.* one where the alveolation is evident even with a very low power, the following points can easily be made out.

The stroma is composed of a number of septa varying in thickness from 1 μ to more than 50 or 60 μ. These septa look, in most places, almost homogeneous, but when examined carefully they

generally show faint indications of a longitudinal fibrillation. These partitions separate a number of irregularly rounded or elongated spaces or alveoli. From the arrangement and shape of these spaces it is evident that they are elongated sinuous channels, the various shapes presented by them in the section being due to the greater or lesser obliquity of the plane of section in relation to their long axis.

Passing now to the contents of the alveoli we find that they are made up chiefly of small, irregularly-rounded cells, varying in size from 8 or 9 μ to 16 or 17 μ, the average being from 12 to 13 μ. (It is probable that during life, in addition to these cells, the alveoli contained a fairly large amount of lymph.)

In those alveoli which have an elongated shape the cells are seen to be connected with the stroma. This is best seen where the septa are thin and the cells form a single layer on their surface, an arrangement which obtains in many parts of the tumour. In such places it will be seen that the cells are more or less pyriform in shape, and that their tail or stalk is inserted obliquely on the surface of the septa. When there are many of these cells attached in this manner to one of the trabeculæ it is difficult to recognise clearly their attachment, but they are distinctly imbricated, and this indicates that the arrangement must be the same.

The processes through which the cells are attached to the stroma may in many places be seen to be continuous with some of the fibrillæ noticeable in the septa, which may also contain in such places small, badly-formed, spindle-shaped cells. The thickness of the interalveolar partitions is proportional to the number of cells accumulated on their surface.

It is difficult to say whether all the cells are directly connected with the stroma or not, but from the appearance and size of some of the alveoli it seems evident that the cells after a time become free, and accumulate in the central portions of the spaces.

2. *Diaphragmatic secondary growths.*—In these nodules we find all the characters of the primary growth *plus* the effects of the invasion of the muscular tissue of the diaphragm. The invasion of the serous and subserous coats of the parietal pleura and peritoneum are also well seen.

Both the pleural and peritoneal serous layers are much thickened. This thickening is due to multiplication of the elements of the

serous layer itself. The layer of endothelium can be well recognised, and between it and the layer of elastic fibres separating the serous from the subserous coats there are bundles of fibrous connective tissue, separated by the alveolar growth. The fibrous tissue itself is certainly increased in amount; the state is therefore one of chronic thickening of the pleura and peritoneum due to irritation caused by the growth.

The subserous coat is in the same state as the serous coat. The muscular stratum forms here the most interesting part for examination. At the margin of the nodule the muscular fibres are found closely packed together with hardly any intervening interstitial tissue (endomysium) between them. We may therefore infer that the muscle before being invaded by the growth had the usual appearances of normal striped muscular tissue, at least as far as the arrangement of the fibres was concerned.

As we pass from the border of the tumour towards the centre we find, however, that the fibres get more and more separated one from the other, and at the same time they get smaller and smaller in diameter until they can hardly be recognised. So far there is nothing unusual, for we have here the usual effects resulting from the increase of interstitial tissue in any organ, a process which almost always leads to atrophy of the specialised parts of the organ.

But if we examine the tumour carefully the following points will be recognised:—Between the endomysium and the muscular fibre a number of small cells accumulate, encroaching upon the space belonging to the fibre. These cells evidently grow from the endomysium, and at first form a thin more or less crescentic layer on one side of the fibre; at this stage the cells are often flattened. The muscular fibre soon gets smaller and more regularly oval or round than at first; occasionally its shape is much altered owing to unequal pressure on various sides. As the new cells get more numerous they either form a complete layer around the fibre, or accumulate on one side of it, flattening it against one of the sides of the cavity in which it is now contained. As this goes on, fluid probably accumulates between the cells and around the muscular fibre. Finally the muscular fibres are entirely destroyed by pressure, the only trace remaining of their former existence being the general arrangement of the modified endomysium. The endomysial compartments or alveoli retain the original elongated shape

of the fibre, but are now several times their original size owing to the large number of cells distending them. There are a great many other points of interest in this tumour, but it would take too much time to discuss them here.

3. *Pulmonary secondary growths.*—Two of these were examined and showed the same points in different degrees. In one the pleura is more affected, in the other the lung parenchyma. In the first the pleura measures from a quarter to three eighths of an inch in thickness. The underlying lung is intersected by a number of thickened interlobular septa. In the other specimen the pleura does not measure more than an eighth of an inch in thickness, but the subjacent parenchyma is entirely consolidated and resembles a piece of glandular tissue, in which interlobular septa cannot be recognised.

In both cases the pleura exhibits under the microscope the same features as those of the primary growth, and of the infiltrated peritoneal and pleural coverings of the diaphragm. In many parts of the pleura the alveolation is even better marked and more regular than in the other tumours. In other parts the cells remain spindle shaped and the alveolation is not well marked. In the superficial layers the formation of the new growth at the expense of fibrous connective tissue is well shown; and if there could be any doubt in the mind as to the origin of the tumour it would be impossible to retain it after an examination of that region. The fixed connective-tissue corpuscles are seen in the section to become larger, forming stout spindles, which by multiplication soon form spindle-shaped masses of cells in the midst of the fibrous matrix. The cells become more rounded in shape and almost epithelial looking. At the same time the matrix becomes more hyaline, as if it had been treated with some weak acid.

Finally the fibrillation disappears. When this stage is passed, the cells not only continue to proliferate, but most of them remaining connected with some of the matrix continue to add to it in a way which cannot be discussed here, so that there is at the same time proliferation of cells and formation of matrix. The stroma is very thick in young vessels most of which are evidently of new formation.

The subserous layer of the pleura shows several large veins and lymphatics distended by masses of tissue having the same charac-

ters as the rest of the tumour. The same thing is found in the thickened interlobular septa.

All the connective-tissue stroma of the lung has taken to a greater or lesser extent the structure of the neoplasm. The mucous membrane of the small bronchi is often more than ten times the normal thickness; this of course causes a proportional narrowing of the lumen. A number of small bronchi present on their fibrous coats a remarkable modification of the tumour; in these parts the intercellular substance is very transparent and separates a number of small spaces containing one or two rounded cells. The arrangement in some places is not unlike that of parenchymatous cartilage. This may possibly be due to some modification of small peribronchial nodules; however, the origin of that tissue has not been fully ascertained yet.

Where the lung parenchyma is completely consolidated its original structure can hardly be recognised. However, by careful examination one can recognise that the alveoli, alveolar passages, and terminal bronchi have their lumen filled up with small polypoid growths springing from their altered walls. This is of course what might be expected from the general structure of the tumour. The intima of several of the small arteries is very much thickened, and in some cases the swelling takes the form of a small polypoid growth occupying nearly the whole lumen of the vessel. As in the case of the primary tumour, the relative amount of cells and stroma varies much in different parts of the tumour.

Conclusion.—From the above description, it is evident that the tumour belongs to the class of sarcomata, and to that special variety which Billroth has named alveolar sarcoma. However, it differs somewhat from the form of tumour described by that observer in the small size of the cells; so that whilst Billroth's alveolar sarcoma deserves the name which has often been ascribed to it, viz. "large-celled, round-cell alveolar sarcoma," our specimen should rather be called a "small-celled alveolar sarcoma." This smallness of the cells is also a characteristic feature of some of the cases which have been published since Billroth's original paper appeared. This can be seen by comparing the various drawings which have been published by Rindfleisch, Godlee (or Erichsen), Green (from the same case as that used by Mr. Godlee), Ziegler, and others; a tumour of the same kind has also been delineated by Mr. Parker from a case of Dr. Sidney Coupland's, and

although it is named in Druitt's 'Vade Mecum' a round-celled sarcoma, it can be taken as a good instance of a transition form between round-celled sarcoma, lymphadenoma, and alveolar sarcoma. It should also be remarked that it is hardly right to call this tumour a round-celled sarcoma, as the most typical cells are either oval or pyriform.

The tumour has certainly, in many places, a carcinomatous look, but unless we receive, among others, Cornil and Ranvier's definition of carcinoma it is evident that the tumour belongs to the class of sarcomata.

1. It is distinctly a connective-tissue tumour, for (*a*) it distinctly arises from pre-existing connective tissue. (*b*) The walls of the vessels have, in many places, taken the characters of the tumour. (*c*) The cells and the stroma are intimately connected.

2. It is evidently malignant, and therefore a sarcoma, for (*a*) the course of the case shows it. (*b*) There are metastatic growths in various parts of the body, and the infection has evidently taken place through the blood-vessels. (*c*) The tumour has no definite border, but encroaches upon the neighbouring tissues, causing transformation of connective tissue into embryonic tissue and atrophy of all other formed elements. (*d*) The tumour is, in many places, distinctly heteroplastic in the sense that the variety of tissue which it represents is not normally found in some of the parts affected. (*e*) All the cells show very distinct, embryonic characters having one or several large nuclei with very little protoplasm around them, and a tendency to revert to the spherical shape.

3. The tumour is an alveolar sarcoma, or a lymphadenoma, because it is composed of a distinct stroma forming meshes which enclose a number of cells; but the large size of the alveoli, the abundance of the stroma, the appearance of the cells, the distribution of the tumour, its mode of origin from fibrous tissue, all are against its being classified among lymphadenomata, whilst, on the contrary, all these characters support the view that it is an alveolar sarcoma. It will be evident from this that we do not agree with those who would make alveolar sarcomata a variety of lymphadenoma. That there are strong affinities between the two cannot be doubted; but so there are between cartilage and mucous tissue, and certainly nobody would venture to say that it is unnecessary to separate them one from the other.

There is, however, a pecularity of the tumour which distinctly connects it with lymphatic structures, and this is the arrangement of its alveoli; when these are properly cut they can be seen to form long channels which, during life, must have contained not only cells but also lymph. The cells attached to the stroma form an epithelioid lining to these cavities, and by their proliferation fill them up gradually with new cells. The tumour takes, therefore, an appearance which is very analogous to that of a glandular epithelioma, *i. e.* an adenoma. And as the cells which line the alveoli are closely allied to endothelial cells, the tumour might, with advantage, as has been suggested by some writers, be named an endothelioma.

In this case there is nothing to justify Waldeyer's views that such a tumour should be called a plexiform angio-sarcoma.

March 3rd, 1887.

---

10. *Recurrent ? melanotic sarcoma of the breast.*

By Henry T. Butlin.

[With Plate XIX, fig. 1.]

The following case presents several points of interest, particularly in the determined local recurrence of the disease, and in the colour and structure of the tumours.

The patient, when she first came under notice in June, 1880, was 64 years old, married, and the mother of children, the youngest of whom was twenty years of age. About the beginning of the year she had noticed a lump the size of a small nut in the breast, and this had continued to grow until it reached in June the size of a bantam's egg. It was situated below and external to the left nipple, was firm in feel, irregular in shape, not adherent to the integument. There was no retraction of the nipple, and the glands were not enlarged. I made a free removal of the tumour, but am not able to say whether I removed the entire breast or not. The breast was removed at one of the operations, but neither the notes in the hospital case-book nor my memory serve to say whether this was at the first or at one of the later operations.

The tumour was perfectly circumscribed, enclosed in a thin capsule, of brownish-black colour, firm but friable.

In June, 1882, she returned to the hospital with a tumour the size of a walnut situated at the outer extremity of the scar, to which it was adherent. It was freely removed and presented the same appearance as the original disease.

In February, 1884, she again returned with two or three nodules at the extremity of the scar, to which they were adherent. They had been growing for about a year. They, and the skin over and for some distance around them, were removed, and each again presented the same circumscribed outline and brownish-black colour as the first and second tumours.

In October, 1886, I removed two little tumours, the larger about as large as a nut, from beneath the scar, where they had been noticed several months. They precisely resembled the tumours which had been removed on the previous occasions.

The patient recovered rapidly from each one of the operations. Her health does not appear to have suffered from the recurrence of the disease or from the operations which have been undertaken for its removal. The glands have never been enlarged, and there has not been any sign of affection of any other part of the body. The recurrence has always appeared on the axillary side of the previous disease, so that the situation of the last growth was almost on the side of the chest towards the axilla.

Sections of the tumours removed at different times were examined by myself and Mr. Bowlby. I could not make up my mind whether they presented the characters of alveolar sarcoma or carcinoma, but thought that there were pigment granules in the bundles of connective tissue which separated the groups of cells. I therefore considered the tumours to be melanotic, but could not be sure whether they were carcinomatous or sarcomatous. Mr. Bowlby could not discover any pigment, but thought the colour was due to effused blood. He believed that the disease was alveolar sarcoma.

The disease was therefore recorded in the case-books as alveolar sarcoma, and it is certain that its clinical characters have been throughout those of sarcoma, not of carcinoma.

With regard to the melanosis, if it be melanosis, it is curious to observe that when it occurs in malignant mammary tumours the tumours present usually an alveolar structure, and this has led to

difficulty in classifying them. Professor Billroth has described a melanotic tumour in his article on the breast in the 'Deutsche Chirurgie,' which presented the characters and ran the course of carcinoma, affecting the lymphatic glands, &c., but of the exact nature of which he found the greatest difficulty in convincing himself. It was only after repeated examination of the sections that he at length came to the conclusion that the disease was alveolar sarcoma. He appears also to be confident that melanotic carcinoma does not exist.

Gross, on the other hand ('Tumors of the Mammary Gland') has never seen a melanotic sarcoma of the breast, but thinks that melanotic carcinomas are not rare.

(In the discussion on this case, various opinions were expressed, which may be found in the 'British Medical Journal,' 1887, i, 63; and the case was referred at my request to the Morbid Growths Committee, the report of which is appended.)

January 4th, 1887.

Report by the Morbid Growths Committee on Mr. Butlin's case of recurrent tumour of the breast.—The material submitted to us consists of the entire tumour (hardened in alcohol) removed at the fourth operation, together with microscopic sections of the growths removed on the second and third occasions.

The tumour is about as large as a filbert, is distinctly circumscribed, and invades neither the skin which covers nor the fat which elsewhere surrounds it.

On section a distinct limitary wall of fibrous tissue is easily recognisable forming the periphery of the morbid growth. The divided surface is slightly blood-stained towards the centre, but otherwise is of pure white colour, and it has, what is of cardinal importance, a distinctly foliaceous character somewhat like that of an ordinary adeno-fibroma of the breast.

Histology.—The most important fact evident on microscopic examination is the distinct papillary construction of the growth. From the inner surface of its fibrous wall, there arise branching processes of connective tissue, in many places (especially in their ultimate subdivisions) of extreme delicacy and mucous in nature.

All the processes are thickly invested with epithelium. The deepest layer of the cells is distinctly columnar; the rest, to judge from the spherical form and equidistance of the nuclei, are pro-

bably spheroidal, though the outline of the cell-body is untraceable (Pl. XIX, fig. 1).

Extensive hæmorrhage has occurred into the tissue of some of the delicate trabeculæ of the tumour; the shape of the extravasated red corpuscles is unaltered.

There is no pigmentation in any of the preparations of the tumour which we have examined.

In regard to the sections submitted to us of the second and third removals, they sufficiently resemble those made by ourselves of the fourth to lead us to conclude that the previous growths are essentially of the same nature as that last removed.

The appearances presented, we consider, remove the tumour from the class of sarcomata; and we regard it as a villous carcinoma (duct cancer of Cornil and Ranvier), originating, as evidenced by the columnar character of the deeper epithelium, in connection with the ducts of the breasts as distinguished from its acini.

That infection of lymphatic glands has not yet occurred, and that the tumour last removed, like those preceding it, does not invade the tissues amidst which it lies, are facts certainly rare in the life of those tumours which are anatomically classed as carcinomata, but they are facts which are not unknown in the history of carcinoma in other situations.

R. W. Parker.

March 15*th*, 1887. Samuel G. Shattock.

---

11. *Adeno-sarcoma of tongue with calcifying nodule in the centre.*

By Rickman J. Godlee, M.S.

[With Plate XVIII.]

Towards the end of last year a young woman, aged 24, was sent to me by Mr. S. N. Bruce, of Kensington Gardens Square, complaining of a tumour on the under surface of the left side of her tongue near the tip. She had only noticed it for five weeks, and she asserted that at first one small sore place appeared, then



Fig. 5.

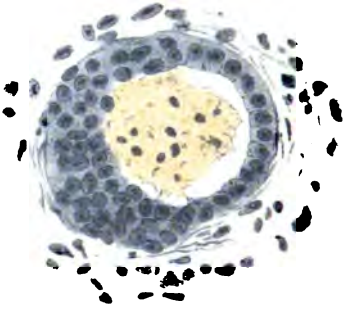

Fig. 4.

Fig. 1.

Fig. 2.

Fig. 3.

R. J. G. del.

Mintern Bros. Chromo. lith.

DESCRIPTION OF PLATE XVIII.

To illustrate Mr. Godlee's case of Adenosarcoma of Tongue. (Page 346.)

From drawings by himself.

FIG. 1.—The calcareous nodules. Natural size.

FIG. 2.—Section of tumour, showing both stroma and acini. (Beck, $\frac{4}{10}''$.)

FIG. 3.—Section of stroma. (Beck, $\frac{1}{10}''$.)

FIG. 4.—Section of a small acinus. (Beck, $\frac{1}{10}''$.)

FIG. 5.—Section of calcareous nodule. (Beck, $\frac{4}{10}''$.)

another; that these ran together, forming a larger sore, and that afterwards a lump developed itself.

When I saw her there was a grey slough as large as a shilling in the centre of a very distinct elevation in the position described, and this elevation, which felt hard when grasped between the fingers, seemed as large as a large nut, and formed a slight projection upon the upper surface of the tongue. I was much puzzled by it, and with the view of ascertaining whether it might possibly be an abscess, I punctured it deeply through the soft slough with an exploring trocar, and was much astonished to hit a hard substance in the interior. A pair of sinus forceps, introduced in the same position, easily extracted a piece of what looks like bone in two portions, for it broke during the process; it had the appearance and shape of a small pisiform bone (Pl. XVIII, fig. 1).

Thinking it was perhaps a foreign body, accidentally or even purposely introduced, nothing was done for a time; but a few weeks later, as matters did not much improve, I scraped out the soft interior of the mass with a sharp spoon, and having in this way ascertained that it was a tumour I removed it with scissors. The wound healed readily and soundly.

A section of the growth shows it to be an adeno-sarcoma. A large proportion of the mass is made up of sarcoma tissue; the cells varying much in size and shape, but being for the most part spindle shaped or round, and provided with nuclei of fair size (fig. 3). This part is well supplied with vessels. The glandular element is arranged in irregularly-shaped acini, single or multiple, and differing much in size (fig. 2.) The epithelium is for the most part square, but in parts the cells tend towards an oblong shape, and they are of small size. The acini are often dilated into small cysts containing a brownish almost structureless material, sometimes showing signs of concentric lamination and containing nuclei (leucocytes?) in varying numbers (fig. 4). The hard material, when ground down, looks very much like imperfectly formed bone; but I do not think it really is bone, as the spaces filled with the débris of grinding in no parts take quite the typical shape of bone-corpuscles, and in some have no resemblance to these bodies. It is quite unlike any calcareous deposit that I have ever examined, but I have no doubt that it is nothing more nor less than a salivary calculus. A drawing of the section is shown in fig. 5.

Stricker ('Handbuch der Lehre von den Geweben,' Leipzig, 1871, Band i, Seite 369) refers to a gland, described by Nuhn ('Ueber eine bisjetzt noch nicht näher beschriebene Drüse im Innern der Zungenspitze,' Mannheim, 1845) under the mucous membrane, and covered by a layer of longitudinal fibres of the stylo-glossus. It was described still earlier by Blandin, and is mentioned briefly in other text-books. It is a mucous gland, or perhaps mixed mucous and serous gland 7—10″′ long, and 3—4½″′ broad, and 1½—2½″′ thick, and has about five ducts opening on the under surface of the tongue near the tip. (A specimen prepared by Mr. Pearson for the Royal College of Surgeons was shown.)

It is perhaps not an unreasonable hypothesis, that this tumour which, as far as I know, is a unique specimen, may be connected with this gland. The epithelium is not indeed so large, nor is it of the same shape as that of the terminal acini of an ordinary mucous gland, but it is not dissimilar from that of the ducts. The presence of bone in this situation would be very remarkable; the nodule is, however, in fact a calcareous or cretaceous mass developed by transformation of the contents of one of the cysts mentioned above, which had reached a larger size than the others.

March 3rd, 1887.

---

12. *Tumours of the palate.*

By Stephen Paget.

[With Plate XIX, fig. 2, and Plate XX.]

1. A tumour removed from the palate of a gentleman, aged 60. It had been growing for a year and a half, more rapidly of late. It occupied the right half of the soft palate, and grew forward over the hard palate, inward across the middle line, and downward so as to touch the tongue. It was globular, soft, and elastic, almost fluctuating; the mucous membrane over it was thin and tense, but not adherent; there were no enlarged glands. The voice was thick and indistinct, but he could swallow easily, and had no pain. I incised the mucous membrane, and stripped some of it off; then easily shelled out the tumour. It had no firm

1871,
Ueber
n der
rane,
ts. It
fly in
ucous
$-2\frac{1}{2}$"
of the
n for

mour
ected
it of
ucous
sence
le is,
rans-
bove,

87.

l 60.
y of
grew
and
and
thin
The
and
ome
irm

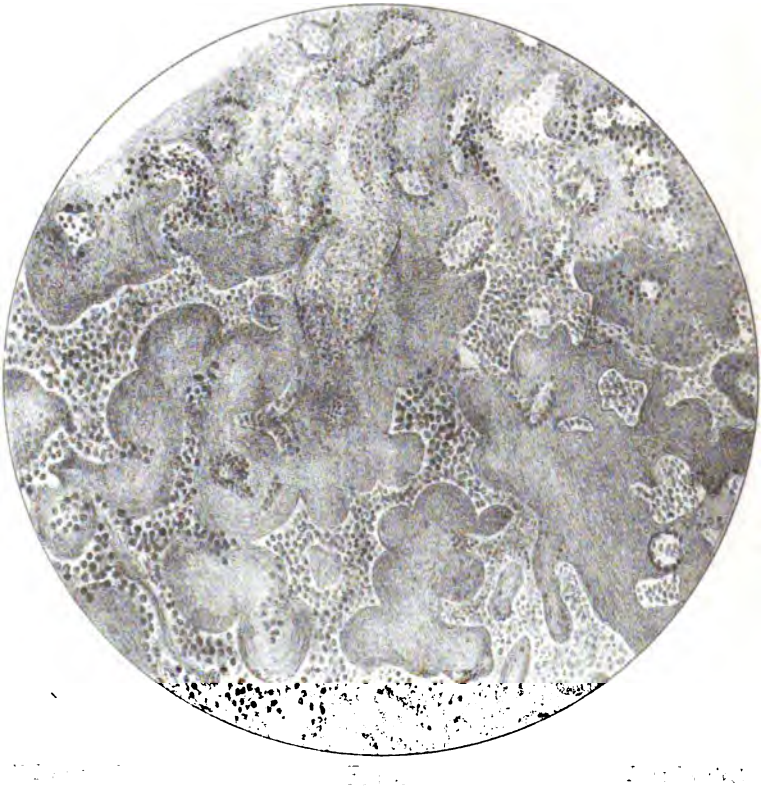

DESCRIPTION OF PLATE XIX.

FIG. 1.—Illustrating the report of the Morbid Growths Committee on Mr. Butlin's case of Recurrent Tumour of the Breast. (Page 343.)

From a drawing by Mr. Shattock.

The figure shows part of a delicate branching trabecula of connective tissue, thickly invested with epithelium. Obj. 4, oc. 4 (tube cut), Hartnack.

FIG. 2.—Illustrates Mr. S. Paget's paper on Tumours of the Palate. (Page 348.)

The figure shows a section of tumour of hard palate, from a girl of twenty-one. Four years' duration.

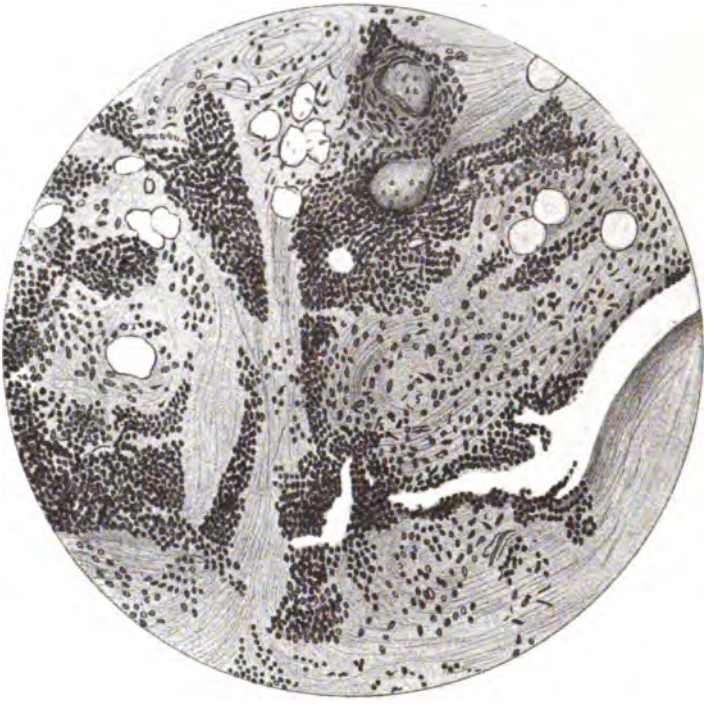

Fig. 1.

Fig. 2.

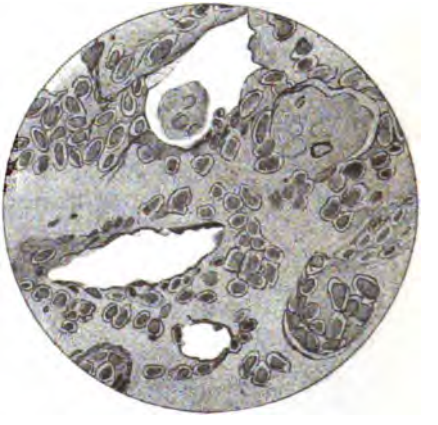

Fig. 3.

E. M. Paget del.

Pantelsson & Co. lith.

DESCRIPTION OF PLATE XX.

To illustrate Mr. S. Paget's paper on Tumours of the Palate. (Page 348.)

FIG. 1.—Section of tumour of palate from a woman of forty-five, fourteen years' duration. It shows masses of small round-cells in a groundwork of more or less developed fibrous tissue. In places the small round-cells are replaced by distinctly epithelial-cells, which form definite cell-nests. There is much glandular tissue.

FIG. 2.—Section of tumour of palate from a girl of twenty-one, four years duration. It consists of masses of epithelial-cells, mixed with much embryonic connective tissue. In places the epithelial-cells have degenerated into an opaque, structureless, granular substance, which is being invaded by growing blood-vessels. Gland tissue also occurs among the masses of epithelial-cells, and here and there are well-marked cell-nests.

FIG. 3.—From same case as Fig. 2.

attachment anywhere, but seemed to lie loosely in the palate, in a distinct capsule. The bleeding was free, but stopped by pressure. The tumour is a mixed-celled sarcoma, of round- and spindle-cells, with much embryonic connective tissue, and some imperfectly formed tubular glands.

2. A tumour removed by Mr. Thomas Smith from the hard palate of a girl, aged 21. It had been there for four years. It was small, circumscribed, and easily movable; the mucous membrane over it was smooth and not adherent. The growth was easily shelled out, and was found to lie in a smooth, shallow, round pit on the bone. Its structure is peculiar (Plate XIX, fig. 2; Plate XX, figs. 2 and 3). It shows a hyaline, homogeneous, or faintly granular matrix, which is broken up by masses of cells into curious tracts and processes with sinuous, crescentic, indented edges, sometimes split and frayed. The masses of cells are heterogeneous; some look like lymph-cells, but most are of an epithelial type, and there are many large squamous epithelial cells; there are also cell-nests. In and around the sinuous tracts of hyaline ground substance are scattered shrunken ill-shaped cells, which suggest that the ground substance and the cell-nests may be due to degeneration or perversion of masses of cells. In other parts of the section the cells are of a glandular type, and are laid down in tubules. Thus the general aspect of this tumour, under the microscope, is altogether irregular and embryonic.

3. A tumour removed by Mr. Walsham from the hard palate of a woman, aged 45; it was of fourteen years' duration. It was small, circumscribed, and freely movable; the mucous membrane over it was smooth and natural. The tumour was easily shelled out. In structure it is (Plate XX, fig. 1) of the same nature as No. 2; but the ground substance is fibrous, not hyaline. There is the same diversity of cells, the same unfinished gland tissue, the same well-marked cell-nests

Remarks.—Mr. Shattock has lately found these same cell-nests in another tumour of the palate. They serve to show the embryonic nature of these growths; and there are many ways in which tumours of the palate are like the tumours of the parotid region, which are manifestly embryonic in nature. For a collection and analysis of nearly one hundred cases of tumour of the palate, the writer refers to a paper by him in 'St. Bartholomew's Hospital Reports,' 1886. *November 2nd and December 7th,* 1886.

13. *Melanotic sarcoma of the hard palate.*

By Frederick Treves.

[With Plate XXII, fig. 1.]

In vol. xxxvi of the 'Transactions' of this Society I reported two cases of primary tumour of the soft palate. The present specimen concerns the hard palate, and consists of a variety of tumour that, so far as I am aware, has only once been previously observed in connection with this part.

The patient was a woman, aged 58. She was thin and wiry, of very fair complexion, and in the enjoyment of excellent health. Her family and personal histories revealed nothing of note. For the last four years she had been edentulous so far as the lower jaw was concerned, and retained in the upper jaw two teeth only, a molar on either side. Since this time she had worn a vulcanite plate carrying six false teeth. This plate had never been quite comfortable, and had always produced some irritation of the hard palate near the alveolus and just to the right of the median line. The "irritation" was such that it was always a relief to her to remove the plate. Four months ago a small soft swelling appeared upon the long irritated part of the hard palate, that is to say upon the right segment just behind the sockets for the incisor teeth. This tumour was smooth and at first painless. The pain increased, and to relieve it a dentist removed the remaining tooth on the right side, but without any benefit. For two months, and for two months only, the presence of the tumour had prevented the wearing of the false teeth. The pain occasioned by the growth appears to have been considerable.

The tumour was limited to the right hard palate. It reached nearly to the middle line on the inner side, and almost to the alveolus on the anterior and outer sides. Behind it reached the suture between the maxilla and the palate bone. The growth was flat, its margin was clearly and abruptly marked, and the surface of the tumour was raised above the surface of the palate about one centimetre. In general outline it was rounded. It felt uniformly firm, but not hard. It was of a dusky purplish black colour, the discolouration being patchy. In one place the epithelium appeared

to be a little worn, but apart from this the skin was sound, and there was no ulceration. There had been no bleeding. The growth was both tender and painful. No enlarged glands could be detected. The patient appeared in good health.

I removed the tumour on December 11th, 1885. By means of a chisel and mallet I took away the whole of the right side of the hard palate including the alveolus. To ensure a complete removal and to give ample room the upper lip was freely detached from the bone. The part removed was brought away in a single piece. On section the tumour was firm, homogeneous, and quite black. It looked like the section of a blood-clot. The skin covering it was thin, and appeared to be free from abnormal pigment. The growth was incorporated with the bone, and at its centre the bone had disappeared entirely over an area equal to that of a threepenny piece. The patient made a rapid and uninterrupted recovery, and returned to the country on the 20th of December. I saw her again in May, 1886. She appeared in excellent health. There was no evidence of recurrence at the site of the operation, and no enlarged glands could be discovered. The face had not suffered deformity. An obturator had been adjusted to the palate, and the patient's articulation was quite distinct.

Microscopic examination.—The tumour sprang from the periosteum. This fact was rendered clear when the margin of the growth was examined. The structure was that of a spindle-celled sarcoma. The cells were large, and there was a considerable amount of intercellular tissue. No myeloid cells were discovered. The mass was unevenly pigmented. The pigment appeared in the form of irregular blotches of a golden brown colour. Some of the collections were very small. In the majority it was evident that the pigment granules occupied the body of a spindle-cell. The blotches conformed as a rule to the outline of the nucleus of those cells. In some instances a part of the nucleus of the cell could be seen by the side of the pigment. It appeared, indeed, as if the pigment had replaced the nucleus in whole or in part. A few of the blotches were so large that this change must have extended beyond the limits of the nucleus. A considerable number of the pigmentary deposits were of most irregular outline, and their relation to the cells of the growth difficult to determine. Under a high power the deposits were seen to be made up of granules, some a ruddy brown, others black. The latter, however, were

comparatively few in number. The skin over the tumour was thinned, but apart from this appeared to be quite sound. The growth had not invaded it, nor was it the seat of any abnormal pigmentation.

From the very dark colour that the tumour presented to the naked eye the growth would have been expected to contain a great deal more pigment than it actually did.

The only case of a like nature of which I can find a record is reported by Gussenbauer.[1] The most elaborate work upon the palate with which I am acquainted is that by Gayraud in the 'Dictionnaire Encyclopédique' (1884), but he makes no mention of melanosis in connection with this region.

Two points are worthy of note. The sarcoma appears to have been caused by well-localised and long-continued irritation. Pigment is not, I believe, normally found in the human palate, but it is interesting to note that it is in the roof of the mouth that pigment is especially collected in many of the lower mammals.

November 2nd, 1886.

---

14. *Horny papilloma of hand.*

By Walter Edmunds, M.D.

[With Plate XXI.]

The growth is on the back of the right hand and covers a considerable surface, extending transversely from the outer side of the thumb to within an inch of the inner border of the hand, and from above downwards from an inch above the knuckles down the whole of the back of the thumb and index finger, and partly down the middle and ring fingers; the growth consists of a layer of horn of varying depth; it is thickest over the back of the index finger, where it is as much as an inch thick; in places it has sloughed away, but elsewhere it has a smooth even surface.

Under the microscope the superficial horny tissue is seen to be composed of dense columns of epithelium; the papillæ are greatly

[1] 'Prager med. Wochenschrift,' Nov. 9, 1886.

enlarged, the rete Malpighii is thickened, and in the corium is an infiltration of indifferent cells. There was no enlargement of the glands either at the elbow or in the axilla.

The history of the case is, that when three years of age the patient sustained a severe burn of the right hand which caused considerable contraction and deformity which has remained throughout life, and it was on the scar of the burn that the papilloma has appeared.

The patient and her friends state that the growth was first noticed five years ago, which would have been when the patient was 68 years of age and sixty-five years after the burn; its growth did not commence to slough till two years before admission, since which time it has gradually been becoming more offensive. Mr. Sydney Jones amputated the hand and the patient made a satisfactory recovery, and when last heard of, nine months after the operation, was in good health.

The specimen is preserved in the museum of St. Thomas's Hospital. *February 1st*, 1887.

Report of the Morbid Growths Committee on Dr. Edmunds's specimen of horny papilloma of the hand.—We have examined several sections prepared by ourselves from one of the fingers as well as from the back of the hand, in both of which situations some necrosis of the new growth has occurred.

The sections from the back of the hand show a layer of "horn" about five millimetres in thickness, formed by dense vertical processes of epithelium produced upon greatly elongated papillæ.

Sweat-glands are observable in all the sections; and taking the position of these as an index of the deep limit of the corium, it may be said that in none of the sections has the cutaneous epithelium traversed the entire substance of the true skin.

In all the sections there is a well-marked interval between the deepest limit of the epidermis and these glands; as a minimum this interval measures two millimetres.

The corium, however, is abundantly infiltrated with small round-cells, in places grouped in masses of considerable size around the vessels.

The lower edge of the epithelium, moreover, is very irregular in course, and has distinctly passed beyond the general lower level of the epidermis.

The sections taken from one of the fingers show similar appearances.

From this description it will be evident that no positive statement can be made as to the benignancy or the infectiveness of the new growth.

The amount of epithelial invasion is not sufficient to justify a verdict of malignancy; the signs presented would apply equally to the earliest stage of squamous-celled carcinoma and to a horny papilloma, in which inflammatory changes had subsequently supervened.

As regards the clinical history, we would direct attention to the facts that necrosis of these portions of the growth had extended over a period of two years, that there was no enlargement of lymphatic glands, and that the patient is at present free from any signs of disease, now almost twelve months after the amputation of the hand.

R. W. PARKER.

May 3rd, 1887. SAMUEL G. SHATTOCK.

---

15. *Horny growth from the neck.* (*Card specimen.*)

By ALBAN DORAN.

FROM a woman, aged 58. It grew from the skin of the neck, immediately above the middle third of the left clavicle, and pointed towards the middle line somewhat downwards. The patient first noticed the growth sixteen months before it was excised; it caused her much inconvenience, through dragging and catching in clothes and towels. It measures half an inch in length, and is flattened and curved.

In many respects it closely resembles the "Horny Growth from the Neck" exhibited in 1882 ('Trans. Path. Soc.,' vol. xxxiii, p. 337, and Museum Royal College of Surgeons, Pathological Series, specimen 4124), but no sebaceous cysts were found in the neighbourhood of this specimen. *March 3rd*, 1887.

16. *A case of a horn growing from the glans penis, associated with epithelioma.*

By A. Pearce Gould.

[With Plate XXIII, fig. 1.]

B. S—, aged 52, came under my care on December 16th, 1886, at the London Temperance Hospital.

He had been the subject of congenital phymosis, and had never been able to withdraw the prepuce; but this does not appear to have given him trouble until four years ago, when he had difficulty in passing water, for which he went to the London Hospital, where he was told that he had "something under the foreskin," and for it he was circumcised. The wound healed completely except in the middle line above, where a small granulating surface about the size of a split pea remained. Here a small "wart" developed, and six months ago a second "wart" developed by the side of the first. About two months ago the first-formed "wart" commenced to discharge, and this has continued ever since. The later formation he has regularly pared down with a knife. There are no other facts of importance about his personal or family history.

On the middle of the upper surface of the glans penis was a sessile truncated horn, hard in consistence, yellowish in colour and translucent, about the size of a marble. Posterior to this, over the site of the circumcision wound, was an ulcer of irregularly oval shape covered with warty granulations; posteriorly the edge was raised, while anteriorly it shelved off to the level of the glans; it was firmly attached to the deeper parts, and was of semi-cartilaginous hardness.

In each groin three inguinal glands could be felt, and one of them in the left side was distinctly harder than the rest. Both of the growths on the penis were tender and pungent. No other disease detected.

On December 20th I amputated the penis about one inch in front of the pubes, cutting a flap of urethra and stitching it over the face of the corpora cavernosa, and then removed all the inguinal glands on each side. He left the hospital well on January 11th,

and I have recently seen him quite well, and experiencing no difficulty in micturating.

Mr. Hudson has kindly prepared for me sections of the horn and of the ulcer and the glands. The horn shows the usual epidermic structure, the cells being flattened, nucleated, and arranged in regular superposed layers. No enlarged papillæ enter the base of the growth. The ulcer is a typical globular epithelioma. The glands do not show any secondary epithelial deposits.

The occurrence of horns in various parts of the body has excited interest from very early times. They are most common about the head and face, and are more frequent in women than in men. Several other cases have been noted on the glans penis, and this fact among others justifies the assertion that horns are met with in many of the favourite sites of epithelioma.

A Committee of the Royal Academy of Medicine of France[1] collected seventy-one observations of horny growths from the skin, of which three were on the glans penis. Sir Erasmus Wilson,[2] whose article on this subject is most useful from the numerous references it gives, was able to collect ninety cases, of which five were on the penis. H. Lebert[3] collected 109 cases of keratosis, with six on the penis. To those collected by Lebert, Hessberg[4] has added two, Hebra[5] one, Bergh[6] one, Pick[7] one, Wilson[8] one, Jewett[9] one, so that the specimen shown to-night is the fourteenth that I can find a record of. Some of these horns have reached a great size. Thus in Jewett's case the horn was three and a half inches long and three quarters of an inch in diameter; in Pick's case, drawings of which I hand round, the horn was at least two and a half inches long. In my case the patient regularly pared the corn down, and so prevented its attaining any large size.

Horns have been shown to start in three different ways; some grow from the interior of sebaceous cysts,—the most frequent

[1] 'Mémoires de l'Academie Royale de Médecine,' Juin, 1830.

[2] 'Diseases of the Skin,' 1867, p. 799.

[3] 'Ueber Keratose,' Breslau, 1864.

[4] 'Beitrag zur Kenntniss der Hauthörner am Menschen u. Thieren,' Göttingen, 1868.

[5] 'On Diseases of the Skin,' New Sydenham Soc., vol. iii.

[6] 'Archiv f. Dermatologie u. Syphilis,' 1873.

[7] Ibid., 1875.

[8] 'Diseases of the Skin,' 1867, p. 799.

[9] Erichsen's 'Science and Art of Surgery,' 8th edit., vol. ii.

mode of origin, and one that has been met with on the penis. Others develop from the matrix of nails; and a third class appear to be formed by some change occurring in the growth of warts. It is to this last group that horns springing from the glans penis belong.

Viewed histologically, horns may be divided into the papillary and the flat; the case in point is flat; Pick's case would seem to be a good example of the papillary variety.

There are three features of this case which illustrate important facts about horns.

1. The first is the development of the horn from a wart (in all probability) after circumcision, which necessarily somewhat desiccated the part. The effect of this desiccation has been often shown, thus one part of an ordinary papillary wart may, under its influence, develop into a horn. Wilson pointed out that a comedo when dried may grow into a horn, and he held that it was desiccation of a sebaceous cyst that induced the growth of horn from it; and cases quite parallel to mine in this respect are described by Pick and Jewett.

2. The second point is the association of a horn with epithelioma; this point has also been observed by others, and is mentioned by Mr. T. Smith and Mr. Godlee in 'Holmes's System of Surgery,' where it is pointed out that the horns generally grow from the thickened and tuberculated skin at the margin of a cancerous ulcer. Pick mentions the same association, and points out that horns and epithelioma have the same favourite sites. Sir James Paget remarks that "horns have a great tendency to be reproduced;" thus they possess one of the characteristics of epithelioma. The fact that the epithelioma developed along the line of incision through the prepuce is worthy of passing remark.

3. The third point is one that is closely connected with the two others; it is that the horn was preceded by a condition of phymosis; this was the case also in Pick's and Jewett's patients.

Thus horns have a close relationship with the three distinctive epithelial formations—the papillary, the cystic, and the epitheliomatous, the relationship being physiological or vital as well as merely anatomical.

Lebert mentions that horny growths have been observed on the penis of many animals. *February* 15*th*, 1887.

17. *Unilateral papilloma of tongue.* (*Card specimen.*)

By Frederic S. Eve.

The left half of a tongue with a papillary growth covering its posterior two thirds and extending from the middle line to the edge. The growth consists of coarse hair-like papillæ and projects considerably above the surface of the tongue. The mucous membrane covering the anterior third is thickened and corrugated.

The microscope showed an enormous increase in the epithelium of the tongue, which formed long papillæ covered with a thick layer of cornified epithelium. The inter-papillary processes of the epithelium were prolonged downwards and some of them contained cell-nests. The mucosa was infiltrated with leucocytes.

Removed from an Irishwoman aged 59, under my care in the London Hospital She had noticed white patches on the tongue for ten years. Twelve months before admission some "white pimples" formed on its left side and gradually grew. The teeth on the left side were very bad, and for many years she had been a great smoker, using a clay pipe which she held on the left side of the mouth.

Remarks.—The growth was a papilloma which was clearly becoming epitheliomatous, but no distinct transgression of the normal limit of the epithelium was observed. Considering the relative rarity of epithelioma of the tongue in women, it is significant that she was a smoker. *January 4th*, 1887.

---

18. *Large parotid tumour.* (*Card specimen.*)

By Sydney Jones.

This was removed from a lady aged 51, by Mr. Sydney Jones. It weighed, when first removed, 3 lbs. 7 oz. It had been growing for twenty-five years. A small lump about the size of a pea was noticed when the patient was twenty-six. The tumour had grown

steadily ever since but more rapidly during the last six months. Its removal was effected by two transverse incisions, so as to remove much excess of skin along with the tumour. The latter was pretty easily enucleated. The wound readily healed and there was a simple transverse line of scar. There was some little drawing of the mouth and loss of power on the side affected.

Mr. Shattock reported of the tumour that "it is of the usual kind; constructed of well-marked trabeculæ of fibrous tissue, enclosing spaces of considerable size, filled with cells. There is no cartilage present in any part of the growth." One half of the tumour is in St. Thomas's Hospital Museum, the other in the Museum of the Royal College of Surgeons. *May 17th*, 1887.

---

19. *Multilocular cystic tumour of the lower jaw.*

By Anthony A. Bowlby.

The patient from whom this specimen was removed was a married woman aged 29, who was admitted into St. Bartholomew's Hospital under the care of Mr. Walsham in February, 1886.

Her history was that five years previously she had been operated on by the same surgeon for a tumour, which at that time had been growing for seven years in the site of a broken left lower molar tooth. This, the original growth, had evidently developed in the substance of the jawbone, and had made its way to the surface, partly by causing absorption of the compact tissue on the anterior surface of the inferior maxilla, and partly by extending into the alveolus of the first molar. The growth was removed by a gouging operation, but was not examined microscopically.

On readmission in 1886 the left side of the inferior maxilla was found to be much enlarged, and occupied by a tumour which had evidently originated at the site of the previous operation. This tumour extended along the alveolar margin in such a manner that when the mouth was shut the growth covered the outer aspect of the upper molar teeth, and prevented complete closure of the jaws. The whole body of the inferior maxilla on the left side was

expanded by the tumour, which had at one place fungated through into the mouth. There were no enlarged glands in the neighbourhood, and the patient's general health was good. The operation of removal of the left half of the lower jaw was successfully performed by Mr. Walsham, the patient making a rapid recovery.

An examination of the specimen after removal shows that the whole of the body and the greater part of the ramus of the jaw are occupied by a new growth, which appears to have originated in the substance of the bone itself. The two bicuspids are firmly fixed in their normal position; the first and second molars are absent, but the wisdom tooth is thrust upwards by the growth, so that it now occupies the base of the expanded coronoid process. The body of the jaw is expanded by a tumour which has thinned and destroyed much of the compact bone. The growth protrudes on both surfaces of the lower jaw, and on the anterior aspect has infiltrated the masseter muscle. The anterior part of the ramus has been almost completely destroyed. The section of the body of the jaw shows that the tumour extended forwards as far as the canine tooth. The growth is soft and friable, in parts cystic, with its anterior margin definitely encapsuled. In the recent state the cysts contained a brownish, blood-stained fluid.

Microscopic examination shows a fibrous stroma containing masses of epithelial cells. The outermost of the cells in each mass are chiefly columnar, the more central ones squamous. The central cells tend to become vacuolated and to break down, thus forming the cysts already mentioned. There are no cell-nests.

March 15*th*, 1887.

---

20. *Malignant cysts of the neck.*

By Frederick Treves.

[With Plate XXII, figs. 2 to 4.]

The cases that are herein described may be considered as affording examples of a very rare form of cervical growth. Although the pathogenesis of these tumours is quite obscure, yet their clinical features are so alike that they may well be described under

one term. The completeness of the clinical likeness is the more striking since the tumours differed entirely as regards the nature of their contents and the histological structure of their walls.

The first case is that of a cellarman aged 53, who was admitted into the London Hospital on August 27th, 1885, with a tumour of the neck. He was a somewhat stout man, with fair muscular development. He was a trifle anæmic, and his face appeared a little puffy He had enjoyed all his life exceptionally good health, and could not remember that he had been ever laid up. He had had no sore-throat nor any previous swelling in the neck. He had never had syphilis, was not the subject of rheumatism, and had been always a most temperate liver. The swelling in the neck was first noticed eight weeks ago, when he discovered by accident a hard mass about two inches below the left ear. The tumour grew steadily and extended lower down in the neck. It always felt quite immovable. As it increased in size it became softer. On admission there appeared on the left side of the neck, under the centre of the sterno-mastoid muscle, a swelling the size of a large goose's egg. It was very fixed. Its general shape was roundish, but its outlines were a little indistinct. It did not move during deglutition, and was clear of the thyroid body. The skin covering the mass was red and slightly œdematous. The tumour presented distinct fluctuation, but the periphery of the swelling was no denser than the central parts. The tumour was not tender, and the patient experienced no difficulty in moving the neck. Sharp pain had been felt along the supra-clavicular, great auricular, and small occipital nerves. The temperature was normal. An examination of the mouth, pharynx, and larynx revealed nothing abnormal. The swelling was considered to be a chronic abscess. It was punctured with a trocar, but in the place of pus there escaped 3 oz. of clear mucoid fluid. This material was of a pale yellow colour, and in consistence thick and glutinous. It drew out into glairy threads between the fingers. It became solid on boiling; became thin and watery when mixed with liquor potassæ, and was coagulated by acetic acid. It presented, indeed, the chemical characters of mucin. Microscopically, nothing was discovered except a few blood-corpuscles, many leucocytes and some granular matter. The cyst appeared to be entirely emptied by the tapping. Some solid swelling remained, but it was

no more in amount than would have been accounted for by the cyst wall. The cavity rapidly refilled, the skin became redder, and the parts around more swollen. The temperature rose, and on the fifth day after the tapping I opened the cyst freely under chloroform. The fluid that escaped was now muco-purulent. A large cyst was discovered with thick and regular walls. The interior of the cavity was smooth. The tumour lay under the sterno-mastoid and extended down to the thyroid body. A large drain was inserted, and the cavity was well washed out daily with a solution of iodine. The discharge now became entirely purulent and considerable in amount. A splint similar to that I employ in cases of scrofulous neck was applied. The temperature kept high, the patient became anæmic and weaker. He was not, however, confined to bed until October 15th, about six weeks after the first tapping. At that time the discharge was very profuse, and the undermined skin about the wound was beginning to break down. Throughout the temperature had ranged between 99° and 102°. On October 19th for the first time bleeding occurred from the cyst. The cavity was plugged with perchloride of iron. The bleeding recurred next day, was very free, and led to pronounced anæmia and great prostration. The neck was now swollen, red, and œdematous. The swelling was diffuse, and could not be defined. There was slight dyspnœa. The patient was much wasted.

The hæmorrhage did not recur, but the patient became weaker and weaker, diarrhœa set in, and the man died of exhaustion on November 5th, about seventeen weeks after the swelling was first noticed.

Autopsy.—The cyst extended from the hyoid bone to the clavicle; it was placed beneath the sterno-mastoid, and rested upon the left lobe of the thyroid body and the thyro-hyoid muscle. It had no connection with the thyroid gland, the left lobe of which was flattened and greatly wasted. The cyst wall appeared to have infiltrated the tissues. Although it could in no place be separated from the parts around, yet its limits were fairly defined. The wall was about half an inch in thickness, was on section white, fleshy, homogeneous, and evidently vascular. The interior of the cyst was very irregular, and the lining wall closely resembled that of the left ventricle of the heart, being thrown into numerous bar-like ridges. Near the opening into the cyst there was much granulation tissue, and from thence the pus had no doubt been

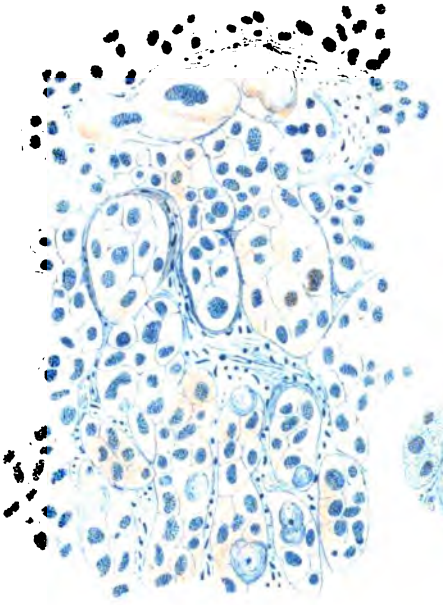

Fig. 2

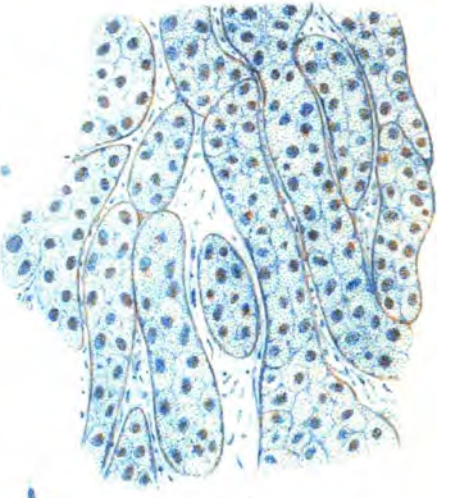

Fig. 3

Fig. 1

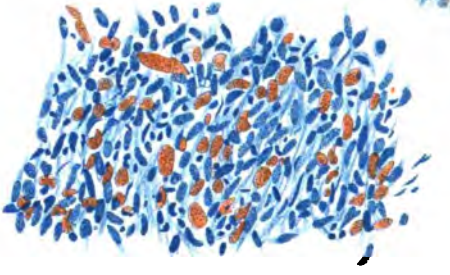

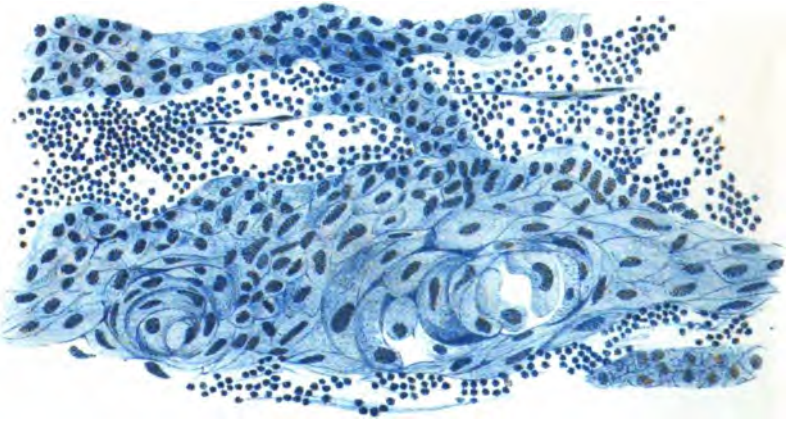

F. Treves del.

Fig. 4.

Mintern Bros. Chromo lith.

DESCRIPTION OF PLATE XXII.

To illustrate Mr. Treves's papers on Melanotic Sarcoma (page 350), and on Malignant Cysts of the Neck. (Page 360.)

From drawings by himself.

FIG. 1.—Section of melanotic sarcoma of the hard palate.

FIG. 2.—Section of the wall of a malignant cyst of the neck. The general arrangement is that of a carcinoma. Many cells are undergoing mucoid degeneration. At the upper part of the specimen is a large collection of mucoid or colloid matter.

FIG. 3.—Section of the wall of a malignant cyst of the neck. Carcinoma. The arrangement of the cells in alveoli or columns is well marked. The cells exhibit no morbid change.

FIG. 4.—Section of the wall of a malignant cyst of the neck, showing the structure of an epithelioma.

derived. The rest of the cavity was quite free from granulations, and perfectly smooth.

The three carotid arteries were embedded in the cyst wall, but their lumina remained clear. The superior thyroid artery was lost in the growth, and it was from this vessel that the bleeding had occurred. The internal jugular vein was obliterated in the greater part of its extent. The superior laryngeal and sympathetic nerves were sound, but the vagus—just below the carotid bifurcation—was lost in the mass, and so well obliterated was it that no trace could be followed on careful dissection. The patient had never presented any symptoms of irritation or paralysis of the cervical sympathetic; he only had dyspnœa when the swelling in the neck was excessive, was never sick, and had no symptoms that would suggest a lesion of the vagus. There were no enlarged glands in the neck, and no secondary deposits in any organs. The viscera were quite healthy.

On microscopic examination the tumour presented the features of a carcinoma. The cells were large and rounded, but altered in outline by mutual pressure. They were distinctly epithelioid in character. The alveoli were somewhat ill marked, and the stroma scanty. The alveoli were so disposed that the cells were grouped for the most part in the form of elongated cylinders. The cells were in many places undergoing mucoid degeneration. Rounded masses of mucoid material filled some of the cells, and larger masses occupied whole alveoli. It appeared evident that the degeneration concerned the cell originally, and not the intercellular tissue. The larger masses of mucoid matter appeared as clear homogeneous districts marked by a faint but regular concentric striation. In some of these nuclei remained embedded (Pl. XXII, fig. 2).

It would appear that in this case the cyst was due to the mucoid degeneration of a carcinoma. From what tissue that carcinoma had origin must be a matter of pure conjecture. It certainly did not arise from the thyroid body, or at least not from the main part of it. It might possibly have arisen from the so-called "superior accessory gland."

This gland has been lately elaborately described by Streckeisen ('Virchow's Archiv,' Jan., 1886). It appears to be due to separation of a pyramidal process from one of the lateral lobes of the thyroid body. In old persons especially is the process apt to be found detached. It must be, however, noted that the structure of

the present tumour did not conform to that of the thyroid body, although in malignant growths from that organ it is usual to find the epithelium conforming in some extent to the cell arrangement found in the normal thyroid. Streckeisen, however, has also described a number of glandular bodies about the hyoid bone, from one of which the tumour in this instance may well have taken origin. These bodies represent the remains of the central diverticulum which is protruded from the ventral wall of the pharynx, and from which the middle part of the thyroid gland is formed. Both Streckeisen and His ('Anatomie menschlicher Embryonen') have pointed out that the foramen cæcum of the tongue indicates the spot where this diverticulum leaves the pharynx. In one case, indeed, a duct was found leading from the foramen cæcum to an epi-hyoid gland body. There is therefore no lack of epithelium from which it is possible that this carcinoma may have taken origin. Failing this source there are still the epithelial masses and cords that have been discovered in the neck as the remains of imperfectly closed branchial clefts, and from such epithelium the present growth may have arisen. Finally, Streckeisen states that he has often found small cysts about the hyoid bone lined with ciliated epithelium.

With regard to the mucoid degeneration of the tumour one surmise may be hazarded. The left lobe of the thyroid was found to be atrophied, a condition that had no doubt been produced by pressure. There is evidence to support the view that the thyroid body controls the formation of mucinoid substances in the body and takes a part in albuminoid metabolism. The association between myxœdema and atrophy of the thyroid has been made evident. It may be a legitimate conjecture, that in the present case some connection existed between an extensive local mucoid degeneration and a wasting of a lobe of the thyroid. That a rapidly growing, active, and vascular mass of embryonic tissue would be peculiarly sensitive to any modification in metabolism may be allowed. In the present instance it would have to be assumed that the tumour was at first solid, and that as it caused wasting of the thyroid by pressure the degeneration of its substance took place. The smooth and distinct lining wall of the cyst is a little difficult to explain. The mucoid matter did not occupy the centre of a broken-down mass. It was clear and free from débris, and after its evacuation a simple cyst wall remained.

From a clinical point of view, the close resemblance of this cyst to a chronic abscess is worthy of special notice.

The second case is identical with that just described, so far as its pathological characters are concerned. In it, however, the cystic element did not predominate. The patient was a woman aged 52, who was admitted into the London Hospital in November, 1885. She described herself as having been always strong and vigorous. She had had several children, all of whom were healthy. There were no evidences of syphilis. A very large tumour occupied nearly the whole of the right side of the neck. In front it reached to the middle line. Behind, it had extended back nearly to the anterior border of the trapezius muscle. Its upper extremity was one and a half inches from the lower jaw, and below it was in contact with the clavicle. The skin covering it was thin and of a dusky red colour. In two spots the integument had given way, and the growth was exposed, and had commenced to fungate. Each of these districts was about the size of a shilling piece. The skin was not adherent to the tumour, nor was it in any way infiltrated. The mass was fairly fixed, was placed beneath the sterno-mastoid muscle, and had pushed the trachea over to the left side. The posterior part of the growth was hard and resisting, but over that part of the tumour that extended between the centre of the sterno-mastoid and the middle line there was distinct deep fluctuation. The mass was displaced laterally on swallowing, and appeared to move a little in the vertical direction. No enlarged glands were discovered. The patient had first noticed the tumour six months ago. It then appeared as a small hard mass about the size of a walnut, which was placed under the centre of the sterno-mastoid muscle. From this point the tumour grew in all directions, but especially downwards and backwards. For three months the woman remained in good health, and the growth caused little or no inconvenience. After that time, however, the tumour began to grow rapidly. It caused very intense pain, she became gradually weaker, and lost flesh. The skin over the swelling had only given way a few days before admission.

When first seen the patient was weak and anæmic, and greatly wasted. The pain—produced apparently by pressure upon the cervical and brachial plexuses—was severe and constant. An examination of the viscera and of the rest of the body revealed nothing abnormal. There had been no hæmorrhage from the

tumour. The temperature ranged from 99° to 100°. The diagnosis of sarcoma was made. As the patient clamoured for operation, and as the growth appeared to be well encapsuled, I attempted to remove it. The incision extended from the jaw to the clavicle. The external jugular vein was found obliterated. The wasted sterno-mastoid was cut through. The whole of the outer part of the tumour was well encapsuled, and was so readily exposed that it appeared at one time as if the whole mass would shell out with perfect ease. The deeper parts of the growth, however, had infiltrated the tissues. The great vessels were adherent to it. The carotids were bared, the internal jugular vein had to be divided and its cut ends ligatured. The brachial plexus was exposed by the dissection. The growth was adherent to the larynx, trachea, and œsophagus, and in this direction it was obvious that complete removal was impossible. The amount finally left behind was inconsiderable. No enlarged glands were met with, and there was no trace of the right thyroid lobe. Little blood was lost during the operation, and none subsequently. The patient remained profoundly exhausted after the operation, and from this exhaustion she never rallied. She became very restless, and finally died three days after the tumour had been removed. An autopsy was not allowed.

The greater part of the growth was provided with a thin but distinct capsule. It was only at what may be termed the pedicle that infiltration had taken place. It was evidently at this point, which would be represented by the tissues immediately under the centre of the sterno-mastoid, that the tumour had its origin. The posterior part was solid, the anterior cystic. The solid portion represented more than two thirds of the entire tumour. This segment was firm and on section precisely resembled the cyst wall in the previous case. It was pale, homogeneous, and fleshy. The cystic part was composed of a single large cyst with many loculi. The lining membrane was smooth. The cyst wall varied in thickness from 2 or 3 lines to nearly half an inch. The fluid evacuated was of a pale yellow colour, quite clear, and in consistence thick and glutinous. It amounted to 2½ oz. and was identical with the material discharged in the previous case. A microscopic examination of the solid parts and of the cyst wall revealed the same structure as that already described,—large epithelioid cells lodged in alveoli. The stroma was so arranged that the cells appeared grouped in elongated cylinders, and so narrow were these cylinders that in the majority

there were only two cells abreast (fig. 3). There was no reason to suspect the existence of secondary deposits in any part.

This case would not rightly be included among malignant cysts. The solid part of the growth predominated. It is recorded, however, because it serves to illustrate and supplement the case first described. In structure and in the nature of the cystic contents the two were perfectly identical. They sprang from the same region although not from the corresponding side of the neck. In both instances one lobe of the thyroid body had been practically destroyed. In the one case it had wasted from pressure; in the other it had been invaded by the growth. In both instances mucoid degeneration had occurred. In both also the general clinical character of the growths was that of sarcoma, while from microscopic examination it appeared that they should be classified as carcinomata. It is well to note also that the cyst was provided with a distinct smooth lining wall and that the mucoid matter it contained was unmixed with débris.

The third patient was a painter aged 43, who was admitted into the London Hospital in May, 1884, with epithelioma of the tongue. The man was in fair health and there was no evidence that he had ever been the subject of syphilis. The ulcer was quite small and was limited to the right border of the tongue. The anterior extremity was three quarters of an inch from the tip of the organ. The rest of the tongue was healthy. The ulcer had existed for four months. A small indurated gland was to be felt under the right lower jaw. Nothing could be detected in the left side of the neck. As a precaution the patient was treated for three weeks with iodide of potassium in increasing doses. The ulcer was not affected thereby. The patient had never suffered from lead-poisoning.

In June I ligatured the right lingual artery in the neck and removed the whole of the right half of the tongue with scissors. In exposing the artery the enlarged gland was encountered and removed. No other gland was detected. The ulcer was found to be quite limited to the margin of the tongue. The wounds healed well and the patient left the hospital in fourteen days to resume his work. He returned again in August, 1885, some fourteen months after the operation. In the interval he had felt well and had been regularly engaged in work. The tongue was quite sound. The wound on the right side of the neck was well healed and no glandular enlargement could be detected beneath it. There was

now in the *left* side of the neck a swelling the size of a duck's egg. It was placed beneath the sterno-mastoid, extending nearly to the mastoid process and to within one inch of the median line. The muscle was stretched over it and made to deviate a little. The mass was firmly fixed, was tense, and presented a sense of fluctuation. The limits were ill defined. The skin over it was neither red, œdematous, nor adherent. No enlarged glands could be felt about the tumour. The mass was a little tender, but painless. The movements of mastication and of swallowing were performed without difficulty. The neck was kept stiff and much pain was felt along the superficial cervical, great auricular, and small occipital nerves. The temperature was normal. The patient's teeth were much decayed, but nothing abnormal could be detected in the mouth, tongue, nose, nor in any part of the periphery with which the cervical glands are concerned. The man was not anæmic nor had he lost flesh. The swelling was discovered by accident two months ago. It was at first hard. As it enlarged it became softer.

At the end of a week the swelling had increased in size, fluctuation was very distinct, and I imagined the case to be one of abscess. On introducing a trocar into the cyst 3 oz. of clear yellow serous fluid escaped. A drachm of iodine was injected, and the cannula removed. The fluid presented the physical and chemical characters of lymph. Under the microscope a few leucocytes were observed. After standing for a while a very slight flocculent deposit formed. This was found to be composed mainly of epithelial cells, some free, others collected together in masses.

In a few days the cyst had regained its original size and produced much distress. Thereupon I laid it freely open under an anæsthetic. Several ounces of a lymph-like fluid mixed with iodine escaped. On examination the cyst was found to lie in the connective tissue under the sterno-mastoid. Its lining membrane was quite smooth and even except at one spot on the deeper wall. Here, over an area of about one square inch, a hard, projecting, cauliflower-like mass could be felt. No bleeding followed the examination. The patient seemed for a while much improved and from the tube introduced into the cyst a little flaky pus escaped. There was no oozing of serous fluid. Fourteen days after the incision the patient had a slight rigor, and the temperature—that had up to this time been normal—rose to 102°. He rapidly lost flesh and strength, his appetite entirely failed, and he was troubled with profuse sweatings.

He had no repetition of the rigor. His urine was healthy and nothing abnormal could be detected in any of his viscera. The incision still discharged a little pus, but the site of the cyst was now replaced by an indistinct solid mass. The patient developed a slight cough and had some trouble in swallowing and breathing. Within eight days after the rigor the man was greatly prostrated. His temperature remained between 99° and 100°. Venous bleeding now occurred from the wound. The cyst filled with blood and extreme dyspnœa resulted. All attempts to arrest the bleeding failed and after it had continued for twelve hours the patient died.

Autopsy.—The body was much emaciated. In the apex of the right lung two small cretaceous nodules were found. With this exception all the viscera, apart from being anæmic, presented a normal appearance. No secondary deposits of any kind could be found. The cyst was filled with blood-clot and the larynx pushed over to the right side. On removing the clots the larynx returned to its normal position. The cyst was oval in shape and extended from the mastoid process to within a short distance of the clavicle. It reached in front nearly to the middle line and behind to the posterior border of the sterno-mastoid muscle. It was quite free of the thyroid body. Near the lower end of the cyst one small indurated gland was found. It was softened in its centre and appeared to be breaking down. This was the only enlarged gland detected in the body, and it might here be said that its structure was identical with that of the cyst wall. The interior of the cyst was irregular and its surface was thrown into distinct but smooth ridges very like the columnæ carneæ of the ventricle. In this respect the three cysts were singularly alike. The three carotid arteries could also be felt through the parietes as three wide cords. Over about one third of the lining wall was a cauliflower growth that was evidently epitheliomatous. The cyst wall varied in thickness from one eighth to one sixth of an inch. On section it was dense, fibrous, yellowish and homogeneous. It was most intimately blended with the structures in its vicinity, although it had invaded the muscles to a less degree than the connective tissue and blood-vessels. It had spread a little into the parotid gland. The walls of the carotid vessels were invaded, but the lumina of those trunks were free. The superior thyroid, lingual, facial, and occipital arteries were buried in the cyst wall and were entirely occluded. The vagus nerve was also embedded in the new

growth. The hæmorrhage had occurred from the internal jugular vein. This vessel was thrombosed above the bleeding point but free below it. The larynx and gullet were free from disease and no enlarged glands could be found in the mediastina. There was no appearance of any return of the cancer in the right side of the tongue nor in the right side of the neck. A careful examination of the tongue revealed nothing abnormal. In the excision the median line had not been transgressed.

A microscopic examination showed that the tissue of the cyst wall was the tissue of an epithelioma. Between the cylinders and masses of epithelium there was a fair amount of small cell growth. There were the usual epithelial "nests" (fig. 4). The precise character of this malignant cyst must be open to a certain amount of doubt. It would be fair to assume that it was a secondary growth following upon the epithelioma of the tongue, and that it had taken its origin in a lymphatic gland. It is remarkable that such a deposit should have occurred on the left side of the neck, while the primary epithelioma was entirely limited to the right side of the tongue. The phenomena, however, could be explained by supposing some unusual anastomoses of the lingual lymphatics. A like cross-infection has been met with in the groin in association with syphilitic sores upon one side of the penis.

The formation of the cyst I imagine to be due to some peculiar obstruction to the lymph current. Of the manner in which the lymph circulation is affected in the early stages of secondary gland enlargement we know nothing. The possibility that lymph may have still been poured into the gland after it had become the seat of an epitheliomatous deposit cannot be denied. There is no reason to suppose that the fluid had escaped from the growth, and no evidence to show that it was derived from the breaking down of the same. The rapid progress of the tumour is worthy of note. But for the strong probability that the mass was of secondary formation it would be interesting to speculate upon its connection with some of the epithelial collections often met with in the neck as the result of incomplete development, and especially with the occasional duct that Streckeisen describes as running from the foramen cæcum to the vicinity of the hyoid bone. If this last case and that first described are compared the resemblance between the two is very striking. The patients were adult men; the tumour was upon the left side of the neck; the rate of growth was about the same;

the time that elapsed between the discovery of the mass and the death of the patient was thirteen months in one instance and seventeen in the other; in both cases the local manifestations were those of abscess, and in both the patients died of hæmorrhage; the tumours were quite local; there were no secondary deposits; and the growths had both sprung from corresponding regions in the neck.

While the clinical likeness was singularly complete, the histological differences were as singularly marked. One was an epithelioma, the other a spheroidal-celled cancer. One was apparently a secondary growth, the other was primary. In one the contents were lymph-like, in the other mucoid.

In the first and second cases the clinical features of the growth coincided with those of sarcoma rather than with those accredited to cancer. The disposition to infiltrate was not marked. One tumour was partly encapsuled, and was fungating through the skin, although it had not infiltrated it. There was no glandular enlargement in either instance.

Cases such as these serve to show that the histological classification of tumours is not all-sufficing; they illustrate the common experience that the clinical and pathological conditions of tumours do not always coincide as they ought. These particular examples, moreover, would seem to support Mr. Hutchinson's plea for a classification of growths upon clinical and local grounds.

The cysts here described are certainly rare, and I have not been able to find, in the many works on pathology I have consulted, an account of cystic tumours that would be quite applicable to these particular examples.

The whole subject of malignant growths of the neck is one that is in need of systematic treatment.

The 'Transactions' of this Society contain two remarkable examples of cystic epitheliomata. One case, reported by Dr. Seymour Sharkey,[1] concerned a man aged 43. Three tumours appeared in the subcutaneous tissues of the body—two on the head and one near the umbilicus. They had not grown from the skin, and were apparently primary and independent of one another. They proved to be squamous epitheliomata, and on being cut into gave exit to a thick, brownish fluid, which contained innumerable cells and many cell "nests."

[1] Vol. xxxv, 1884, p. 374.

Like cystic tumours were found in the liver and other organs. Dr. Sharkey considered the cysts "to be due simply to solution of the tissue which originally kept the epithelial cells together," so that the latter were found floating free in the fluid which filled the cysts. The same explanation could hardly apply to my case, since the lining of the cysts was very distinct, the fluid was clear and thin, and contained scarcely any cell elements.

The second case is reported by Mr. Godlee.[1] The patient, a man aged 56, had an epithelioma of the left side of the tongue. There were enlarged glands on the neck, and near the sternum a brawny fluctuating tumour formed. This was supposed to be an abscess, and was incised. Nothing escaped but "a clear fluid." After the patient's death secondary deposits were found in the skin, liver, lungs, and other viscera. The mass at the root of the neck had perforated the manubrium sterni, and was continuous with enormous spreading growths that occupied the anterior mediastinum, and, extending up into the side of the neck, encased the great vessels. The central portion of the mass that had been incised was soft, and contained an opaque, serous fluid. "Just as the large mass over the manubrium sterni had broken down in the interior into an irregular cystic cavity, so had the process repeated itself, even in the most minute tumours that were found elsewhere .... even the smallest tumours showing this remarkable tendency to soften in the interior." Mr. Godlee's case bears a very near resemblance to the one I have described. In my case the cyst wall was a little too precise to suggest that the cavity was due to the breaking down of the new growth. In both cases the fluid was clear and serous. In the enlarged gland that existed below the cyst in my patient there was evidence of breaking down in the centre, just as in the secondary deposits in Mr. Godlee's case.

A third case in the 'Transactions' of the Society may possibly be allied to the epitheliomatous cysts described. It is recorded by Dr. Morell Mackenzie,[2] and concerns a man of sixty who had an epithelioma of the *right* side of the epiglottis, followed by a tumour in the *left* side of the neck. The glands upon both sides of the neck were enlarged. The tumour was the size of an orange and pressed upon the larynx and pharynx. It proved to be a cyst

[1] Vol. xxxii, 1881, p. 27.

[2] Vol. xix, p. 61.

filled with fluid. From an unfortunate accident the cyst and the contents were not examined.

Some striking examples of epitheliomatous cysts of the neck have been furnished by French surgeons. Lebert[1] reports two. In the first case the patient was suffering from cancer of the gullet. The glands in the neck were enlarged, and the most prominent of these secondary masses was found to be cystic and to be filled with a yellow transparent fluid. In the second case there was an epithelioma of the lip and lower jaw. Many enlarged glands existed in the neck, and of these three were converted into cysts that contained a clear yellow fluid. Lebert has no doubt of the origin of these cysts from glands.

An interesting but somewhat obscure case is reported by Richard.[2] It concerns a man aged 45, who presented a large tumour in the left side of the neck the size of the fist. It had been growing for seven months. It was in the form of a cyst and contained transparent serum. The solid part resembled the tissue of a lymphatic gland. There were enlarged glands in the neck, some of which were also cystic. An excellent plate of the parts concerned is added to the paper.

It may here be observed that Cloquet, Nélaton, Lücke, Klebs, and others believe that certain cervical cysts are developed from lymphatic glands or lymph trunks.

Muron[3] records a case of Verneuil's that has some resemblance to my case of carcinomatous cyst. The tumour was the size of a turkey's egg, and was removed from the supra-clavicular region. It was very adherent to the parts around, and was removed with difficulty. It was entirely cystic and contained a reddish fluid. The inner surface of the cavity was thrown into irregular ridges and closely resembled the interior of a ventricle of the heart. The walls of the cyst varied in thickness from 3 to 6 mm., and presented fusiform cells with a tissue like that of a lymphatic gland. The report is exceedingly scanty. *October 19th*, 1886.

[1] 'Mém. de la Soc. de Chir. de Paris,' 1852.

[2] Ibid.

[3] 'Comptes-rendus de la Soc. de Biologie,' Aug., 1870, p. 149.

21. *Three cases of cystic epithelioma of the neck.*

By A. Quarry Silcock, B.S.

The two specimens shown may be of interest to the Society, since they belong to the same category of cases as those cited by Mr. Treves a few weeks since. It may be within the recollection of the Society that Mr. Treves then drew attention to a certain class of primary tumours of the neck, which were cystic, of rapid development, and having all the clinical characters of local malignancy, although not associated with secondary or metastatic growths. In two of his cases the histological characters of the tumour growth were those of a squamous epithelioma, and another, although less definite, may not improbably have been of the same nature.

Case 1.—Henry D—, aged 32, was admitted into St. Mary's Hospital under the care of my colleague, Mr. Owen, on October 14th, 1886, having a large inflamed and suppurating swelling under the lower third of the left sterno-mastoid. He was a strong, healthy-looking man, who had lived most of his life in Ceylon, having returned to England three months before admission. Shortly after his return home, a small lump appeared at the lower and front part of the neck; it grew in size and was very painful, whilst he began to lose flesh and became generally weakened. The swelling was lanced by a surgeon outside the hospital, but the supposed abscess did not cease to suppurate, consequently the man was sent into the hospital. Mr. Owen, on two different occasions, scraped away large portions of the growth with relief to the patient, but he ultimately died on June 19th, 1887.

No *post-mortem* was allowed. I removed, however, as much of the tumour as I could without disfiguring the body. The growth occupied the left anterior and posterior triangles of the neck, chiefly the anterior, and evidently infiltrated most of the structures entering into these regions. It presented a cystic cavity, lined with large papillary or cauliflower-like granulations, many of which were the size of a filbert, or larger.

Microscopically, these papillary growths consisted almost entirely of epithelium cells, the most developed of which were evidently of

the squamous type (but not "prickled"), forming well-marked "nests," whilst long columns of like cells radiated into and formed the mass of the tumour. Some swollen lymphatic glands lying over the tumour were examined microscopically, but these showed no signs of secondary infection.

CASE 2.—Charles R—, aged 56, was admitted to St. Mary's under the care of my colleague, Mr. Pepper, on December 4th, 1886, presenting a large tumour, partly solid, partly cystic, of the right side of the neck. About five months previously the patient had noticed a small lump in the position of the tumour, then about the size of a marble. This was quite hard and occasioned no inconvenience; it appeared to remain stationary for a time, but it began to grow rapidly after a fall (such is his account of the matter) which occurred two months after its first appearance. At the same time he began to lose flesh, and when admitted was evidently much emaciated. The tumour at this time was about the size of a cricket ball.

The swelling was incised and a quantity of glairy, yellow fluid escaped, and the cystic cavity, the inner wall of which presented similar large papillary granulations or cauliflower-like growths to those described in the previous case, suppurated and discharged freely up to the time of the man's death on January 17th, 1887.

At the *post-mortem*, the growth presented appearances, both to the naked eye and microscopically, identical with those described in the last case, though perhaps it was somewhat less extensive, and occupied the right side of the neck. Some small lymphatic glands lying on the surface of the growth and partly adherent to it, were, when examined microscopically, found to be simply inflamed, otherwise unaffected.

CASE 3.—A man aged 64, was admitted to St. Mary's on December 24th, 1886, under my own care. He presented a large tumour of the left side of the neck, the mass of which lay beneath the sterno-mastoid muscle, but encroaching both on the anterior and posterior triangle; it extended from the jaw to the clavicles, and reached as far forwards as the middle line, as far backwards as the mastoid process.

He had noticed the swelling about four months before I saw him, which, at that time about the size of a walnut, had gradually

increased in size. It was neither painful nor tender, but the skin over it was reddened, and at first sight I thought it was an abscess.

I tapped it on several occasions; in the first place with a view to diagnosis, and afterwards to relieve the tension to which the superjacent skin was subjected. I drew off thick yellowish grumous fluid, in which on microscopic examination numbers of large epithelium cells were present, so that I cannot doubt but that the growth is of the same kind as that in the other cases which I have narrated. Unfortunately, the patient, when told that nothing could be done for him, left the hospital, and is now too ill to be present, as I had hoped he would be.

The pathological relations of these growths, which do not seem to be very uncommon, are not easy to unravel. In none of the cases related was there any suspicion or evidence of a growth or growths besides that in the neck, although I carefully sought for such. One is almost driven to the hypothesis that they may owe their origin to the development of some belated portion of epiblast, perhaps the representative of a branchial cleft, although the advanced age of the individuals in whom they are usually found may appear to negative such a supposition.

March 15*th*, 1887.

---

22. *Recurrent epithelial tumour of foot.* (*Card specimen.*)

By S. Paget, for Mr. Thomas Smith.

From a female patient aged 55. Primary growth removed fourteen months ago from inner side of foot. Not attached to bone. Recurrent growth removed by amputation of the foot; a mass of diseased femoral glands also removed.

Section of femoral gland shows masses of flat epithelial cells, in a rapidly growing stroma of connective tissue. The growth in the foot was attached to the deep fibrous tissues, but not to bone

December 21*st*, 1886.

23. *Carcinoma myxomatodes.* (*Card specimen.*)

By WALTER EDMUNDS, M.D.

THE specimen is a microscopic section from a tumour about the size of a chestnut removed from the breast of a woman aged 60; the tumour had been noticed three months. To the naked eye a section of the tumour had a colloid appearance.

Microscopically, it was seen to be scirrhus, but the stroma consists of mucous tissue in which capillaries occur; the whole of the stroma is of this nature. Some of the cancer-cells in the loculi have undergone a colloid change.

A similar tumour is described and figured in 'Ziegler's Pathology' (MacAlister's translation, vol. i, p. 243), and a tumour of the same nature was exhibited to the Society by Mr. Eve last session ('Path. Soc. Trans.,' vol. xxxvii, 1886, p. 493).

April 5th, 1887.

---

24. *Some intra-bursal growths.*

By G. H. MAKINS.

THE exhibition of the tumour just described by Mr. Jones[1] (fibroma of tendon sheath) seems a suitable occasion to bring forward some cases of probably a similar nature, affecting the bursæ. These are, I think, of interest, not only in connection with Mr. Jones's case, but also as bearing on the whole question of tumours of synovial cavities. I am the more encouraged to do this, as although some mention of changes of a similar nature is made in the text-books, I find no description of any so well-developed specimens as those before you. I may say that on looking through the Society's 'Transactions' only seven cases of morbid changes in bursæ are recorded, and of these only one, an unusually large cyst, during the last twenty years.

[1] See p. 324 *ante*.

The first specimen is one which has been in the museum of St. Thomas's for some years, and no clinical details of the case are forthcoming, except that it was removed with the bursa in front of the patella.

It consists of a portion of the bursal wall, from the inner surface of which numerous pedunculated growths project, while on the outer aspect a number of prominences appear which correspond to folds and depressions of the bursal wall.

On examination, the papillary growths are seen to vary in shape and size; some are simple, others compound, while a third variety consist of long branching processes, some free at one end, others attached at both extremities, and from the surface of these again small papillary growths project. The growths are all pedunculated. Besides the larger growths a portion of the lining membrane, which in the spirit preserves a darker colour, is thickly studded with small villi, large enough to be easily recognised by the naked eye. The surface is for the most part smooth, but in places, and especially over the villous processes, a thin coagulum exists. The projections on the outer surface are rough from having been dissected from their connections; the section of one of them shows it to be a hernial pouch.

Microscopic examination of one of the pedunculated growths shows it to be composed of adipose tissue with a firm fibrous capsule and peduncle.

The second specimen is also from the leg. It arose in connection with the tendon of the biceps muscle, and was removed by Mr. Sydney Jones, by whose kind permission I exhibit it this evening.

It occurred in a youth of seventeen, and had gradually developed during the preceding seven years. The only symptom complained of was some stiffness of the calf. It projected as a considerable tumour, and stretched downward three and a half inches from the insertion of the biceps. It felt hard but elastic, and was fixed very deeply; the skin was free.

When removed it was distinctly encapsuled, lobulated on the surface, and from its posterior aspect several small round nodules projected. One or two of these seemed to have pushed beneath the external lateral ligament of the knee-joint.

On section the capsule, which was formed by the bursal wall, is seen to contain numerous proliferous growths varying in size from that of a large nut to a mustard seed. The cut surface of these is

very firm, and in the fresh state was of a whitish grey colour and rather greasy.

Microscopic examination shows the growths to consist of firm fibrous tissue.

The third specimen shows a large cystic bursa, with a small localised fibroma in its outer wall. This is not exactly the type of specimen I wished for to institute the parallel I am about to make since here the cystic enlargement is the more striking change, but I use it merely to illustrate the fact that in some cases the development of fibrous tissue may be so localised as to be an actual fibroma, the bursal cavity being little enlarged, and showing on section as a mere slit situated at comparatively the peripheral part of the tumour. I have notes of such a case which occurred in connection with the bursa beneath the ligamentum patellæ, but unfortunately did not save the specimen. I would remark with regard to that tumour and to one already exhibited (No. 2) that both were connected with the insertion of tendons, and it would seem possible that their growth may in some measure be due to the constant pressure exerted on them when enlarged, by the tendons crossing them.

No. 4, one of a series of beautiful sections made by Messrs. Shattock and Reid for the St. Thomas's museum, exhibits the papillary form of growth in its simplest form. It is an excellent example of the small growths, which may become detached to form one variety of the so-called melon-seed bodies.

The interest of these specimens seem to me to lie in the fact that here we have examples in bursæ of certain new growths met with in joints and tendon sheaths.

No. 1 illustrates the growth of the so-called lipomata, and I think explains by strict analogy the occurrence of these tumours in the palm and sole in connection with the tendon sheaths, and also of those occasionally met with in the joints. The development of fatty growth in the light of this example is much more simply explained by the hypertrophy of a synovial fringe than by the somewhat ingenious suggestion of König and Riedel,[1] who supposed that a trauma has led to a rupture of the synovial capsule, and a hernia of the subserous fat.

Another point of great interest in this specimen are the small

[1] 'Erfahr. aus der Chir. Klinik zu Göttingen,' 1882, p. 5; Lauenstein, 'Central. d. Chir.,' 1884, p. 836.

pouches existing on its external aspect, which I would venture to suggest are strong evidence of the occasional hernial origin of simple ganglions of tendon sheaths.

Again, assuming some of these to contain similar pendulous growths (as is in fact the case in this example), should such growth attain any size a lipoma would be developed, which might be removed without exposure of the tendon, and which might therefore be looked upon as independent of the sheath.

No. 2 in like manner I think illustrates the development of fibromata in tendon sheaths such as that exhibited by Mr. Jones, and of those occurring in joint cavities, as in a case described in this Society's 'Transactions'[1] by Mr. Godlee.

No. 3 I have shown in consequence of its bearing on another form of fibroma of tendon sheath which has been described by Nelaton,[2] Wordsworth,[3] and others. In Nélaton's case three small fibromata were removed from the superficial surface of the sheath of the flexor tendon of the middle finger, two of them without baring the tendon. I hoped to have shown a specimen of this nature to-night, removed from the tendon of the middle finger of a young woman of twenty. It was of three years' growth, not painful except when pressed upon, and on removal looked like a typical hard fibroma. It reached on to the posterior aspect of the sheath, but was removed without baring the tendon. On section, however, I found scattered myeloid cells. I find these to have been present in published cases (by Broca,[4] Guerin,[5] Czerny,[6] and de Pezzer[7]).

Considering the necessarily close proximity of these tumours to the phalanges, however, I think, in spite of their intimate connection with the tendon sheath, we could scarcely deny their probable original connection with the periosteum. No mention of recurrence is made in the cases recorded.

I am sorry to be unable to show a case of pedunculated bursal growth containing cartilage, but this is the less to be regretted

[1] 'Path. Soc. Trans.,' vol. xxxii, 1881, p. 207.

[2] 'Nélaton, 'Clinique de l'Année, 1856.'

[3] Wordsworth, 'Lancet,' 1857, p. 63; Wordsworth amputated the finger.

[4] 'Bull. de la Soc. de Chir,' 1864, p. 541.

[5] Ibid., 1860, p. 342.

[6] 'Archiv für klin. Chir.'

[7] 'Thèse Inaugurale,' Paris, 1880.

since the change is so well known in joint cavities affected with rheumatoid arthritis, while well-authenticated examples of such growths in tendon sheaths exist, published by Billroth,[1] Volkmann,[2] Jacobson,[3] and others.

The presence of cartilage in the walls of bursal cysts has moreover often been demonstrated, and a papillary growth consisting of large cartilage cells in a stroma of coarse fibrous tissue has been described by Mr. Simon[4] in the 'Transactions' of this Society.

November 2nd, 1886.

---

25. *Further specimens of intermuscular synovial cysts.*

By D'Arcy Power, M.B.

[With Plate XXIII, fig. 2.]

In the early part of the year 1885 I had the honour of bringing under the notice of the members of this Society four specimens of intermuscular synovial cysts occurring in connection with the knee- and shoulder-joints. In the communication[5] which I then made it was stated that these cysts in some cases resulted from the enlargement of one of the bursæ which are so frequently found beneath the muscles in the neighbourhood of the various articulations, whilst in other cases they were formed by a hernial protrusion of the synovial membrane of a diseased joint. In all the examples of this affection which I then exhibited I was able to find a direct communication between the cavity of the joint and the cyst, and I therefore drew the conclusion that my specimens more nearly resembled those which have been described by Mr. Morrant Baker than those which M. Foucher has detailed in the 'Archives Gén. de Méd.' for 1856. Finally, I was unable to discover any causal relation between these cysts and osteo-arthritis of the neighbouring joint.

The specimens which I exhibit to-night confirm in every respect

[1] 'Chirurg. Klinik,' 1868, p. 114.
[2] 'Billroth und Pitha,' Band ii, Abth. 2, p. 829.
[3] 'Brit. Med. Journ.,' 1879, vol. i, p. 227.
[4] 'Path. Soc. Trans.,' vol. i, p. 153.
[5] 'Path. Soc. Trans.,' vol. xxxvi, p. 337.

my previous observations, both as regards the situation of the cysts and as to their mode of origin. Indeed, I should not have again troubled the Society with any further observations upon this point if one of the cysts did not show some important variations from the group previously described, inasmuch as it does not, nor ever did, communicate with the joint. For permission to show the specimens I am indebted to the kindness of Mr. Thomas Smith and Mr. Morrant Baker.

The first specimen somewhat resembles that which is figured in Pl. XII, vol. xxxvi, of the Society's 'Transactions.' It consists of the lower third of the right thigh and the upper third of the leg, from a man aged 41, who was a valet by occupation. On his first admission to St. Bartholomew's Hospital he had a large fluctuating but painless swelling upon the inner side of the right knee. The swelling had been noticed for six weeks and was at first confined to the calf of the leg, but subsequently it extended upwards to the knee. The patient was certain that he had received no injury over the seat of the enlargement, and he stated that the swelling attained its maximum size in two or three days after he first noticed it. Upon aspiration 6 oz. of clear synovial fluid were drawn off and shortly afterwards the patient was discharged. Three months later he was readmitted, saying that the cyst again began to refill about a week after he left the hospital. The right leg now measured over the swelling three and a quarter inches more than the left, and there were two fluctuating tumours on the inner side of the knee, each being about the size of half an orange and communicating with its fellow. The swelling was again aspirated and 4 oz. of synovial fluid containing flakes of mucus were obtained. Four months later, after having been readmitted and discharged in the interval, the patient again entered the hospital with all the symptoms of general tuberculosis. The right knee-joint was then swollen but painless, and there was a large fluctuating swelling over the lower and inner side of the knee, which, as before, communicated with a second swelling near the upper and front part of the joint. Six weeks later, or ten months after the first appearance of the cyst, the man died of tubercular phthisis.

Upon making a dissection of this joint after the *post-mortem* examination, an irregular cystic swelling containing serous fluid in which floated a large number of melon-seed bodies, was found

lying immediately beneath the skin upon the inner side of the joint, and occupying in part the position of a bursa between the semi-membranosus and semi-tendinosus tendons. The cyst was lined throughout by a thin membrane which forms its wall; it was irregularly hour-glass in shape, the two swellings lying opposite the inner condyle of the femur and the upper and inner part of the calf respectively, the constriction between the two parts being apparently due to the passage across the cyst of the sartorius and gracilis tendons. The lower portion of the cyst was the more superficial, and lay entirely in the connective tissue above the muscles, for it could be readily separated from the tibial border of the inner head of the gastrocnemius. Under the hamstring tendons the constricted portion of the cyst opened by a tortuous passage into a second dilatation situated immediately beneath the popliteal vessels and nerve, to the fibular side of the inner head of the gastrocnemius and in close contact with, but not opening into, the bursa which lies under this portion of the muscle. From this point the cyst could be traced beneath the gastrocnemius muscle, where it again dilated into a large sac which was, so far as I could find, terminal. The popliteus muscle was found on exposure to be greatly distended and at the same time much thinner than usual. On cutting through it a large ramifying cyst was situated beneath it, filled, as in the preceding case, with mucous fluid containing numerous melon-seed bodies. The cyst beneath the popliteus muscle appeared to be a dilatation of the subpopliteal bursa. It was separated from the larger cyst by a thin but dense membranous septum as well as by the expanded popliteus muscle, and it did not appear that the two cysts had ever been in communication with each other. Neither of the cysts were in either direct or indirect communication with the synovial cavity of the joint. Of this I assured myself by fully distending the sacs with spirit and finding that none of the fluid escaped into the knee, an experiment which was subsequently confirmed by careful dissection. The knee-joint itself contained no excess of fluid. The cartilages were everywhere natural except for a slight roughening of that which covered the external condyle of the femur and of the corresponding portion upon the patella. There were neither osteophytes nor ecchondroses. The ligaments, however, were much frayed and softened, and the semilunar cartilages were in part worn away. The softening of the ligaments would account for an

unusual mobility which was observed in the joint before death. The synovial membrane was thickened and its fringes were enlarged into irregular outgrowths which present microscopically all the appearances of tubercular disease.

The explanation of this cyst appears to be that, for some reason which I am at present unable to explain, but which is perhaps connected in this particular instance with the constitutional disease to which the patient succumbed, the bursæ in the neighbourhood of the right knee became enlarged. From the history it appears that the bursa lying beneath the sartorius tendon at its insertion first became distended, and this passing upwards has opened into the enlarged bursa lying between the semi-tendinosus and semi-membranosus muscles. The cyst thus formed, and following the line of least resistance, has passed backwards into the popliteal space, instead of opening into the joint or communicating with the exterior. It has then passed downwards into the loose areolar tissue of the ham, where it has dilated into a large cyst. At the same time the bursa beneath the popliteus muscle has undergone a similar cystic enlargement, but without opening, as it often does, into the knee-joint. The two cysts have not as yet fused, though it appears as if they would soon have done so had the patient survived.

I can only briefly allude to the second specimen, as an account of its general features has already been published in a medical periodical.[1] It is (Plate XXIII, fig. 2) the left knee-joint in a condition of acute inflammation, following upon the formation of an intermuscular synovial cyst which communicated with the joint. The cyst appears to be an enlargement of the bursa lying beneath the tendon of the semi-membranosus muscle. The point of especial interest about it is that it communicates, by means of a very narrow channel, with a pre-existing cyst, which is represented by a fibrous cord, only partially pervious, and which runs for an inch and a half along the inner margin of the gastrocnemius. It is better seen in the drawing, which was made whilst the specimen was fresh, than in the spirit preparation. The joint was obtained from a man aged 45, a maker of sieves, in whom the main symptoms of joint disease were intense pain on the slightest movement of the limb. Sixteen months before his admission to the hospital the synovial cyst, whose shrivelled remains are still seen, was opened with antiseptic precautions; its contents were evacuated, and the wound

[1] 'Lancet,' vol. ii (1886), p. 970.

DESCRIPTION OF PLATE XXIII.

FIG. 1.—Illustrates Mr. Pearce Gould's case of a Horn growing from the Glans Penis. (Page 355.)

From a drawing by E. B. Osmond.

It represents the glans penis, from the upper surface of which there projects a sessile, truncated horn, about the size of a marble. Posteriorly to this, at the site of a circumcision wound, is seen a warty (epitheliomatous) growth.

FIG. 2.—Illustrates Mr. D'Arcy Power's paper on Intermuscular Synovial Cysts. (Page 381.)

From a drawing by T. Godart.

It represents the left lower extremity, which has been amputated above the knee. In communication with the knee-joint is a synovial cyst, which has apparently developed from the bursa lying beneath the tendon of the semi-membranous muscle. This cyst communicates by a very narrow channel with a pre-existing cyst, represented by a partially pervious fibrous cord running along the inner margin of the gastrocnemius.

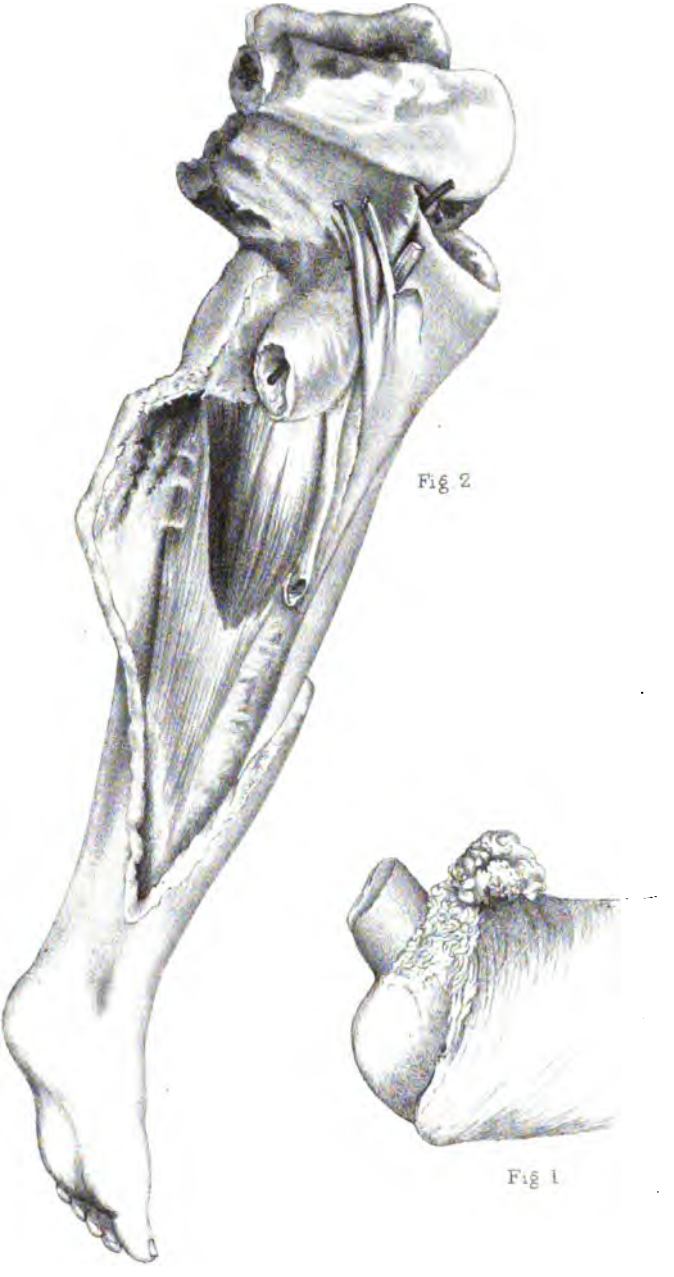

Fig 2

Fig 1

healed by first intention. Six months later a fresh cyst appeared and the joint became intensely painful. Amputation was performed, and the patient made a good recovery. In this case the other bursæ in the neighbourhood of the joint appeared to be normal, and the case therefore more closely resembles one variety of the cysts described by Mr. Baker, inasmuch as it coexisted with a diseased condition of the joint, with whose synovial cavity it communicated. It is remarkable that in this case the symptoms of disease of the knee did not manifest themselves until six months after the tapping of the cyst, and at a period coincident with the appearance of the second swelling. As in the previous case, the disease of the joint is tubercular in origin. The futility of aspirating cysts which are more or less directly dependent upon progressive joint disease, is, I think, rendered apparent by this case, for although the enlargement was for the time arrested, a fresh cyst very soon developed itself.

The third case presents yet another variety of such a cyst, to which attention has also been drawn by Mr. Baker. It is the left elbow-joint of a man aged 34, a porter in the General Post Office. He was first admitted to St. Bartholomew's Hospital on account of a painless swelling in the neighbourhood of the left elbow-joint. The swelling was oval in outline, and was situated immediately above the internal condyle. It had been observed for two and a half years, and was diagnosed by Mr. Morrant Baker, under whose care the patient was, as a cyst in connection with the joint. The swelling was tapped, but it rapidly reappeared, and for twenty months afterwards it hardly underwent any change. At the time of tapping it was observed that there were no signs of joint disease, but the forearm could not be completely flexed or extended. Twenty months later the patient was readmitted to the hospital, with a large abscess occupying the site of the cyst. This was allowed to burst spontaneously, and it was then washed out and drained, but the patient gradually lost ground until amputation was performed, after which he made a good recovery.

The specimen, which has been carefully dissected by my friend Mr. E. W. Willett, shows that the capsule of the joint is distended on both its anterior and posterior surfaces, and is much thickened by chronic inflammation. The synovial cavity is in connection with the exterior by two sinuses, along which glass rods have been passed into the joint. The articular surfaces of the bones are in-

flamed, and are almost entirely denuded of cartilage. The cyst appears to have resulted from a hernia of the synovial membrane itself, such as is figured by Billroth, and examples of which I have already exhibited before the Society.

I may conclude my remarks this evening by observing that it is a significant fact that in two out of the three examples which I have shown the cysts were in connection with tubercular disease of the neighbouring joint, and this may, I fancy, in time to come, afford a clue to their origin.

The specimens are preserved in the museum of St. Bartholomew's Hospital, Series VII, Nos. 1205 e, f, and g.

February 15*th*, 1887.

---

26. *Ranula and cysts in the neighbourhood of the hyoid bone.*

By J. Bland Sutton.

The floor of the mouth is frequently occupied by cysts known as *ranulæ* from their fancied resemblance to the body of a frog; in Germany the condition is known as *der Frosch* and the French equivalent is *la grenouillette*.

There is a great deal of truth as well as sarcasm in the remark of Dr. Wilks[1] when writing concerning ranula, "This name is given much in the same loose worn-out way as that of epulis on the gums, to cysts in the floor of the mouth under the tongue, cysts which have a bluish colour and may grow to a large size."

This term ranula, like so many others used in clinical medicine and surgery, has only a generic significance. It is the object of the present communication to draw attention to this matter, as well as to analyse the records of cases for the purpose of tracing as far as possible the history of many of these cysts.

Cystomata in connection with the floor of the mouth may arise as dilatations of the ducts of the various glands opening into it, such as the submaxillary, sublingual, or mucous glands, as well as of a mucous gland, sometimes of a large size and of a horseshoe

[1] 'Pathological Anatomy,' 2nd ed., p. 363.

shape, situated at the tip of the tongue. The obstruction of the salivary ducts may arise as a result of inflammation, foreign body or calculus lodged in a duct, or even after surgical operations.

Cysts, sometimes of very large size, may originate in what are known as accessory thyroids, and small detached cysts are very frequently found in the neighbourhood of the hyoid bone. The etiology of these structures is of very great interest to the pathologist as well as of value to the surgeon. The most elaborate study of this question is that by Streckeisen,[1] who divides them into four sets according to their situation: (1) Those superficial to the mylo-hyoid—pre-hyoid. (2) Between, or in the substance of the genio-hyoid—supra-hyoid. (3) Above the genio-hyoid muscles—epi-hyoid. In this situation they would lie between the genio-hyo-glossi muscles. (4) If lodged in the hollow of the hyoid bone they are termed intra-hyoid. Accessory glands may be found in the neighbourhood of the greater cornua of the hyoid bone, but they are rare.

Mr. Barker,[2] in his excellent paper on lingual dermoid cysts, gives us a similar classification. This surgeon collected sixteen cases and found:

1. They may be unilateral, lying between the genio-hyo-glossi and the mylo-hyoid muscles, on one side or the other.

2. They may be central, lying between the genio-hyo-glossi muscles.

3. They may be bilateral, lying between the mylo-hyoid and genio-hyo-glossi muscles.

Streckeisen further points out the relative frequence of a pyramidal process to the thyroid gland. He found it in 79 per cent. of 153 subjects examined. Not only are accessory thyroids met with, but small cysts lined with epithelium, occupying similar positions. These also occur at the apex of the pyramidal process.

Streckeisen comes to the conclusion, that these various structures have a common origin in the remains of the central diverticulum, from which the main portion of the thyroid is developed, known as the hypo-pharyngeal diverticulum. He further concludes that the foramen cæcum indicates the spot where the diverticulum is origi-

[1] "Beiträge zur Morphologie der Schilddruse," 'Virchow's Archiv,' Bd. ciii, S. 131.

[2] 'Clin. Soc. Trans.,' vol. xvi, p. 215.

nally protruded, and he has, in one case, found a duct leading from the foramen cæcum to an epi-hyoid gland.

Attention has already been drawn to the existence of this duct, described by His[1] and traced by him developmentally. It is a narrow duct lined with epithelium running from the foramen cæcum on the dorsum of the tongue, downwards and backwards between the genio-hyo-glossi muscles, to end blindly in the hollow of the hyoid bone. This is termed by His the lingual canal. Associated, and often in connection with the duct is a third or middle lobe to the thyroid gland. This too is in connection with a duct known as the thyroid canal. In embryonic life the two ducts are con-

WOODCUT 15.

A longitudinal section of a human tongue, to show the lingual duct.

tinuous, and constitute a canal known as the ductus thyreo-glossus. The existence of these ducts admits of no doubt whatever. In the tongue of the human fœtus at birth a thin bristle may often be passed from the foramen cæcum to the hollow of the basi-hyoid. In the adult it is best demonstrated by removing the body of the hyoid bone and carefully dissecting the cellular tissue lying between the genio-hyo-glossus; the duct, if present, is easily found. The existence of these ducts also explains, as His is careful to point out, the presence of the accessory thyroid glands and cysts described by Kaydi, Zuckerkandl, and others.

Zuckerkandl seems to have been the first to describe these accessary thyroids, but failed to connect them with any definite structure. Kaydi has found a ligamentous string extending into the septum of the tongue. He believed the glands to arise from the same germ as the thyroid, and that this gland was originally more extensive and surrounded the hyoid on all sides.

I have, in another place,[2] drawn attention to the circumstance

[1] Anat. Mensch. Embryonen.,' Bd. iii, 1885.

[2] 'An Introduction to General Pathology,' 1886.

that the lingual canal is very frequently persistent and capable of admitting a bristle, and the same holds good for the thyroid canal, but how far they are the representative of the original pharyngeal diverticulum it is difficult yet to decide. This is, moreover, a question of morphology, and has no definite bearing on the subject matter at present. It may, however, be remembered that the hypo-pharyngeal diverticulum, by the best embryologists, is regarded as hypoblastic. The lingual duct is certainly epiblastic, and derived from the stomodæum.

During the long vacation I have made a series of dissections of the parts in the neighbourhood of the hyoid bone from human subjects of various ages and of both sexes. I was induced to undertake this investigation because Streckeisen's observations seemed so much at variance with the experience of English pathologists, and Dr. Norman Moore's statement to this Society, that "he believed accessory thyroids to be of very rare occurrence."

My observations go to show that accessory thyroids, pyramidal processes, and a persistent lingual duct occur with great frequency, but the proportion is not so high as in Streckeisen's list. This may in part be accounted for by the circumstance that Streckeisen obtained his material at the Pathological Institute of Basle, a district where goitre is endemic. Sir James Paget speaks of outlying masses of thyroid gland not being rare near bronchoceles, "lying by them like the little spleens often seen near the larger mass."

There can be no doubt that many of the cysts coming under the observation of surgeons in the neighbourhood of the hyoid bone arise from dilatation of these detached pieces of tubular structures, and I shall also take occasion to show that some cysts connected with the floor of the mouth and tongue originate in this manner also, especially those described as dermoid and sebaceous.

Cysts of the tongue described as sebaceous are very few in number. Sir William Fergusson described one as large as the fist, which he successfully removed.

Mr. Pollock[1] speaks of a rare form of cyst met with amongst the soft tissues of the submaxillary regions, usually between the symphysis and angle of the jaw, and more or less deeply situated between the floor of the mouth and the inner surface of the bone. The cyst contains sebaceous matter, and frequently hairs.

[1] 'Holmes' System of Surgery,' vol. ii, p. 525, 2nd edition, 1883.

This writer then makes the following important remark:—"Its existence may have been noticed from birth; but as far as experience enables us to arrive at a conclusion on this point, it appears more frequently to become evident at some later period of life; for although in all likelihood congenital, it may originate in so small a cavity, and may so slowly fill, that it will only make itself conspicuous to sight, or be detected by touch, at some subsequent date."

There can be no doubt that the cysts of the tongue described as sebaceous are of the same nature as those reported by other writers as lingual dermoids.

Mr. Barker, in the paper before mentioned, has collected sixteen cases of lingual dermoids, and Mr. Butlin[1] informs us that the details of about twenty cases can be referred to. I find, however, that they occur far more frequently than these statements would lead us to believe. Reference to a goodly number of cases will be found in Jean Cusset's work on 'Branchial Fistulæ,' Paris, 1877, besides many recorded in detail for the first time.

In one case the cyst occurred in a child a few days old; it was removed by M. Richet in l'Hôpital Saint Louis. This is interesting, for it is rare that the cysts attain a size sufficient to permit of their detection in infants.

An examination of the collection of cases in Cusset's work is of practical interest. In many instances the cyst was treated as a ranula, and it recurred only to be cured by total extirpation.

A good example of a lingual dermoid was recorded by Mr. Stephen Paget[2] last year, and if these cysts are so rare it is certainly a very extraordinary circumstance that two examples should come under my care within three weeks of each other.

During the past autumn a male patient, twenty-four years of age, came under my care in the Middlesex Hospital with a tumour occupying the floor of the mouth in the vicinity of the frænum, and bulged forward exactly in the middle line. He had, during the course of nine years, submitted to seven operations; the cyst, supposed to be a ranula, had recurred after each attempt.

When I saw the patient the cyst had not the ordinary appearance of a ranula, and on piercing the cyst wall with a scalpel a yellowish viscid material escaped, which by its peculiar smell convinced me

[1] 'Diseases of the Tongue.'

[2] 'Trans. Path. Soc.,' vol. xxxvii, p. 225, 1886.

that the supposed ranula was a dermoid. An anæsthetic was administered, and the cyst wall dissected out from its bed by means of two pairs of forceps. It lay between the genio-hyo-glossi muscles, and was so firmly fixed to the body of the hyoid bone as to need a raspatory to detach it. Very little hæmorrhage occurred during the operation, but some hours afterwards recurrent bleeding gave some little trouble, but the patient was soon convalescent.

The cyst was full of sebaceous material, and a few hairs were detected in the mass. On hardening the specimen and making sections for the microscope, the walls were found to be composed of connective tissue supporting a thick layer of epithelial cells, mostly of a spheroidal shape, but the superficial ones were flattened. Minute sebaceous glands occupied the wall of the cyst.

The second case occurred in a woman aged 27; she had a swelling of the size of a bantam's egg lying to the left of the tongue and projecting into the floor of the mouth. The wall of the cyst had become so thinned that whilst manipulating it the cyst burst and gave exit to a considerable quantity of viscid, yellow, sebaceous material, but no hairs were detected

Unfortunately I have as yet been unable to examine the anatomical details of the cyst so thoroughly as in the preceding case, for up to the present time the patient has failed to summon sufficient courage to submit to operative interference.

Dermoid tumours in the immediate neighbourhood of the tongue are interesting and important in that they constitute a connecting link between the more complex teratoid tumours and sebaceous cysts. A critical examination of the details of some cases, described as sebaceous cysts, serves to show that they are of the nature of the tumours we have just been considering.

A true sebaceous cyst results from the obliteration or obstruction of the duct of a sebaceous gland with consequent accumulation of secretion, which gradually leads to the distension of the follicles.

In the variety we have been considering we find originally an obsolete canal lined with epithelium, and in some cases possessing sebaceous glands. The secretion from these glands, mixed with the débris of the shed epithelium slowly accumulating in the duct, dilates it into a cyst. Should hairs or teeth spring from the cyst wall, it would be characterised as a dermoid or teratoid tumour.

It seems to me clear that we must sharply distinguish between a sebaceous cyst originating in gland and cysts containing epithelial scales and sebum originating in obsolete canals. In this latter class I would include not only those cysts occurring about the hyoid bone, but sebaceous cysts lying deeply in the neck (below the deep fascia) originating in connection with branchial clefts.

Paget,[1] in a paper on branchial fistulæ of the external ears, suggests it as possible that some forms of ranulæ may originate in branchial fistulæ or rather imperfectly obliterated branchial clefts. This view is rendered more probable by an observation of Neumann.[2] This surgeon extirpated a congenital sublingual cyst from a man aged 52. The interior of the cyst was covered with ciliated epithelium like that of the air passages and of some forms of branchial cysts. The contents of the cysts consisted of a dirty viscid reddish fluid with epithelial scales and pus-cells.

Conclusion. — An examination of the normal anatomy of the parts in relation with the hyoid bone, shows undoubtedly that many detached fragments of tubular structures exist, derived in part from branchial clefts and from the thyreo-lingual canal. These may dilate and become cystomata, with fluid, sebaceous, or papillary contents. In some cases these growths may invade the floor of the mouth and become recognised clinically as ranulæ. With regard to cysts originating in the lingual canal one form of treatment only is of use,—complete extirpation. Cysts arising from accessory thyroid structures may behave in the same way and present the same variations as cysts originating in the paroophoron, parovarium, or Gartner's duct. In the simple form the cyst is filled with mucoid or clear fluid, and its interior lined with epithelium, resembling parovarian cysts. Others present an arrangement of spaces lined with cubical epithelium recalling the structure of the thyroid, and villous processes may sprout into its interior as in an excellent case described by Mr. Bilton Pollard.[3] Such cysts resemble the well-known papillary cysts of the parvoophoron and duct of Gartner. In the third group we must place malignant cysts such as those described by Mr. Treves.[4] These bear the same relation to simple and papillary cysts in the neck

[1] 'Medico-Chir. Trans.,' vol. xli, p. 41, 1878.
[2] 'Langenbeck's Archiv,' 1877, Heft. 4, S. 825.
[3] 'Trans. Path. Soc.,' vol. xxxvii, p. 507.
[4] Ibid., vol. xxxviii, p. 360.

as malignant carcinomatous ovarian cysts bear to parovarian and papillary cysts occurring in the ovary and broad ligament, whilst dermoid cysts are occasionally present as the result of gradual passive dilatation of functionless tubes lined with epithelium as the result of accumulated secretion and shed epithelial scales.

November 2nd, 1886.

---

27. *Large dermoid cyst over the sternum.*

By H. H. Clutton.

This specimen was removed at St. Thomas's Hospital in October, 1886, from a married woman, aged 39, who had been kindly sent to me by Dr. Huddart, of Redcliffe Gardens.

A small body of about the size of a pea was first noticed in front of the chest when the patient was only six weeks of age. When ten years old the cyst was tapped, but nothing was obtained from the interior. At nineteen years of age she states that it was of about the size of a hen's egg. Since then it has increased more rapidly, especially during the last five years. As regards its situation she was quite sure that it had always been placed over the middle of the sternum. Her mother had told her that it was in that position from the very commencement, when it was about the size of a pea. So far as her own memory was concerned she could recollect it distinctly when it was about the size of a filbert, and then most decidedly it was placed over mid-sternum. I am thus particular over this part of the history because it has been suggested to me that possibly in infancy it was situated over the episternal notch, and by constant traction had acquired the lower position on the front of the sternum.

When the patient was admitted into the hospital the tumour hung in a pendulous manner from the centre of the sternum exactly between the two breasts, and measured thirteen inches in circumference at its base. It was soft and flaccid, but distinctly fluctuating. The skin moved freely over it, but showed lines of atrophy in the central part, such as are often seen, I think, over the middle of a dermoid cyst. A strong artificial light showed no

signs of translucency, but by displacing the contents the edge of the cyst wall could be very distinctly felt, so that no doubt was entertained as to the fluid nature of the interior. Before proceeding to the removal of this cyst I naturally felt anxious to prove that it had no communication with the interior of the chest, a condition of things which might very well have existed if the tumour were, as I supposed it to be, a dermoid cyst. It had no impulse on coughing, but the tumour was too large to allow an examination of the bone beneath its centre. Ether was given to facilitate a more thorough and complete examination as the patient was excessively nervous. A trocar having been introduced and a little fluid withdrawn, the whole surface of the sternum was then easily examined and considered to be free from any aperture or depression. The cyst was therefore removed the next day without opening its cavity. The sternum, to which the cyst was not even adherent, was perfectly normal. The clinical history requires no further description, for the temperature never rose more than one degree above the normal standard, and the wound healed by first intention.

Mr. Shattock found some difficulty in showing the cyst in its globular form, and has therefore turned it inside out and stretched it upon a glass disc. In the recent state some flakes, which proved to be epithelium, were loosely adherent to its inner surface. These were easily removed, and the lining membrane thus exposed to view presents the ordinary appearance to the naked eye of skin; one hair only can be seen projecting from its surface. Microscopically, the membrane appeared to be deficient in the size and number of its papillæ, and no sebaceous or hair follicles could be found, but in other respects it was similar in its structure to skin. The contents were carefully preserved, and measured 11 oz. It will be remembered in estimating the real size of the cyst, that some of the fluid had been withdrawn by tapping the day before the operation.

Under the microscope were seen epidermis, fat, and cholesterine, but no hair. After standing in a glass jar for some time the oil floats upon the top, and forms a very considerable proportion to the whole fluid, probably about one sixth.

March 15th, 1887.

28. *Congenital sacral tumour containing bone.* (*Card specimen.*)

By J. H. TARGETT.

HISTORY OF CASE.—John B—, aged 19, admitted with discharging sinus between the buttocks over the coccyx, which had existed since childhood. There had probably been a swelling there from birth, but it was first lanced when three years old. The sinus was explored, and a tumour removed by Mr. Bryant.

Description of specimen.—An irregular multilocular cystic tumour situated between the coccyx and rectum. There was an interval of four and a half inches between the tip of coccyx and the anus. The various loculi of the tumour were enveloped in tough fibrous tissue, so that it was difficult to free them, but there was no distinct capsule. An irregular arch of bone was found buried in this fibrous tissue, in shape something like a large hyoid bone. One cyst was shut off from the main cavity, and contained slightly opalescent fluid with a thick white precipitate like "bread-sauce," which showed granular fatty matter and epithelium under the microscope. The precipitate was converted into a thin opalescent liquid by caustic soda. Ether had little effect on it.

A section of the wall of the cyst showed that it was lined with columnar epithelium with one or two deeper layers of rounded and flattened cells.

No definite pedicle or cord was found connecting the tumour with the spine, but it has probably developed in connection with the neurenteric canal of the embryo. *November 2nd*, 1886.

IX. DISEASES ETC., OF THE DUCTLESS GLANDS.

1. *Cancer of the thyroid.*

By G. Stoker.

The patient, C. D—, a female aged 56, stout and of full habit, complained of loss of voice, dyspnœa, and swelling in the neck.

On laryngoscopic examination the left vocal cord was seen to be completely paralysed, lying in the middle line, and the right nearly so, leaving only a small aperture, which fully accounted for the dyspnœa. The thyroid was felt to be enlarged, especially on the left side; the swelling was not prominent, but was deep-seated and very fixed and immovable.

She had no difficulty in swallowing. She first noticed the swelling eighteen months ago; during the last six months she had pain, and during the last three great difficulty in breathing. There were no enlarged glands in the neck; she had no appearance of myxodema; and the urine was normal. Tracheotomy was performed to relieve the dyspnœa; the operation was not attended with any difficulty, but she got bronchitis and died four days afterwards.

The *post-mortem* examination showed the left recurrent laryngeal nerve embedded in the growth, from which it was impossible to dissect it; the right recurrent was embedded in the right lobe of the thyroid, but could be traced into it for a much greater distance than the left into the left.

On microscopic examination the growth was found to be composed of a fibrous stroma filled with epithelial cells; none of the original structure of the gland remained.

October 19*th*, 1886.

2. *Malignant disease of thyroid (round-celled sarcoma).* (*Card specimen.*)

By Stephen Paget.

From a woman aged 59. She had noticed a swelling for thirty years, but did not complain of it till six weeks before death. She then had dysphagia, and later dyspnœa, and could not get proper sleep. She became unable to take solids, and could only take fluids with very great difficulty. She had severe pain. The dyspnœa increased, with loss of voice; and she died suffocated.

The tumour appears to have grown from the left lobe of the thyroid. Part of this left lobe remains, pushed upward and flattened over the top of the tumour. The tumour extends from half an inch below the hyoid bone to the bifurcation of the trachea. It is smooth and globular; its upper part is hard and tough, and contains a cavity with calcareous walls, filled with broken-down clot. The lower part of the tumour is soft, almost diffluent, diffused through the mediastinal space.

Anteriorly, the tumour has perforated the trachea, projecting into it at the level of the eighth to the twelfth rings. To the left, it has embraced the great vessels and the vagus; the artery is much flattened, but not obliterated. Posteriorly, it has thrust the cricoid and arytenoid cartilages backward and to the right; and the œsophagus, for nearly three inches of its course, is thrust backward and to the right, and tightly strained flat over the back of the tumour.

The right recurrent laryngeal nerve is involved in a mass of diseased lymphatic glands. The rest of the body was not examined. *October 19th*, 1886.

3. *Sarcoma of left lobe of thyroid growing round œsophagus, and invading left internal jugular vein and left vagus. Ante-mortem clot on right side of heart containing growth. (Card specimen.)*

By G. N. Pitt, M.D.

The patient, aged 65, had noticed a swelling on the left side of his neck three weeks previously; this rapidly increased in size. On admission he had aphonia and a very irregular, feeble pulse. He died suddenly the following day. Dysphagia had not been a prominent symptom. A very soft, rapidly growing, round-celled sarcoma forming a semi-fluctuating, smooth, non-lobulated tumour, $4 \times 3\frac{1}{2} \times 3$ inches, occupied the left lobe of the thyroid. This was encapsuled. There was also a mass of growth in the adjacent glands, which had grown into the left internal jugular vein, where a clot mixed with growth was adherent, continuous with the wall below, and projecting freely above. The left vagus was embedded in growth, and showed two fusiform enlargements where it had been involved. The growth extended between the trachea and œsophagus for five inches, forming a submucous swelling, which at the upper part was one inch thick. In the lower part the growth more or less surrounded the œsophagus, but did not infiltrate the mucous membrane. In this portion of the growth there was extensive hæmorrhage.

The right side of the heart contained an extensive flattened *ante-mortem* and *post-mortem* clot extending into the pulmonary artery, and showing localised patches of white growth doubtless carried from the internal jugular vein. No secondary growths in viscera.

There was diffuse bronchopneumonia with recent pleurisy over the diaphragmatic surface of the left lung, but there were no infarcts in the lung. The right lobe of the thyroid was healthy.

December 21*st*, 1886.

4. *A case of simple diffuse goitre, with secondary tumours of the same structure in the bones of the skull.*

By JOSEPH COATS, M.D. (Glasgow).

[With Plate XXIV.]

THE case which I venture to bring before the Society is one which seems to me to present several points of considerable importance. In the first place, although there are very few cases of a similar kind on record, yet I think there are indications that it is an example of a distinct class which is probably of more frequent occurrence than the paucity of recorded cases would indicate. It is also of consequence, as showing that a disease which most writers regard as scarcely belonging to the class of tumours is capable of secondary extension, very much in the fashion of a malignant tumour.

The following note, as to the condition during life, is extracted from the journal of Ward IX, where the patient was under the care of Dr. G. P. Tennent:

"The patient is a woman aged 46, a laundress, who had borne eight children, all living and well in health. A swelling is noticed in front of the neck, immediately above the clavicles. It extends on each side of the middle line, but the chief bulk is on the left side. It corresponds in position very much to a goitre, is hard to the touch, and pulsatile, not excentric, but only so far as the vessels beneath convey pulsation. This swelling was first noticed about sixteen years ago.

"On raising the patient's head there is noticed a soft swelling, occupying pretty much the position of the external occipital protuberance, and in area rather larger than a two-shilling piece. It is distinctly pulsatile, and on pressing the fingers around the edge of the tumour the hard prominent edges of the bone are felt. The patient's daughter says that this commenced with pain about a year and a half ago. The pain was very extreme, but she does not know that it was worse at nights. The swelling appeared a few weeks after the pain, and increased to the size of a pigeon's egg. The swelling is not always of the same size—at times much smaller

than at others, but never entirely away. There is no history of an injury. There has been no complaint of pain for some months past, and when the patient was herself asked regarding it, a day or so after admission, she distinctly stated that it gave her no discomfort or annoyance of any kind, except in so far as its actual presence was concerned."

The patient had been subject to subacute rheumatism for about two years before admission. While in the infirmary she presented great restlessness and irritability, and was the subject of delusions. Inability to swallow or to speak gradually developed, but there was no paralysis of the limbs. The heart presented greatly exaggerated pulsations, and the cardiac dulness was increased to the left. The temperatures were latterly febrile, ranging up to 104·5°.

Inquiry as to the place of residence of the patient shows that she was born and brought up in Kilmarnock. At fourteen years of age she went to Stewarton. She lived in Glasgow for about five years before death.

The description of the appearances after death is thus given in the *post-mortem* reports:

The thyroid gland presents a very striking enlargement, especially of the left lobe, which measures 2¾″ from above downwards, and 1¾″ transversely. The right lobe is also enlarged, measuring 1⅞″ by 1⅜″. There is considerable calcareous deposition in both lobes, but especially in the left, which feels as if surrounded by a hard shell, and is only with difficulty penetrated by the knife. There is no enlargement of the isthmus, and, indeed, scarcely a trace of isthmus discernible, so that the two lobes are virtually isolated from each other.

The head presents externally a prominent tumour in the occipital region, having its centre near the occipital protuberance; it is quite soft to the touch, and the bone is obviously defective in this region. On reflecting the soft parts and removing the calvarium several other tumours are found occupying the place of the bone and destroying it more or less. The following tumours are noted in the skull:

The largest of the tumours—that mentioned above as being visible externally—measures 1¾″ in diameter, and as seen in section is ¾″ in thickness. The centre of the tumour is just above the position of the torcular herophili, and this, with the lower part of the longitudinal sinus, is pushed somewhat inwards,

but the dura mater is nowhere involved in the tumour. The bone, at the upper and lower extremities of the tumour, ends quite abruptly, and is not infiltrated with tumour tissue. The tumour itself has a red, fleshy appearance.

The next largest tumour was discovered in removing the soft parts from the surface of the skull, there being a slight defect in the external table, but without any prominence. This tumour had a considerable projection inwards, and the internal table and diploë were destroyed over an irregular quadrilateral area, measuring rather more than an inch in diameter, the gap in the external table being about $\frac{3}{4}''$. The gap in the bone was filled with soft, red tumour tissue, which was firmly adherent to the outer surface of the dura mater, but did not penetrate this membrane. The tumour had exercised pressure on the brain, the region affected being about the inferior extremity of the ascending frontal convolution. The situation of this tumour is at the extreme anterior and inferior edge of the left parietal bone, possibly involving slightly the squamous portion of the temporal bone.

There is another tumour in the right parietal bone, about an inch in front of the apex of the lambdoidal suture. This is about $\frac{3}{4}''$ in diameter, and circular in outline; the external table is deficient, but the internal is preserved, except at the very centre. Two other areas are discovered by the red colour shining through the internal table, and by a slight projection internally; both of these are in the right parietal bone.

No other tumours were discovered anywhere, and the only additional lesion was slight hypertrophy of the heart.

On examining microscopically a section of one of the tumours of the skull I was at first greatly astonished at its structure. It was seen to be composed of a congeries of saccules, such as constitute the thyroid gland. A small portion of such a section is represented in figs. 3 and 4. The saccules are of various sizes, but mostly small, and they are lined with a distinct nucleated epithelium, usually cubical in shape. The shape of the epithelium is sometimes shown, when the floor of a saccule is seen, in which case the epithelium forms a distinct pavement. The saccules themselves are generally rounded in shape, but they are sometimes oval or elongated. There is mostly a calibre or cavity to the saccules, but sometimes the epithelium fills the saccule. This is the case in the smaller, and, presumably, the younger of them.

The cavity is often filled with colloid matter. This is so frequent that there are always a few examples of it in each field with a low magnifying power. The saccules so affected are enlarged, but this is never very extreme, and there are no proper cysts. The sections represented in the figures were taken from the occipital tumour, but sections from that in the parietal bone had precisely the same structure.

The structure of the tumours of the bone naturally suggested an examination of the thyroid gland. It was difficult to make sections of the thyroid gland, especially of the left lobe, on account of the dense calcareous masses which it contained, but by exercising some care sections were obtained of the soft parts of the tissue. They presented exactly the same structure as that of the tumours in the skull, and figs. 1 and 2 might stand for representations of such sections. The saccules here, as there, are small in size, and the colloid change is only of occasional occurrence, being perhaps less frequent in the thyroid than in the skull, but there are considerable variations in this respect. No cysts were found in the left lobe, but in the right there were some filled with colloid matter.

The calcareous matter which is so abundant in the left lobe is in the form of small, hard masses, which seemed to be contained in the septa dividing the gland, and I believe that the lime salts are situated in old, obsolete pieces of gland tissue. I have placed under the microscope sections of the left lobe of the gland, made after the lime salts had been extracted with hydrochloric acid, while the tissue was being hardened in alcohol and chromic acid.

These sections exhibit two changes, which are evidences of long continuance of the goitre. There is, in the first place, a great thickening of the capsule, and of the septa, a fibrous induration of the gland. These thickened septa were almost cartilaginous in consistence. In one place is a rounded mass embedded in dense fibrous tissue. This mass is stained somewhat deeply, and presents no structure whatever. It has all the characters of a piece of dead tissue which has undergone the process which Weigert has designated coagulation necrosis. I believe that this represents a piece of dead tissue. Wölfler, in his work to be referred to shortly, depicts a similar appearance, and gives it this interpretation. The calcareous infiltration seems to have taken place into

DESCRIPTION OF PLATE XXIV.

To illustrate the paper by Dr. Coats on Goitre with Secondary Tumours in Skull. (Page 399.)

From drawings by R. J. Godlee.

FIGS. 1 and 3 represent sections of the thyroid; and Figs. 2 and 4 of the tumours of the skull.

Figs. 1 and 3 were drawn with Beck's $\frac{4}{10}''$, Figs. 2 and 4 with Beck's $\frac{1}{10}''$, immersion.

The sections were stained with alum carmine, and mounted in Canada balsam.

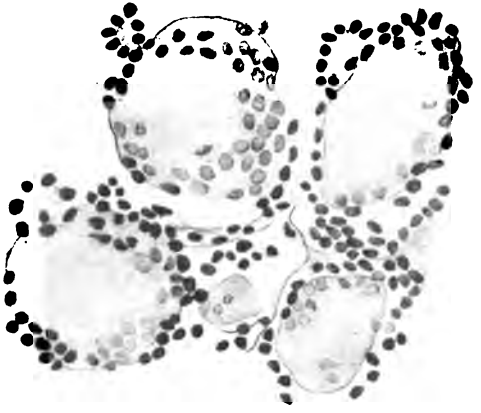

such necrosed pieces of tissue. This would accord with the observations of Cohnheim and Litten, who, on the basis of experiment, associate calcification with coagulation-necrosis.[1] These changes altogether indicate that the affection of the gland has been a chronic one, and they are all changes which are comparatively common in ordinary endemic goitre.

Remarks.—Of the enlargement of the thyroid gland which we are accustomed to call goitre, and the Germans Struma and Kropf, we may, to begin with, separate exophthalmic goitre as having nothing to do with this case. Endemic goitre consists in an enlargement of the thyroid dependent on new formation of the tissue of the gland, usually accompanied by colloid degeneration.

Cohnheim has endeavoured to draw a sharp line of distinction between hypertrophy of the thyroid and adenoma. In the former case there is a diffused or general enlargement of the gland, while in the latter there are distinct separate tumours composed of gland tissue. He states his belief that the endemic form of goitre (which he ascribes to an unknown miasma) always affects the gland itself, while the adenoma or the proper tumour arises in the usual way of other tumours from embryonic foci in the gland.[2]

Wölfler has endeavoured to distinguish hypertrophy from adenoma on a somewhat different basis.[3] He also refers to the genesis of the structures, and designates as hypertrophy cases in which the new-formed tissue arises from the pre-existing gland tissue, either by enlargement of the existing follicles, or by formation of saccules from the undeveloped gland-cells, which are always present in the thyroid gland. He applies the name adenoma when the tissue by its atypic vascularisation shows that it is a proper new formation. As both the hypertrophy and the adenoma may appear either as a general enlargement of the gland or as separate nodules, it must be difficult to carry out this distinction. Most cases of ordinary goitre are classed by Wölfler as adenomata, and perhaps it is better to retain the older term of simple goitre, distinguishing it as diffuse or nodulated according to its structure. Our case would be classed by Wölfler as adenoma, but as the lesion is present in both lobes and causes a general

[1] Cohnheim and Litten, 'Virchow's Archiv.,' vol. 83, p. 508.

[2] Cohnheim's 'Vorlesungen,' 2nd edition, vol. i, p. 755.

[3] Wölfler "Ueber die Entwickelung und den Bau des Kropfes," 'Arch. f. klin. Chirurgie,' vol. xxiv, pp. 1—97, and 754—866, 1883.

enlargement of the gland it may be described as a simple diffuse goitre.

Very few cases of a kind similar to the present one have been recorded. So far as I have been able to discover, there are only three others on record.

The most complete case is one published by Cohnheim in 1876, on which he has based some interesting speculations in regard to the malignancy of tumours.[1] In this case there were isolated tumours in the thyroid, and the tissue showed such considerable colloid metamorphosis as to warrant the name colloid goitre. There were secondary tumours in the bronchial glands, the lung, and in several bones, and all these had the same microscopic structure as those in the thyroid gland. The author notes that on fine dissection one of the tumours in the thyroid gland was seen to project into a large vein, a branch of the inferior thyroid, in the form of a small, smooth, bud-like prominence. Cohnheim suggests that cases of this kind may not be very uncommon, and cites a case recorded by Runge, in which there was a large tumour of the atlas and epistropheus, as well as a goitre with several adenomas in the enlarged gland. Cohnheim has little doubt that the case is one of colloid goitre with metastasis, although Recklinghausen, on the ground of the microscopic structure, regarded it as cancer, and gave it as an instance of primary cancer of bone. In a subsequent number, however, Recklinghausen repudiates this, and gives an illustration of the microscopic structure which certainly conforms to that of cancer, and not to that of goitre.

Another case, which I believe to belong to the same class, is given by Wölfler in his very elaborate papers on the development and structure of goitre already referred to.

In the second of his articles Wölfler enters into a long criticism of Cohnheim's case, with the conclusion that, in his opinion, Cohnheim has not proved his contention, and that the tumours may have been cancerous. He suggests that there may have been some part of the enlarged thyroid overlooked by Cohnheim which had not the structure of a simple goitre, but was cancerous, and that this formed the primary tumour. In rather an inconsequent manner Wölfler adds a case of his own, which appears to confirm the position of Cohnheim, and seems to me to resemble somewhat the case which I have here brought forward. It was one in which

[1] Cohnheim, 'Virchow's Archiv,' vol. 68, p. 547, 1876.

an oval tumour about the size of a goose's egg was situated over the external angle of the left eye. It was almost immovable, of somewhat hard consistence, and covered with bony lamellæ. The tumour was removed by Billroth, under the impression that it was a periosteal sarcoma. To the great astonishment of the author the unossified parts of the tumour had distinctly the structure of an ordinary adenoma of the thyroid. The appearances are figured and the description of the structure is as follows: "There were gland saccules, of medium size as compared with the normal, or exceeding these in size by about double; they were lined with a short cubical epithelium, and filled with old, yellowish grey, colloid fluid." There was no opportunity of examining the thyroid gland microscopically, but the left half of the gland is stated to have had the dimensions of a small fist; it was but slightly movable, and hard to the touch. The author, with some apparent unwillingness, admits that this looks very like a metastatic tumour of the thyroid, and surely the precise reproduction of the structure of the gland establishes it as a case of metastatic simple adenoma.

An important additional case was presented to this Society by Mr. Morris, under the heading "Pulsating Tumours of the Left Parietal Bone, associated with other similar Tumours of the Right Clavicle and both Femora." I have to thank Mr. Godlee for calling my attention to this case. It is very fully recorded in vol. xxxi of the 'Transactions.' The tumours were submitted for microscopic examination to Dr. Goodhart, Dr. Thin, M. Cornil, and the Morbid Growths Committee. M. Cornil remarked that the tissue approached *un peu* to the structure of the thyroid gland, and the Morbid Growths Committee were similarly "struck with the resemblance between this growth and that of certain enlargements and tumours of the thyroid gland." They afterwards discovered that this patient suffered from a considerable enlargement of the thyroid.

I think it is likely that records of similar tumours are to be found scattered through medical literature, but, being published under different names, and subjected to various interpretations, they will be difficult to find. It will at least be agreed that this class of cases deserves to be placed in a distinct category.

April 5th, 1887.

5. *Tubercular mass in suprarenal capsule.*

By Harrington Sainsbury, M.D.

The specimen is from a case of advanced and widespread tuberculous disease in a woman of between thirty and forty years of age. She was admitted into the Royal Free Hospital for lumbar abscess. Clinically the case presented nothing special.

At the *post-mortem* there was noted much wasting of the body; bedsores over the sacral prominences; a lumbar sinus to the left of the spine leading down to bare bone, also subcutaneous burrowing of cheesy pus along the spine towards the sacrum; in the thorax, miliary tubercles in both lungs, especially the left, but without marked predilection for the apices; at the root of the lung a caseous gland; in the posterior mediastinum, lower third of dorsal spine, a collection of cheesy pus in connection with carious bone; in the abdomen, a yellowish nodule the size of a pea, in the spleen; another yellow nodule the size of a kidney bean in the right suprarenal; considerable enlargement of the mesenteric lymphatic glands, many of them being caseous; in the large intestine well-marked ulceration; in the small intestine, for one or two feet above the cæcal valve, great congestion of the mucous membrane with here and there a patch of an adherent greenish pellicle (croupous inflammation ?).

Associated with these morbid states there was present widespread albuminoid degeneration, intense in spleen and liver, less marked but still distinct along the vasa recta of the kidneys, well marked in the alimentary tract (stomach, duodenum, large intestine); present also in the suprarenal, at junction of cortex and medulla.

The interest of the case centres in the yellow nodule in the right suprarenal. As to its nature it is obviously tuberculous, presenting all the external characters of crude or conglomerate tubercle; equally obviously it is a secondary affection. In both of these respects how will it compare with those fibro-caseous conditions of the suprarenals which are most commonly met with in Addison's disease ? I will leave undiscussed the first of these two questions, viz. that of the tuberculous nature of the fibro-caseous change in Addison's disease, and assume that it is tuberculous. There still

remains to be answered the question, Is this change primary or secondary? It may seem that the answer is at once obtained in those cases of Addison's disease in which the change in the suprarenals has been the only discoverable one. But apart from the fallacy here, that a caseous focus in gland or in bone tissue may have been overlooked, it would not be safe to assume that in those other cases of Addison's disease in which tuberculous lesions coexist in other organs, that in these cases also the suprarenal trouble is primary, and in point of fact Dr. Greenhow suggests for certain of his cases that the suprarenal change is secondary. It is in relation to this question that the present specimen suggests, I think, an answer, or if not an answer, yet a mode of answering.

All cases of secondary involvement of an organ, provided it is not by direct extension, *i. e.* by continuity of tissue, all such are in a manner chance affections. The poison from the primary focus enters the blood stream, and its secondary lodgment in one or other or several organs will be a matter of probability. Now, the two suprarenal bodies are, so far as the blood stream is concerned, *i. e.* so far as the channels of infection are concerned, practically identical, and the chances hence of a secondary implication of one or other, as here, are equal. If now we accept certain of the cases of Addison's disease to be secondary, then inasmuch as all these are cases of bilateral affection (for without the bilateral implication we do not get Addison's disease) we shall be prepared to meet with a comparatively very large number of cases in which one or other capsule *alone* is affected.

This relation admits of definite numerical statement, but it suffices to point out the relatively very great number of cases, of the kind here present, which *should* exist on the hypothesis that the bilateral fibro-caseous lesion of Addison's disease is secondary.

With the enormous amount of tuberculous material in this country at our disposal this question admits of being dealt with by the statistical method. All that is necessary is a routine examination of the adrenals. If it should prove, as I suspect, that a lesion such as that now shown is rare, perhaps rarer than the actual cases of Addison's disease themselves, or scarcely exceeding them in number, we shall then have sufficient proof that the bilateral suprarenal affection of Addison's disease is the result of a primary affection, and that we have to deal with a system disease:

This point being determined we shall be better able to reconsider the question of the tuberculous nature of this affection.

November 2nd, 1886.

---

6. *Genito-urinary tuberculosis, with caseation of both suprarenal capsules.* (*Card specimen.*)

By S. Coupland, M.D.

The kidneys, ureters, bladder, &c., showing extensive tubercular disease.

The *right kidney* is in an advanced stage of "tubercular pyelitis," with multiple abscesses in the remaining renal tissue. *Left kidney* shows less advanced pyelitic change, but the whole organ is thickly beset with suppurating foci.

Both *ureters* are enlarged, walls thickened, lining membrane ulcerated throughout, and covered with caseous débris.

Bladder. Lining membrane wholly destroyed by tubercular ulceration, which extends into the *urethra* for about an inch beyond membranous portion.

Prostate is the seat of a tubercular abscess.

Vesiculæ seminales and *vasa deferentia* are also tubercular.

Left epididymis is enlarged and caseous; and a few caseous nodules occur in body of *left testis*. *Right testis* is fibrous.

Each *suprarenal capsule* is firmly adherent to the kidney. The *right is wholly caseous;* and the *left is similarly affected* except for about the lower one fourth, where the normal distinction of cortex and medulla is preserved. Each organ has preserved its characteristic shape to a certain extent.

There was also caseous tubercle and recent granulations in the lungs. No tubercle of serous membranes.

Chronic endocarditis (mitral stenosis) with recent vegetations on the thickened mitral cusps was also present.

From the body of a man aged 46, who died in the Middlesex Hospital on October 25th, 1886. He was very pallid, sallow, and cachectic, but had none of the symptoms of Addison's disease. He complained chiefly of persistent lumbar pain, and passed large quantities of urine, which contained a very small amount of pus.

November 2nd, 1886.

7. *Morbus Addisonii.* (*Card specimen.*)

By WILLIAM PASTEUR, M.D.

THE organs were obtained from the body of a lad aged 16, who was admitted into the Middlesex Hospital on December 3rd, 1886, and died on the following day. A diagnosis was not made, but the general impression was that he was suffering from some acute cerebral disease, or possibly from typhoid fever.

Autopsy eight hours after death.—Ill-nourished but not emaciated. There was deep pigmentation of the areolæ of the nipples and of the skin of the penis and scrotum.

Lungs small, adherent on both sides, and stained towards the periphery by inhaled blood. No signs of tubercle, old or recent.

Liver and kidneys of normal appearance.

Attention was drawn to the true nature of the case by the remarkable appearances met with in the intestines and which have been fully described in the 'Pathological Transactions' by Drs. Greenhow and Coupland. Peyer's patches were unduly visible throughout; in one of them, towards the lower end of the ileum, there was a small clean cut superficial ulcer from which some hæmorrhage had taken place. Throughout the whole of the small intestine, but most marked in the lower three feet, there was a remarkable uniform enlargement of the solitary follicles, which stood prominently out from the mucous membrane, looking like sago-grains. The peritoneal surface of the intestine was perfectly normal. The intestines were empty and collapsed. The spleen was enlarged but not very soft. The right adrenal was firmly attached to the under surface of the liver. Its normal shape was entirely lost, what remained being an agglomeration of caseous and calcareous nodules supported in a semi-translucent, homogeneous, fibrous matrix. Its bulk was somewhat diminished. The left adrenal was a little larger than normal and in a similar condition. There were no enlarged glands or signs of tubercle in the abdominal cavity. The stomach was of natural size. Its rugæ were unduly prominent, and there was slight mammillation of the mucous membrane at the pyloric end.

December 7th, 1886.

X. DISEASES OF THE SKIN.

1. *Tubercular disease of the skin.* (*Card specimen.*)

By Samuel G. Shattock.

Two elliptical portions of skin, including the subcutaneous fat. (These formed originally a single continuous piece.)

In each there is a depressed area about two inches in length and half an inch in breadth, the surface of which is raised either in low undulatory ridges or in distinct close-set papillary processes. The margin of the healthy skin is sinuous and notched, at parts shelving smoothly on to the diseased surface, at parts sharply defined and in close lateral contact with the adjacent elevations. During life these surfaces secreted a semi-purulent fluid, and were of a bright red colour.

Histology.—Vertical sections taken transversely to the long axis of the affected areas, show a continuity of epithelium over the diseased surface, except in certain spots where the tissue of the corium is "granulating."

The remains of the corium exhibit an abundant small-cell infiltration, and scattered through this are well-marked giant-cells; some of the latter lie in the denuded papillary processes close beneath the suppurating surface. The leucocytes are collected especially around the smaller vessels, and form long-spreading tracks or circular groups according to the plane of section.

I am indebted to Mr. Clutton for the following notes of the case.

The patient a man aged 44, noticed a small hard lump near the anus, two years before the operation.

Four months before operation this opened and discharged, and the ulcer then slowly crept up the angle between the thigh and the scrotum.

On admission, the ulcer was four inches in length; and still higher up towards the groin were two small round ulcers presenting similar characters. On August 20th, 1886, Mr. Clutton

removed the whole; a fistula was then discovered leading from the anal extremity of the ulcer into the rectum. The patient presented signs of pulmonary disease. The wound was healed in September, when the patient showed signs of lunacy, and was sent to the Lambeth Infirmary.

The disease corresponds with that form of lupus named verrucosus (McCall Anderson), or papillaris, or sclerous (Vidal and Leloir). The figure from the last-named authors, reproduced in Cornil and Ranvier's 'Pathological Histology,' represents very faithfully the changes shown by sections of the present specimen, which is of some interest in relation to the disputed question of the identity of lupus and tubercle.

The clinical history in the present case may be held to render it certain that the disease is tubercular; the history is one of anal fistula resulting from abscess in a patient who presented signs of pulmonary disease.

It is of some importance, therefore, to notice that whilst giant-cells are present in fair numbers, there are no circumscribed tubercles. This structure, it may be concluded then, is sufficient to constitute one form of tubercular lesion.

Reference may be made also to a case of "lupus" of the pharynx which was reported by Mr. Clutton in the 'Transactions' of the Clinical Society, 1886. Here, after death, the histological characters were found to resemble those just mentioned in that the giant-cells did not constitute the centres of definite tubercles.

There were in this case signs of pulmonary disease during life, and Dr. Acland was able to demonstrate afterwards the presence of tubercle bacilli in the lungs.

Dr. Brailey also recently exhibited at the Ophthalmological Society a specimen of thickening of the choroid having similar histological characters, the tubercular nature of which he himself considers quite certain; and he writes to me that he has seen other examples of the same disease.

McCall Anderson[1] classes all the varieties of lupus as "strumous" affections of the skin; the verrucose form he makes synonymous with "scrofuloderma," and remarks that it is usually associated with other manifestations of strumous disease, either in the skin, glands, or bones. *April 19th*, 1887.

[1] 'A Treatise on Diseases of the Skin,' 1887.

XI. SPECIAL COMMUNICATIONS.

1. *Cultivation-experiments with new growths and normal tissues, together with remarks on the parasitic theory of cancer.*

By Charles A. Ballance and Samuel G. Shattock.

[With Plate XXV, figs. 2, &c.]

SCHEME OF PAPER.

1. Preliminary Remarks.
2. Presumptive Evidence in Favour of the Parasitic Nature of Cancer.[1] Comparison with Tuberculosis.
   - A. Local carcinoma; exceptional occurrence; auto-inoculation.
   - B. Lymphatic gland infection.
   - C. General infection through the lymph- and blood-streams from a local focus.
   - D. Primary origin apart from a possible local inoculation.
     - (1) Single primary tumour.
     - (2) General outbreak.
3. The Infective Character of Cancer.
   - A. Considered in the primary growth.
   - B. As seen in the secondary tumours.
4. Further Considerations.
   - A. The parasite and the surface of the body.
   - B. The inward spread of the epithelium in carcinomatosis. The origin of benign tumours. "Benign" carcinomata.
   - C. The cancerous cachexia.
   - D. The phenomenon of atavism.
   - E. The rate of growth.
   - F. The alleged antagonism between cancer and tubercle.
5. Cultivation-experiments.
   - A. New growths.
   - B. Normal tissues.
6. Conclusions and Suggestions.

[1] The term cancer is used to include all malignant new growths.

1. Preliminary Remarks.

In view of the fact that so many specific diseases are now shown to have a micro-parasitic origin, malignant new growths naturally suggest themselves as a promising field for inquiry in the same direction; and the object of the present communication is to record the first results of an investigation made with the idea of determining whether malignant growths have a similar pathology, and although we have no evidence to offer of a positive kind, negative results are not without value in that they clear the way for further research.

2. Presumptive Evidence in Favour of the Parasitic Nature of Cancer. Comparison with Tuberculosis.

The theoretical considerations which render the view of a parasitic origin of malignant new formations plausible are many. To us the view recommends itself as bringing the essential pathology of such growths into natural relation with other diseases, the parasitic pathology of which admits of demonstration. And among lesser advantages it would reconcile the advocates of the local with those of the constitutional origin of cancer, by deciding that the origin of cancer may be either. It makes but little change in the doctrine of cancer maintained by Sir James Paget; it is, indeed, hardly more than a legitimate and natural extension of that doctrine, which is so well known as to render any particular reference to it not merely unnecessary but almost disrespectful.

In the same way that anthrax is taken as the standard of comparison in pathological mycology, so we propose tuberculosis as the standard of comparison in the study of sarcomatosis and carcinomatosis.

Sir John Simon has previously said also,[1] that most instructive suggestions may be derived from a consideration of the wonderful advances which, during the last dozen years, have been made in the etiology of tubercle.

A. *Local carcinoma; exceptional occurrence; auto-inoculation.*—Carcinoma, then, we should regard firstly as having sometimes a purely local origin, in the same way that the tubercular infection-process may arise by direct inoculation, and remain a local though

[1] An address on "Some Points of Science and Practice concerning Cancer" ('Brit. Med. Journal,' Feb. 16th, 1878).

a spreading disease. So we should look upon some examples of squamous-celled carcinoma of the lip in smokers, the early and free removal of which may be followed by complete cure of the disease. In other words, a patient suffering from a carcinoma which has arisen as a local disease, and has not passed beyond the stage of local infection, may not only be relieved by the knife from the actual disease but freed from an almost certain secondary infection. The case in fact is exactly comparable to one of local tuberculosis arising from direct inoculation, or to external anthrax whilst it is yet a local process, and might be termed one of local carcinomatosis. Against this view, thus typically illustrated, the main argument adduced is that all those exposed to the local irritation arising from smoking should become therefore the subjects of carcinoma. But the efficient cause lies beyond the mechanical irritation, which is but the partial cause of the disease; and the question resolves itself into this,—Why are some persons infected under such circumstances whilst others escape?

In this respect tetanus affords a valuable parallel. Tetanus[1] is now known to be due to secondary infection resulting from the inoculation of a wound with a specific bacillus. The local origin of tetanus is evidenced, in its experimental production, by the local spasms which regularly precede the general disease.

The same very rarely occurs in man. Mr. Anderson tells us of the case of a young man under his care many years ago, in whom trismus was preceded by tetanic spasms of the arm corresponding with the injured hand. The virus is widely distributed in the soil; nevertheless a very insignificant number of common wounds in this country are followed by tetanus, and the same question presents itself for solution,—Why are some persons infected whilst others escape? Reflection will suggest possible answers for both cases, —the irregular distribution of the virus, the dependence of its efficacy upon the various elements of environment, &c.

Tetanus is more common in certain parts of the globe than others. The same is true of tubercle,[2] to say nothing of those specific diseases which, like malaria or cholera, are endemic. And

[1] Rosenbach in 'Langenbeck's Archiv,' Bd. xxxiv, Heft 2; Brieger in Deutschen Chemischen Gesellschaft,' Jahrgang xix, Heft 18; Brieger in "Deutschen medicinischen Wochenschrift,' 1887.

[2] Buchanan, quoted by C. Theodore Williams in 'Quain's Dictionary of Medicine,' p. 1167, "Damp Districts, Clay Soil, Moist Atmosphere."

cancer[1] has in the same sense, a geographical distribution. Cancer, too, is more common in towns (*i.e.* relatively to the population) than in rural districts.

Erichsen states ('Surgery,' 8th edition, vol. i, edited by Marcus Beck, p. 1015) that "cancer is said to be unknown in the frigid zone;[2] it rarely occurs amongst the inhabitants of the torrid zone, though in the more populous parts it is not unknown."

In Peru, where extremes of heat and moisture occur, acute tuberculosis and acute forms of cancer are not uncommon; the environments favouring these two diseases would appear to be much the same.

Mr. Butlin,[3] who strongly inclines to the parasitic theory of cancer, notices as a remarkable fact telling in its favour that the lympho-sarcoma of the lungs of the cobalt miners of Schneeberg (Hesse) ('Archiv d. Heilkunde,' Bd. xix, S. 160), undoubtedly a true tumour disease, occurs only amongst the miners in the cobalt pits, killing all the men who work there for a certain number of years, but affecting none of the persons in the neighbourhood who are not employed in the pits. He draws attention also to the green colour and rapid dissemination of green cancer (chlorosis) with the invariable presence in the tumours of very numerous minute highly refractive molecules.

It has even been recently suggested[4] that the remarkable limitations in the distributions of goitre and its occasional epidemic outbreak tell in favour of a parasitic origin. It is asserted also that some cases of goitre are arrested or cured by removal from the affected district. It is a remarkable fact that goitre is at times congenital in man, and the same too has been observed

[1] "Collective Investigation Record," 'Brit. Med. Journal,' Feb., 1887; "Low-lying Districts, especially Towns, near Rivers and on Clay Soil." Also Havilland ('Journal of the Soc. of Arts,' vol. xxvii, No. 1367).

[2] Hirsch notices also the almost total absence of cancer in Egypt; a statement lately corroborated by Dr. Milton, of the Cairo Hospital. On the other hand, we have learned, through Sir John Simon, of the remarkable prevalence of cancer in certain districts of New Zealand.

[3] Article, "Tumours," in 'The International Encyclopædia of Surgery,' vol. iv. With regard to Gussenbauer's alleged discovery of the infecting agent, a highly refractive minute molecule within and without the cells, Mr. Butlin observes that until the observations have been confirmed or contradicted they must be regarded with caution.

[4] Klebs and Bircher, 'Zeigler's Pathology,' vol. iii, p. 195, article 623 A.

in animals, amongst which goitre is by no means uncommon.[1] The congenital occurrence of cancer may be studied in the same regard.

Lastly, there is fair proof of the local inoculability of squamous-celled carcinoma in the well-known cases of infection of one labium arising from contact with a carcinomatous ulcer on the other. An excellent example of the same class is given by Mr. Harrison Cripps[2] in his paper on carcinoma of the rectum, in which he mentions a case of carcinomatous infection of the skin of the arm from contact with an ulcerating scirrhus of the mamma.

B. *Lymphatic gland infection.*—The disease of the lymphatic glands in anatomical relation with a carcinoma admits of no other explanation than that it results secondarily from infection conveyed from the primary focus. There is no conceivable alternative.

In this respect, again, tubercle has a parallel history in the secondary gland disease that sometimes arises from a local tubercular lesion, and which invariably follows the experimental production of tuberculosis by subcutaneous inoculation of tubercle bacilli in healthy animals.[3]

C. *General infection through the lymph- and blood-streams from a local focus.*—The instances of general infection occurring through the lymph- or blood-stream from a local carcinomatous or sarcomatous lesion have so many parallels in the history of other specific diseases that the analogies need not be further referred to. The succession of general tubercular infection as witnessed in animals after primary inoculation is strictly like the general dissemination of sarcoma that not rarely occurs. The special anatomical

[1] See a good *résumé* of the "Comparative Pathology of Goitre" in the 'Lancet,' May 28th, 1887, by Mr. A. T. Sloan, who mentions the disease as having been observed in buffaloes, antelopes, cows, pigs, cats, horses, goats, mules, mice, &c.; and who quotes Principal Williams, of the New Veterinary College, Edinburgh, to the effect that goitre "must be due to something else besides the magnesian limestone water."

[2] 'Path. Soc. Trans.,' 1881. See also the very suggestive remarks in this paper concerning the infective properties of cancerous epithelium.

[3] As analogous to a locally spreading tubercular lesion of the skin or mucous membranes, may be cited those cases of local dissemination observed in carcinoma of the breast, producing the well-known cancer *en cuirasse;* in a case of villous carcinoma of the cardia we have seen numerous discrete secondary growths of a similar kind scattered over the œsophagus: perhaps a similar mode of spread obtains in some cases of carcinoma of the bladder.

characters of the secondary growths in carcinoma are ample proofs of their source from the primary tumour. In the case of sarcoma perhaps the best proof of the same fact is furnished by the melanotic variety, where the pigmentation of the secondary tumours is sufficient evidence of their origin from the primary growth.

The sarcoma-cell possesses doubtless the same determinate hereditary tendency as is further on claimed for the epithelial; and by virtue of this it produces, in whatever part of the body it is carried to, the same elements that would have resulted from its division had it retained its original position; and further, these elements tend to produce by the arrrangement that results from their similar mode of growth a structure or tissue like that of the primary tumour.

In the ossifying sarcomata of bone, again, the secondary growths often ossify to an extent equalled only by the primary tumour. Most of the cases, however, spoken of under this class come under discussion in the next section.

D. *Primary origin apart from a possible local inoculation.*—(1) *Single primary tumour.*—The foregoing, doubtless, include only the simpler of the pathological processes involved in the history of malignant new growths; and far more abstruse problems arise in connection with the more numerous cases in which the disease, though first manifested locally, has a "constitutional origin;" amongst parallel diseases tubercle again offers itself for consideration.

When tubercular arthritis is set up by a local injury the problem has yet to be solved as to how the local disease derives its specific characters. What is true of tubercle is almost certainly true of cancer. The apparent cause of the latter may be some slight injury, but such an injury can be the partial only, and cannot be the whole cause.

Clinical observers are agreed that tubercular disease is predisposed to in certain persons; that the predisposition is hereditary; that the scrofulous diathesis, although it may not always be recognisable by the ordinary gross tests, is nevertheless a fact. What this diathesis really is cannot as yet be stated. It may, however, be provisionally thought of either as tuberculosis without a local lesion, or as a soil eminently favorable for the growth and development of the virus of tubercle.

The influence of the personal element or "predisposition" in relation to infective diseases is recognised, indeed, as a fact of wide importance in medicine.

This influence is well known to obtain, for instance, in scarlet fever and measles; and a remarkable example of it in the case of diphtheria was related by Dr. Murchison in his lectures.[1] In the case referred to, four brothers suffered from diphtheria, though residing in different parts of the globe, and in places where the disease was not exceptionally prevalent.

As a corollary of this may be noted the peculiar *in*disposition shown by certain persons to take the same diseases.[2]

Perhaps the tubercular diathesis bears a just comparison with hereditary syphilis. In hereditary syphilis the disease will remain latent after its earliest manifestations until puberty, when it will again disclose itself. In this long period of latency it surely must be held that the virus, or to speak more definitely, the bacillus, remains potent for evil, though it does not make its presence shown.[3] In acquired syphilis in the adult the same is true, as seen in the outbreaks which are liable to occur for years after the date of the primary disease,—the gumma is not less characteristic of syphilis than is caseous tubercle of tuberculosis.

Is it therefore that the tubercle bacillus is dormant, in the scrofulous diathesis, and that its presence is shown only when a local injury lowers the vitality of the part, and furnishes a medium in which it will grow? On this supposition the scrofulous diathesis is derived through a parentage of tubercular disease.[4]

The other view that may be held concerning a localised manifestation of tubercular disease, arising from some slight injury and independently of direct inoculation, is that the tissues of the patient, though not harbouring the seeds of disease, are below the proper "standard vitality," and that whilst organisms gaining

[1] From notes of lectures at St. Thomas's Hospital, unpublished.

[2] See Hirsch, 'Historical and Geographical Pathology,' New Syd. Soc., vol. iii, p. 110, where instances of indisposition to diphtheria are given.

[3] Compare the cases of long-delayed formation in the history of certain galls referred to by Sir James Paget as illustrating the phenomenon named by German writers "Eiruhe" (address on "Elemental Pathology," 'Brit. Med. Journal,' 1880).

[4] Malaria and relapsing fever well illustrate the possibility of certain pathogenic organisms remaining for a period dormant without producing results by which their presence may be shown.

entrance through the internal or external surfaces of a healthy person fail to grow, in the other case they find a suitable soil for growth in the injured part.

In one or other of these ways we should support the view which makes certain forms of cancer, whether shown first by a primary tumour, or by an apparently simultaneous outbreak of new growths, depend upon a specific diathesis comparable to that of tuberculosis.[1]

And the many recorded cases in which cancerous tumours have rapidly grown after injury bear comparison with the specific local tubercular lesions arising under similar circumstances in "scrofulous subjects."[2] The variations in the rapidity of onset and in the subsequent history of the morbid process in the latter case have their counterparts in malignant disease. (See cases recorded by Mr. Barwell in the 'Brit. Med. Journal,' 1883, under the term Acute Traumatic Malignancy; and a fuller paper by Mr. Pearce Gould in the ninth volume of the 'Medical Society's Proceedings.')

In rare cases, besides the general diathesis, there appears to be transmitted a particular local predilection for the manifestation of the disease; this implies possibly a developmental defect analogous to those more easily recognisable in the case of the skin (as moles) or undescended testicle. One of the most striking instances is that given by C. Moore ('Antecedents of Cancer,' p. 37, 1865): a mother and her five daughters all suffered from cancer of the left breast.

(2) *General outbreak.*—Lastly, there appear to be cases of a simultaneous outbreak of malignant tumours in various parts of the body ("general sarcomatosis"); and such cases may be compared with those of general tuberculosis arising independently of a known primary lesion. Here, however, it is probable that the real sequence of events has escaped detection, that the primary source of infection has been overlooked, and that further knowledge will

[1] See also the remarks made by Mr. Cripps in the ninth vol. of the 'Medical Soc. Trans.,' in which the growth of a malignant tumour, following traumatism, is compared with the infective process arising at the seat of an injury in dogs fed with the flesh of animals which have died from septicæmia. In either case the injured tissues form a suitable soil in which the living contagia may germinate.

[2] In Billroth's opinion there is just as much a specific predisposition to the development of tumours as there is to chronic inflammations with proliferation of the inflammatory new formation with suppuration, with caseous degeneration ('Surgical Pathology,' 1881, p. 610).

diminish the number or abolish the whole of the cases at present included under the term "simultaneous outbreak."[1]

3. The Infective Character of Cancer.

A. *Considered in the primary growth.*—The malignant new formations we hold to be sharply and definitely marked off from innocent tumours, not perhaps so much by any single anatomical character of structure as by their physiology. The malignant new formation tends to invade the surrounding tissues, and further, it gives rise to the production of secondary tumours.

In these ways it must be held that an unnatural or morbid character (in the case of carcinoma) has been imparted to the epithelium. It is not the epithelial multiplication alone which constitutes carcinoma; this occurs, though not to such an extent, in adenoma and on free surfaces under various conditions; but it is the growth of the epithelium into the surrounding tissues. The epithelium acts in fact itself in a parasitic-like manner and grows as a foreign substance amongst the normal tissues.

The cell masses invade the lymph spaces and from the detachment, by collateral channels, of cell-emboli, the secondary growths result in those glands which are in anatomical relation with the primary tumour.

But the transported epithelium retains its altered character, for the secondary tumours are not benign but lead again in their growth to a tertiary series. And the evidence afforded by this history we hold to be more consonant with the view advocated in the present communication than with any other.

Sir John Simon remarks upon this (loc. cit.) that of all the etiological characters of cancer that which is incomparably the most important is the property of infectiousness which its cause imparts to it, and which in fact makes the identity of the disease. . . . . The fact that cancer has a marked affinity for organs which are already in certain accidental ways disordered, seems to show that the unknown exciting cause is not native to the body, or at least is not specially an attribute of the texture in which the disease breaks out.

In the 'Guy's Hospital Reports' vol. xviii, 1873, Dr Moxon

[1] See Dr. Bristowe's 'Practice of Medicine,' 1st edit., 1876, pp. 29 and 131. He there compares cancer to smallpox, and states that in his view every general specific disease begins as a local process.

writes in his article on the "Pathological Nature of Tumours," "Whatever takes place in our bodies has two distinct factors, the intrinsic factor, which is the constitutional power of the part affected to react by its irritabilities, functional, nutritive, and formative; and the extrinsic factor, which is the external injurious agent that inflicts the injury. . . . . This may be mechanical or chemical . . . . or it may be vital like the spermatical agent, whatever it is, which forms the contagion of fever. . . . . The spermatozoid once meeting the right ovule may create a life, and so, the fever sperm coursing into and finding the living frame germinal to its spermatic impulse, is able to create a sort of other life, or parabiosis," &c.

In such parasitic diseases as tubercle, actinomycosis, and syphilis, the new formations are, it may be said, chiefly or simply inflammatory; infective granulomata result but not infective epithelial tumours.

In the sarcomatous tumours, however, the anatomical forms are more or less closely like those that result from inflammatory processes; the most rapidly growing are of the round-cell kind, the more slowly fibrify; and those arising in connection with the bones tend to chondrify and ossify, as does the granulation-tissue produced in callus-formation or osteoplastic inflammation.

In carcinoma the primary and the secondary formations are essentially epithelial. But in carcinoma there are nevertheless all the anatomical signs of inflammation (especially at the circumference of the tumour) combined with the epithelial growth, and in this degree it is a "granuloma." The inflammatory process may be due to the action of the ingrowing epithelium as a foreign substance, or to some excitant which the diseased epithelium produces.

In a spreading tubercular lesion the diseased tissue is inflammatory; in a spreading carcinomatous infection, though there is an associated inflammation, the essential element is the spreading epithelium. The difference must be assumed to imply a difference in the habitat of the irritant. A predilection for particular tissues is seen so well in the history of the larger parasites that it is impossible to doubt that the same obtains also in those that are more minute. And so it may be held that the epithelium is the necessary habitat of the parasite concerned in the production of carcinoma and that it will live and grow in none other. The excitant of sarcoma may, however, be identical with that of carcinoma.

The two classes of tumours may be the specific results of causes

which are not identical, as the various kinds of galls mark as many specific modes of infection and constitute amongst plants the same number of specific diseases. But it is possible that the same parasite may find a suitable soil in one case in epithelium, in another in the connective tissue.

Sir James Paget in his well-known address on "Elemental Pathology,"[1] cites a few cases in which the same insect produces different kinds of galls according to the different sites of oviposition. And so in hereditary cancer, there may arise variations in the kind of morbid growth, the essential cause of the disease remaining the same.[2]

B. *As seen in the secondary tumours.*—The secondary epithelial growths in glands or organs, since they invariably repeat the character of the primary growth, must be due to the transference of elements from the primary tumour together with the efficient cause of the latter, and they may be held to result from the subdivision of the elements so transported.

A consideration of the remarkable rapidity of cell division in quickly growing tumours, and in many forms of vegetable tissue, will remove any difficulty in understanding the rapid increase of the secondary growths. The transported cells grow as they would have done had they remained within the primary tumour, except in so far as their new situation affects their nutrition for better or for worse.

That the transport of a normal cell is not sufficient to account for the indefinitely-growing secondary tumours is proved by Leopold's experiments, which show that portions of growing tissue if transplanted, though they grow for a while, subsequently undergo atrophy; they do not grow into tumours; and a similar result has been obtained by Cohnheim and Maas ('Virchow's Archiv,' vol. 70), in the case of periosteum, &c., made to lodge in the lung.

The dermoid cysts on the palmar aspects of the fingers (see Poland, 'Path. Soc. Trans.,' vol. xxxv, and Barker, vol. xxxvii) if they really arise, as has been suggested, from the transference of growing epithelium by injury into the deeper substance of the corium, are hardly exceptions, for they attain only an insignificant size and certainly do not possess the property of infectiveness.

[1] Loc. cit.

[2] The different results produced by tubercular infection in the skin illustrate this possibility: recent researches tending to prove that lupus is one of the forms of tubercular disease.

In the epithelial grafting practised upon healing ulcers, the evidence of a reserve power of growth is clear; but such grafts never grow into carcinomata,—they grow to an extent limited in accordance with their normal capacity and with their determinate hereditary tendency, and perhaps also in accordance with the physiological requirements of the part to which they are transplanted. In this respect the history of normal and of diseased cells is markedly different.

Dr. Creighton's theory[1] that the cancer cells have a spermatic influence on the tissues around, the elements of which they incite to multiply, in reality leaves untouched the main question under discussion. For, as urged by the writers (Sir James Paget, Mr. Moore, Mr. Butlin) in 'Holmes's System of Surgery' (3rd edit., vol. i, p. 252), if this spermatic influence be admitted, the moment and manner in which it is acquired yet require to be demonstrated.

And the same criticism may be extended to the conclusion formulated by Ziegler, that the phenomenon is ultimately due to some change affecting individual elements of a tissue, whereby they are rendered dissimilar to their neighbours; and that the change is manifested especially in this, that the normal checks to the indefinite growth of the proliferous cells are inoperative or inadequate.

The chief difficulty to be met in regard to the secondary growths in carcinoma is the resemblance which these sometimes present to normal structures.

In columnar-celled carcinoma of the rectum, the secondary growths in the liver may resemble the crypts of the intestine. In thyroid cancer the metastatic growths may resemble the thyroid gland. With respect to this we submit the following consideration.

In the normal process of development it is the epithelial element which determines the general anatomy of any particular gland; the arrangement of the connective tissue and the vascular supply are adapted to the requirements of this the essential element. Hence it will follow that when epithelium from one of the diseased crypts of the intestine is transported to the liver, it would tend to produce by its inherited capacities, a structure resembling that of which it primarily formed a part, the sustentacular tissue and vascular supply being furnished by the indifferent tissue around.

In the periodical regeneration of the uterine mucous membrane after its partial destruction in menstruation, a normal process of

[1] 'Path. Soc. Trans.,' vol. xxv.

gland-formation occurs from the relics remaining in the undestroyed portion of the membrane.

It is possible, though it does not seem to us probable, that the sustentacular tissue of the secondary growths in carcinoma is derived directly from the epithelial cells, as has been held with regard to the neuroglia of the central nervous system and the supporting framework of the highly specialised epithelial cells which are subservient to the physiology of the special senses.

The secondary growths in the case of squamous-celled carcinoma of the skin arising in connection with the epidermis, repeat the structure of the epidermis, with horny nests, &c., whilst in a glandular carcinoma (sudoriparous or sebaceous) of the skin the original gland-like structures are more or less closely represented. It might even be conjectured, in accordance with this rule, that a carcinoma arising in connection with the epithelium over the papilla of a hair, would tend to produce hair-like structures in the primary and in the secondary tumours.

In most cases the epithelium in the primary tumour soon deviates from the normal type, and in the secondary growths in such cases the same want of normal characters obtains.

In this way we conceive how it is that the secondary epithelial tumours in carcinoma repeat the characters of the first.

4. Further Considerations.

A. *The parasite and the surface of the body.*—Organisms which are innocuous upon a healthy mucous or cutaneous surface acquire a position of advantage, so far as their entrance into the body is concerned, when they reach the terminal ramifications of gland-ducts or bronchioles; they are then separated only by a delicate single layer of spheroidal or flattened epithelium from the blood- or lymph-stream, and their products, thus pent up, may have a deleterious influence upon the nutrition of the cells around. A diminution of the standard vitality of the surface-epithelium again may allow of the transmission of the organised ferment into the system. To suppose a particular instance, if the infecting agent be a true parasite of the epithelial cell (in the same sense that some algæ are true parasites of certain Protozoa) such a depression of vital power may be the necessary antecedent to the entrance of the parasite into its epithelial habitat. Prolonged mechanical irritation, by lowering the standard vitality of the

epidermis, becomes thus an important antecedent to infection (*e. g.* in cancer of the scrotum in chimney-sweepers, and of the lip in smokers); a spot is prepared for the morbid process. The importance of this principle is forcibly urged by Sir James Paget, who cites as another example of it the frequency of carcinoma in the breast after its functional activity has ceased, in other words, when the degenerative changes of local senescence in the secreting epithelium have set in. In this last case of course there is no question of direct inoculation,—the excitant must gain admission in some more complex manner.

That organisms do pass to the bottom of gland-ducts is illustrated in the case of boils, and by the difficulty experienced in sterilising such a surface as the skin of a horse, which possesses large and deep hair-follicles. Moreover, when drugs are administered by inunction those areas of skin are chosen (such as the axillæ and groins) in which the cutaneous glands are especially abundant, and from which experience has indicated that absorption will most readily occur.

B. *The inward spread of the epithelium in carcinoma. The origin of benign tumours. Benign carcinomata.*—The question may be asked, Why say in a squamous-celled carcinoma of the skin is there an inward spread of the epithelium? The epithelial cell which is infected with the cancerous virus multiplies with extraordinary rapidity. This manifestation of reproductive power is the first, most prominent feature of malignancy. Bearing this in mind the history of the disease may provisionally be explained on physical principles, though we do not maintain that all the phenomena of infectiveness admit of such an explanation.

The great production of cells say at some point in the rete Malpighii or at the extremity of a gland-tubule, may be the cause of a local increase of pressure, which bursts the basement membrane, and the infected cells extend in consequence inwards along the lines of least resistance into the lymphatic spaces, and not outwards through the hardened epithelium of the "wart" or "pimple."[1] In these channels the arrangement takes place which is more or less typical of the situation from which the cells are derived.

When ulceration occurs around the tumour the lymph-spaces

[1] Amongst other views as to the cause of the local spread are the migration of nuclei through the basement membrane (Harrison Cripps), and the budding out of cell-processes through the membrane which may grow until they become solid cylinders of cells (Eve).

are probably still less protected, and therefore more accessible to the infected epithelium. In fact the latter may be thought of under these circumstances as more easily reaching the capillary lymph or blood-channels. The increased vascularity attending ulceration may accentuate the epithelial proliferation, and this in its turn may aid in the more speedy infection of the system. In tubercle also, ulceration, it may be noted, increases the rapidity of general systemic infection. Further, the ease with which a poison is absorbed from an ulcerated cutaneous surface is a matter of every-day experience.

A general tubercular infection has been observed to follow operations on localised tubercular lesions, but this appears to arise only when the operation is not performed away from the seat of disease. A similar event has been observed in some cases of cancer. In ulceration following carcinoma, the infection is hastened, as evidenced by the rapidity of the secondary growths, and this appears to indicate an increased passage of infective material.

Erichsen remarks (loc. cit., p. 1011), "Coincidently sometimes with the implication and ulceration of the skin, secondary growth takes place in the lymphatic glands, and most commonly with the supervention of constitutional cachexy."

Mr. Birkett, in his article on "Carcinoma of the Breast" ('Holmes's System of Surgery,' 3rd edit., p. 457), states that generally the integuments are more or less implicated before the lymphatic glands are deeply involved; and the same statement is repeated by Mr. Bryant in his 'Practice of Surgery,' vol. ii, 3rd edit., p. 252.

In a carcinoma the exterior of the epithelial column is freely bathed in the lymph of the channel which it occupies; and in this fact may be explained the immunity of the cells from the possible harmful results of their own activity, since their products are readily carried away by the lymph-stream.

The pathology of infective tumours is altogether much less difficult of conception than is that of those which are benign. Those of the latter that are "continuous" might perhaps be best looked upon as "variations," which do not persist since they bring no advantage to their possessor. The local accumulations of fat, however, which are seen in certain races (*e. g.* on the buttocks in the Hottentot) may be exceptions; these might be regarded as persistent variations of the nature of "continuous" tumours. In this view benign tumours are allied to monstrosities by excess. But a carcinoma, charac-

terised as it is by its essentially infective character and fatal tendency, cannot, we hold, be rightly classed amongst the same growths; it can indeed no more properly be called a "variation" than might the lesions due to tubercular infection or the pigmentation of the skin in Addison's disease.

We are not, however, prepared to admit at present that the theory of "variations" offers a completely satisfactory explanation of the occurrence of *benign* tumours which are *not continuous* (as is a diffuse lipoma, or an exostosis) with normal tissues; which seem to have a life-history of their own, that is independent of the state of general nutrition of the subject whom they grow; and which in some families at least appear to alternate in different individuals, and in succeeding generations, with cancerous growths.

And in this place we may note the considerable variations that are met with in the degree of infectiveness of malignant tumours. Some tumours, indeed, which have the anatomical characters of carcinomata remain almost quiescent for considerable periods. This is observed in the history of some palatine tumours which, although more or less encapsuled, have nevertheless the anatomical structure of carcinoma. Some carcinomata and sarcomata appear as limited or localised as are some of the masses of caseous tubercle that are sometimes found accidentally after death in different organs of the body.

c. *The cancerous cachexia.*—There are still other obscure points in the pathology of cancer that would receive elucidation if the parasitic theory be true. Amongst these is the cancerous cachexia. This, although largely explicable on general principles,—the interference with the functions of the affected organ, pain, mental depression, and later the septic processes arising from ulceration or sloughing, may be nevertheless in part due to the presence of the tumour itself as such. For it is characteristic of pathogenic micro-organisms to give rise to chemical products which are the real source of the evil resulting from their growth; and it may be that in cancer a deleterious product is continually being carried off from the substance of the tumour by the lymph-stream, and thus into the general circulation, and that it may in this way be the cause of a direct impairment of the general health, or of a peculiar "cancerous" cachexia.

The general rise in temperature that is noticed during the growth of some tumours, wholly independently of any inflammatory pro-

cess, points to the same result, to the transmission of a deleterious substance into the circulation from the new growth, and to the subsequent effects on the heat centre, which are assumed at present to be the intermediate source of fever.

D. *The phenomenon of atavism.*—It is within our knowledge that whilst the first and third generations of a particular family were devastated by cancer[1] the second wholly escaped.[2]

Without discussing the important laws of atavism it might be submitted that the above facts imply a passing change in a constitutional character or predisposition. The minute differences of "constitution" may arise from the same class of causes that obtain in the grosser anatomical variations which mark reversion to previous ancestral types, and in this way the "predisposition" to cancer may fail of development in one generation to develop again in the next. There are, however, other views more directly related to the parasitic theory of the nature of cancer.

The abrogation or change of diathesis (for cancer not only passes over certain generations, but appears in different generations under different forms) may arise from a temporary impoverishment of the peculiar soil or diathesis, which impoverishment results from the activity of the parasite. The phenomenon, in short, would be comparable to that which necessitates in agriculture a rotation of crops.

In this inquiry statistics on the largest scale could alone furnish a basis for right induction; or the atavism might depend, not on the subject, but on the parasite itself, the life of which might furnish an instance of alternation of generations; it might be productive of actual disease in one period and be inoperative at another.

E. *The rate of growth.*—Again, such chemical products may under certain conditions have a more local action and affect the growth of the tumour itself. Pathogenic micro-organisms will eventually destroy themselves by means of the chemical products to which their activity gives rise, and this fact raises the possibility of a partial cessation of growth in malignant tumours due to this cause, or at least to irregularities in the rate of growth of such tumours.

[1] Paget, 'Lectures on Pathology,' 1st edit., 1853, vol. ii, p. 540:—"The tendency which exists in the parent may never become in him or her effective, although it may become effective in the offspring."

[2] Atavism also occurs in tuberculous families, (see Bristowe's 'Practice of Medicine,' 1st edit.,' 1876, p. 431):—"Parents seemingly healthy may beget a family of children who all die of phthisis." The "taint" is latent *in transitu.*

But the resistance offered by the tissues, or the general impairment of nutrition in different persons or in the same person at different times, must be also taken into account in such an argument, for it is of common experience that tumours in young persons grow with great rapidity, whilst those in the aged, whose nutrition is defective, may grow very slowly for many years, and never affect the general health. We have seen a woman eighty-five years of age, whose breasts and axillary glands had for fifteen years been invaded by scirrhous carcinoma: one breast and one axilla were slowly ulcerating and yet the patient (who had never suffered any pain) presented no indication of ill-health or loss of strength.

F. *The alleged antagonism between cancer and tubercle.*—But there is a certain amount of evidence of a highly interesting kind as regards the antagonism of cancer and tubercle. Reasons are adduced for this belief, which originated with Rokitansky, by Sir James Paget,[1] and it was the teaching also of the late Dr. Murchison. Cases seem to show that if these two diseases coexist, one, usually the tuberculous process, will decline as the other advances. That is to say, the lesions indicating these diseases are not found in active progress at one and the same time.

Sir John Simon writes to us in a private letter that whilst he was able to see that the two diseases were not mutually exclusive, even in the one person, and still less so in given family stocks, nevertheless, his general impression was that though the two diseases might in some measure coexist in one body, they at any rate expressed rival forces or required different predispositions, and the vigour of one would be inconsistent with the vigour of the other.

Now, it is a well-established fact that certain micro-organisms are destructive of others—if not in an active at least in a passive sense—viz. in the sense that they grow more vigorously, and thus survive as the fittest of those which have commenced to grow with them. It is possible also that one organism may, by virtue of the chemical products to which it gives rise, be really destructive of others. The parasitic theory of cancer offers therefore a possible explanation of this clinical and pathological phenomenon. The tubercle bacillus and the parasite of cancer may be in some degree antagonistic.[2]

[1] 'Lectures on Surgical Pathology,' 4th edit., pp. 640 and 785; 1st edit. (1853), vol. ii, pp. 337 and 537.

[2] See "Remarks on a Case of Colotomy," 'St. Thomas's Hospital Reports,' vol. xv, p. 199.

As germane to the same question we may instance those exceedingly rare cases in which, under the influence of some fever,[1] a cancer has been known to wither or slough off.

Fehleisen's remarkable attempt to apply the principle here involved to practical therapeutics is worthy of deep attention. Fehleisen inoculated cancerous tumours and lupus with pure cultivations of the micrococcus of erysipelas, and he reports beneficial results from this method of treatment.[2]

Many authors had previously recorded a similar result in cases where erysipelatous infection had accidentally occurred. The disappearance of a keloid of the abdominal wall under the same circumstances was observed not very long ago at St. Thomas's Hospital in a patient of Mr. Anderson's. The growth reappeared, however, some months later, but the man would not not enter the hospital for therapeutical inoculation; he returned a year later with extensive disease of the thoracic wall and died.[3]

5. Cultivation Experiments.

A. *New growths.*—The tumour immediately after its removal was taken from the operating theatre to an adjoining room, and portions were at once removed by means of sterilised scalpels and transferred to tubes of beef-peptone jelly, beef-peptone agar-agar, and solidified blood serum. The knives were sterilised by heating to a low red heat in the flame of a spirit lamp, after which they were placed edge upwards on a stand and allowed to cool without the blade coming in contact with any surface. Three fresh knives, and sometimes five or six, were used for the removal of each piece of the tumour. With one knife a portion of the surface was sliced off, with a second knife a deep incision was made into the tumour at right angles to the pared surface, and then with another knife or knives a wedge-shaped or square piece, averaging half an inch in its chief measurement, was cut away from one of the edges resulting from the previous incisions. The detached piece was then

[1] Paget, 'Surgical Pathology,' 1st. edit., vol. ii, 1853, p. 538; 4th edit., 1876, p. 786.

[2] 'Die Ætiologie d. Erysipels,' 1883.

[3] Cases of spontaneous resolution of goitre are stated to have occurred also after acute fevers; and perhaps the resolution that sometimes ensues after division of the isthmus in goitre is explicable on the same grounds, for fever is very common after this operation, even when no putrefactive processes affect the wound.

transferred on a loop of platinum wire (sterilised in the flame) to one of the cultivating tubes. Other pieces were subsequently removed in a similar way, every detail being again repeated, and none of the surfaces exposed in the first case being used in any of the others. The tubes were placed in a Babes's incubator, which was maintained at a temperature of 100° F.

In this manner we have experimented with three lipomata, one myxoma, one sarcoma, and many carcinomata.

The results yielded by this particular method, and the particular cultivating media mentioned, may be described in a single word as being negative.

We have disregarded some of our first experiments as unsatisfactory owing to various flaws in technique, which are, in such investigations, obviated only by experience and the acquisition of a certain amount of skill and rapidity of manipulation. In our later experiments the whole time occupied in the removal and transference of each "lump" averaged thirty seconds, and sometimes it was even less.

We exhibit portions of three lipomata that remain perfectly sterile after respectively seven, twenty-one, and thirty-five days' incubation at 100° F., and portions of a myxoma sterile after an incubation of thirty-three days.

These specimens have been kept since their removal from the incubator until the present occasion, the only additional precaution adopted being that of sealing the ends of the tubes with gutta-percha tissue; and as they have undergone no perceptible change it would appear that they may be kept for an indefinite time in the same condition. No difference is observable in any respect between such benign tumours and the carcinomata with which we have experimented; and side by side with the above specimens we exhibit portions of many carcinomata of the mamma sterile after various periods of incubation up to thirty-three days. The carcinomata used were almost, without exception, tumours of the mamma. These were chosen in order to keep the problem as free as possible from the complication that might arise from external contamination. The pieces incubated on the solid media have undergone no naked-eye change whatever.

In our later experiments a very small proportion of the specimens in each case showed any growth. In some, every portion has remained sterile on the agar, serum, and in or on the gelatine.

In certain cases the absence of sterility admitted of explanation by reason of the great toughness of the tumour, which necessitated an unusually long exposure for cutting, seeing also that the knives used had previously been on different occasions heated to redness. In one case in which inguinal glands infected with squamous-celled carcinoma from the sole were used, the failure may be ascribed to the fact that the primary tumour had long been ulcerated. It may be well to note here that the gelatine tubes were almost always incubated like the others at 100° F., but in a few cases one or more tubes (of gelatine) were kept in a warm room at a temperature which did not liquefy the medium. When a growth occurred it invariably took, on the serum or agar, the form of a thin milky white or pale yellow film spreading from the piece of the tumour with a sinuous or wavy outline over the surface of the cultivating medium. In the liquid gelatine, the first indication of growth was cloudiness in the upper part of the fluid. Cover-glass preparations of these growths stained with fuchsin, display different forms of cocci from the surface of the solid media; in the liquid gelatine, rods, short and long, and streptococci were at different times discovered. The organisms are the same apparently as those described and figured by different observers as occurring in healthy living tissues; the evidence on which the latter view rests being the discovery of such forms in the tissues of apparently healthy animals upon incubation after other methods of experimenting.

B. *Normal tissues.*—Having found that we could maintain portions of living tumours sterile under the most favorable conditions for growth, we felt bound to experiment again upon the subject of micro-organisms in healthy living tissues. This question indeed in the present inquiry is of primary importance, and yet nothing could be more conflicting than the statements made in this respect by different observers. Lister,[1] Cheyne,[2] Meissner,[3] &c., report negatively on this subject, while Tiegel,[4] Burdon Sanderson,[5] Mott and Horsley,[6] and others report that they fail to keep organs

[1] 'Quart. Journ. Micr. Sci.,' April, 1878; 'Trans. Roy. Soc. Edin.,' 1875 'Trans Path. Soc.,' 1878.

[2] 'Pathological Transactions,' 1879.

[3] 'Deutsche Zeitschrift f. Chirurgie,' vol. xiii.

[4] 'Virch. Archiv,' 60, p. 453.

[5] 'Brit. Med. Journ.,' 1878.

[6] 'Journal of Physiology,' vol. iv, No. 3.

or portions of organs sterile. We do not intend to criticise the methods adopted by these different observers, or to attempt any explanation as to how such contrary results have arisen, but merely to record our own experiments and to notice the method adopted, which appears to us at least devoid of fallacy. It would indeed have been remarkable if cancerous tissue was sterile and healthy organs were not; and to make the test the more searching we chose especially to experiment with glands which communicate externally by means of ducts, and in which it was conceivable that certain micro-organisms might so to say "naturally" be present.

Briefly, the mode of experimenting was precisely that before detailed as adopted in the case of tumours, q. v.; no antiseptics whatever were used in these cases, and the results therefore are free from this possible source of error. In a certain minority of specimens growth occurred from the incubated tissue. The great majority of the tubes remained sterile. We have experimented with *muscle, testicle, submaxillary salivary gland, kidney,* and *liver.* The result has been that with few exceptions we have been able to keep portions of these organs perfectly sterile after incubation at 100° F., for various periods of from one to three weeks. The tubes, moreover, have undergone no change since their removal from the incubator. The experiments with the liver have been the least successful of all so far as the maintenance of sterility is concerned, a fact which may perhaps be explained by the free communication of the bile-ducts with the intestine, and by the direct association of the intestinal circulation with this organ. This result corroborates Mr. W. Cheyne's work of a few years ago. Large pieces of kidney show no alteration after prolonged periods of incubation, a fact which harmonises with Sir J. Lister's experiments as to the sterility of normal urine.

When the cultivating media showed growths, the latter were found on examination to be identical with those already described as occurring in certain of the experiments made with tumours. In different instances micrococci and megacocci, streptococci, B. termo, and short and long rods were seen. Cocci were almost invariably found on the solid media when growth occurred on them, and the rod forms were most common in the liquid gelatine; and, further, cultivations were made from the air and water of the room in which our incubator was placed, and the same organisms were discovered in these tubes as had previously been found growing in

those containing pieces of tumours, or normal tissues which had not remained sterile.

6. Conclusions and Suggestions.

A. That since no growth occurs under the most favorable conditions on serum, agar-agar, or in or on Koch's beef peptone jelly, therefore, in the particular healthy living tissues experimented with, there are no micro-organisms (in the usual acceptation of the term) capable of development. It is to be noted in this relation that all known micro-organisms admit of being cultivated on one or more of the above media, and that the cultivation test is the most delicate of all at present discovered.

B. That the same statement is true as regards malignant new formations.

C. Nevertheless, the circumstantial and comparative evidence appears to be so complete that we do not doubt that cancer is, in its essential pathology, a parasitic disease. It may be that a process of cultivation more nearly allied to the natural is indispensable, that in the place of a dead medium it is necessary to use one which is either potentially or actually alive, and that possibly the living soil must be furnished by a constitution predisposed to the disease; in other words, contain that chemical or physical something essential for the manifestation of cancer.[1]

D. That with respect to the nature of the parasite itself, it may be allowable to conjecture that it possibly does not belong to the Protophyta, but to the Protozoa. If this be the case it is probably of the naked[2] kind, and would, like the Gregarinæ, live upon the nutritious juices of the tissues in which it resides.

The number of species increases so vastly as an approach is made to the first beginnings of life in the animal and vegetable kingdoms, that future investigation will probably disclose the existence of many organisms, the structure and physiology of which are as yet quite unknown. It may be safely affirmed that if the infecting agent of cancer belongs to the Protophyta it must be of a very special kind.

[1] Alibert inoculated himself and some of his pupils with cancer, without result; but no final conclusion can be drawn from this fact alone as to the nature of ancer. Doutrelepont and others have obtained the same negative results in similar experiments with dogs, &c.

[2] See article "Protozoa," by Professor Lankester in the 'Encyclopædia Britannica.'

On the hypothesis that the carcinomatous parasite is a Protozoon, we suggest that some light would be thrown on the following obscure points in the life-history of the epithelia in carcinoma, and this elucidation would in itself be an argument in favour of the retention of the idea as a working basis for inquiries in the future.

At the outset the question may be asked, How is the infection communicated to the epithelium? How is the function of the first infected epithelial cell changed from a benign to a so-called malignant character? We surmise that it may be in one or more of the following ways:

(1) By inoculation arising from contact with the specific Protozoon, or by absorption of a chemical product which is secreted by the parasite. In this manner an indefinite number of cells might be infected by one specific organism and by its descendants.

(2) By the passage into the epithelial cell of the organism, the latter maintaining a separate existence in the former, and possessed or not possessed of the power of leaving the cell first infected and entering another. In the former case the young only of the infected cell would be cancerous.

(3) By the process of rejuvenescence, in which the flagging life of a Protozoon is revived by means of its temporary or permanent union with one another.

The spermatic theory is like the parasitic, in that in either case a contact is implied between the infecting cell or its secretion and the neighbouring elements as yet uninfected.

There is one other question to which a reply may be attempted: What happens to the epithelial cell which is first infected? Is the cancerous process limited to it and to its offspring, or do the neighbouring cells become infected?

We have already pointed out that the gross indication of infection of an epithelial cell is an abnormal activity—an extraordinary manifestation of its power of multiplication. Now, although single binary division is the chief mode of reproduction, it is also very usual for Protozoa to break up into from 10 to 100 or more little pieces or spores. In these cases the nucleus is not visible or has disappeared ("pulverisation of nucleus"), so that each piece contains all the elements of a perfect cell. Another method of multiplication is by the nipping off of spores from the parent cell ("budding"). If the carcinomatous cell has a similar life-history

it would probably follow that the malignant process is not limited to the young of the cell first infected. The pieces or spores of the parasite itself, or of the infected epithelial cell, when set free, may be thought of as conjugating with the surrounding normal epithelium, and being the *fons et origo* in it of a carcinomatous rejuvenescence.

Note.—To the surgeons of St. Thomas's Hospital we desire to tender our best thanks for so freely placing at our disposal the tumours removed by operation. We have also to thank Mr. Horsley for leave to carry out part of the investigation at the Brown Institution, to express our obligations to Mr. Richard Quain, and to acknowledge the pecuniary aid afforded in the research by the Scientific Grants' Committee of the British Medical Association.

Table of Experiments with Healthy Living Tissues.

Exp. 1.

Tissue.	Serum.	Gelatine Peptonized.	Agar.	Result.
Muscle from limbs	8	3	5	13th day—sterile.
Liver	2	...	...	8th day—sterile.
Kidney	1	...	...	„ sterile.
Exp. 2.				
Muscle from limbs and masseter, &c.	...	3	4	20th day—sterile.
Testicle	1	2	3	„ „
Submaxillary gland	...	1	2	„ „
Kidney	...	1	1	„ „
Liver	...	2	1	„ not sterile.
Exp. 3.				
Muscle	1	2	5	12th day—1 serum, 2 gelatine, 3 agar, sterile.
Testicle	1	1	3	12th day—1 serum, 2 agar, 1 gelatine, sterile.
Kidney	1	1	2	12th day—1 agar, 1 serum, sterile.
Liver	1	1	4	4th day—All putrid.

At the Society's meeting on May 17th, 1887, most of the above tubes were exhibited. This and the following table are intended to show the absolute number of tubes which remained sterile.

A Selection of Cases from Cultivation-experiments with New Growths.

No. of Experiment.	Nature of Tumour.	Clinical History.	Serum.	Agar.	Gelatine.	Result.
A . .	Scirrhus of breast	Female, aged 55, noticed 6 months; nipple not retracted; growth peripheral in situation. Operation Jan. 8th, 1887	1 inoc., 2 pieces	...	...	21st day—sterile.
B . .	Scirrhus of breast	Female, noticed 3 years; nipple retracted; axillary glands enlarged. Op. Feb. 7th, 1887	3 pieces	...	...	10th day—sterile.
C . .	Infiltrating scirrhus of breast	Female, tumour somewhat adherent to skin. Op. Mar. 26th, 1887	1 piece	2 pieces	2 pieces	33rd day—sterile.
D . .	Scirrhus of breast	Female, aged 50; nipple not retracted; growth peripheral. Op. April 30th, 1887	1 piece	2 pieces	1 piece	9th day—sterile.
E . .	Scirrhus of breast	Female; nipple not retracted; growth nearly central; skin not adherent; axillary glands involved. Op. May 10th, 1887	1 piece	2 pieces	2 pieces	7th day—sterile.
F . .	Infiltrating scirrhus of breast	Female, aged 45; nipple retracted, but free from disease; there had been discharge from the nipple. Op. May 10th, 1887	1 piece	2 pieces	...	7th day—sterile.
G . .	Scirrhus of breast	Female, aged 53; nipple not involved; skin adherent to tumour, but not ulcerated; tumour was about 1½ inches from nipple. Op. May 12th, 1887	2 pieces	2 pieces	2 pieces	5th day—sterile.
H . .	Lipoma from back	Young female. Op. Dec. 2nd, 1886	1 inoc., 1 piece	1 inoc., 1 piece	...	35th day—sterile.
I . .	Lipoma from shoulder	Male, aged 45. Op. Mar. 5th, 1887	1 piece	1 piece	...	10th day—sterile. Transferred to gelatine in which they were sterile on the 21st day.
K . .	Diffuse lipoma from loin	Female, aged 18. Op. May 11th, 1887	1 piece	...	1 piece	6th day—sterile.

A Selection of Cases from Cultivation, &c.—continued.

No. of Experiment.	Nature of Tumour.	Clinical History.	Serum.	Agar.	Gelatine.	Result.
L. .	Myxoma from thigh	Female, noticed 12 months. Op. Feb. 16th, 1887	1 inoc., 3 pieces	1 piece	...	6th day—sterile. One piece was transferred from the serum to gelatine, and 21 days later was sterile. Another piece was transferred from serum to gelatine on the 29th day, and 11 days afterwards was sterile. Both of the pieces were sterile on the 33rd day after the date of operation.

At the meeting of the Society on May 17th, 1887, almost all of the above tubes were exhibited and were sterile.

Addendum.

M. .	Sarcoma of thyroid	Male, aged 30. Op. July 6th, 1887	6 pieces	...	...	8th day — Four pieces sterile. Two pieces previously removed after 48 and 72 hours' incubation; these also were sterile.
N. .	Scirrhus of breast	Female, aged 56. Small tumour, peripheral; axillary glands infected. Op. Aug. 29th, 1887.	5 pieces	...	...	10th day—sterile.
O. .	Scirrhus of breast	Female, about 60. Infiltrating; axillary glands infected. Op. Sept. 2nd, 1887.	...	5 pieces	...	8th day—sterile.

DESCRIPTION OF PLATE XXV.

To illustrate Mr. Shattock's case of Microphthalmos (p. 321), and Mr. Ballance and Mr. Shattock's paper on Cultivation Experiments in Cancer (p. 412).

From drawings by Mr. Shattock.

FIG. 1.—A vertical section through the left orbit, showing the lids and lashes, and the conjunctival reflection behind and below, which is the diminutive globe lying in the fat of the orbit.

FIGS. 2—7.—From cover-glass preparations of various micro-organisms, stained with fuchsin, showing the forms found in cultivation experiments, with cancer and healthy tissues in which accidental contamination had occurred.

Fig. 2. Cocci.
Fig. 3. Micrococci.
Fig. 4. Streptococci.
Fig. 5. Large rods.
Fig. 6. Small rods.
Fig. 7. Rods and streptococci.

Fig. 1.

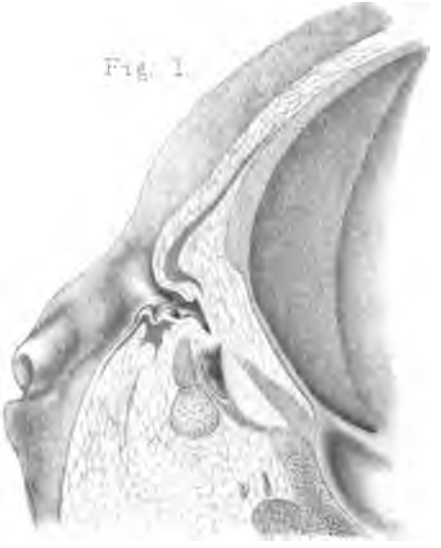

Fig 2

x 965.

Fig. 3.

x 965.

Fig. 4.



x 965.

Fig 5.

x 524.

Fig 6.

x 965.

Fig. 7.

x 965

S G Fraddock del

Mintern Bros sc

XII. MISCELLANEOUS SPECIMENS.

1. *Bacilli of leprosy.* (*Card specimen.*)

By Beaven Rake, M.D.

A drawing made from a preparation sent by Dr. Beaven Rake, of Trinidad, showing the relation of the bacilli of leprosy to the cells.

Dr. Rake compressed a leprous tubercle in the living subject, punctured it, and smeared the expressed juice on a cover-glass which he stained in fuchsine and methylene blue. The preparation shows that the bacilli are so intimately applied to the nucleus as to justify the belief that they are contained within the cells, as has been stated by most observers, an opinion which has been controverted lately by Dr. Unna, of Hamburg.

Remarks on Dr. Rake's preparation of lepra-bacilli.—The various observers who have studied the leprosy bacillus have described it as being chiefly found in the so-called "lepra-cells." Dr. Unna has lately published some observations by which he believes it is shown that the bacilli are not contained within the cells, but that groups or clumps of them lie in the connective-tissue spaces. Dr. Unna's statement has not received general assent.

Dr. Beaven Rake, utilizing an opportunity which was afforded him by his being in charge of a leper asylum, has examined this question. By compressing a leprous tubercle in a living subject and pricking the distended tissue he was able to obtain preparations of lepra-cells isolated from the tissues.

An examination of these cells stained on a cover-glass by fuchsine and methylene blue seemed to him to show that the bacilli are associated with the cells. I have examined a preparation of this kind sent me by Dr. Rake. In this preparation, as it came into my hands, the nuclei of the lepra-cells are well stained; but the pro-

toplasm of the cells is either not visible, or is very faintly indicated. The relation of the bacilli to the nuclei has impressed me in the same sense as it did Dr. Rake.

As the question is of general interest as regards the relation of pathogenic bacteria to the living tissue, I have had a drawing made of some of the appearances seen in Dr. Rake's preparations, and, with his consent, now submit it to the Society.

April 5th, 1887. G. THIN.

---

2. *Case of included ovum.*

By SEYMOUR TAYLOR, M.D.

FREDERICK C—, aged 11 months, was admitted to St. Thomas's Hospital under Dr. Ord, on August 12th, 1886, suffering from diphtheria. It was found necessary to perform tracheotomy whilst under treatment in the hospital, and he died on August 15th.

On making a *post-mortem* examination of the body, I found the usual conditions of fauces and air passages which are diagnostic of diphtheria, and I need say nothing further on this point.

When I examined the belly cavity, my attention was drawn to a tumour situated immediately behind the stomach, in the middle line. I carefully removed the stomach from its omental attachments, and then the tumour was found to be directly in front of the vertebral column, lying on the first and second lumbar vertebræ, and having the pancreas, with the splenic vein and artery, stretched over its anterior surface, whilst the inferior mesenteric vessels emerged from its lower border to cross the duodenum which was directly below. The abdominal aorta was pushed slightly to the right of the median line.

The tumour was not attached to the vertebræ by any fold of peritoneum, nor had it caused any erosion of the bones beneath. When removed, the tumour was about the size of a duck's egg, measuring 7 cm. vertically, 5·8 cm. transversely, and 5·1 cm. thick. It was also somewhat of an egg shape, the pointed end being upwards. It was distinctly nodular to the feel, and was covered

by a loose-fitting tunic which could be easily moved over a lumpy but somewhat greasy surface.

I may at this point confess that I had no notion that I was examining a specimen of included ovum, but imagined it was some new growth in connection with mesenteric glands or with pancreas. Accordingly, I made a vertical transverse section, that is to say, in the longest axis of the tumour, from right to left as it lay in the host's belly. This was attended with difficulty owing to the resistance of the contained bony structures. The cut surfaces of the two halves then presented the following appearances.

On closely examining the specimen, which is really a vertical antero-posterior section, there is seen a rudimentary, but distinct, vertical column composed of definite, superimposed bodies of vertebræ. It is curved, as in the normal condition of the embryo, with the convexity on its dorsal surface, and the concavity on its ventral surface. Below, it terminates in a pointed coccyx, whilst above is a well-marked basi-occipital bone. Just below this are seen what I take to be the odontoid process vertically bisected with a rudimentary body of atlas in front, and a rudimentary atlas arch behind. The fœtus was therefore placed with its long axis corresponding to that of its host, with its anterior surface to the right.

Behind the bodies of the vertebræ is a groove running longitudinally, which contains the spinal cord, or what represents it, and its membranes, all of which can be traced upwards to a foramen, which they traverse, in the basi-occipital.

In the concavity formed by the bony vertebral column is a distinct sac which is probably primitive gut. The cephalic extremity is somewhat difficult to interpret; but there can be no doubt that the bony particles which are found here, represent a rudimentary facial portion of skull. Immediately surrounding the bony elements is an envelope of dense fat, measuring 1·7 cm. at its widest portion, viz. in the mid-dorsal region.

The external surface of the ovum is invested with skin, which is of a pale yellow tint, firm and distinctly follicular in character. The numerous depressions, however, do not contain hairs, the period being probably too early for their full development. Still there can be no doubt that this envelope is skin.

On this surface also are seen distinct rudimentary limbs, upper and lower, both of which are bent towards the ventral

aspect of the fœtus. The extremities of both the upper and lower limbs present bud-like projections for fingers and toes, and there is, in addition, in both limbs, a longitudinal groove showing the differentiation of radius from ulna, and of tibia from fibula.

There is a rudimentary bony pelvis to which the femur, although distinctly movable, is attached; whilst in the upper extremity the scapula and the rest of the shoulder-girdle is foreshadowed by a prominence corresponding in situation and in ontline with the various anatomical details thereof.

The outer membrane was not adherent to the fœtus except at its anterior aspect about its middle. Under this membrane was a thick layer of granular fatty matter, which suggested vernix caseosa, a surmise which proved correct, as on scraping it away with the handle of a scalpel the integument was discovered beneath.

The skin can be traced upward to the cephalic extremity and over the basis cranii. The fœtus may thus be considered anencephalous. How far the embryo had progressed in its development is somewhat difficult to state, and at the best we can only be conjectural.

I would, however, draw the attention of the Society to the following data, viz.:

(1) Length of embryo 7 cm.; this perhaps being a little in excess of its real measurement owing to the dense fatty envelope which surrounds it.

(2) Limbs distinct with rudimentary fingers and toes.

(3) Umbilical stalk.

(4) Face distinct.

(5) Alimentary canal entirely within the belly.

(6) Ossification of vertebræ.

These points would pretty well agree to the developmental condition of the fœtus at the tenth or twelfth week as described by Drs. Robert and Fancourt Barnes, in their work 'Obstetric Medicine and Surgery,' p. 96.

The preparation which is shown is therefore an example of the condition known as "included ovum."

Although it will doubtless be classified as a form of monstrosity, yet I venture to argue that it is not a "monster" in the true sense of the term. It is not a "fœtus more or less perfect, constituting a tumour, covered by integument," in the sense implied in the description contained in 'Nomenclature of Diseases,' p. 301. Nor

do the host and this preparation amount to a double fœtus, one perfect, the other an appendage, with contiguous or even correlated parts united in any portion of their axes; but it must be described as a "fœtus, more or less perfect, contained within another fœtus" which was perfect.

Turning for a moment aside to examine the development of the chick, it has been not unfrequently observed that within one completely formed egg, the shell and other envelopes being perfect, there has been found another (included) egg, with shell and envelopes also perfect. This condition is rightly termed "included ovum."

Now, as the shell is formed near the end of the duct, and not in the earlier portion, it has been suggested by scientific naturalists that this condition is accounted for by the normal peristalsis of the duct becoming reversed, so that an egg which was about to be protruded, again traverses the oviduct, and meets a second ovum which is on its way down, and which is not yet covered with a calcareous tunic. It thus becomes included within this second ovum, which in its turn becomes invested with lime salts. Thus arises a condition of true included ovum, the outer egg or host, however, being really the one which should in the normal condition of things have appeared subsequently to the inner one, or guest.

But here the analogy ceases. In my specimen the included fœtus must have been shut in at an early, not a late stage of development. The puzzle is, how has it got shut in? We can imagine two primitive streaks on one blastoderm, both making a race for perfect development and one outstripping the other; the more favoured one, by some influence or other, developing the faster, so as to partially absorb (not include) the other, and producing fusion of neighbouring or like structures, the result being a monster fairly developed, but developed at the expense of its twin embryo, which ultimately shows itself as an appendage thereof.

Obviously, this preparation cannot, as before pointed out, be an example of such a condition.

With our present knowledge of development I can only suggest one method by which an included fœtus can be produced.

Let us suppose an ovum having become impregnated makes its migration from ovary to uterus, the various stages of development such as the heaping-up of cells to form the blastoderm, and the

cleavage of the primitive layers to have occurred. This ovum now meets a second impregnated ovum, which may have descended from the same or the opposite ovary. This second ovum is invaginated into the first sideways as it were, taking with it its host's epiblast, and also the outer layer of the host's mesoblast, till such a stage arrives that the second ovum is enveloped by these two tunics which form the somatopleure, and which meet round this secondary ovum at the point of contact.

Finally, the cells of the host's epiblast coalesce, so that the second ovum is included within the first, but only so far as the host's epiblastic layer is concerned, the mesoblastic cells not coalescing. This method would place the included ovum in the situation where it was found, viz. beneath the parietes and behind the pleuro-peritoneal cavity. The theory may appear fanciful, but at present we can only theorise.

I contend that we have parallel examples of inclusion in the cellular stage of development.

We see the amniotic cavity shut off by a fusion of cellular layers which form the amnion; and even the shutting off from one parent sac, of pleura, pericardium, peritoneum, and also tunica vaginalis, may be cited as examples, which, if not exactly identical, are somewhat analogous.

I might also quote the development of the eye as illustrative of a similar phenomenon.

I would call the attention of the Society to a like preparation (No. 135 in the Teratological Series in the Hunterian Museum of the Royal College of Surgeons), but there is no evidence of spinal cord or membranes as in my preparation, although it has distinct lungs and also genital organs.

The admirable descriptive catalogue of this series is written by Mr. Lowne, and if I read Mr. Lowne's argument aright, the cyst containing the second ovum "originates in a common amniotic sac which it carries before it, and which secondary sac disappears, especially when it is remembered that the membrane must have been extremely thin at the time of its invagination."

I would also point out that the host was a male child, which, according to Mr. Lowne, is usual. I have not determined the sex of the included fœtus. *December 7th*, 1886.

3. "*Lithopædion.*" (*Card specimen.*)

By C. Stonham.

The specimen was removed from a woman aged 43, who died in the seventh month of pregnancy from bronchitis and ulceration of the trachea. There were no signs connected with the specimen, which was only discovered at the *post-mortem* examination. The larynx and trachea, with the atheromatous aorta, were shown, at a previous meeting of the Society, by Dr. Maudsley.

The fœtus is enclosed in a thick membrane, presumably the dilated and chronically inflamed Fallopian tube. Most of the anatomical parts can be recognised. The bones are, some of them, completely macerated. The soft structures are macerated and soapy in consistence. There is hardly any deposit of calcareous material in the cyst wall, and what there is is only on the inner aspect.

The specimen was removed from the right broad ligament; the left one was normal. The uterus contained a seven months' fœtus, which was apparently living at the time of the mother's death, since it showed no signs of maceration.

The patient, S. S—, was under the care of Dr. Sydney Ringer, in University College Hospital. *May 3rd*, 1887.

---

4. *Trunk of an infant, showing a persistent fœtal condition of the peritoneum.* (*Card specimen.*)

By C. Stonham.

In this specimen the whole intestinal canal, from the duodenum downwards, is enclosed in the folds of a mesentery; but the various parts of the gut maintain their normal relations to each other. The descending colon passes, however, straight into the rectum without showing any sigmoid flexure.

The mesentery connecting the descending colon is attached a little to the left of the middle line of the trunk; the length of this fold

is about two and a quarter inches (from the parietes to the gut), and is quite distinct from the mesentery of the small gut.

The fold enclosing the ascending colon varies from three quarters of an inch to an inch in length, and is directly continuous with and forms a part of the small gut mesentery.

The covering of the transverse colon is partially continuous with that of the ascending and small intestine, and partly with that of the descending colon.

The attachment of the descending meso-colon is almost vertical, and much nearer the middle line than usual; this represents the original vertical peritoneal fold.

The specimen is of importance as bearing on the etiology of intussusception and volvulus. The child died of tubercular meningitis.

March 15*th*, 1887.

---

5. *Congenital abnormality of lower lip associated with cleft palate.* (*Card specimen.*)

By H. H. Clutton.

[With Plate XXVI.]

The patient was a single woman aged 24, who came from Wales on account of a cleft palate, and was admitted into St. Thomas's Hospital during September, 1886.

The accompanying drawing shows a fold of mucous membrane on the inner surface of the lower lip. It is exactly central in its position, and of a triangular shape, the apex of the triangle being the most prominent part. At each extremity of its base is a small dimple, which looks like the opening of a duct or sinus, but a fine probe cannot be introduced beyond the bottom of the depression.

From the history it appears to be congenital, and the only explanation of this condition, if it were acquired, namely, traction by pressure between the teeth, was proved to be absent. She has, at the present time, no teeth in either jaw, and the plate which she wears cannot press the fold against the lower jaw. Her teeth

DESCRIPTION OF PLATE XXVI.

The drawing illustrates Mr. Clutton's case of Congenital Abnormality of the Lower Lip. (Page 446.)

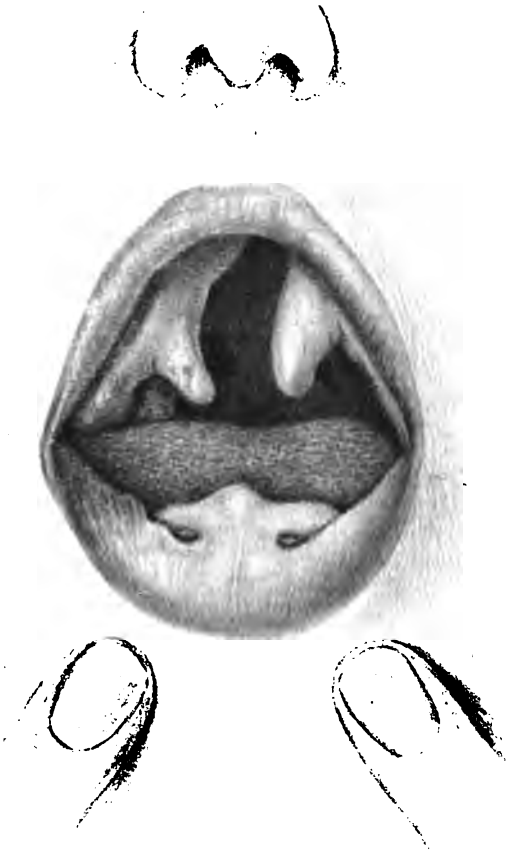

F. Huth, Lith.r Edin.r

had always been bad, and were all removed at nineteen years of age. She does not remember, at any time of her life, being able to catch this fold between her teeth.

The cleft palate was successfully closed by Langenbeck's muco-periosteal flaps. *February 15th*, 1887.

---

6. *Congenital malformation of hand.* (*Card specimen.*)

By Sydney Jones.

F. R—, female, aged 11, was admitted into St. Thomas's Hospital on October 19th, 1886. Patient is one of five children; not one of the others is in any way deformed, and there is no history of deformity on either the father's or mother's side. Description by Mr. R. F. Walker, dresser: The left hand looks very much like a foot (see Woodcut 16); the fingers, the distal phalanges of which only are present, being all in a line; and the palmar surface is hard and rough like the sole of the foot. The whole arm is smaller than the right and half an inch shorter. The lower ends of the radius and ulna can be plainly felt, only two carpal bones, the middle and inner one of the first row, and only one metacarpal bone, rudimentary and apparently belonging to the thumb. The distal phalanges only of the fingers are

Woodcut 16.

present, and they are not connected to the rest of the hand by any articulation.

The whole hand can be voluntarily slightly flexed and extended; but the fingers cannot be moved independently. The child seems healthy, and has no pain nor discomfort beyond the loss of use.

After consultation with Mr. Ernst, it was determined that no apparatus could be adapted to the malformed hand, that the best

plan was to amputate just above the wrist-joint—so as to allow of an apparatus to be applied soon after healing, and later in life of adaptation of an artificial hand. The hand was accordingly amputated by Mr. Sydney Jones on December 1st.

The hand and cast are in St. Thomas's Hospital museum.

December 7th, 1886.

---

7. *Hydatid of the breast.* (*Card specimen.*)

By C. J. Symonds, M.S.

Removed from the right breast of a married woman aged 30. It was first noticed two years ago, just after weaning a child. She has suckled another since then.

The cyst was situated in the upper part of the breast and extended to the nipple. It was about three inches from above downwards, abruptly circumscribed and movable in all directions over the deeper structures. The skin over it near the nipple was inflamed. There was distinct fluctuation. When punctured the usual watery fluid characteristic of hydatid escaped. It became slightly opalescent. No hooklets were found in it. The cyst was extirpated through a vertical incision. A little pus was found in the tissue over it near the nipple. When removed the tumour was translucent. On section it showed a thick capsule of condensed inflammatory tissue within which was the hydatid membrane. There were no secondary cysts. It seems to be an example of the *Cysticercus cellulosæ.*

January 4th, 1887.

---

8. *Hammer toes.* (*Card specimen.*)

By Samuel G. Shattock.

The third or fourth toes from each foot, removed by amputation through the metatarso-phalangeal articulation.

The joint between the first and second phalanges is flexed to a right angle; that between the second and third is very slightly hyper-extended. There is a corn over the summit of the convexity, and beneath the corn a well-defined pressure bursa.

By moderate force the flexed joint may be fully extended, and on being again flexed from the extended position the resistance suddenly diminishes when the joint has nearly regained its malposition, which is reached abruptly and almost with a jerk.

A careful dissection of the tendons and ligaments of the affected part displays nothing obviously abnormal. Indeed, all that appears to account for the alterations in the movements referred to is an unnatural shortness of the lower portion of the lateral ligament.

From dissection of the lateral ligaments in the normal toe it will be found (after all the surrounding structures other than the ligaments have been removed), that in the movement of flexion the lower fibres of the lateral ligament are relaxed, whilst the upper become tense, and that in extension the lower fibres become tense, the upper, on the contrary, becoming relaxed. It will follow, therefore, that if the flexed position be long maintained the lower, or in this position the relaxed, fibres will undergo adaptive atrophy, and so hinder extension of the joint. Of the cause of the malposition, nothing can be deduced from the dissection.

The fibro-cartilaginous flexor plate offers nothing for consideration; it certainly does not become interposed between the articular surfaces during extension, as has been surmised. This is shown by flexing and extending the bisected specimen on a sheet of glass, through which the interior of the joint may be viewed.

December 21*st*, 1886.

9. *The parts after removal of the ovary six months previously.* (*Card specimen.*)

By Samuel G. Shattock.

The interest of this specimen lies in the condition of the pedicle after the application of a silk ligature. The ovary was removed by Mr. Knowsley Thornton; it was the seat of a large cyst, from the interior of which there projected papillary outgrowths.

The patient died six months subsequently from general sarcoma infection, the lungs being completely strewn with tumours; there were others in the liver, and one in the brain.

The tissues forming the broad ligament are quite lax and normal. There is a narrow well-formed band of adhesion, about an inch and a half in length, passing from the seat of ligature to the neighbouring part of the large intestine. The ligature could be felt on rolling the tissues between the fingers, otherwise there was no indication of its presence.

On dissection, it was found closely invested with a delicate film of granulation tissue, but in itself absolutely unchanged.

November 2nd, 1886.

XIII. DISEASES, ETC., OF THE LOWER ANIMALS.

1. *Diseases of the genito-urinary organs in animals.*

[With Plate XXVII.]

By J. Bland Sutton.

The cases to be related in this paper are in continuation of my investigation into the diseases of animals, especially those dying in the Gardens of the Zoological Society. It is undesirable to burden the 'Transactions' with repetitions of specimens described in my previous communications, but it is necessary to state that no opportunity has been lost of testing the views which I have expressed regarding diseases of the reproductive organs in animals. The abundant material at my disposal has enabled me to demonstrate, beyond any question, all the statements which I have made before the Society, especially those with regard to the frequency of disease in the female reproductive organs. The present cases are of interest, some from their rarity, others from their severity, and the remainder from a general point of view.

Renal and vesical calculi.—The occurrence of renal and vesical calculi in domesticated animals is well known, especially among horses and dogs. I have examined a large number of cases of calculi in connection with the urinary organs of horses, contained in museums, and it is easy to see that in this animal they give rise to precisely the same effects as in man. They may originate in the kidney and be retained in the renal pelvis, or descend the ureter and remain in the vesical segment of this duct, thus leading to dilatation of the ureter, and subsequent sacculation of the kidney. Should the calculus gain the bladder it will form the nucleus of a vesical stone. Although stone occurs with tolerable frequency in domesticated, it is very rare in wild animals. A case of vesical calculus which was found in a field-mouse has been recorded in the 'Transactions,' vol. vii, p. 40, by Dr. Gibb. This

makes the following specimen more interesting. It is the kidney of a three-toed sloth which had lived in the Zoological Gardens twelve years. The pelvis of the kidney is completely occupied by two calculi, the larger weighing 12·83 grains, the smaller one about 1 grain. The kidney was in other respects normal. The exterior of the calculus is composed of oxalate of lime, as determined by Mr. Foster, Lecturer on Chemistry at the Middlesex Hospital (Plate XXVII, fig. 1).

The following case is noteworthy in its relation to the retention of secretory products. Whilst examining the viscera of a hog-deer, *Cervus porcinus*, the uterus was found to be enormously enlarged, and, suspecting pregnancy, it was opened, but nothing except a thick, viscid, brown-coloured fluid escaped. The changes will be best understood by reference to the drawing on Plate XXVII, fig. 2. On comparing the two specimens it will be seen that the left uterine cornu is enormously distended; the right one is also dilated, but not to the same extent as its fellow. The cervix uteri is the seat of a very curious change, presenting in four situations a diaphagm with a small, rounded perforation in the centre with smooth edges. The upper diaphragm corresponds to the internal os, whilst the fourth represents the external orifice of the cervical canal, but the intermediate septa and the three distinct cavities in the corresponding part of the uterus are difficult of explanation at present. The walls of the vagina were in a curious condition, for the surface of this canal was beset with mucous cysts, varying in size from a millet seed to a cherry, and presented an appearance not unlike a coat of mail. Regarding the cause of the distension of the uterus I can offer no explanation.

The next specimen is the uterus and appendages of an agouti. On opening the abdomen both uterine cornua were found very distended, and care was exercised, thinking the animal was pregnant. The coils of intestine were found matted with recent lymph, and from the cavity of the peritoneum pus issued. On examining the left ovary an abscess was found in its parenchyma. On opening the uterus the left horn was also found to contain a large quantity of pus which oozed freely from an aperture connecting it with the ovarian abscess. In the right uterine cornu a piece of placenta and a fragment of amnion were found, of the size of a walnut, but no trace of the embryo itself.

In this case the chain of events is tolerably clear, inflammation

DESCRIPTION OF PLATE XXVII.

To illustrate Mr. Bland Sutton's paper on Genito-Urinary Disease in Animals. (Page 451.)

FIG. 1.—Kidney of a sloth with an oxalate of lime calculus, weighing 12·8 grs. Nat. size.

FIG. 2.—The uterus and appendages of a hog-deer. The parts were enormously distended, and contained inspissated blood and mucus. The vaginal walls were covered with mucous cysts.

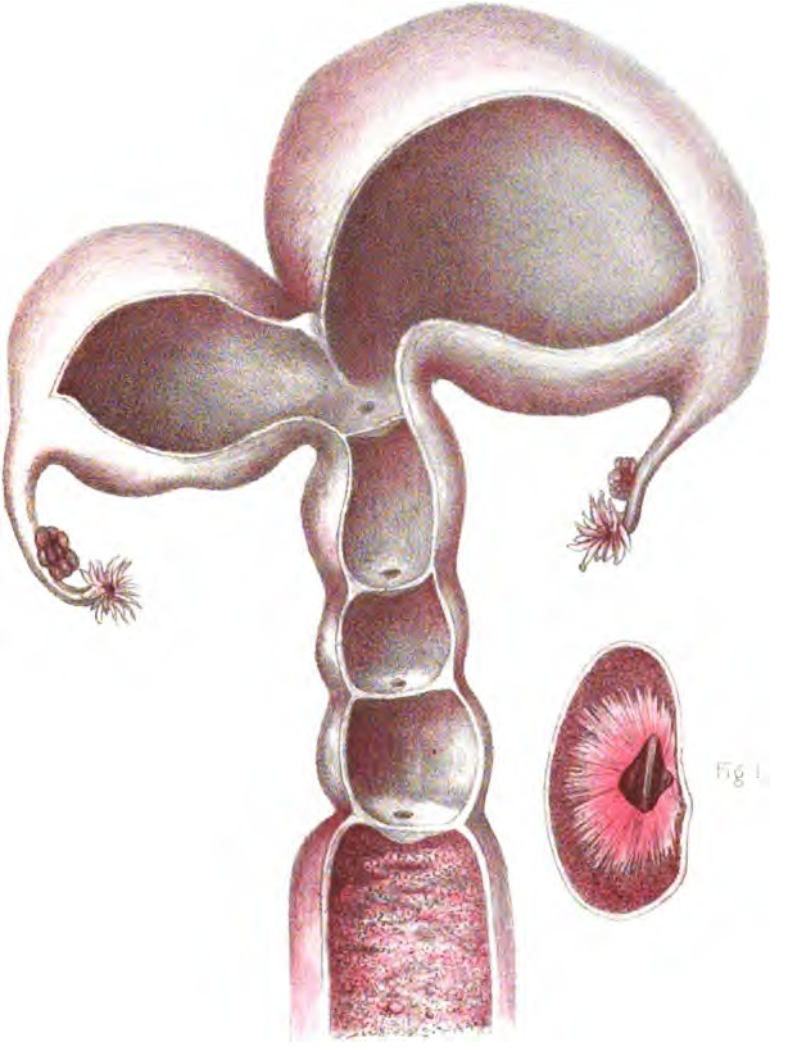

Fig. 1

Fig. 2

F. B. Osmond del.

Mintern Bros. Chromo lith.

of the left half of this bicornuate uterus, suppuration which extended to and involved the ovary, giving rise to an abscess. The condition of the parts corresponded exactly to pyosalpinx in the human female following pregnancy. The ovarian abscess ruptured, leading to fatal purulent peritonitis. The retained products of conception in the opposite uterine cornu may be accidental, but possibly the trouble in the left cornu may have its origin from some such cause. The two cervical canals open separately into the vagina in the agouti.

For the following interesting specimen I am indebted to my friend Mr. Bernard Lawson. It is well known that hens will occasionally lay eggs of very small size consisting of shell and albumen only. In many cases, especially with young fowls, it is due to the ovum failing to find its way into the infundibulum of the oviduct. In such cases the yolk falls into the peritoneal cavity and becomes absorbed, whilst the albumen and shell secreted by the oviduct to surround the lost ovum, are expelled in the ordinary course. In older fowls it is usual to believe that the ovum may, by accident, be tossed from the oviduct into the peritoneum. The case now before us admits of another interpretation. Fowls suffer at times from inflammation of the oviduct; this may be suspected when the shell is rough. In Mr. Lawson's fowl it was easy to demonstrate that the hen had inflammation of the oviduct; this spread upwards to the infundibulum, and involved the ovary, leading to firm adhesion between the two latter structures. Gradually the inflammation extended to the peritoneum, and this, aided by the continual dehiscence of yolks into the peritoneal cavity, brought about universal peritonitis, but the final sacrifice was made in obedience to my demands. The likeness this case bears to salpingitis in the human female is too obvious to need indication.

Specimens illustrating flexions of the uterus in monkeys have been exhibited from time to time, and I have pointed out that they may arise from rickety changes in the pelvis leading to displacement of the viscera, as well as from copulation when disparity of size favours the male. Such cases are very common. Recently an opportunity has befallen me of dissecting the parts in a Guinea baboon in which the flexion was more extreme than in any case yet observed by me, and in which neither of the previously mentioned conditions were operative, nor had the baboon borne young or had

had any opportunity of so doing. It is further interesting as being accompanied by some well-marked symptoms.

The uterus is enlarged, acutely retroflexed, and at the same time twisted towards the right side. The right ovary lies behind the uterus, the fundus of which directly pressed upon it. The left ovary was squeezed between the rectum and body of the uterus. All the veins belonging to the ovary and uterus were engorged with blood.

In another place[1] I have described the peculiar changes the macaques and baboons exhibit during menstruation. Now, this particular baboon was during the last few months of its life in a state of chronic menstruation; the labia and surrounding parts rendered it unpresentable, so it ended its life in solitary confinement.

During normal menstruation in baboons, the objective phenomena consist in the monthly escape of a small quantity of blood from the genital passage, accompanied by swelling and redness of the pale and comparatively nude parts of the body, such as the labia and ischial tuberosities; the cheeks also participate in the change of colour, and in a few days become of a lively pink. Associated with this congestion, is swelling of the labia and parts about the anus, until they present a condition of things comparable to the same parts in a woman suffering from extreme general anasarca.

The baboon whose case I have just attempted to describe, was, during the last few months of its life, in this state; it appears to have suffered from a sanguineous discharge at least once in each week, sometimes even at such short intervals as three days. The specimen is of value, as it is the only case in a monkey where I have detected symptoms directly traceable to a flexed uterus.

The rectum in the quadrumana, as in the human fœtus, occupies the middle line of the pelvis, and this, I believe, serves to explain the almost constant lateral tendency these flexions assume when the fundus is displaced backwards in monkeys.

In the last communication I made to this Society on "Diseases of the Reproductive Organs of Animals," an endeavour was made, as far as possible, to prove that corpora lutea are not infrequent sources of ovarian cysts, and some observations were recorded and specimens exhibited of cysts arising in this manner in the ovaries

[1] 'Gynæcological Journal,' part vii, p. 288.

of cows; arguments were also raised to show that some cysts arise in this way in the human ovary.

An apparent stumblingblock to this was raised in the suggestion that cysts may thus arise in girls after puberty and adults, but it failed to account for the cysts found in the ovary of the fœtus and infants.

The objection is of no value, for ova ripen, form follicles, and undergo suppression during the last month of intra-uterine life. This has been pointed out by De Sinéty, Waldeyer, and Beigel. These observations I can confirm in every particular.

During the past year I have examined the ovary of all fœtal mammals which have come under my notice, including species as widely different as kangaroos and lemurs; deer and monkeys; sloths and lions; and have had the satisfaction of finding that in all the same ripening and suppression of ova may be detected. There are good grounds for believing that the process is not confined to the mammalian subkingdom.

I am of opinion that we may divide the life of the human ovary into the following alternating periods of activity and repose. The first period extends from the seventh month of intra-uterine life to the end of the first year. Ova ripen in such abundance that in some cases a marked diminution in the number of the ova is appreciable at the second year after birth.

During this stage cysts are formed in abundance, which, like the ova, gradually become suppressed; occasionally, however, one will exceed the usual limits, and become recognisable clinically. To this succeeds a period of comparative repose, which terminates at the age of ten or twelve, when the ripening of ova is again easily detected, and goes on independently of menstruation, even after the accession of the climacteric period. Finally, the ovaries, like the skin, shrivel and become functionless.

So far as mammals are concerned, there is also a period of fœtal activity and an interval of comparative idleness before the advent of puberty.

Lastly, in monkeys, as in the human female, ovulation and menstruation are independent processes. Maturation of ova from the period of puberty until senility manifests itself is going on continually, and the existence of a ripe ovum or a recent corpus luteum concurrently with menstruation is a coincidence, for in a healthy woman a ripe follicle is always to be found between the tenth and

fiftieth year. The question needs extended inquiry and much labour. I should not have ventured to bring this fragmentary communication forward until the investigation was more complete, but material comes to hand in a very uncertain way, and the few facts recorded in this paper are of sufficient interest to justify them being recorded. *February* 1*st*, 1887.

---

2. *A curious effect of rickets on the skulls of young lions.*

By J. Bland Sutton.

It is a fact well recognised that when the skeleton of a mammal is affected by that remarkable disease, rickets, and particularly if the skull is much implicated, the bones most thickened in this part of the skeleton are those pre-formed in membrane.

A glance at the horizontal section of a cranium of a monkey (Woodcut 17) will serve to show the great thickening of the membrane bones of the skull vault. In severe cases the facial bones likewise share in this overgrowth.

On the other hand, the bones of the skull base, which are preformed in cartilage from some unexplained cause, become thinned, and in severe cases of rickets we have the extraordinary anomaly of a very thick cranial vault, and in the same specimen thinned and, in some cases, perforated cerebellar fossæ, as seen in Woodcut 18. This drawing was made from the skull of the most rickety monkey that has yet come before me.

A singular extension of this curious process has recently come under my notice in young lions. These mammals, in common with other carnivora, possess an ossified tentorium cerebelli. Such a tentorium, even in the largest lion or bear, consists of a lamella of bone of the thinness of writing paper.

I have described, in the 'Transactions' of this Society, cases of rickets in which a fatal result has been induced by the enlarged rickety vertebral epiphyses pressing upon the spinal cord and causing paraplegia. Recently a lion, eighteen months old, died in the Zoological Gardens with extreme paraplegia, and the condition

of the vertebral epiphyses was not such as to fully account for the paralysis. On examining the skull the bones of the vault were extremely thick and the tentorium extensively overgrown, resembling

WOODCUT 17.

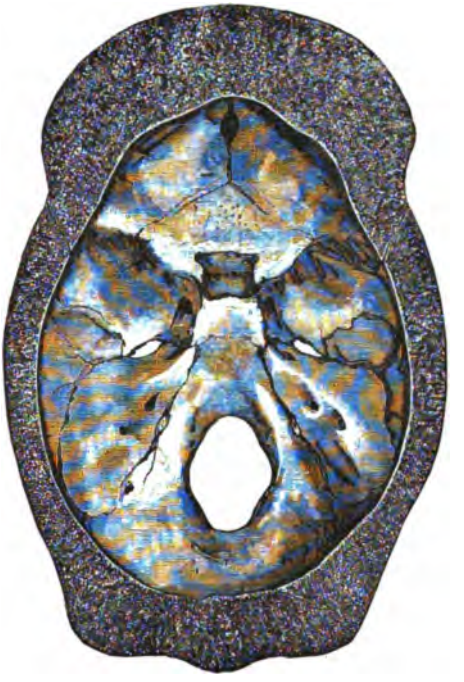

A horizontal section of the skull of a rickety monkey. The enlargement of the bones is confined to those pre-formed in membrane.

in fact a large exostosis. The slow but progressive enlargement of this plate had caused compression of the medulla oblongata, thus explaining the paraplegia and its fatal termination.

In the accompanying drawing (Woodcut 19), a longitudinal section of the skull of a rickety lion is shown. The increased thickness and absence of diplöe in the bones of the vault are well seen and the extension of the disease from the parietes to the tentorium. This lion was fifteen months old, and like its companions exhibited marked symptoms of paraplegia coming on gradually, and slowly increasing until death. This lion, like the preceding specimen, was born in the Gardens.

My third specimen is of great interest. Three cubs were born in the Gardens early in 1887. When two months old signs of paralysis became evident, and at the age of three months one of the

WOODCUT 18.

A view of the base of a skull of a rickety monkey, to show the tabetic perforations in the cerebellar fossæ.

cubs died. The opportunity was seized to freeze the skull and bisect it longitudinally in order to examine the effects of the pressure upon the brain. Truly the section exhibited a most remarkable condition. The tentorium was well ossified, very thick, and presented a smooth, well-rounded, anterior margin. This overgrown septum had pressed upon the vermiform process of the cerebellum, and occluded the upper part of the fourth ventricle and preventing a free flow of fluid from the remaining cavities. As a consequence the lateral ventricles were greatly dilated, and the foramen of Monro, instead of being of the size of a crowquill, was an oval aperture measuring an inch in its major, and half an inch in its minor axis. The third ventricle was likewise dilated and the infundibulum, instead of being a narrow tube ending in the pituitary body, was widely dilated and formed part of the general cavity of the ventricle. The remaining portions of the skeleton manifested the usual evidence of rickets.

The symptoms induced by a tentorium such as this are very striking, and I have been able to study them in one of the cubs belonging to the same litter. The most noticeable symptom on

looking at one of these patients is that it prefers to remain quiet whilst the healthy cubs are playing about the cage, and compared with them it is thin and small. When the cub attempts to walk it advances a few paces and then the hind quarters fall over to one

WOODCUT 19.

A longitudinal section of the skull of a rickety lion, showing thickening of the tentorium and skull vault.

side or the other. At the same time the head is rotated laterally, the eyes oscillate, and the patient is convulsed. Occasionally when in the sitting posture, so commonly assumed by cats, rhythmical movements of the head may be noticed, which continue for some minutes.

The condition of the brain in these cases, and the symptoms produced by the pressure of the enlarged tentorium, are of great interest, inasmuch as they resemble very completely the symptoms and effects of obstruction to the interventricular communications in children, when the lateral recesses are occluded by inflammatory or congenital defects, or in those instances where a papillary tumour from the choroid plexuses of the fourth ventricle, or from the under surface of the tentorium cerebelli, obstruct the Sylvian aqueduct. Such cases have been carefully described by Hilton in his work on 'Rest and Pain,' and in Wilks and Moxon, 'Pathological Anatomy.'

The specimens from lions have been described because they illustrate so well, how slight modifications of structure widely exaggerate or modify the effects of disease. *May 17th*, 1887.

XIV. DISEASES, ETC., OF VEGETABLES.

1. *Vegetable tumours in relation to bud formation; with a new theory of neoplasia.*

By W. Roger Williams.

"A pathological tumour in man forms in exactly the same way that a swelling on a tree does, whether on the bark, or on the surface of the trunk or a leaf, where any pathological irritation has occurred. The gall-nut which arises in consequence of the puncture of an insect, the tuberous swellings which mark the spots on a tree where a bough has been cut off, and the wall-like elevation which forms round the border of the wounded surface produced by cutting down a tree, and which ultimately covers in the surface—all of these depend upon a proliferation of cells just as abundant, and often just as rapid as that which we perceive in a tumour of a proliferating part of the human body. The pathological irritation acts in both cases precisely in the same manner; the processes in plants conform entirely to the same type."—Virchow.

When a man begins to study any subject in a really independent spirit, the first thing he perceives is the connection between the various branches of science, by which they mutually enlighten and assist each other. This is especially the case with the subject we are about to consider; for, inasmuch as pathology is but a branch of biology, it necessarily follows that when new facts and principles are discovered in the latter, they react powerfully on the former.

The history of pathology amply illustrates this statement. Thus, we are indebted to the genius of the vegetable morphologist Schleiden, for the famous cell theory, which must be ranked among the most important steps by which the science of biology has ever been advanced. Every great pathological epoch has in fact been foreshadowed by some such precursory innovations.

It is astonishing what relatively long periods often elapse before the significance of such discoveries is duly appreciated.

The *vis inertiæ* opposed to all progress is immense. We see this in the case of the modern doctrine of evolution. Already more than a quarter of a century has elapsed since the publication of Darwin's great work on the 'Origin of Species,' which has revolutionised the rest of biology; but with regard to pathology, it has as yet produced no commensurate results.

My endeavour in this essay will be to contribute something towards the building up and developing of pathology, in accordance with these neglected principles—in short, to give a scientific basis to our pathology of cancer and tumour formation.

It appears to me that any attempt in this direction must necessarily fail which does not treat the subject in connection with *kindred processes* throughout the organic world, and consequently as part of a very large subject—that of organic morphology.

In advancing in this direction I have no predecessors to guide me with their critical light. If my task appears to be imperfectly performed, this must be my excuse. I will at any rate endeavour to give a right bent to inquiry.

We are indebted to the sagacious Johannes Müller, who continued the investigations commenced by Schwann, for insisting on the correspondence between the development from the embryo and the pathological neoplastic process. Virchow has further pointed out that the structural elements of all neoplasms are derived from the pre-existing cells of the organism whence they originate. Diseased states are in fact merely modifications of healthy states. This is what we mean when we say that every pathological process has its physiological prototype. But, strangely enough, no one has hitherto demonstrated the physiological prototype of cancer and tumour formation. Consequently, current statements regarding the genesis and development of neoplasms are of the crudest and most conflicting nature. They reflect the prevailing confusion and its cause—the want of clear conception as to the nature of the morbid process.

This want I shall now endeavour to supply, by tracing out the evolution of certain vegetable neoplasms, in accordance with general biological principles. Although I shall in this essay limit my remarks to vegetable neoplasms, I wish it to be distinctly understood that the same treatment of the subject is equally applicable to animal neoplasms.

Ever since the establishment of the cell theory it has been recognised that the life of every higher organism is but the expression of the collective functional activity of its constituent elementary parts or cells. Further, the one common factor underlying the evolution of all vegetable and animal structures is the development from cells; and each cell is a seat of life. Though each of the constituent cells of the higher organisms is to a large extent dependent upon others, yet at the same time each manifests a certain independence or autonomy. Every single cell may in fact be regarded as leading a kind of parasitical existence in relation to the rest of the organism.

We may even go further, since there are good reasons for believing that every component cell of the multicellular aggregates has the inherent power, under favorable conditions, of developing itself into the form of the parental organism: we may say then that each cell is potentially the whole organism. That the degree of development actually attained by each cell falls far short of this in most cases, is due to the restraining and modifying influence exerted by the whole organism on its protoplasm, which is thus compelled to the performance of comparatively subordinate, modified functions. In the performance of these special duties most of the original protoplasm is metamorphosed and used up. Hence in proportion as the cells are highly specialised their primitive reproductive function is either greatly reduced or altogether lost. But in the higher organisms certain cells never attain a high degree of development: they remain in a lowly organised condition, and serve, according as they are more or less unspecialised, either as germs for reproducing the entire individual, or for forming and maintaining the various tissues and organs. Such cells are found in all growing parts; they are the only real cancer and tumour germs.

I maintain that there is no fundamental distinction between the various modes of reproduction—sexual and asexual, the process of repair and formation of tissues, the reproduction of lost parts, and the different morphological variations, including bud, cancer, and tumour formations.

I regard all of these apparently so different phenomena as merely modifications of one common process which underlies and is the cause of them all, to wit, cell-growth and proliferation. The particular outcome of the process in any given case can in the end

be traced to the influence of the conditions of nutrition—understanding by this term the whole of the material changes wrought in the organism through its relations with the surrounding outer world. This being so, we can readily understand that under favorable conditions, certain cells may take on independent action: may grow and develop without regard to the requirements of the adjoining tissues and of the organism as a whole. Thus the various morphological variations arise, whether anatomical or pathological.

In the ordinary course of organic evolution, the growth and development of the cells proceeds in a regular and orderly manner, in accordance with the specific hereditary tendency of the whole. But the process once started does not cease on account of irregularity, or because it is taking a wrong direction. Hence, cells may arise at a place where they have no business, or at a time when they ought not to be produced, or to an extent which is at variance with the normal formation of the organism. In the embryo monstrosities and malformations are thus originated, and at a later period of development the various pathological new formations. These extremes graduate so insensibly into one another that it is impossible to separate them.

In treating a subject from the evolutional standpoint, definitions are, as a rule, worse than useless. We have rather to acquire the habit of recognising the transmutation of related things into one another, so that our conceptions may harmonise with the sequence of events, as they occur in nature. To this end it is constantly necessary to refer to the past, and not merely to the immediate present. This is especially the case with the subject we are now entering on—that of bud formation in its protean aspects. In this connection none of the processes of gamogenetic reproduction will be included, notwithstanding the intimate relationship which these bear to the processes of bud formation.

With this proviso we will now proceed to trace the subject genetically—both in individual cases (ontogenetically) and in the chief types (phylogenetically)—beginning with the study of the simplest forms, and proceeding successively to the most complex ones; for in this way, we shall, I think, best arrive at an adequate perception of the essential relations. Indeed, it is impossible to demonstrate the nature and morphological phenomena in any other way. To understand the grown we must follow

the growth; the history of development is the true light giver in every investigation into the nature of organic structure.

I think there is no doubt that the neoplastic process can be more satisfactorily studied in plants than in animals; owing to the absence, in the former, of many factors—such as the nerves and blood-vessels—which, in the latter, complicate and obscure the essential nature of the process.

In plants, the early embryo, and the lower animals, all the phenomena of growth go on without either nerves or blood-vessels. And so it is, at the outset, with all morphological variations, including bud, cancer, and tumour formations. In all of these cases the nerves and blood-vessels have not the slightest direct influence.

The lowest forms of vegetable life consist of single isolated cells, as in the *Protophyta*. In these lowly organisms these is no sexual reproduction: new individuals are produced by cell multiplication —by fission or gemmation—which is bud formation in its simplest form.

We are committed by the theory of evolution to the conclusion that at the earliest period of organic development these were the only kinds of buds; hence their formation must have preceded that of the higher and more complex kinds now extant. We may therefore infer, on phylogenetical grounds, that the primitive origin of every bud is a single cell. And ontogenetically, this is demonstrably so in the case of the lower plants, although in the higher ones it is generally impossible to trace the developmental process back to this early stage.

Such being the initial step in the evolution of bud formation, it follows from the law of heredity that the more complex kinds of buds, which have subsequently arisen, must have inherited their essential qualities from these simpler ones. Hence, we need not be surprised in studying these higher forms to find everywhere traces of this earliest phase of their evolution.

Advancing from the unicellular plants to the simplest multicellular ones, we see among the *Thallophyta*, the bud represented by a single cell or group of cells, separated from some part of the body of the parent plant. Not unfrequently any part of the thallus may subserve this purpose. Such cells develop into new individuals *after* separation from the parental organism. Here growth exceeding a certain rate ends in the production of new

individuals, rather than in enlargement of the old. We shall presently see the process undergoing various modifications in adaptation to other ends.

When, for instance, certain cells of the thallus or frond, instead of developing separately, multiply only in certain definite directions, whilst still maintaining their connection with the parent form, branched structures are produced instead of new individuals. This is the aspect of bud formation with which we are now more particularly concerned.

In seeking for the determining causes of the one or the other mode of development, it is to the conditions of nutrition that we must look. When the nutrition is relatively low the buds develop discontinuously; when it is relatively high their development is continuous; whilst changes in nutrition determine transitions from one mode of development to the other.

There are good reasons for believing that it is through the integration and development of proliferous outgrowths thus arising, that the higher kinds of plants have been evolved from the lower ones. Just as the thallus has arisen by the integration of cells, so we may conclude the higher plants have arisen by the integration of thalloid outgrowths into branching colonies.

Spencer has thus sketched the process:—"From fronds that occasionally produce other fronds from their surfaces, we pass to those that habitually produce them. From those that do so in an indefinite manner, to those that do so in a definite manner. And from those that do so singly, to those that do so doubly and triply through successive generations of fronds. Even within the limits of a sub-class, we find gradations between fronds irregularly proliferous, and groups of such fronds united into a regular series. Nor does the process end here. The flowering plant is rarely uniaxial—it is nearly always multiaxial. From its primary shoot, there grow out secondary shoots of like kind." In the course of this evolution the distinction between axial and foliar organs has gradually arisen. We must, then, regard the simple proliferous outgrowths of fronds as the original of all kinds of bud formation in the higher plants. According to Spencer the portion of one of the higher plants that corresponds to one of the primordial fronds is "a foliar appendage together with the preceding internode, including the axillary bud when this is developed."

The details of the histological process by which thalloid bodies

give rise to proliferous outgrowths or buds, has of late been very accurately determined. On examination we find the growing point composed of a number of undifferentiated protoplasmic cells—the primary meristem. Out of these cells the various kinds of tissue which subsequently arise are formed by differentiation. In most of the *Cryptogamia* the origin of the whole of these cells has been traced back to a single mother-cell, lying at the apex of the growing point, the apical cell. This cell is usually larger than any of the adjacent ones. The primary meristem arises from its constantly repeated divisions in the following way:—two unequal daughter-cells are at first produced, of which the larger one remains from the first similar to the mother-cell, whose place it

WOODCUT 20.

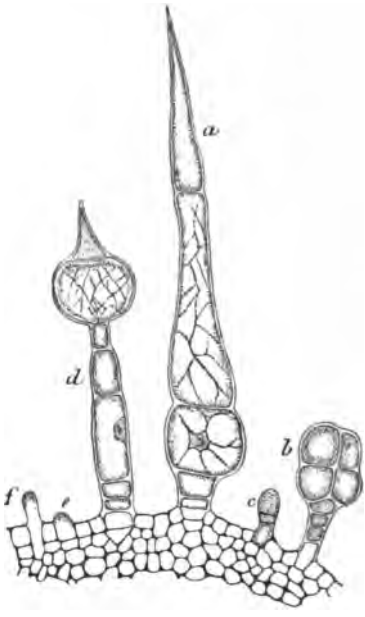

Illustrating the development of hairs.

takes, developing into a new apical cell which repeats the process; whilst the other daughter-cell—the smaller one—appears like a piece cut off from the back or side of the apical cell, and is therefore called the segment.

In the simplest cases, when there is very little differentiation, the segment remains undivided; in such cases the structures produced by division of the apical cell take the form of simple rows of cells, as in some algæ, fungus, hyphæ, and hairs.

Let us pause a moment to follow out this interesting process as it occurs in hairs (trichomes).

Here we have (Woodcut 20) a transverse section of the epidermis and subjacent tissue of the ovary of *Cucurbita* (× 100), showing hairs in various stages of development. From this it will be seen that each hair is the product of a single cell of the external layer. In the earliest stages of development (as at *e, f, c*) each hair is nothing but a simple protuberance from such a cell. Some hairs never pass beyond this primitive unicellular stage. Others, however, grow into various forms in consequence of repeated cell-division, as above described. When, for instance, the divisions take place in one direction only, as transversely, a structure is formed consisting of a single row of cells; and when they take place longitudinally the parts become thicker; whilst divisions proceeding at the same time in two or more directions give rise to masses of cellular structure which may develop variously (as at *a, b, d*).

In this way then hairs arise, and the process is a typical one. It constitutes the simplest and most instructive example of the formation of cellular growths—whether anatomical or pathological—to be found in the whole range of biology, and as such I particularly invite attention to it.

Outgrowths similarly arising from cells which lie beneath the epidermis originate the structures called emergences, such as the prickles of roses, which may be regarded as transitional forms between hairs and foliar organs. Abnormal developments in this direction may give rise to warty excrescences.

Generally, however, the process is more complicated than that just described. The segment, instead of remaining single, divides into two cells, each of which again breaks up into two, and by repetition of the process many times in the daughter-cells, a mass of protoplasmic cells is produced constituting the primary meristem. A simple case of this kind is shown in the subjoined figure (Woodcut 21).

A branch of the thallome of *Stypocaulon scoparium* is here represented, with two branchlets, *x* and *y*, and the rudiment of a third branchlet, *z*; all the lines indicate cell walls.

A very large apical cell (*s*) is shown divided by septa (I^a, I^b), and thus giving rise to the segments which lie in a row one over the other. Each of these soon becomes divided by other septa (II^a, II^b).

WOODCUT 21.

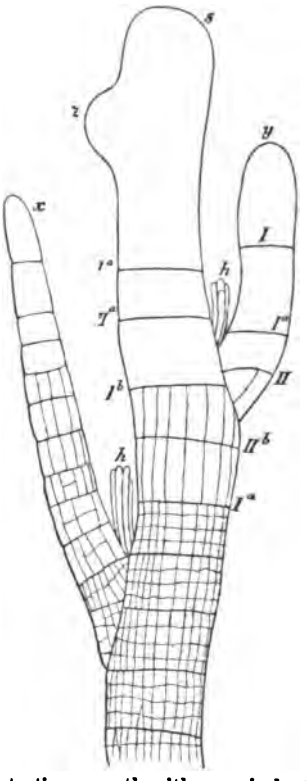

Illustrating growth with an apical cell.

By the formation, in each of these last of vertical, and afterwards of horizontal septa, numerous small cells arise.

Thus it is easily seen how the structure of the whole stem is built up of cells derived from a single segment, as at the lower part of the figure. In the same way each branch (*x*, *y*) originates as a lateral protuberance (*z*) from the apical cell; this becoming separated from the parent forms a new apical-cell, which develops into its proper form by repetition of the above process.

Proceeding to somewhat more highly differentiated forms, we

see in *Characeæ*—the lowest of the prothallus plants—buds giving rise to lateral outgrowths of the stem, which appear to be homologous with the leaves of the higher plants. The origin of each of these buds can be traced back to a single cell. The structure of the stem of *Chara* depends upon the properties of the cells which are successively derived by transverse division from the apical cell. Each segment thus cut off immediately divides again transversely into two superimposed cells, of which the lower—the internodal cell—elongates greatly, but does not subdivide; whilst the upper one—the nodal cell—elongates little, but becomes greatly subdivided by successive vertical septa, forming a whorl of peripheral cells. It is from these cells that all the lateral members of the *Characeæ* originate, each from a single cell.

In still higher forms, such as the *Mosses*, *Equisetaceæ*, and many *Ferns*, leaves and branches originate in a similar manner, each from a single cell. Just in the same way the modified buds which develop into gemmæ, bulbils, detachable leaves and axes, and other forms of agamic reproduction common in these orders, take origin, each from a single cell.

From these types we pass through various transitional stages to the higher Cryptogamia and *Phanerogamia*, in which no apical cell can be detected at the growing point. There is no single primitive mother-cell recognisable as the original of the first rudiments of lateral structures, leaves, shoots, &c. These first appear as protuberances composed of a few or a considerable number of small, primary merismatic cells, without any definite arrangement (*k*, *k*, Woodcut 22). At this stage, in their simple cellular structure, and in some other respects, these buds resemble the thalloid outgrowths of the lower Cryptogamia. But the cells soon group themselves into certain layers, which when traced backwards are found to be continuous with the epidermal tissue, the cortical structures, and the fibro-vascular bundles respectively; and may be recognised as the first rudiments of these structures. These relations are shown in Woodcut 22, which represents a longitudinal section through the growing point of the stem of the embryo of *Phaseolus multiflorus*.

Covering the apex (*s s*), we find an outer single layer of cells; the *dermatogen* (*a*) continuous with the epidermis of the older parts; beneath this, a stratum consisting of several layers of cells, the *periblem* (*b*), from which the cortical tissues are derived, and enveloped by the periblem, a cylinder of somewhat smaller cells,

the *plerome* (*c*), out of which proceed the axial tissues and fibro-vascular bundles; *pb*. represents parts of two leaves, and *k*, *k* their axillary buds.

WOODCUT 22.

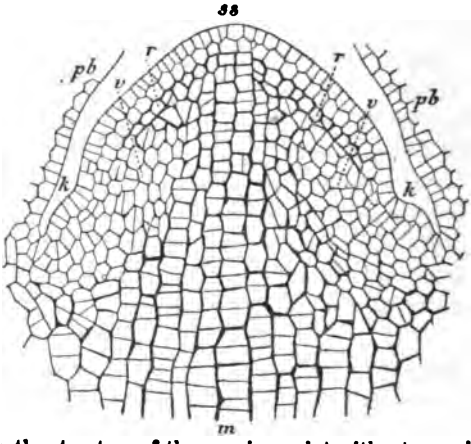

Showing the structure of the growing point without an apical cell.

It is evident, therefore, that whilst the various tissues and members of plants with apical growth have a common origin, it is otherwise with those which arise without apical growth, where each tissue-system is derived from its corresponding cellular stratum. It must not be inferred from this description that the processes in the growing point of Phanerogams are essentially different from those in Cryptogams. The whole teaching of vegetable morphology is opposed to any such conclusion. The truth seems to be that our knowledge of the transitional processes connecting these extreme types of development is at present very defective.

Briefly, then, these are the conclusions to which we have arrived: The simplest buds consist either of single, lowly-organised cells, or of groups of such cells derived from single cells. The differentiated tissues of the parent plant have no share in the formation of the primitive bud, and have no connection with it until a later period.

Usually buds develop in organic connection with the parent stock; but sometimes they fall off and develop separately. Each bud is potentially a new individual, having under favorable conditions the power of developing into a perfect organism; but the

degree of development actually attained often falls far short of this; buds become variously modified in adaptation to other ends.

In the higher plants, buds are usually distributed with great regularity, being either terminal or axillary; buds arising in any other way are said to be of adventitious origin.

Under ordinary circumstances a bud develops into a branch; but it does not therefore follow that all buds become branches. On the contrary, owing to disturbances in nutrition, buds may be very variously modified. Thus, in extreme cases, they may remain permanently undeveloped; or they may remain for long periods, even for years, in a dormant or latent state; and yet under favorable conditions their activity may revive.

When their evolution is somewhat less restricted, the products may be dwarfed, or developed into spines, tendrils, or various irregular formations, which may properly be called tumours. Flowers, too, are merely modified branches.

Adventitious buds differ from normal buds only in respect to position; they originate in precisely the same way as those normally formed on the axis of plants. Adventitious buds have been found on almost every part of plants. They sometimes develop in extraordinary numbers on the stems and branches of trees, owing to some interference with the vegetation of the normal buds. Care must be taken to distinguish between true adventitious buds thus arising and old dormant "eyes," which, having been formed at an earlier period as normal exogenous buds, have been left behind and become enveloped by the subsequent growth. In a general way the root is distinguished from the stem by the absence of buds; but under exceptional circumstances adventitious buds may be found even on roots. The physiologist, Duhamel, having planted a willow with its branches in the ground and its roots in the air, saw the roots become covered with buds, whilst the buried branches produced roots.

The production of a flower-bud has even been noticed on the root of a species of *Impatiens*. In some cases the divided root will reproduce the entire plant, as in the *Japan quince*, the *Osage orange* and especially the *Paulownia*, the roots of which may be cut into small sections, each of which, if planted, will develop into a perfect tree.

There are many plants which produce buds on their leaves. This is of much commoner occurrence among the lower orders, and the

ferns, than with the *Phanerogamia*. As examples among native plants may be instanced the *Watercress*, *Cardamine pratensis*, and *Malaxis paludosa*; in the last-named the buds are known to be derived from single cells of the surface of the leaves. *Begonias* exhibit this power in a remarkable degree; in some instances single scales from the leaves or stem habitually develop into young plants. One of the best known instances is that afforded by *Bryophyllum calycinum*, a succulent tropical plant, whose leaves produce buds furnished with roots, stem, and leaves, at the extremities of its lateral nerves. These buds, which fall off spontaneously and root in the earth, may be compared to ovules which do not need to be fertilised before developing; and the leaf of *Bryophyllum* may be regarded as an open carpal, in which the seeds have been developed by nutritive action alone. Consideration of the subject in this light leads us to regard the bud as an individual vital centre, resembling the ovule. Many facts in vegetable physiology and pathology confirm this view. Schleiden regarded the ovule as a modified bud, and the now well-authenticated cases of parthenogenesis in plants support his theory. In these cases new individuals are developed from unimpregnated ovules, as from buds, the defect in the ovular reproductive power, which ordinarily renders impregnation necessary, being removed. The ovule or seed bud, then, differs from the branch bud essentially only in this: that it generally needs for its development the fertilising influence of the pollen The fecundity of *Bryophyllum* completes the analogy between the bud and the fertilised ovule. According to Hofmeister, the buds of *Bryophyllum* arise before the complete unfolding of the leaf, as small masses of undifferentiated parenchyma in the deepest parts of the crenations of the leaves. Buds thus arising may take root and give origin to leaf-bearing branches whilst still in connection with the parent plant, as in *Drosera intermedia*, *Episcia bicolor*, &c., though they generally develop more readily after the leaves have fallen off. Adventitious buds have also been found on the petiole, lamina, stipule, and, in short, on every part of the leaf. It seems indeed as if *buds may arise whenever undifferentiated cells are present.*

Such anomalous bud formations in the higher plants may be ascribed to reversion to an original mode of growth; they remind us of the proliferous outgrowths so common among the *Thallophyta.*

The shoots which spring from buds usually develop into structures of the same form as those which compose the parent plant;

WOODCUT 23.

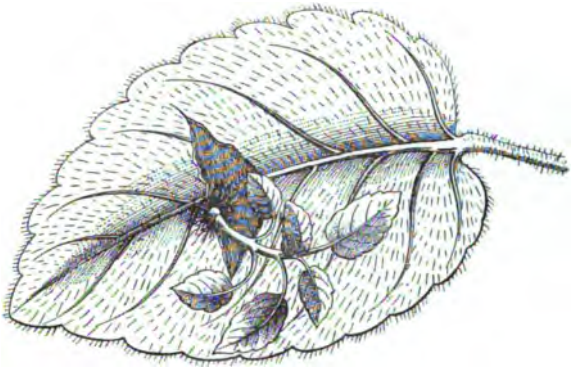

Represents an adventitious leaf-bearing shoot developed on a leaf of *Episcia bicolor*.

but it occasionally happens that particular buds develop differently from the others of the same stock. Gardeners call these changes "sports." Darwin has very carefully studied this remarkable process, to which he has given the name of bud variation.

Many cases of the kind are attributed by him to reversion; but he has determined that others can only be ascribed to the so-called spontaneous variability, such as often occurs in cultivated plants raised from seed. The common moss-rose is considered by Darwin to have originated in this way from the Provence rose (*P. centifolia*). Not only normal, but adventitious buds as well, are liable to this kind of variation. Fronds on the same fern, for instance, often manifest striking morphological deviations.

Of this a remarkable example is figured below (Woodcut 24). It represents a portion of a frond of *Pteris quadriaurita*, in which the foliage emerging from an adventitious bud is seen to be very different from that of the rest of the plant. It accords with the theory of reversion that such anomalies are of much commoner occurrence among the lower than among the higher orders of plants.

In determining the nature of such variations, the constitution of the organism seems to play a much more important part than the direct influence of the environment. In illustration of this subject,

Darwin says: "Let us recall the case given by Andrew Knight, of the forty-year-old tree of the yellow magnum-bonum plum, which has been propagated by grafts on various stocks for a very long

WOODCUT 24.

Portion of a frond of *Ptoris quadriauriata* in which the foliage emerging from an adventitious bud is very different from that of the rest of the plant.

period throughout Europe and North America, and on which a single bud suddenly produced the red magnum bonum. We should also bear in mind that distinct varieties, and even distinct species, —as in cases of peaches, nectarines, and apricots: of certain roses and camellias—although separated by a vast number of generations from any progenitor in common, and although cultivated under diversified conditions, have yielded by bud variation closely analogous varieties. When we reflect on these facts we become deeply impressed with the conviction that in such cases the nature of the variation depends but little on the conditions to which the plant has been exposed, and not in any special manner on its individual character, but much more on the general nature or constitution inherited from some remote progenitor of the whole group of allied beings to which the plant belongs. We are thus driven to conclude that in most cases the conditions of life play but a subordinate part in causing any particular modification; like that which a spark plays when a mass of combustibles bursts into flame, the nature of the flame depending on the combustible matter,

and not on the spark. No doubt each slight variation must have its efficient cause; but it is as hopeless to attempt to discover the cause of each as to say why a chill or a poison affects one man differently from another."

From the consideration of this interesting process we will now pass to a closely allied subject—that of the formation of vegetable tumours, which is essentially abnormal bud evolution. We shall find that in these cases the local changes are modelled after the processes of normal growth, and that both are subject to the same laws. Changes of nutrition causing altered growth and impaired development seem to be the common etiological factor underlying all of these abnormal formations. We must seek the physiological prototypes of these pathological new formations in such kindred processes as those above described. The clear recognition of this important fact is likely to lead to great results in the future development of this branch of pathology.

My investigations into the nature of tumours in trees have led me to classify them into three main groups.

The first group comprises the discontinuous or circumscribed growths, to which the vaguely used term of *kraurs* should be restricted. It includes all those nodules so often met with in the bark of the beech, elm, oak, birch, holly, cedar, and other trees. Mr. Stephen Paget has lately presented some good examples of these tumours to the Hunterian Museum, where they may now be seen. They are generally single, but occasionally several are

WOODCUT 25.

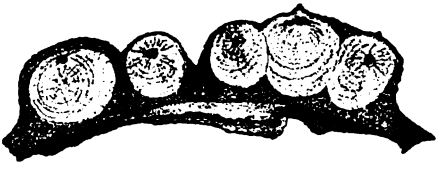

Showing five circumscribed tumours in the bark of a holly tree (natural size).

found close together. This was the case in one of Mr. Paget's specimens now exhibited—for which I am indebted to the courtesy of Mr. Eve—No. 546 A in the general pathological series of the Hunterian Museum. It is described in the catalogue as a portion of the bark of a holly tree with the cambium layer and a small portion of the wood. Deep in the substance of the bark are five

rounded tumours composed of hard wood, their cut surfaces showing joint concentric lamination. At the upper part of the specimen three of these have partially coalesced. They are distinctly circumscribed in the surrounding tissues; and there are no signs of any pedicles connecting them with the wood of the tree. The succeeding specimen, No. 546 B, shows a similar tumour from a beech tree, also devoid of any pedicle; and in No. 546 D we have five tumours from the surface, also of a beech tree, with one or two buds projecting from their surfaces. Here and there some of these buds have developed into shoots or minute branches.

It may be said of these tumours that they usually present as rounded or ovoid swellings in the deeper part of the bark, varying in size from a pin's head to a cocoa nut. The older nodules are generally found lying completely isolated in the bark, enclosed in a distinct capsule; a narrow fibro-vascular pedicle may sometimes be seen connecting the younger ones with the woody tissues of the trunk or stem. They are occasionally surmounted by a small stunted branch or shoot. On section, after removal, they are usually found to consist of very dense wood having a more or less concentric arrangement around a common centre. In most cases both pith and medullary rays can be seen. Sometimes, however, their woody structure is much more irregularly disposed. In short, they contain all the structural elements of the part whence they spring, but differently arranged. It would seem as if they were really shortened branches in which the woody layers had been abnormally developed in compensation for the curtailment in length and in other respects.

Lying completely isolated in the bark, these nodules increase in size at the expense of the surrounding nutritive materials. Hence, it often happens that their growth on the side of the cambium outruns that on the side of the free surface, where the nutritive supply is less abundant, so that a certain eccentricity in the arrangement of the laminæ is produced. Destruction of the bark which usually covers them in, whether as the result of injury or some other cause, such as pressure by the growing nodule itself, renders this tendency to increased growth on the side of the cambium still more obvious; for we then see complete cessation of growth at the exposed surface, which may even decay in consequence, whilst the side of the nodule next to the wood of the tree, owing to the proximity of the cambium, still continues to increase.

According to Dutrochet these tumours first appear as very small globular bodies in the cellular tissue of the bark, where they originate from unspecialised cells quite independently of the wood of the trunk, and this is the view generally held. Trécul, however, states that if they are examined at an early stage of development, they will be found to communicate with the woody tissue, whence they originate. The subsequent isolation he attributes to rupture of the primitive pedicles by the further growth of the tumours. Trécul also maintains that with rupture of their pedicles the nodules lose the power they at first possessed of originating shoots or branches; and when they retain this power it is due, he says, to the separation never having taken place.

Almost all observers are now agreed in ascribing the origin of these tumours to disorderly growth of adventitious or dormant buds. After remaining for several years in the latent state, such buds develop renewed activity under the influence of favorable conditions, the result being either a branch or one of these tumours. In all cases the morbid product signifies a reduction or minus of the healthy one, differing from it only in degree.

Arising in this way we need not be surprised to find these tumours like buds, possessed of a distinct individuality. It even occasionally happens that they may be used for purposes of propagation, as in the case of the "burrs" of some species of apple, which produce both leaves and roots in abundance.

In all of the above instances the result of the morbid process is the production of a highly organised circumscribed new growth, strictly comparable to the fibromas, lipomas, and other similar new growths of animal pathology.

Before entering on the consideration of the second group of tumours in trees, I must first of all offer a few observations with regard to certain intermediate formations of the nature of local overgrowths. I have often remarked in various trees the presence of hypertrophous branches; and in several instances I have seen localised hypertrophies involving the whole thickness of portions of the branches of such trees as the elm, lime, and oak. These conditions may be described as hyperostoses. They occupy in vegetable, as in animal pathology, an intermediate position between the processes of hypertrophy and tumour formation. They fall short of tumours chiefly in that they manifest but feeble signs of individuality. On this account I regard them as more akin to the

hypertrophies than to the neoplasms. Such conditions appear to arise at an early stage of development in consequence of excessive activity of the whole of the cambium at the affected part. Hyperostoses generally present as rounded protuberances covered with bark, their diameter being many times greater than that of the part whence they grow. On section they consist of hard wood, the concentric layers of which are unusually thick and very obvious, whilst the medullary rays, extending from the centre to the periphery, are very thin. Trécul has figured a very fine example of this kind from a birch tree. The second group, comprising the continuous tumours—to which the term of exostoses should be restricted—present as woody outgrowths of the trunk or branch. They often attain great size, as in the example now before the Society (Woodcut 26), which weighed 67 lb., and measured 16 × 11 inches. The diameter of the branch on which the tumour grew was four and a half inches on the proximal, and four inches on the distal side.

The general characters of these growths may be gathered from the subjoined brief description of this specimen, which was removed from one of the largest branches of a young elm tree—probably about thirty-five years old—on the main trunk of which was another similar growth, the tree being in other respects healthy. It was completely covered with rather hypertrophied bark, and two small branches grew from its surface near the periphery. On longitudinal section it was found to consist of very hard wood directly continuous with that of one side of the branch whence it grew. The laminæ composing the tumour showed a concentric arrangement of outcurved, irregularly wavy layers; whilst those of the branch itself appeared longitudinal (*vide* Woodcut 26). Moreover, the former were many times thicker than the latter; in the broadest part of the tumour I was able to count twenty-six of these layers. A singular feature in this case is that a portion of the tumour had grown completely round the healthy part of the branch, outside the bark, and had then blended with the main tumour on the opposite side, so as completely to encircle the branch on which it grew.

Mr. Edwin Clarke kindly allowed me to remove this specimen from a tree in his meadow at Winchmore Hill. An adjacent elm tree of about the same size, presented a single similar outgrowth on its main trunk. The situation was a damp one, and the soil

heavy; close to the trees ran a small ditch, the water of which was highly contaminated with animal excreta.

Dutrochet has described these growths as arising in much the

WOODCUT 26.

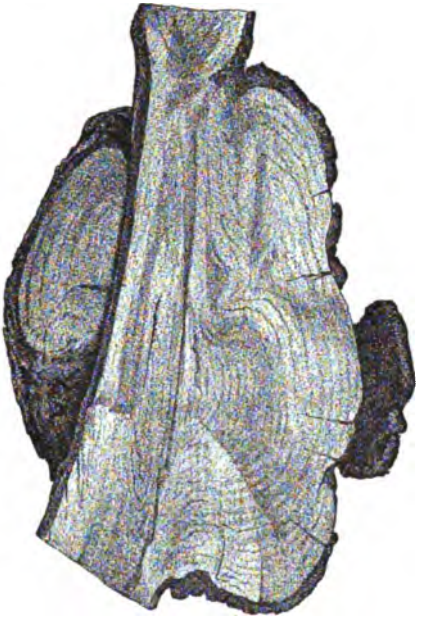

A continuous tumour (exostosis) from an elm tree, in longitudinal section.

same way as the circumscribed ones—by a kind of bud formation or excessive local cell proliferation of the cambium layer; but their connection with the woody tissue of the stem is from the first more decided, and is never lost. These tumours must be regarded as abnormally developed branches. Such being their structure and mode of origin they may be fairly compared with the exostoses and allied continuous tumours of animal pathology; and like them they are highly organised.

In the third group, I include those new growths which present a surface thickly studded with shoots and stunted branches. There is here a combination of the exostosis with diffuse bud formation. The French call such growths *broussins;* the term "burrs" might very well be employed as the English equivalent. Growths of this kind often attain enormous proportions.

WOODCUT 27.

An old lime tree with an enormous growth densely studded with shoots and stunted branches.

An excellent example of this kind of growth is figured above (Woodcut 27). The engraving is from a photograph. It shows an old lime tree with a huge excrescence densely covered with brushwood and shoots, growing at the junction of the trunk with the main branches. Three other aged lime trees in the immediate vicinity were similarly affected. In all of these cases the general nutrition of the trees appeared to have suffered considerably as indicated by numerous dead branches.

The following figure (Woodcut 28) gives an idea of the appearance of this kind of growth at close quarters. In the same neighbourhood I have seen similar growths on elm and birch trees. The trees of this particular locality are in fact remarkably prone to these growths, and to various other morphological anomalies, such as multiple excrescences, hyperostoses, and hypertrophies. Most of the trees are old and of large size. For a long period they have been left quite uncared for—innocent of the arts of forestry. The situation of the locality is peculiar. It forms part of a shallow saucer-like depression, lying below the slope of a hill. A large brook, the natural watershed of the neighbourhood, runs sluggishly through the lowest lying part. In its course it here forms several large lacustrine ponds owing to the slightness of the gradient. The water is highly charged with sewage matter. Clay formation underlies the whole neighbourhood, and forms the bed of the watercourse; whilst a layer of loose gravel rests on the clay. It results from this arrangement that the whole of the depressed area is thoroughly saturated with the sewage-contaminated water. The soil is heavy. A mist commonly hangs over the locality. As the result of these conditions its vegetation has long been abnormally nourished; even the grass shows it, for I suppose such large, coarse, rank grass could hardly be found elsewhere.

The peculiarity of growths of this kind consists in the immense number of buds which develop adventitiously in the cambium layer of the affected part, where they either remain dormant or forthwith develop into shoots or stunted branches. The aggregation of these structures causes retardation and irregularity in the flow of the sap; whence the exuberance of the growth, and the curious markings produced in the wood. Moquin-Tandon mentions the case of a grafted ash in the botanic garden of Toulouse, where below the graft a large growth of this kind formed, from which proceeded over a thousand small, densely-packed, interlacing

WOODCUT 28.



A near view of the growth represented in Woodcut 27.

branches. Similar conditions have been described as occurring in several other kinds of trees.

The production by these growths of large quantities of proliferating lowly organised cellular tissue, which subsequently undergoes imperfect evolution, constitutes the nearest approach in vegetable pathology to the sarcomas and carcinomas of animal pathology. The absence in vegetable tumours of anything like infectiveness (malignancy) may be urged as an objection to this comparison. To which the answer is, that in the absence of a highly specialised lymph-vascular system to transport the proliferous cells, such infectiveness is not to be expected; and that it is to deficiency in this respect, and not to any essential difference in the nature of the morbid process, that the absence of infectiveness in vegetable tumours is to be ascribed.

Hitherto, very little has been said with regard to the difficult subject of Etiology; now this matter must be briefly discussed.

We shall here have to deal largely in generalities, for it must be confessed, notwithstanding the great advances recently made in biological science, that in the majority of cases we are still unable to indicate the precise nature of the circumstances which determine particular variations in organisms.

Everyone who has investigated the nature of the local changes in neoplasms must have been struck by the fact that at every turn the phenomena met with have their counterparts in the normal processes of evolution.

Between the laws which govern the evolution in the two cases there is evidently no intrinsic difference,—the normal is the type of the pathological. Hence, we may reasonably hope, that as the normal process becomes better understood, so our knowledge of the abnormal process will increase.

When we come to examine the linked chain of living things in the light of the doctrine of evolution, we are insensibly led to the important conclusion that functional modifications in all cases go before structural changes, and are from beginning to end their determining cause.

In the development of every higher organism there may be observed a twofold progress proceeding *pari passu*. On the one hand, there is a continuous perfecting of bodily structure by increasing histological and morphological differentiation, whence result the numerical increase and subdivision of tissues and organs; and, on

the other hand, there is a continual transition from lower to higher types of development.

We are indebted to Baer for pointing out that these metamorphoses indicate roughly the changes of structure undergone by ancestors.

Each individual organism reproduces in the rapid and short course of its own evolution the most important morphological changes through which its long line of ancestors have passed.

The development of the individual from the fertilised germ (ontogeny), is, in fact, an epitome of that of the race (phylogeny), conditioned by the laws of heredity and adaptation. To Darwin is due the great merit of having placed the phenomena of heredity and adaptation in their true light. He it was who first showed how organic forms are changed, by the interaction of these two important physiological functions. So completely are they interwoven that it is generally impossible to say how much of a given morphological change is attributable to the one, and how much to the other. Taken as a whole they stand in a certain opposition. Heredity is the cause of the stability of organisms, and adaptation of their modification. Heredity may be regarded as the conservative factor, ever tending to keep the descendants like the ancestors; whilst adaptation represents the progressive factor, striving to change the organism through the direct or indirect influence of the environment. According as the one or the other influence is paramount the organism will remain constant or vary.

In every act of reproduction a certain quantity of protoplasm is transferred from the producing to the produced organism, and along with it the molecular motion peculiar to the parental individuals.

The phenomena of heredity are essentially due to this material continuity and partial identity of the producing and produced organisms. If instead of a succession of individuals thus produced we substitute in imagination a single continuously existing individual, we shall at once see the relation in which an organism stands to the rest of the species; and how the succession of all living things is, as Goethe says, a linked chain.

Thus, the persistence of impressions (unconscious memory) in protoplasm is the property upon which, in ultimate analysis, the phenomena of heredity depend. Hence, every living thing produces new ones, each after its kind. It is in virtue of this

property that, in Paget's words, "a mark once made on a particle of blood or tissue is not for years effaced from its successors."

For the initiation of the evolution of the higher organisms the blending of two cells derived from different individuals is, as a rule, essential; both of these exert their influence in forming the offspring. Sometimes the male influence is seen to predominate in one direction, and the female in another. No definite rule can be laid down. Equal transmission by both sexes is the commonest, but sometimes characters are transferred exclusively to the sex in which they first appear.

It should be borne in mind that the actual product of the development of a fertilised germ by no means represents the full measure of its potentiality. The particular form evolved in any given case must be regarded as the resultant of the many fluctuating forces inherent to the parental reproductive cells at the moment of impregnation, which in other generations may be differently compounded. Only a portion of the many varying tendencies inherited by the reproductive cells from their long line of ancestors are actually evolved in each generation.

Hence, the transmission and development of qualities, though they usually go together, are in reality quite distinct powers. Thus the secondary sexual characters of one sex lie latent in the opposite sex, ready to be developed under favorable conditions. In like manner qualities are transmitted through the earlier years of life which are only subsequently developed. In accordance with the same law we frequently see qualities transmitted in a dormant state through hundreds or thousands of generations, and then suddenly redeveloped. In some cases the number of intervening generations may be enormous. "In every organism," says Darwin, "we may feel assured that a host of lost characters lie ready to be evolved under favorable conditions." All of these wonderful phenomena are included under the term of atavism or reversion, which is a very important subject in relation to the etiology of morphological variations.

Not only can organisms transmit those qualities which they have inherited from their ancestors, but also those which they have acquired during their own lifetime. New characters thus transmitted tend to appear in the offspring at the same age as they were first acquired by the ancestor; and when deviations from this rule occur the transmitted characters usually appear earlier. It

has also been observed that local variations tend to appear in the offspring at the same place as they first appeared in the ancestors. We are unfortunately not acquainted with the precise conditions under which the transmission of acquired characters takes place. It is, however, known that certain of these qualities are much more easily transmitted than others, *e.g.* phthisis, insanity, albinism, weeping willows, copper beeches, &c. In these instances the change transmitted seems to be chiefly a constitutional one.

Such, then, are the chief facts with regard to heredity with which we are here concerned.

In ultimate analysis the phenomena of adaptation are traceable to the endless variability of protoplasm, owing to molecular changes excited in it by the unequal incidence of the ever-changing environment. Changes of nutrition cause functional alteration, which ultimately develops into obvious morphological variation. But modification of function and its expression by gross structural change is a gradual process; hence adaptation is only noticeable in a long series of generations, whilst heredity can be recognised in every generation. When, therefore, a new variation seems to come suddenly into existence, there is always under the surface an unbroken physiological evolutionary process. For instance, the sudden development of a neoplasm, in an otherwise healthy organism, is in reality the outcome of gradual and continuous changes in the evolution of the cells of the affected part, owing to changes in the nutrition of the tissues in that situation.

We see, then, that variability of every kind is directly or indirectly caused by the changed conditions of life to which each organism, and more especially its ancestors, have been exposed.

"Of all the causes which induce variability," says Darwin, "excess of food, whether or not changed in nature, is probably the most powerful." In the case of animals want of proper exercise has probably been an important factor in causing variability. These seem to be the chief reasons why domestic productions are so much more liable to vary than natural species.

It has been ascertained that the influence of changed conditions accumulate, so that several generations must generally be exposed to the new conditions before any effect is visible. Thus slight changes often suffice to induce considerable variability. Once the process has commenced the more disposed is the organism to vary still further.

Variations may be induced either by the direct action of the environment on the whole organism or only on certain parts of it; or indirectly, through some subtle alteration in the reproductive system without there being any obvious change in the parental form.

The causes which induce variability may act on the mature organism, the embryo, or on the sexual elements before impregnation. It seems certain that either sexual element may be affected in such a manner as to cause modifications in parts developed from it at a late period of life. Morbid impulses thus generated issue —through the parental reproductive system—as disease in the offspring.

In determining the nature of particular variations the constitution of the organism acted on seems to be a much more important element than the nature of the changed conditions. This is what may be inferred from the appearance of nearly similar modifications under different conditions, and of different modifications under nearly identical conditions. What is known of bud variation points to the same conclusion.

As Darwin insists, bud variation shows that variability may be quite independent of sexual reproduction and likewise of reversion. For instance, the sudden appearance of a moss-rose on a Provence rose cannot be attributed to reversion, for mossiness of the calyx has never been observed in any natural species. Here the aid of the so-called spontaneous variability has to be invoked as a cloak for our ignorance. It is important to observe that bud variations are of much more frequent occurrence in plants that have been highly cultivated during a length of time than in other and less highly cultivated plants; and very few well-marked instances have been observed in plants living under strictly natural conditions.

Let us now briefly pass in review the process of gall formation which appears to me likely to throw some light on this subject; for there is evidently a likeness between it and the process underlying other anatomical and pathological variations.

Galls arise in consequence of excessive local cell-growth and proliferation, excited by the virus instilled into wounds made by insects in depositing their ova. Considering the very small size of most gall-producing insects, the drop of poison instilled must usually be exceedingly minute. Hence, it probably acts only on

a single cell, or on a very few cells, which, being abnormally stimulated, proliferate. The subsequent growth is often very rapid. It is remarkable that galls present definite form and character; moreover, each kind keeps as true to its type as any independent organism—each has, in fact, an individuality of its own.

Notwithstanding the close affinity between many groups of gall-producing insects, yet the number of different galls caused by them is very great. On the oaks of middle Europe alone nearly a hundred different kinds have been described, all produced by species of gall-wasps. Hence, we may infer that very slight differences in the nature of the poison causes widely different results; and that the nature of the fluid instilled is a much more important factor in determining the form of the gall than the specific character of the tree acted upon. In treating of this matter Darwin remarks: "As the poisonous secretion of insects belonging to various orders has the special power of affecting the growth of various plants; as a slight difference in the nature of the poison suffices to produce widely different results; and lastly, as we know that the chemical compounds secreted by plants are eminently liable to be modified by changed conditions of life, we may believe it possible that various parts of a plant might be modified through the agency of its own altered secretions. With such facts before us, we need feel no surprise at the appearance of any modification in any organic being."

We have seen that buds arise whenever there is an excess of nutritive materials, capable of being utilised for growth by the cells of the part. Under such circumstances buds may be formed wherever undifferentiated cells are present. The stimuli which determine the nutritive flux may be either internal or external. In either case the result is the same; the protoplasm of the part thus excited to excessive growth and proliferation gives rise to collections of lowly organised cells. These, not being required for the building up of the parental structure, become superfluous, and are no longer retained directly under its controlling influence.

Groups of more or less completely emancipated cells thus arise, which, as they develop, assume an *individuality* of their own; the local processes cease to be subordinate to the specific hereditary tendency of the whole. Here we see growth exceeding a certain amount tending to the formation of new aggregates. Whether

such centres of vital activity continue to develop in organic connection with the parental form, or after separation from it, is determined by the conditions of nutrition. If the cells from which a leaf-bearing shoot would normally spring are abnormally nourished, they may develop instead into a tumour or some other abnormal production.

In the present imperfect state of our knowledge it is impossible to fix upon the precise change in the conditions of nutrition required to bring about a given abnormality. We can only point out in a general way, that such changes must be sought in the particular relation which each part has with the environment, either habitually in the individual or occasionally in the race.

For the present, therefore, we must content ourselves with such indications as can be gathered from the following considerations.

It has been observed in plants that any intermission in the local or general nutritive activity may determine the formation of buds. At first sight this seems to contradict a previous statement to the effect that buds may arise wherever nutrition is in excess. The explanation is, that this question of nutritive excess is a purely relative one; for we find that growth varies according to the surplus of nutrition over expenditure. In all cases bud formation implies a relative local excess of nutrition, for it occurs when the forces which result in growth are in excess of the antagonistic forces.

Thus, we interpret the fact, that in so many cases bud formation takes place during the period of declining growth. And thus it is that plants may then be successfully transplanted, an operation which is generally impossible during the periods of active growth.

Further, it has been observed that anything which arrests the growth of an organism at any part, or only interrupts the continuity of the cellular tissue, may determine bud formation. For example, it is well known that injuries often call forth a large number of adventitious buds. This is the effect of cutting or breaking off a branch, or of anything that interferes with the vegetation of the normal buds. Wounds of the bark are often followed by the same result. Many plants present in their bark little groups of roundish cells—lenticels—which originally lie

beneath the epidermis, but when this wears away they are laid bare. As the growth of the part proceeds the bark is often rent at these places, so that the growing cellular tissue is freely exposed. At the edges of such rents adventitious buds are very liable to form, which may develop into tumours. When a begonia leaf is placed in damp soil and incisions are made across its nerves, buds

WOODCUT 29.

Buds formed along incisions into the base of a hyacinth bulb.

spring from every incision, and as many fresh plants may be obtained in this way as the leaf has received wounds. The Dutch bulb growers have very cleverly availed themselves of this circumstance to propagate hyacinths. This they effect either by making two or three deep incisions into the base of the bulb—destroying the nascent flower stalk—when, after a short time, numerous small buds form along the edges of the cut surface (*vide* Woodcut 29); or by scooping the interior of the base of the bulb, and so leaving exposed the cut ends of the sheathing leaves, from which buds soon spring in great numbers. Leaves subjected to slight pressure and in process of decay frequently develop buds in a similar way.

Degrees of injury which fall far short of this, such as those produced by various mild irritants, as described by Waldenberg, cause local thickenings, owing to increased growth and proliferation of the cells of the part. Similarly, as we have seen, the various kinds of galls arise.

In all of these cases the subordination of the local processes to the specific hereditary tendency of the whole appears to be lost or diminished; so that unspecialised cells then manifest their potential reproductive qualities by taking on independent growth—establishing, so to speak, an *imperium in imperio*. There is, in

short, departure from the definite order, limitations, regular stages, and fixed periods of the normal evolution.

In conclusion, I have only to remark, that throughout this essay it has been my endeavour to make it clear that cell life and cell processes constitute the real foundation of all morphological variations, whether anatomical or pathological.

With regard to the Woodcuts, Nos. 25, 26, 27, and 28 are original; the rest are after Prantl, Sachs, Masters, &c.

November 16*th*, 1886.

ERRATUM.

At page 335, the name of Sheridan Delépine, M.B., should have been added to that of Mr. G. R. Turner, the Case of Alveolar Sarcoma being their joint production.

INDEX.

ABNORMALITY, congenital, of lower lip associated with cleft palate (H. H. Clutton) 446
„ see *Deformity, Malformation.*
ABSCESS in the œsophagus caused by cerebro-spinal meningitis (W. Hale White) 14
„ retro-œsophageal (H. H. Clutton) 130
ACETABULUM, absence of margin without displacement of head of femur in a fœtus (C. B. Lockwood) 303
„ — — with displacement of the head of the femur in a fœtus (C. B. Lockwood) 305
ADAMS (W.), remarks on congenital displacement or so-called dislocation of hip-joint 300
ADDISON'S DISEASE (W. Pasteur) 409
ADENO-SARCOMA of tongue with calcifying nodule in the centre (R. J. Godlee) 346
ALCOHOLIC PARALYSIS, see *Paralysis.*
ALLCHIN (W. H.), chronic perforating ulcer of duodenum with erosion of pancreatic artery 144
ANEURYSM of aorta (transverse part of arch) rupturing into the œsophagus; no previous œsophageal symptoms (H. Handford) . . . 118
„ of arch of aorta communicating with superior cava (G. Gulliver) . 120
„ — rupturing into pericardial sac (A. W. Green) . . . 119
„ of heart (A. Money) 97
„ ruptured (syphilis) (A. W. Green) 102
„ of sinus of Valsalva (N. Moore) 100
„ of the mitral valve in a child (W. B. Hadden) . . . 116
„ thoracic, spontaneous cure of, in anæsthetic leprosy (B. N. Rake) . 120
„ interstitial, of the interauricular septum (R. Maguire) . . 100
ANGINAL symptoms in stenosis of mouths of coronary arteries (H. Sainsbury) 117
ANGIOMATA, multiple, of leg with multiple enchondromata and a sarcoma (F. S. Eve) 326
ANGIOSIS, see *Macro-angiosis.*
ANIMALS, diseases, &c., of 451–459
„ diseases of the genito-urinary organs in (J. B. Sutton) . . 451
ANUS, imperforate; (A) male, (B) female (D'Arcy Power) . . 149
AORTA, aneurysm of (transverse part of arch) rupturing into the œsophagus; no previous œsophageal symptoms (H. Handford) . . . 118
„ — of arch of, communicating with superior cava (G. Gulliver) . . 120
„ — — rupturing into pericardial sac (A. W. Green) . . . 119
„ rupture of, ulceration of trachea (H. Maudsley) . . . 89

ARMS, multiple painful fatty tumours of (F. S. Eve) . . . 323

ARTERITIS, syphilitic, case of (S. J. Sharkey) . . . 124

ARTERY, basilar, embolism of (H. Maudsley) . . . 11
„ posterior cerebral, meningeal hæmorrhage from rupture of (H. Maudsley) 11
„ coronary, stenosis of mouths of the; anginal symptoms (H. Sainsbury) . 117
„ pancreatic, erosion of, in case of chronic perforating ulcer of duodenum (W. H. Allchin) 144
„ pulmonary, ulceration of large branch of the, in a child, causing rapidly fatal hæmoptysis (W. Pasteur) 91

ARTHRITIS, senile (Thomas Smith) 313
„ tubercular, microscopic sections from six cases of (S. G. Shattock) . 316

ATAXY, locomotor, see *Locomotor ataxy*.

ATROPHIED KIDNEY and dilated ureter, from a female child aged 2 years (W. R. Dakin) 169

ATROPHY, see *Hemiatrophia*.

BACILLI of leprosy (B. Rake) 439
„ — remarks on above (G. Thin) 439

BACK, sarcoma of the, with fibrous nodules over it (J. H. Targett) . 330

Ballance (C. A.) and S. G. Shattock, cultivation-experiments with new growths and normal tissues, together with remarks on the parasitic theory of cancer 412

Barling (Gilbert), tubercular tumour of brain . . . 42

Barlow (Thomas), ulcers of stomach in a child, the subject of general tuberculosis 141

Barwell (Richard), "macro-angiosis" of left upper extremity . . 121

Battle (W. H.), extensive disease of the bones from a case of congenital syphilis associated with rickets 279

BILHARZIA HÆMATOBIA, urinary organs from a case of (R. Harrison) . 191

BLADDER, ectopia of the (S. G. Shattock) 173
„ encephaloid disease of apex of (E. H. Fenwick) . . . 182
„ double epithelioma of the (W. Bruce Clarke) . . . 181
„ functions of, interfered with by large fibroid in pelvis; extirpation of uterus for (Sydney Jones) 247
„ hypertrophied, frozen section of, removed from a case of stricture of the urethra (E. H. Fenwick) 173
„ purpura hæmorrhagica of the (E. H. Fenwick) . . . 188
„ from a case of purpura (F. C. Turner) 189
„ subperitoneal rupture of the (W. Bruce Clarke) . . . 177
„ chondrifying sarcoma, together with multiple papillomata removed from the (S. G. Shattock) 183
„ tumour (papillomatous) of, removed by supra-pubic cystotomy (Sydney Jones) 179
„ case of villous tumour of the (F. Hewkley and E. H. Fenwick) . . 179
„ extra-peritoneal wound of, without extravasation (J. H. Targett) . 176
„ sacculated, with calculus fixed behind prostate (C. M. Moullin) . . 178
„ see *Cystitis*.

BONES, extensive disease of the, from a case of congenital syphilis associated with rickets (W. H. Battle) 279

BOWELS, obstruction of the, two cases of gall-stones causing (P. H. Pye-Smith) 160

BOWLBY (A. A.), congenital dislocation of the hip . . . 295
„ multilocular cystic tumour of the lower jaw . . . 359
„ *report* on Mr. Hutchinson's case of sarcoma (?) of the lower end of the femur) 292
BRAIN, cholesteatoma at the base of the (J. A. P. Price) . . 24
„ softening and secondary descending degeneration, with old meningeal hæmorrhage (W. Hale White) 13
„ round-celled sarcoma of (W. P. Herringham and D'Arcy Power) . 43
„ tumour of (A. Money) 97
„ tubercular tumour of (G. Barling) 42
BREAST, hydatid of the (C. J. Symonds) 448
„ recurrent (?) melanotic sarcoma of the (H. T. Butlin) . . 343
„ — *report* of Morbid Growths Committee on above (R. W. Parker and S. G. Shattock) 345
BRONCHIAL GLAND, caseating, causing bronchiectasis (L. Shaw) . 90
BRONCHIECTASIS, localised, caused by the invasion into a bronchus of a caseating bronchial gland (L. Shaw) 90
BRONCHO-ŒSOPHAGEAL FISTULA, see *Fistula*.
BUD FORMATION, vegetable tumours in relation to, with a new theory of neoplasia (W. Roger Williams) 460
BULL (W.), see *Rouse*.
BULLET WOUND of left ventricle (R. Maguire) . . . 97
BURN, extensive, stomach with numerous superficial erosions following after (G. N. Pitt) 140
BURSÆ, some intra-bursal growths (G. H. Makins) . . . 377
BUTLIN (HENRY T.), recurrent (?) melanotic sarcoma of the breast . 343
„ — *report* of Morbid Growths Committee on above (R. W. Parker and S. G. Shattock) 345

CÆCUM, carcinoma of, with extreme narrowing (W. B. Hadden) . . 148
„ cystic tumour of the (H. Sainsbury) 146
CALCULI, biliary, two cases causing obstruction of the bowels (P. H. Pye-Smith) 160
„ prostatic, in case of primary scirrhus of liver of tubular origin (G. N. Pitt) 151
„ fixed behind prostate: sacculated bladder (C. M. Moullin) . . 178
„ renal, multiple, in case of urinary tuberculosis (E. H. Fenwick) . 165
„ vesical, spontaneous disintegration of (W. M. Ord) . . . 191
„ — with hair-pin as nucleus (S. Jones) 194
„ — formed round an india-rubber umbrella ring (E. H. Fenwick) . 193
CANCER, infective character of (C. A. Ballance and S. G. Shattock) . 420
„ parasitic theory of; cultivation-experiments (C. A. Ballance and S. G. Shattock) 412
„ of the thyroid (G. Stoker) 396
„ colloid, of stomach (L. Hudson) 143
„ encephaloid, of right kidney (E. H. Fenwick) . . . 166
CARCINOMA of cæcum, with extreme narrowing (W. B. Hadden) . 148
„ of right lobe of the prostate (E. H. Fenwick) . . . 195
„ of the left vesicula seminalis and adjoining lobe of prostate (E. H. Fenwick) 199
„ metastatic, of the prostate (E. H. Fenwick) . . . 196
„ myxomatodes (W. Edmunds) 377
CARIES, spinal, see *Spinal caries*.
CARRINGTON (R. E.), recovery (?) from tubercular meningitis in chronic phthisis, with disease of knee-joints and spinal caries . . 16

CARTILAGE, adenoid sarcoma with, originating in the pineal gland (J. Coats) 44
CASEATION of both suprarenal capsules, in case of genito-urinary tuberculosis (S. Coupland) 408
CAST, decidual, of the uterine cavity (W. S. A. Griffith) . . 227
CEREBELLUM, sarcomatous tumour of, in case of osteitis deformans (A. H. Robinson) 262
CEREBRAL HÆMORRHAGE, see *Hæmorrhage.*
CEREBRAL TUMOUR, see *Brain.*
CEREBRO-SPINAL MENINGITIS, see *Meningitis.*
CHOLESTEATOMA at the base of the brain (J. A. P. Price) . . 24
CHONDRIFYING SARCOMA removed, together with multiple papillomata, from the male urinary bladder (S. G. Shattock) . . . 183
CIRCULATION, organs of, diseases, &c. . . . 96–126
CIRRHOSIS of pancreas in diabetes (W. B. Hadden) . . . 163
CLARK (F. W.), subpleural lipoma of diaphragm . . . 324
CLARKE (W. BRUCE), subperitoneal rupture of bladder . . . 177
„ double epithelioma of the bladder 181
CLAVICLE, sarcoma of (J. Rouse) 287
„ right, a new growth apparently springing from the periosteum of the, and extending into the triangles of the neck, &c. (J. R. Lunn) . . 287
CLOT, ante-mortem, on right side of heart, containing growth in case of sarcoma of left lobe of thyroid (G. N. Pitt) . . . 398
CLUTTON (H. H.), retro-œsophageal abscess 130
„ large dermoid cyst over the sternum 393
„ congenital abnormality of lower lip associated with cleft palate . 446
COATS (JOSEPH), an adenoid sarcoma with cartilage originating in the pineal gland 44
„ a case of simple diffuse goitre, with secondary tumours of the same structure in the bones of the skull 399
COLLES' FRACTURE, a neglected point in the pathology of (D'Arcy Power) 250
„ — cases on which preceding paper is founded . . . 253
„ — table of specimens in the London hospitals . . . 256
„ repaired with forward displacement of the lower fragment (S. G. Shattock) 260
COLLIER (WILLIAM), sarcoma of pelvis simulating pelvic hæmatocele during life 334
COLLOID CANCER, see *Cancer.*
COMMITTEE ON MORBID GROWTHS, *report* on Mr. Hutchinson's case of sarcoma (?) of the lower end of the femur (J. F. Payne, Sidney Coupland, Anthony A. Bowlby, Charters J. Symonds) . . . 292
„ *report* on Mr. Butlin's case of recurrent (?) melanotic sarcoma of the breast (R. W. Parker and S. G. Shattock) 345
„ *report* on Dr. Edmunds's specimen of horny papilloma of the hand (R. W. Parker and S. G. Shattock) 353
COMMUNICATIONS, SPECIAL:— 412
„ cultivation-experiments with new growths and normal tissues, together with remarks on the parasitic theory of cancer (C. A. Ballance and S. G. Shattock) 412
CORONARY ARTERIES, see *Arteries.*
COUPLAND (SIDNEY), genito-urinary tuberculosis, with caseation of both suprarenal capsules 408
„ and WILLIAM PASTEUR, two cases of diffuse sarcoma of the spinal pia mater 26

COUPLAND (SIDNEY) (*continued*)—
„ see *Wigleworth* (*J.*).
„ *report* on Mr. Hutchinson's case of sarcoma (?) of the lower end of the femur 292

CULTIVATION-EXPERIMENTS with new growths and normal tissues, together with remarks on the parasitic theory of cancer (C. A. Ballance and S. G. Shattock) 412

CYSTIC enlargement of metatarsal bone: sarcoma [microscopical examination and report by Dr. Mott] (J. H. Morgan) . . . 294
„ epithelioma of neck, three cases (A. Q. Silcock) . . . 374
„ see *Tumour*.

CYSTITIS, acute tubercular exfoliating (perforation) (E. H. Fenwick) . 187

CYSTOTOMY, supra-pubic, tumour removed by (Sydney Jones) . . 179

CYSTS in kidneys produced by old ascending nephritis (G. N. Pitt) . 164
„ and ranula in the neighbourhood of the hyoid bone (J. B. Sutton) . 386
„ dermoid, of the right testis (D'Arcy Power) . . . 224
„ — large, over the sternum (H. H. Clutton) . . . 393
„ intermuscular synovial, further specimens of (D'Arcy Power) . . 381
„ malignant, of neck (F. Treves) 360
„ tubo-ovarian, a pair of chronic inflamed uterine appendages, illustrating the development of (A. Doran) 241
„ see *Tumours, cystic*.

DAKIN (W. R.), atrophied kidney and dilated ureter from a female child aged two years 169

DELÉPINE (S.), case of alveolar sarcoma, see *Turner* (*G. R.*).

DERMOID CYST, see *Cyst*.

DIABETES, cirrhosis of pancreas in (W. B. Hadden) . . . 163

DIAPHRAGM, subpleural lipoma of (F. W. Clark) . . . 324

DIGESTION, organs of, diseases, &c. . . . 127–163

DISEASES, &c., of the nervous system 9–82
„ of the organs of respiration 83–95
„ of the organs of circulation 96–126
„ of the organs of digestion 127–163
„ of the genito-urinary organs 164–249
„ of the osseous system 250–320
„ of the organs of special sense 321–322
„ of the ductless glands 396–409
„ of the skin 410–411
„ of the lower animals 451–459
„ of vegetables 460–491

DISLOCATION OF HIP, bilateral, probably congenital (S. G. Shattock) . 299
„ — remarks on so-called (W. Adams) 300
„ congenital (A. A. Bowlby) 295; (J. H. Morgan) 298; (?) (D'Arcy Power) 299.

DIVERTICULUM, Meckel's (H. Handford) 129

DORAN (ALBAN), a pair of chronic inflamed uterine appendages, illustrating the development of tubo-ovarian cysts 241
„ fibro-myoma of the ovarian ligament 245
„ horny growth from the neck 354

DUCTLESS GLANDS, diseases, &c., of the . . . 396–409

DUODENUM, chronic perforating ulcer of, with erosion of pancreatic artery (W. H. Allchin) 144

DURA MATER, endothelioma of the (E. Hyla Greves) . . . 20
„ hæmatoma of (H. Sainsbury) 12
„ — — (sub-dural) (J. A. Ormerod) 13
„ from a case of purpura (F. C. Turner) 189
„ thrombosis of venous sinuses of; fatal cerebral hæmorrhage in a boy aged five years (H. Handford) 40

ECTOPIA VESICÆ (S. G. Shattock) 170
Edmunds (**Walter**), horny papilloma of hand . . . 352
„ — *report* of Morbid Growths Committee on above (R. W. Parker and S. G. Shattock) 353
„ carcinoma myxomatodes 377
Edwards (**F. Swinford**), cases of small round-celled sarcoma of testicle and spermatic cord 221
EMBOLISM of the basilar artery, with meningeal hæmorrhage from rupture of the posterior cerebral (H. Maudsley) 11
ENCEPHALOID CANCER of right kidney (E. H. Fenwick) . . 166
„ disease of apex of bladder (E. H. Fenwick) . . . 182
ENCHONDROMATA, multiple, with multiple angiomata of leg and a sarcoma (F. S. Eve) 326
ENDOCARDITIS with necrosis of the mitral valve (F. C. Turner) . . 115
„ malignant, right-sided (W. Hale White) 114
ENDOTHELIOMA of the dura mater (E. Hyla Greves) . . 20
ENTERIC FEVER, see *Fever*.
EPITHELIAL TUMOUR, recurrent, of foot (T. Smith) . . . 376
EPITHELIOMA of larynx (S. West) 85
„ case of horn growing from the glans penis associated with (A. P. Gould) 355
„ cystic, of neck, three cases (A. Q. Silcock) . . . 374
„ double, of bladder (W. Bruce Clarke) 181
„ squamous, of œsophagus causing broncho-œsophageal fistula; Meckel's diverticulum in the same subject (H. Handford) . . . 129
Eve (**F. S.**), case of hemiatrophia facialis 81
„ cystic tumours of the testicle 201
„ — table of cases 214
„ multiple, painful, fatty tumours of arms 323
„ multiple angiomata of leg with multiple enchondromata and a sarcoma . 326
„ unilateral papilloma of tongue 358
EXTRA-UTERINE PREGNANCY, see *Pregnancy*.
FACE, case of hemiatrophia facialis (F. S. Eve) . . . 81
FATTY TUMOUR, see *Tumour*.
FEMUR, congenital malformation of, see *Hip*.
„ sequel to a case of central sarcoma of ('Path. Trans.,' xxxvii, 377) (D'Arcy Power) 288
„ sarcoma (?) of the lower end of the (J. Hutchinson and J. Hutchinson, jun.) 288
„ — *report* of Morbid Growths Committee on (J. F. Payne, Sidney Coupland, Anthony A. Bowlby, Charters J. Symonds) . . . 292
Fenwick (**E. Hurry**), urinary tuberculosis with multiple renal calculi . 165
„ encephaloid cancer of right kidney 166
„ frozen section of an hypertrophied bladder removed from a case of stricture of the urethra 172
„ encephaloid disease of apex of bladder 182
„ acute tubercular exfoliating cystitis (perforation) . . . 187
„ purpura hæmorrhagica of the bladder . . . 188

FENWICK (E. HURRY) (*continued*)—
„ calculus formed round an india-rubber umbrella ring . . 193
„ a case of carcinoma of the right lobe of the prostate . . 195
„ a case of metastatic carcinoma of the prostate . . . 196
„ a case of carcinoma of the left vesicula seminalis and adjoining lobe of prostate 199
„ see *Hewkley* and *Fenwick*, a case of villous tumour of the bladder . 179
FEVER, enteric, perforation of large intestine in (W. B. Hadden) . . 145
FIBROID, large, in pelvis, interfering with the functions of the rectum and bladder, uterus extirpated on account of (Sydney Jones) . . 247
„ uterine, large, and the uterus with a smaller submucous fibroid (P. Horrocks) 249
FIBROMA, soft, of palm of hand (Sydney Jones) . . . 324
„ see *Myxofibroma, Neuro-fibromata.*
FIBRO-MYOMA of the ovarian ligament (A. Doran) . . . 245
FIBROSIS OF LUNGS, disseminated (W. B. Hadden) . . . 92
„ — (quiescent tubercle) (R. G. Hebb) 94
FIBROUS NODULES over sarcoma of the back (J. H. Targett) . . 330
FISTULA, broncho-œsophageal, consequent upon malignant growth (squamous epithelioma) of œsophagus; Meckel's diverticulum in the same subject (H. Handford) 129
FOOT, recurrent epithelial tumour of the (T. Smith) . . . 376
FOX (T. COLCOTT), case of infantile scurvy 275
FRACTURE, COLLES', a neglected point in the pathology of (D'Arcy (Power) 250
„ — cases on which preceding paper is founded . . . 253
„ — table of specimens in the London Hospitals . . . 256
„ — repaired with forward displacement of the lower fragment (S. G. Shattock) 260

GALL-STONES, see *Calculi, biliary.*
GENERATIVE ORGANS, diseases of, in animals (J. B. Sutton) . . 451
„ tuberculosis of, with caseation of both suprarenal capsules (S. Coupland) 408
GENITO-URINARY ORGANS, diseases, &c., of the . . 164–249
GLAND, see *Bronchial, Pineal.*
GODLEE (R. J.), adeno-sarcoma of tongue, with calcifying nodule in the centre 346
GOITRE, case of simple diffuse, with secondary tumours of the same structure in the bones of the skull (J. Coats) 399
GOODHART (J. F.), see *Green, A. Withers.*
GOULD (A. PEARCE), a case of horn growing from the glans penis, associated with epithelioma 355
GREEN (A. WITHERS), per *J. F. Goodhart*, ruptured aneurysm of the heart (syphilis) 102
„ per ditto, aneurysm of arch of aorta rupturing into pericardial sac . 119
GREVES (E. HYLA), endothelioma of the dura mater . . . 20
GRIFFITH (W. S. A.), a specimen of early pregnancy in the fimbriated extremity of a Fallopian tube, with retro-uterine intra-peritoneal hæmatocele, and a decidual cast of the uterine cavity. . . . 227
GROWTHS, intra-bursal (G. H. Makins) 377
„ new, apparently springing from the periosteum of the right clavicle, and extending into the triangles of the neck (J. R. Lunn) . . 287

GULLIVER (G.), aneurysm of arch of aorta communicating with superior cava 120

HADDEN (W. B.), fatal cases of alcoholic paralysis . . . 57
„ tubercular ulceration of trachea 89
„ disseminated fibrosis of lungs 92
„ aneurysm of the mitral valve in a child 116
„ perforation of large intestine in enteric fever . . . 145
„ carcinoma of cæcum with extreme narrowing . . . 148
„ cirrhosis of pancreas in diabetes 163

HÆMATOCELE, pelvic, sarcoma of pelvis simulating, during life (W. Collier) 334
„ retro-uterine intra-peritoneal, in case of early pregnancy in the fimbriated extremity of a Fallopian tube (W. S. A. Griffith) . . . 227

HÆMATOMA of dura mater (H. Sainsbury), ... 12
„ — subdural (J. A. Ormerod) 13

HÆMOPTYSIS, rapidly fatal, from ulceration of a large branch of the pulmonary artery in a child (W. Pasteur) 91

HÆMORRHAGE, cerebral, fatal, in a boy aged 5 years, following thrombosis of the venous sinuses of the dura mater (H. Handford) . . 40
„ intraspinal; (?) secondary to sarcoma of dorsal vertebra (T. F. Raven) . 335
„ meningeal (T. D. Savill) 9
„ — from rupture of the posterior cerebral (H. Maudsley) . . 11
„ — old, with cerebral softening and secondary descending degeneration (W. Hale White) 13

HAIR-PIN as nucleus to large vesical calculus (S. Jones) . . 194

HAMMER TOES (S. G. Shattock) 449

HAND, soft fibroma of palm of (Sydney Jones) . . . 324
„ congenital malformation of (Sydney Jones) . . . 447
„ horny papilloma of (W. Edmunds) 352
„ — *report* of Morbid Growths Committee on above (R. W. Parker and S. G. Shattock) 353

HANDFORD (H.), fatal cerebral hæmorrhage in a boy aged 5 years, following thrombosis of the venous sinuses of the dura mater 40
„ fatty tumour (lipoma) of the heart 108
„ aneurysm of aorta (transverse part of arch) rupturing into œsophagus; no previous œsophageal symptoms 118
„ stricture of œsophagus; secondary growths in lung . . . 128
„ broncho-œsophageal fistula consequent upon malignant growth (squamous epithelioma) of œsophagus; Meckel's diverticulum in the same subject . 129

HARRISON (REGINALD), urinary organs from a case of Bilharzia hæmatobia . 191

HEART, aneurysm of (A. Money) 97
„ — ruptured, of the (syphilis) (A. Withers Green) . . . 102
„ *ante-mortem* clot on right side of, containing growth in case of sarcoma of left lobe of thyroid (G. N. Pitt) 398
„ congenital malformation of, two cases; perforation of septum ventriculorum; undefended space open (F. Willcocks) 96
„ diffuse syphiloma of (W. Pasteur) 103
„ fatty tumour (lipoma) of the (H. Handford) . . . 108
„ see *Septum*, *Valve*.

HEBB (R. G.), quiescent tubercle (disseminated fibrosis) of lung . . 94
„ tuberculosis of the uterus 226

HEMIATROPHIA FACIALIS, case of (F. S. Eve) . . . 81

HERRINGHAM (W. P.) and D'ARCY POWER, round-celled sarcoma of the spinal cord and brain 43

HEWKLEY (FRANK) and E. H. FENWICK, a case of villous tumour of the bladder 179

HIP, two specimens of fœtus, illustrating absence of the margin of the acetabulum, with and without displacement of the head of the femur (C. B. Lockwood) 303
„ congenital dislocation of (A. A. Bowlby) 295
„ — (J. H. Morgan) 298
„ — (?) (D'Arcy Power) 299
„ bilateral dislocation, probably congenital (S. G. Shattock) . . 299
„ congenital displacement, or so-called dislocation of the (W. Adams) . 300
HORN growing from the glans penis, associated with epithelioma (A. P. Gould) 355
HORNY GROWTH from the neck (A. Doran) 354
HORROCKS (P.), large uterine fibroid and the uterus with a smaller submucous fibroid 249
HOUR-GLASS CONSTRICTION, see *Stomach*.
HUDSON (LEOPOLD), a case of hour-glass constriction of the stomach . 133
„ colloid cancer of stomach 143
„ sarcoma of pelvic fascia 331
HUMERUS, case of disease of (J. R. Lunn) 266
„ — histology of preceding case (S. G. Shattock) . . . 267
HUTCHINSON (JONATHAN), destructive inflammation of knee-joint without suppuration 312
„ and (HUTCHINSON, J., jun.) sarcoma (?) of the lower end of the femur . 288
„ — *report* of the Morbid Growths Committee on above (J. F. Payne, Sidney Coupland, Anthony A. Bowlby, Charters J. Symonds) . . . 292
HUTCHINSON (JONATHAN, jun.) ulcerative stomatitis in a child; miliary tuberculosis 127
„ see *Hutchinson* (*Jonathan*), sarcoma (?) of the lower end of the femur . 288
HYDATID of the breast (C. J. Symonds) 448
HYDRONEPHROSIS, slight unilateral, due to stricture of the ureter (G. N Pitt) 168
HYDROSALPINX, two cases of (G. N. Pitt) 245
HYOID BONE, ranula and cysts in the neighbourhood of the (J. B. Sutton) 386
HYPERTROPHIED BLADDER, frozen section of, removed from a case of stricture of the urethra (E. H. Fenwick) 173

IDIOCY: aneurysm of heart: cerebral tumour (A. Money) . . 97
INFANTILE PARALYSIS, see *Paralysis*.
INFLAMMATION, destructive, of knee-joint without suppuration (J. Hutchinson) 312
INTESTINE, perforation of, four days after accident (J. H. Targett) . 143
„ — of large, in enteric fever (W. B. Hadden) . . . 145
JACOB (ERNEST), per *Felix Semon*, hyperplastic syphilitic laryngitis . 83
JAW, lower, multilocular cystic tumour of the (A. A. Bowlby) . . 359
JEJUNUM, congenital occlusion of (F. C. Turner) . . . 145
JOINT AFFECTION, multiple, in a case of locomotor ataxy (A. H. Robinson) 319
JONES (SYDNEY), tumour (papillomatous) removed by supra-pubic cystotomy 179
„ large vesical calculus with hair-pin as nucleus . . . 194
„ uterus extirpated on account of large fibroid in pelvis interfering with the functions of the rectum and bladder 247
„ large parotid tumour 358
„ soft fibroma of palm of hand 324
„ congenital malformation of hand 447

KIDNEY from a case of purpura (F. C. Turner) 189
„ atrophied, and dilated ureter from a female child aged two years (W. R. Dakin) 169
„ encephaloid cancer of right (E. H. Fenwick) . . . 166
„ great dilatation of pelvis, secondary to urethral stricture (W. Hale White) 168
„ with old ascending nephritis, which has produced numerous large cysts and extensive local destruction and shrinking (G. N. Pitt) . . 164
KNEE-JOINTS, disease of, recovery (?) from tubercular meningitis in chronic phthisis with (R. E. Carrington) 16
„ destructive inflammation of the, without suppuration (J. Hutchinson) . 312
LARYNGITIS, hyperplastic syphilitic (E. Jacob) . . . 83
LARYNX, epithelioma of (S. West) 85
LEG, multiple angiomata of, with multiple enchondromata and a sarcoma (F. S. Eve) 326
LEPROSY, bacilli of (B. N. Rake) 439
„ remarks on above (G. Thin) 439
„ anæsthetic, spontaneous cure of thoracic aneurysm in (B. N. Rake) . 120
LIONS, young, curious effect of rickets on the skulls of (J. B. Sutton) . 456
LIP, lower, congenital abnormality of, associated with cleft palate (H. H. Clutton) 446
LIPOMA, see *Fatty Tumour.*
LITHOPÆDION (C. Stonham) 445
LIVER, malarial disease of, with tuberculosis (N. Moore) . . 149
„ primary scirrhus of, of tubular type, with secondary growths in liver, lung, vertebra, Douglas's pouch, &c.; prostatic calculi (G. N. Pitt) . 151
LOCKWOOD (C. B.), two specimens of fœtus, illustrating absence of the margin of the acetabulum, with and without displacement of the head of the femur 303
LOCOMOTOR ATAXY, on the falling out of the teeth in (W. Hale White) . 79
„ drawings of multiple joint affection in a case of (A. H. Robinson) . 319
LUNGS, disseminated fibrosis of (W. B. Hadden) . . . 92
„ — (quiescent tubercle) (R. G. Hebb) 94
„ secondary growths in, in case of stricture of œsophagus (H. Handford) . 128
„ from a case of chronic pleurisy (W. Pasteur) . . . 94
LUNN (J. R.), case of disease of the humerus . . . 266
„ — account of the histology (S. G. Shattock) . . . 267
„ a new growth, apparently springing from the periosteum of the right clavicle, and extending into the triangles of the neck, &c. . . 287

MCKINNON (—), see *Ormerod*, subdural hæmatoma.
"MACRO-ANGIOSIS" of left upper extremity (R. Barwell) . . 121
MAGUIRE (R.), bullet wound of the left ventricle . . . 97
„ interstitial aneurysm of the interauricular septum . . . 100
MAKINS (G. H.), some intra-bursal growths 377
MALARIAL DISEASE of liver and spleen with tuberculosis (N. Moore) . 149
MALFORMATION, congenital, of hand (S. Jones) . . . 447
„ see *Abnormality, Deformity.*
MAUDSLEY (HENRY), embolism of the basilar artery, with meningeal hæmorrhage from rupture of the posterior cerebral . . . 11
„ ulceration of the trachea and rupture of aorta . . . 89
MECKEL'S DIVERTICULUM, see *Diverticulum.*
MELANOTIC (?) sarcoma of breast, recurrent (H. T. Butlin) . . 343
„ — *report* of Morbid Growths Committee on above (R. W. Parker and S. G. Shattock) 345
„ — of the hard palate (F. Treves) 350

MENINGEAL HÆMORRHAGE, see *Hæmorrhage.*
MENINGITIS, cerebro-spinal, causing an abscess in the œsophagus (W. Hale White) 14
„ tubercular, recovery (?) from, in chronic phthisis with disease of knee-joints and spinal caries (R. E. Carrington) . . . 16
METATARSAL BONE, cystic enlargement of; sarcoma [microscopical examination and report by Dr. Mott] (J. H. Morgan) . . 294
MICROPHTHALMOS on the left side in a newborn child (S. G. Shattock) . 321
MILIARY TUBERCULOSIS, see *Tuberculosis.*
MISCELLANEOUS SPECIMENS 439–450
MOLLUSCUM FIBROSUM, multiple neuro-fibromata in connection with (J. F. Payne) 69
MONEY (ANGEL), aneurysm of heart; cerebral tumour; idiocy . . 97
MOORE (NORMAN), aneurysm of sinus of Valsalva . . . 100
„ malarial disease of liver and spleen with tuberculosis . . 149
MORBID GROWTHS AND TUMOURS . . . 322–395
MORGAN (JOHN H.), cystic enlargement of metatarsal bone; sarcoma [microscopical examination and report by Dr. Mott] . . . 294
„ congenital dislocation of hip 298
MOTT (F. W.) myxofibroma of the fifth dorsal nerve (left side) extending to the spinal canal, producing compression of the cord . . 52
„ microscopical examination and report in Mr. Morgan's case of cystic enlargement of metatarsal bone; sarcoma . . . 294
MOULLIN (C. MANSELL), sacculated bladder with calculus fixed behind prostate 178
MYOMA, see *Fibro-myoma.*
MYXOFIBROMA of the fifth dorsal nerve (left side) extending to the spinal cord, producing compression of the cord (F. W. Mott) . . 52

NECK, three cases of cystic epithelioma of (A. Q. Silcock) . . 374
„ malignant cysts of the (F. Treves) 360
„ horny growth from the (A. Doran) 354
NECROSIS of mitral valve; endocarditis (F. C. Turner) . . . 115
„ acute, of fourth cervical vertebra in a man of forty-eight (S. West) . 268
NEOPLASIA, a new theory of (W. Roger Williams) . . . 460
NEPHRITIS, old ascending, which produced numerous large cysts and extensive local destruction and shrinking (G. N. Pitt) . . . 164
NERVE, myxofibroma of fifth dorsal (left side), extending to the spinal canal, producing compression of the cord (F. W. Mott) . . 52
NERVOUS SYSTEM, diseases, &c., of the 9–82
NEURITIS, peripheral (W. Hale White) 68
„ — in Raynaud's disease (J. Wigleswortb) 61
NEURO-FIBROMATA, multiple, in connection with molluscum fibrosum (J. F. Payne) 69
NODULES, fibrous, over sarcoma of back (J. H. Targett) . . 330

OCCLUSION, congenital, of jejunum (F. C. Turner) . . . 145
ŒSOPHAGUS, abscess in, caused by cerebro-spinal meningitis (W. Hale White) 14
„ retro-œsophageal abscess (H. H. Clutton) 130
„ aneurysm of aorta (transverse part of arch), rupturing into the œsophagus: no previous œsophageal symptoms (H. Handford) . . . 118
„ stricture of; secondary growths in lung (H. Handford) . . 128
ORD (W. M.), spontaneous disintegration of vesical calculus . . 191

ORGANS OF SPECIAL SENSE, diseases, &c., of . . 321–322
ORMEROD (J. A.), for *Dr. McKinnon*, subdural hæmatoma . . 13
OSSEOUS SYSTEM, diseases, &c., of the . . . 250–320
OSTEITIS DEFORMANS, case of, associated with a sarcomatous tumour of cerebellum (A. H. Robinson) 262
OSTEOMALACIA, two specimens showing metaplasia of the osseous substance into fibrous tissue (S. G. Shattock) 270
OSTEOMYELITIS of scapula; separation of its coracoid epiphysis; pyæmia (J. Poland) 261
OVARIAN cysts, see *Tubo-ovarian cysts.*
„ ligament, fibro-myoma of the (A. Doran) 245
OVARY, parts after removal of the, six months previously (S. G. Shattock) . 450
OVUM, included, case of (S. Taylor) 440

PAGE (H. W.), see *Raven* (*T. F.*).
PAGET (Sir JAMES), address as President, delivered January 18th, 1887 . 1
PAGET (STEPHEN), tumours of the palate 348
„ malignant disease of thyroid (round-celled sarcoma) . . 397
„ see *Smith* (*T.*)
PALATE, tumours of the (S. Paget) 348
„ cleft, congenital abnormality of lower lip, associated with (H. H. Clutton) . 446
„ hard, melanotic sarcoma of (F. Treves) 350
PANCREAS, cirrhosis of, in diabetes (W. B. Hadden) . . . 163
PANCREATIC ARTERY, see *Artery.*
PAPILLOMATA, multiple, with chondrifying sarcoma, removed from the male urinary bladder (S. G. Shattock) 183
„ unilateral, of tongue (F. S. Eve) 358
„ see *Horny papilloma.*
PARALYSIS, alcoholic, fatal cases of (W. B. Hadden) . . . 57
„ infantile, case of; the original attack occurring fifty-eight years before death (S. J. Sharkey) 53
PARASITIC theory of cancer, cultivation-experiments (C. A. Ballance and S. G. Shattock) 412
PARKER (R. W.), *report* on Mr. Butlin's case of recurrent (?) melanotic sarcoma of the heart 345
„ *report* on Dr. Edmunds's case of horny papilloma of hand . . 353
PAROTID TUMOUR, large (S. Jones) 358
PASTEUR (W.), rapidly fatal hæmoptysis from ulceration of a large branch of the pulmonary artery in a child 91
„ lung from a case of chronic pleurisy 94
„ a case of diffused syphiloma of the heart 103
„ morbus Addisonii 409
„ see *Coupland* and *Pasteur*, diffuse sarcoma of spinal pia mater.
PAYNE (J. F.), multiple neuro-fibromata in connection with molluscum fibrosum 69
„ *report* on Mr. Hutchinson's case of sarcoma (?) of the lower end of the femur 292
PELVIC FASCIA, sarcoma of (L. Hudson) 331
PELVIS, sarcoma of, simulating pelvic hæmatocele during life (W. Collier) . 334
PENIS, a case of horn growing from the glans penis, associated with epithelioma (A. P. Gould) 355
PERFORATION, see *Intestine.*

PERITONEUM, trunk of an infant, showing a persistent fœtal condition of the (C. Stonham) 445
PHTHISIS, chronic, recovery (?) from tubercular meningitis in (R. E. Carrington) 16
PIA MATER, spinal, diffuse sarcoma of (S. Coupland and W. Pasteur) . 26
PINEAL GLAND, adenoid sarcoma with cartilage originating in the (J. Coats) 44
PITT (G. N.), stomach with numerous superficial erosions following after an extensive burn 140
„ primary scirrhus of liver of tubular type with secondary growth in liver, lung, vertebra, Douglas's pouch, &c., prostatic calculi . . 151
„ kidneys with old ascending nephritis, which has produced numerous large cysts and extensive local destruction and shrinking . . . 164
„ slight unilateral hydronephrosis due to stricture of the ureter . . 168
„ thickened capsule of testicle 200
„ two cases of hydrosalpinx 245
„ ulcer of vagina 249
„ sarcoma of left lobe of thyroid growing round œsophagus, and invading left internal jugular vein and left vagus; *ante-mortem* clot on right side of heart containing growth 398
PLEURISY, chronic, lung from a case of (W. Pasteur) . . . 94
POLAND (JOHN), osteomyelitis of scapula; separation of its coracoid epiphysis; pyæmia 261
POLLARD (BILTON), tubercle of the skull leading to perforation . . 284
POWER (D'ARCY), imperforate anus; (A) male, (B) female . . 149
„ a dermoid cyst of the right testis 224
„ a neglected point in the pathology of Colles' fracture . . 250
„ — cases on which preceding paper is founded . . . 253
„ — table of specimens in the London hospitals . . . 256
„ the sequel of a case of central sarcoma of the femur ('Path. Trans.,' xxxvii, 377) 288
„ congenital (?) displacement of the hip 299
„ a rhinolith 321
„ further specimens of intermuscular synovial cysts . . . 381
„ see *Herringham* and *Power*, round-celled sarcoma of spinal cord and brain.
PREGNANCY, early, in the fimbriated extremity of a Fallopian tube, with retro-uterine intra-peritoneal hæmatocele and a decidual cast of the uterine cavity (W. S. A. Griffith) 227
„ tubal, note on the pathology of (Lawson Tait) . . . 230
„ extra-uterine, additional note on the pathology of (Lawson Tait) . 236
PRESIDENT'S ADDRESS, see *Paget* (*Sir James*).
PRICE (J. A. P.), cholesteatoma at the base of the brain . . 24
PROSTATE, case of carcinoma of right lobe of the (E. H. Fenwick) . 195
„ — of left vesicula seminalis and adjoining lobe of (E. H. Fenwick) . 199
„ — metastatic (E. H. Fenwick) 196
PURPURA, bladder, kidney, and dura mater from a case of (F. C. Turner) . 189
„ hæmorrhagica of the bladder (E. H. Fenwick) . . . 188
PYÆMIA, in case of osteomyelitis of scapula (J. Poland) . . 261
PYE-SMITH (P. H.), two cases of gall-stone causing obstruction of the bowels 160

RAKE (BEAVAN N.), spontaneous cure of thoracic aneurysm in anæsthetic leprosy 120
„ bacilli of leprosy 439
„ — remarks on above (G. Thin) 439

RANULA and cysts in the neighbourhood of the hyoid bone (J. B. Sutton) . 386
RAVEN (T. F.), per *H. W. Page*, sarcoma of dorsal vertebra; intraspinal hæmorrhage ; (?) secondary 335
RAYNAUD'S DISEASE, peripheral neuritis in (J. Wigleswortb) . . 61
RECTUM, functions of, interfered with by large fibroid in pelvis ; extirpation of uterus for (Sydney Jones) 247
RESPIRATION, organs of, diseases, &c., of . . . 83–95
RHINOLITH, a (D'Arcy Power) 321
RICKETS in case of extensive disease of the bones from a case of congenital syphilis (W. H. Battle) 279
„ curious effect of, on the skulls of young lions (J. B. Sutton) . . 456
ROBINSON (A. H.), a case of osteitis deformans associated with a sarcomatous tumour of cerebellum 262
„ drawings of multiple joint affection in a case of locomotor ataxy . 319
ROUSE (J.), per *W. Bull*, sarcoma of clavicle . . . 287
RUPTURE of aorta, ulceration of trachea (H. Maudsley) . . . 89
„ bladder, subperitoneal (W. Bruce Clarke) 177
„ of posterior cerebral, meningeal hæmorrhage from (H. Maudsley) . 11

SACRAL TUMOUR, congenital, containing bone (J. H. Targett) . . 395
SAINSBURY (Harrington), hæmatoma of dura mater . . . 12
„ stenosis of mouths of coronary arteries ; anginal symptoms . . 117
„ cystic tumour of the cæcum 146
„ tubercular mass in suprarenal capsule 406
SARCOMA of the back with fibrous nodules over it (J. H. Targett) . 330
„ of clavicle (— Rouse) 287
„ central, of the femur, sequel to case ('Path. Trans.,' xxxvii, 377) . 288
„ (?) of the lower end of the femur (J. Hutchinson and J. Hutchinson, jun.) 288
„ — *report* of Morbid Growths Committee on (J. F. Payne, Sidney Coupland, Anthony A. Bowlby, and Charters J. Symonds) . . . 292
„ of leg, with multiple angiomata and enchondromata (F. S. Eve) . 326
„ in case of cystic enlargement of metatarsal bone [microscopical examination and report by Dr. Mott] (J. H. Morgan) . . . 294
„ of pelvic fascia (L. Hudson) 331
„ of pelvis simulating pelvic hæmatocele during life (W. Collier) . 334
„ of left lobe of thyroid growing round œsophagus, and invading left internal jugular vein and left vagus ; *ante-mortem* clot on right side of heart containing growth (G. N. Pitt) 398
„ of dorsal vertebræ ; intraspinal hæmorrhage ; (?) secondary (T. F. Raven). 335
„ adenoid, with cartilage originating in the pineal gland (J. Coats) . 44
„ alveolar, case of (G. R. Turner) 335
„ chondrifying, removed, together with multiple papillomata, from the male urinary bladder (S. G. Shattock) 183
„ diffuse, of the spinal pia mater, two cases (S. Coupland and W. Pasteur) . 26
„ melanotic, of the hard palate (F. Treves) . . . 350
„ — (?) recurrent of breast (H. T. Butlin) 343
„ — *report* of Morbid Growths Committee on above (R. W. Parker and S. G. Shattock) 345
„ round-celled, of spinal cord and brain (W. P. Herringham and D'Arcy Power) 43
„ — of thyroid (S. Paget) 397
„ — of testicle and spermatic cord (F. S. Edwards) . . . 221
„ see *Adeno-sarcoma*.
SARCOMATOUS TUMOUR of cerebellum in case of osteitis deformans (A. H. Robinson) 262

SAVILL (T. D.), meningeal hæmorrhage 9
SCAPULA, osteomyelitis of; separation of its coracoid epiphysis; pyæmia (J. Poland) 261
SCIRRHUS, primary, of liver, of tubular type, with secondary growths in liver, lung, vertebra, Douglas's pouch, &c., prostatic calculi (G. N. Pitt) 151
SCURVY, infantile, case of (T. Colcott Fox) 275
SEMON (FELIX), see *Jacob* (*Ernest*).
SEPTUM, interauricular, interstitial aneurysm of (R. Maguire) . . 100
„ ventriculorum, perforation of (F. Willcocks) . . . 96
SHARKEY (S. J.), case of infantile paralysis, the original attack occurring fifty-eight years before death 53
„ a case of syphilitic arteritis 124
SHATTOCK (S. G.), ectopia vesicæ 170
„ chondrifying sarcoma removed, together with multiple papillomata, from the male urinary bladder 183
„ Colles' fracture repaired, with forward displacement of the lower fragment 260
„ histology of Mr. Lunn's case of disease of the humerus . . 266
„ two specimens of osteomalacia, showing metaplasia of the osseous substance into fibrous tissue 270
„ bilateral dislocation of the hip-joints, probably congenital . . 299
„ microscopic sections from six cases of tubercular arthritis . . 316
„ microphthalmos on the left side in a newborn child . . . 321
„ tubercular disease of the skin 410
„ hammer toes 449
„ the parts after removal of the ovary six months previously . . 450
„ see *Ballance* and *Shattock*, cultivation-experiments with new growths and normal tissues, together with remarks on the parasitic theory of cancer.
„ *report* on Mr. Butlin's case of recurrent (?) melanotic sarcoma of the breast 345
„ — on Dr. Edmunds's case of horny papilloma of hand . . 353
SHAW (LAURISTON), localised bronchiectasis caused by the invasion into a bronchus of a caseating bronchial gland 90
SILCOCK (A. Q.), three cases of cystic epithelioma of the neck . . 374
SINUS OF VALSALVA, aneurysm of (N. Moore) . . . 100
SKIN, diseases of the 410–411
„ tubercular disease of the (S. G. Shattock) 410
SKULL, tubercle of the, leading to perforation (B. Pollard) . . 284
„ secondary tumours of, in case of simple diffuse goitre (J. Coats) . 399
SMITH (THOMAS), senile arthritis 313
„ per *S. Paget*, recurrent epithelial tumour of foot . . . 376
SPERMATIC CORD, cases of small round-celled sarcoma of testicle and (F. S. Edwards) 221
SPINAL CARIES, recovery (?) from tubercular meningitis in chronic phthisis with (R. E. Carrington) 16
SPINAL CORD, compression of the, from myxofibroma of fifth dorsal nerve (F. W. Mott) 52
„ round-celled sarcoma of (W. P. Herringham and D'Arcy Power) . 43
SPLEEN, malarial disease of, with tuberculosis (N. Moore) . . 149
STENOSIS of mouths of coronary arteries; anginal symptoms (H. Sainsbury) 117
STERNUM, large dermoid cyst over the (H. H. Clutton) . . 393
STOKER (G.), cancer of the thyroid 396
STOMACH, colloid cancer of (L. Hudson) 143
„ hour-glass constriction of the (L. Hudson) . . . 133
„ — — fibrous contraction with (F. C. Turner) . . . 138

STOMACH (*continued*)—
„ with numerous superficial erosions following after an extensive burn (G. N. Pitt) 140
„ ulcers of, in a child, the subject of general tuberculosis (T. Barlow) . 141
STOMATITIS, ulcerative, in a child; miliary tuberculosis (J. Hutchinson, jun.) 127
STONHAM (C.), trunk of an infant, showing a persistent fœtal condition of the peritoneum 445
„ lithopædion 445
STRICTURE of œsophagus; secondary growths in lungs (H. Handford) . 128
SUPRARENAL CAPSULES, caseation of both, in case of genito-urinary tuberculosis (S. Coupland) 408
„ — tubercular mass in (H. Sainsbury) 406
SUTTON (J. B.), ranula and cysts in the neighbourhood of the hyoid bone . 386
„ diseases of the genito-urinary organs in animals . . . 451
„ a curious effect of rickets on the skulls of young lions . . 456
SYMONDS (C. J.), hydatid of the breast 448
„ *report* on Mr. Hutchinson's case of sarcoma (?) of the lower end of the femur 292
SYNOVIAL CYSTS, intermuscular, further specimens of (D'Arcy Power) . 381
SYPHILIS; ruptured aneurysm of heart (A. W. Green) . . . 102
„ congenital, extensive disease of the bones from a case of, associated with rickets (W. H. Battle) 279
SYPHILITIC arteritis case of (S. J. Sharkey) 124
„ laryngitis, hyperplastic (E. Jacob) 83
SYPHILOMA, diffuse, of the heart (W. Pasteur) . . . 103

TAIT (LAWSON), note on the pathology of tubal pregnancy . . 230
„ further note on the pathology of extra-uterine pregnancy . . 236
TARGETT (J. H.), perforation of intestine four days after accident . 143
„ extra-peritoneal wound of bladder without extravasation . . 176
„ sarcoma of the back with fibrous nodules over it . . . 330
„ congenital sacral tumour containing bone 395
TAYLOR (SEYMOUR), case of included ovum 440
TEETH, on the falling out of the, in locomotor ataxy (W. Hale White) . 79
TESTICLE, cases of small round-celled sarcoma of, and spermatic cord (F. S. Edwards) 221
„ thickened capsule of (G. N. Pitt) 200
„ dermoid cyst of right (D'Arcy Power) 224
„ cystic tumours of the, with table of cases (F. S. Eve) . . 201
THIN (G.), remarks on Dr. Rake's preparation of lepra-bacilli . . 439
THORACIC ANEURYSM, see *Aneurysm*.
THROMBOSIS of venous sinuses of dura mater; fatal cerebral hæmorrhage in a boy aged five years (H. Handford) 40
THYROID, cancer of the (G. Stoker) 396
„ malignant disease of (round-celled sarcoma) (S. Paget) . . 397
„ sarcoma of left lobe of, growing round œsophagus, and invading left internal jugular vein and left vagus; *ante-mortem* clot on right side of heart containing growth (G. N. Pitt) 398
TOES, hammer (S. G. Shattock) 449
TONGUE, adeno-sarcoma of, with calcifying nodule in the centre (R. J. Godlee) 346
„ unilateral papilloma of (F. S. Eve) 358

TRACHEA, ulceration of, and rupture of the aorta (H. Maudsley) . . 89
„ — tubercular (W. B. Hadden) 89

TREVES (F.), melanotic sarcoma of the hard palate . . . 350
„ malignant cysts of the neck 360

TUBAL PREGNANCY, see *Pregnancy*.

TUBERCLE of the skull leading to perforation (B. Pollard) . . 284
„ quiescent (disseminated fibrosis) of lung (R. G. Hebb) . . 94

TUBERCULAR arthritis, microscopic sections from six cases (S. G. Shattock) 316
„ exfoliating cystitis, acute (perforation) (E. H. Fenwick) . . 187
„ disease of the skin (S. G. Shattock) 410
„ mass in suprarenal capsule (H. Sainsbury) . . . 406
„ meningitis, see *Meningitis*.
„ tumour of brain (G. Barling) 42
„ ulceration, see *Ulceration*.

TUBERCULOSIS, comparison of cancer with (C. A. Ballance and S. G. Shattock) 412
„ malarial disease of liver and spleen with (N. Moore) . . . 149
„ urinary, with multiple renal calculi (E. H. Fenwick) . . . 165
„ genito-urinary, with caseation of both suprarenal capsules (H. Sainsbury) 408
„ of the uterus (R. G. Hebb) 226
„ ulcers of stomach in a child, the subject of general (T. Barlow) . 141
„ miliary, in case of ulcerative stomatitis in a child (J. Hutchinson, jun.) . 127

TUBO-OVARIAN CYSTS, a pair of chronic inflamed uterine appendages, illustrating the development of (A. Doran) . . . 241

TUMOURS, cerebral (A. Money) 97
„ of the palate (S. Paget) 348
„ parotid, large (S. Jones) 358
„ sacral, congenital, containing bone (J. H. Targett) . . . 395
„ secondary, of bones of skull in a case of simple diffuse goitre (J. Coats) 399
„ recurrent epithelial of foot (T. Smith) 376
„ vegetable, in relation to bud formation; with a new theory of neoplasia (W. Roger Williams) 460
„ cystic, of cæcum (H. Sainsbury) 146
„ — multilocular, of lower jaw (A. A. Bowlby) . . . 359
„ — of the testicle, with table of cases (F. S. Eve) . . . 201
„ fatty (lipoma) of the heart (H. Handford) 108
„ — subpleural of diaphragm (F. W. Clark) 324
„ — multiple, painful of arms (F. S. Eve) 323
„ (papillomatous) removed by supra-pubic cystotomy (Sydney Jones) . 179
„ sarcomatous, of cerebellum, in case of osteitis deformans (A. H. Robinson) 262
„ tubercular, of brain (G. Barling) 42
„ villous, of the bladder (F. Hewkley and E. H. Fenwick) . . 179

TURNER (F. CHARLEWOOD), endocarditis with necrosis of the mitral valve . 115
„ fibrous contraction with hour-glass stricture of the stomach . . 138
„ congenital occlusion of the jejunum 145
„ bladder, kidney, and dura mater from a case of purpura . . 189
„ a case of alveolar sarcoma 335

ULCERATION of a large branch of the pulmonary artery causing rapidly fatal hæmoptysis in a child (W. Pasteur) 91
„ of trachea and rupture of aorta (H. Maudsley) . . . 89
„ tubercular, of trachea (W. B. Hadden) 89

ULCERATIVE STOMATITIS in a child; miliary tuberculosis (J. Hutchinson, jun.) 127
ULCERS of stomach in a child, the subject of general tuberculosis (T. Barlow) 141
„ of vagina (G. N. Pitt) 249
„ chronic perforating, of duodenum with erosion of pancreatic artery (W. H. Allchin) 144
UMBRELLA RING, india-rubber, caclulus formed round (E. H. Fenwick) . 193
UNDEFENDED SPACE, open (F. Willcocks) 96
URETER, dilated, and atrophied kidney from a female child aged two years (W. R. Dakin) 169
„ great dilatation of, secondary to urethral stricture (W. Hale White) . 168
„ stricture of, slight unilateral hydronephrosis due to (G. N. Pitt) . 168
URETHRA, stricture of, great dilatation of one ureter and pelvis of kidney secondary to (W. Hale White) 168
„ — frozen section of an atrophied bladder removed from a case of (E. H. Fenwick) 173
URINARY ORGANS, diseases of, in animals (J. B. Sutton) . . 451
„ — see *Genito-urinary Organs*.
„ from a case of Bilharzia hæmatobia (R. Harrison) . . . 191
„ tuberculosis of, with caseation of both suprarenal capsules (S. Coupland) 408
„ tuberculosis with multiple renal calculi (E. H. Fenwick) . . 165
UTERINE appendages, a pair of chronic inflamed, illustrating the development of tubo-ovarian cysts (A. Doran) 241
„ cavity, decidual cast of (W. S. A. Griffith) . . . 227
„ fibroid, large, and the uterus with a smaller submucous fibroid (P. Horrocks) 249
UTERUS extirpated on account of large fibroid in pelvis interfering with the function of the rectum and bladder (Sydney Jones) . . 247
„ tuberculosis of the (R. G. Hebb) 226

VAGINA, ulcer of (G. N. Pitt) 249
VALVE, mitral, aneurysm of, in a child (W. B. Hadden) . . 116
„ — endocarditis, with necrosis of the (F. C. Turner) . . . 115
VEGETABLE TUMOURS in relation to bud formation, with a new theory of neoplasia (W. Roger Williams) 460
VEGETABLES, diseases, &c., of 460–491
VENA CAVA, aneurysm of arch of aorta communicating with superior (G. Gulliver) 120
VENTRICLE, left, bullet wound of (R. Maguire) . . . 97
VERTEBRA, acute necrosis of fourth cervical, in a man of forty-eight (S. West) 268
„ dorsal, replaced by secondary growth in case of primary scirrhus of liver of tubular type (G. N. Pitt) 159
„ — sarcoma of; intraspinal hæmorrhage; (?) secondary (T. F. Raven) . 335
VESICULA SEMINALIS, carcinoma of left, and adjoining lobe of prostate (E. H. Fenwick) 199

West (Samuel), epithelioma of larynx 85
„ case of acute necrosis of the fourth cervical vertebra in a man of forty-eight 268
White (W. Hale), old meningeal hæmorrhage, with cerebral softening and secondary descending degeneration 13
„ cerebro-spinal meningitis, causing an abscess in the œsophagus . . 14
„ peripheral neuritis 68
„ on the falling out of the teeth in locomotor ataxy . . . 79
„ right-sided malignant endocarditis 114

WHITE (W. HALE) (*continued*)—
„ great dilatation of one ureter and pelvis of kidney, secondary to urethral stricture 168
WIGLESWORTH (JOSEPH), per *Sidney Coupland*, peripheral neuritis in Raynaud's disease (symmetrical gangrene) 61
WILLCOCKS (F.), two cases of congenital malformation of heart; perforation of septum ventriculorum; undefended space open . . . 96
WILLIAMS (W. ROGER), vegetable tumours in relation to bud formation, with a new theory of neoplasia 460
WOUND, bullet, of left ventricle (R. Maguire) . . . 97
„ of bladder, extra-peritoneal, without extravasation (J. H. Targett) . 176

PRINTED BY ADLARD AND SON, BARTHOLOMEW CLOSE.

BLIC LIBRA